

УДК 616.98:578.828ВІЛ:616.831:576.31

<https://doi.org/10.26641/2307-0404.2018.1.124925>

L.R. Shostakovych-Koretskaya*, **MORPHOLOGICAL CHARACTERISTICS OF**
K.Y. Lytvyn*, **BRAIN LESIONS IN HIV POSITIVE PATIENTS**
Z.O. Chykarenko*,
T.V. Usenko**,
V.O. Logvinenko***

SE «Dnipropetrovsk medical academy of Health Ministry of Ukraine»*

Department of Infectious Diseases

(Chief - MD, PhD, Professor L.R. Shostakovych-Koretskaya)

V. Vernadsky str., 9, Dnipro, 49044, Ukraine

e-mail: k-lytvyn@ukr.net

CE «Dnipropetrovsk Regional Children's Clinical Hospital»**

Pathoanatomical Department

(Head Physician – O.L. Khytryk)

Kosmichna str., 31, Dnipro, 49100, Ukraine

CE «Dnipropetrovsk City Clinical Hospital N 21»***

Pathoanatomical Department

(Head Physician – L.V. Tymofieieva)

Kanatna str., 17, Dnipro, 49006, Ukraine

ДЗ «Дніпропетровська медична академія МОЗ України»*

кафедра інфекційних хвороб

(зав. – д. мед. н., проф. Л.Р. Шостакович-Корецька)

вул. В. Вернадського, 9, Дніпро, 49044, Україна

КЗ «Дніпропетровська обласна дитяча клінічна лікарня»**

патологоанатомічне відділення

(голов. лікар – О.Л. Хитрик)

вул. Космічна, 13, Дніпро, 49100, Україна

КЗ «Дніпропетровська міська клінічна лікарня № 21 ім. професора Є.Г. Попкової»***

патологоанатомічне відділення

(голов. лікар – Л.В. Тимофеева)

вул. Канатна, 17, Дніпро, 49006, Україна

Key words: HIV infection, pathology, morphology, brain, mortality

Ключові слова: ВІЛ-Інфекція, патологія, морфологія, головний мозок, летальність

Abstract. Morphological characteristics of brain lesions in HIV infection. Shostakovych-Koretskaya L.R., Lytvyn K.Y., Chykarenko Z.O., Usenko T.V., Logvinenko V.O. Currently, diseases of the central nervous system are a common cause of death of patients with HIV infection. The article presents results of retrospective analysis of etiologic structure of 186 lethal cases and typical pathological changes of brain tissue of patients aged 21 to 61 years who had confirmed diagnosis of HIV and died of diseases associated with CNS damage in the Municipal infectious hospital in the city of Dnipro (Ukraine) in the period from 2011 to 2016. The most common causes of death in patients with HIV infection and CNS infection were cerebral tuberculosis (75.0%) including co-infection (n = 35) and meningoencephalitis that developed as a result of yeast fungal (15.6%). In the study of neuropathological processes in the autopsy material of the brain tissue of patients with HIV, various multifocal and diffuse morphological changes have been identified that can be presented in this work in the form of 4 groups: 1) Multiple nonspecific changes associated with both direct action of HIV and co-factors: infection, inflammation, hypoxia, etc., 2) Viral-induced vasculitis with hemorrhages, 3) Subacute aseptic encephalitis, 4) HIV-associated opportunistic infections. General pathomorphological changes in brain tissue are revealed that can cause similarities of clinical manifestations, can complicate differential diagnosis of cerebral lesions of various etiologies, and lead to a divergence of pre and postmortal diagnoses.

Реферат. Морфологічні характеристики ураження головного мозку у ВІЛ-позитивних пацієнтів. Шостакович-Корецька Л.Р., Литвин К.Ю., Чикаренко З.О., Усенко Т.В., Логвіненко В.О. На цей час захворювання центральної нервової системи є частотою причиною смерті пацієнтів з ВІЛ-інфекцією. У роботі представлені результати ретроспективного аналізу етіологічної структури 186 летальних випадків і характерні патологічні зміни тканини мозку пацієнтів, у віці від 21 до 61 року, які мали підтверджений діагноз ВІЛ і померли від захворювань, пов'язаних з ураженням центральної нервової системи, в інфекційній лікарні міста Дніпро (Україна) в період з 2011 по 2016 рік. Найбільш поширеними причинами летальності в цій групі

пацієнтів був церебральний туберкульоз (75,0%), у тому числі в складі коінфекції (n=35), і менінгоенцефаліти, які виникли внаслідок фунгемії дріжджових грибів (15,6%). При вивченні нейропатологічних процесів у мозковій тканині виявлені різні мультифокальні й дифузні морфологічні зміни, які в роботі представлені у вигляді 4-х груп: 1) множинні неспецифічні зміни, пов'язані як з прямою дією ВІЛ, так і супутніх чинників: інфекції, запалення, гіпоксія та ін.; 2) вірус-індуковані васкуліти з геморагіями; 3) підгострий асептичний енцефаліт; 4) ВІЛ-асоційовані опортуністичні інфекції. Спільні патологічні морфологічні зміни в тканині головного мозку, які були виявлені при дослідженні, можуть бути причиною частоті схожості клінічних проявів та ускладнювати диференціальну діагностику церебральних уражень різної етіології і призводити до розбіжності пре- і постмортального діагнозів.

Despite some positive changes in recent years, the epidemiological situation regarding HIV in Ukraine remains complicated: there is a high rate of HIV infection increase, which is one of the largest in the Dnipropetrovsk region comparing to the whole Ukraine (95.1 per 100 thousand of population). Mortality from AIDS in the Dnipropetrovsk region in 2016 was estimated at the level of 31.0 per 100 thousand of population, which is much higher than the same index for Ukraine (7.6 per 100 thousand) [1].

According to the literature, neurological disorders as the first manifestation of symptomatic HIV-infection occur in 10-20% of patients and about 60-70% of patients with advanced HIV infection; they have a clinical picture of neurological dysfunction and their development is associated with a significant increase in mortality risk [4, 5, 9].

The structure of HIV-associated brain lesions varies in different countries, but in common there is a high incidence of infectious diseases of the central nervous system such as tuberculosis, toxoplasmosis, cryptococcosis, progressive multifocal leukoencephalopathy [2, 4, 6, 8, 9]. Existing studies of the nervous tissue in patients who died from HIV / AIDS indicate presence of pathological changes in the brain tissue typical for slow neuroinfections such as focal demyelination. It is believed that these changes start to appear already in the early stages of the disease [3].

There is an assumption that a significant loss of neurons (brain neural weight is reduced to 18%) in patients with HIV may be the pathomorphological substrate for the development of dementia [7].

At the same time, there is not enough information about the structural changes of nervous system disorders that develop in patients with HIV infection. So, there are no explanations for frequent occurrence of focal demyelination, which is associated with the development of symptoms of HIV encephalopathy [6]. Changes caused by both the virus itself and toxic or infectious factors are not delineated. Pathomorphological changes characterizing general clinical picture that exists in many different etiology cases of CNS lesions remain not completely defined.

All these issues require further investigation.

Objective: To analyze cases of CNS-related mortality and to characterize the main pathomorphological patterns of brain tissue lesions in patients with HIV-associated disorders of the central nervous system (CNS).

MATERIALS AND METHODS

Retrospective data analysis with postmortem study of autopsied brain tissue of 186 patients aged 21 to 61 was conducted; the patients had laboratory confirmed diagnosis of HIV and died from CNS-related diseases in the Municipal Clinical Hospital of Infectious Diseases, city Dnipro (Ukraine), in the period 2011 - 2016.

RESULTS AND DISCUSSION

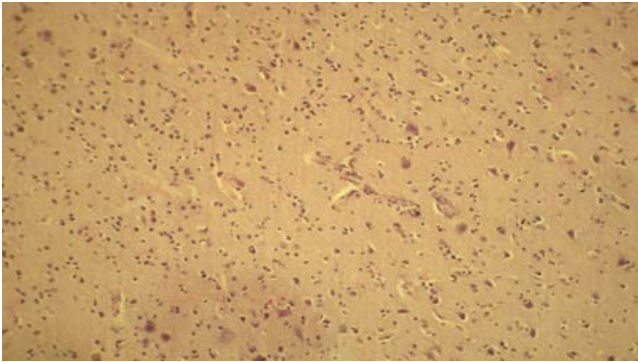
The most common diseases of the central nervous system among lethal cases in patients with HIV infection were cerebral tuberculosis (n = 125, 75.0%), including co-infection (dual and triple CNS infection, n=35) and meningoencephalitis, which developed as a consequence of systemic fungal infection of yeast fungi (n=29, 15.6%). The other lethal causes included EBV infection (n=23); cerebral toxoplasmosis (n = 18); secondary bacterial meningitis (n=11); progressive multifocal leukoencephalopathy (PML) (n=10); encephalitis caused by the herpes simplex virus (HSV 1-2 types) and cytomegalovirus CMV (n=9); primary central nervous system lymphoma (n=4).

Evaluation of neuropathological processes in autopsy material of brain tissue of patients with HIV/AIDS in most cases (> 90%) revealed various multifocal and diffuse brain lesions that can be considered as HIV-induced brain damages and/or the result of other infections and opportunistic diseases.

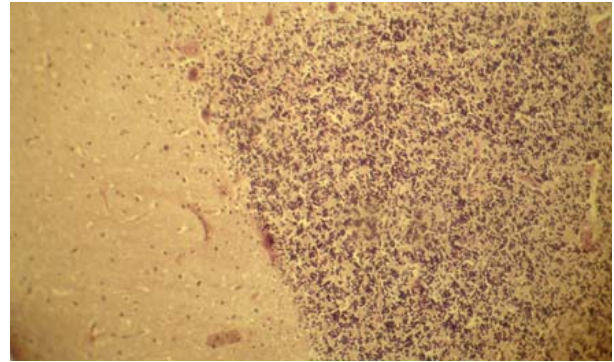
All autopsy findings were presented in four patterns:

1st Pattern: nonspecific features that were related both to the direct effect of HIV and co-factors: infections, inflammation, toxicity with signs of edema, nucleus tigrolysis of large neurons; and the loss of their processes (Fig. 1, 2).

The presence of vacuolization zones and the edema of laminar myelin layer were observed in most patients (Fig. 3).



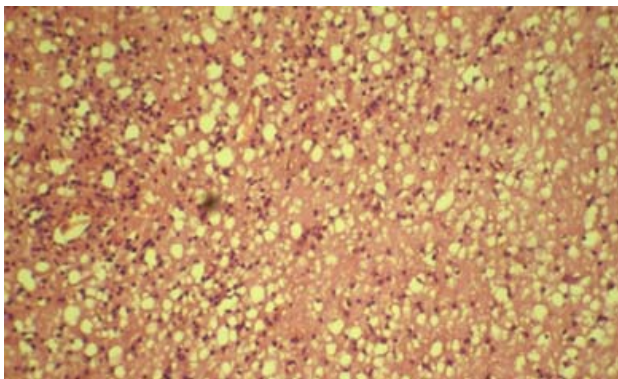
**Fig. 1. Brain tissue with edema, nuclei's tigrilysis of large neurons and the loss of their processes
H & E x150**



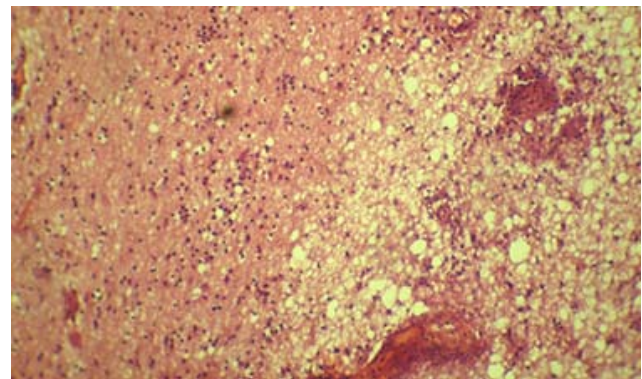
**Fig. 2. Cerebellum, edema, nuclei's tigrilysis of the pear-shaped neuron's with loss of processes
H&E. x150**

In all lethal cases, regardless of the diagnosis, there were pericellular and perivascular edema, hy-

perchromatosis of neurons nuclei, astrocyte reaction and multiple foci of demyelination identified (Fig. 4).



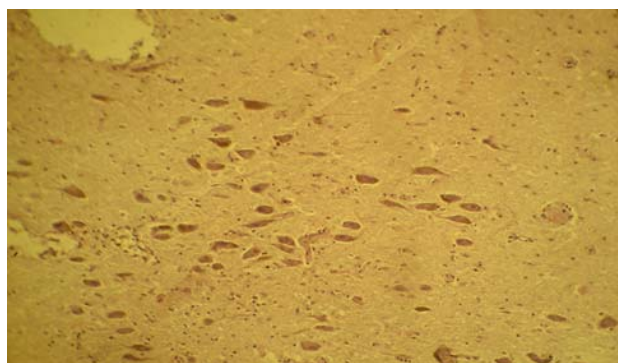
**Fig. 3. Vacuolization zones and lamellar myelin layer edema
H & E x150**



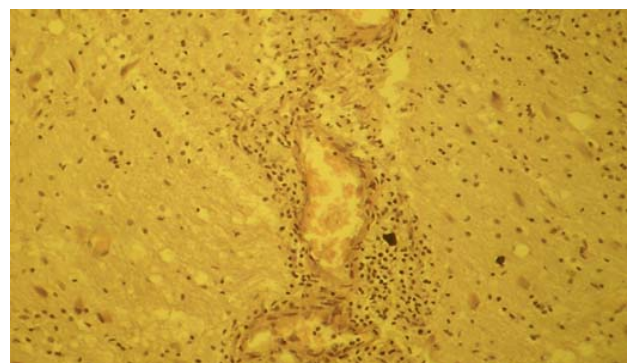
**Fig. 4. Multiple foci of demyelination
H & E x150**

2nd Pattern: Virus-induced vasculitis.
Vasculitis in patients with HIV infection was a frequent phenomenon which included poor pig-

mentation of the substantia nigra, formation of cysts, necrobiosis of neurons (Fig. 5, 6).



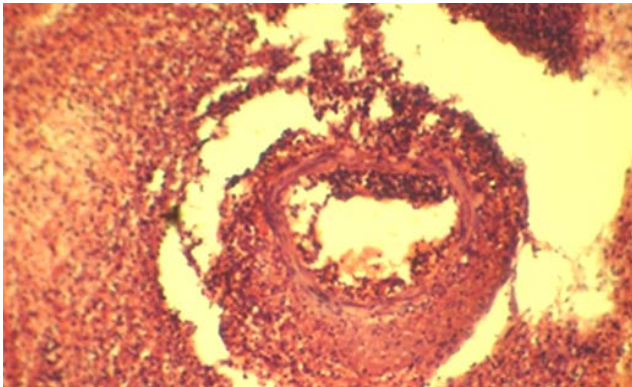
**Fig. 5. Substantia nigra, focal depigmentation of dopaminergic neurons, clusters of lymphocytes around of capillaries
H&E x150**



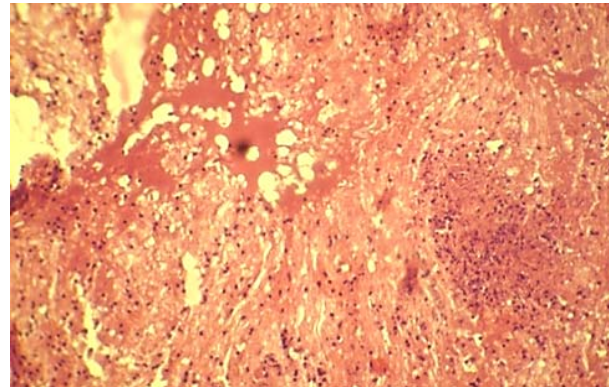
**Fig. 6. Virus induced vasculitis in the form of clusters of lymphoid and glial cells, necrobiosis of large neurons
H&E. x150**

In some cases there was a suppurative necrotizing vasculitis and purulent melting of brain

tissue (Fig.7), hemorrhages, brain tissue necrosis with the formation of cysts (Fig. 8).



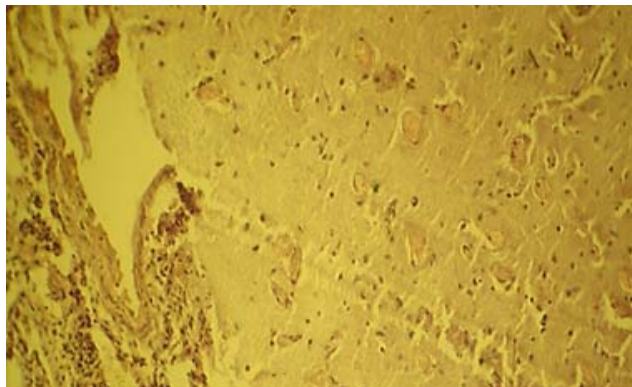
**Fig 7. Purulent melting of brain tissue
H&E x 150**



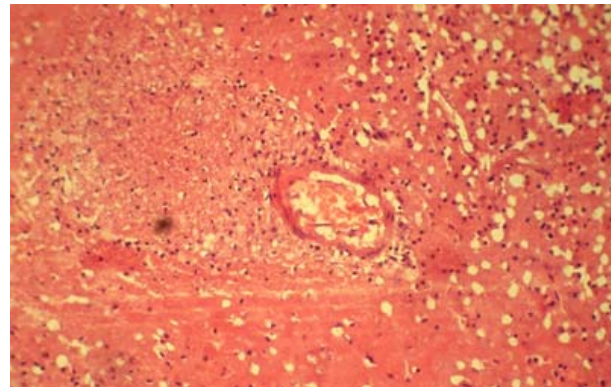
**Fig. 8. Hemorrhagic focus with accumulation of hemosiderophages, areas of necrosis, hemorrhage and cyst formation zones
H&E. x150**

3rd Pattern: aseptic subacute encephalitis. In the cerebral cortex, white matter and other areas in patients with HIV-associated CNS lesions signs of

subacute aseptic encephalitis, lymphocyte and macrophage infiltration, brain tissue necrosis and proliferation of microglia were found (Fig. 9, 10).



**Fig. 9. Meningitis features with the thickening of vascular walls, lymphoid infiltration (green arrow) in the background of the picture of subacute encephalitis (violet arrow)
H&E. x150**

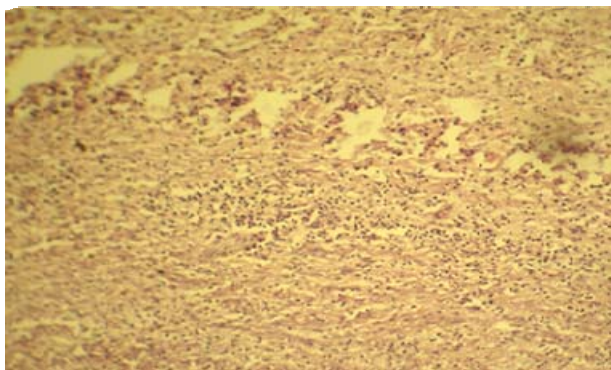


**Fig. 10. Subtotal brain tissue necrosis involving arterial vessels with changes typical for subacute encephalitis (upper right corner)
H&E. x150**

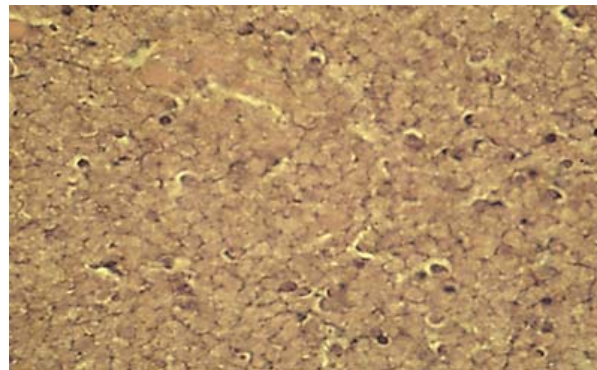
4th Pattern: specific changes related to certain HIV-associated CNS infections such as cerebral Tuberculosis, cerebral Toxoplasmosis and fungal infections.

Changes in brain caused by Cryptococcus were presented by clusters of yeast fungi Cryptococcus with necrosis of brain tissue, formation of cysts, the black substance focal depigmentation (Fig. 13). Pathological changes of brain in patients with Toxoplasmic encephalitis were presented by Trophozoites of toxoplasma in brain tissue, neuronophagia and edema (Fig. 14).

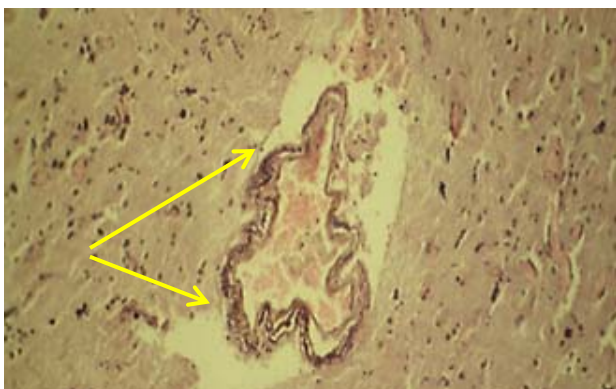Changes caused by M. tuberculosis were presented by exudative-necrotic encephalitis with a large area of caseous necrosis and proliferation of astrocytes (Fig. 11, 12).



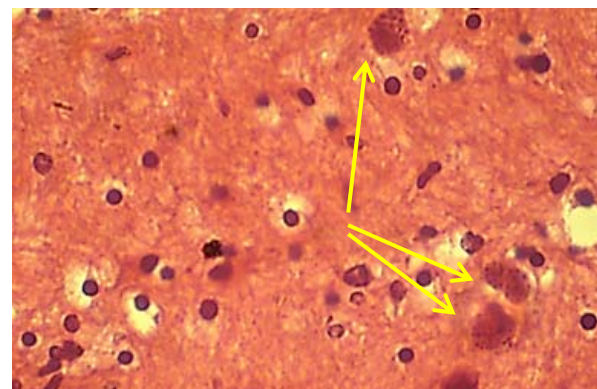
**Fig. 11. Exudative-necrotic encephalitis caused by *M.tuberculosis* with a large zone of caseous necrosis and macrophage-leukocyte infiltration, vasculitis
H&E x150**



**Fig. 12. Central nervous system tuberculosis with proliferation of astrocytes
H&E. x600**



**Fig 13. Diffuse vasculitis, angiomas, aggregations of colonies of fungi spores (yellow arrows) around arterial vessel
H&E x150**



**Fig. 14. Trophozoites of toxoplasma (yellow arrows) in brain tissue, neuronophagia and edema
H&Ex600**

CONCLUSIONS

1. Neurological lesions are specific complications of HIV infection. This phenomenon is confirmed by analysis of autopsy series that show the presence of neuropathological changes
2. Neuropathological examination of post – mortem brain tissue of the HIV/ AIDS patients revealed the multifocal and diffuse brain tissue lesions in 90% of lethal cases and in 75% of them due to tuberculosis. Neurological manifestations of HIV infection in real practice are often non-specific, due to

- the complex of comorbidities, including toxic factors, and not always correlating with the severity of morphological signs of CNS damage. Difficulties in differential diagnosis of CNS disorders in patients with HIV infection may lead to discordance between pre- and postmortem diagnosis.
3. Thus, further comprehensive studies for the advancement of our knowledge of neurological problems of HIV and improvement of diagnosis and treatment of patients with HIV/AIDS are required.

REFERENCES

1. [HIV infection in Ukraine]. *Informatsiynyy byulet*!. 2017;47:148. Ukrainian.
2. Zinserling VA, Komarova DV, Vasilieva MV, Karev VE. [Pathological anatomy of HIV infection based on St. Petepbug's materials]. *Archives of Pathology*. 2003;65(1):42-5. Russian.
3. Zinserling VA. [The most important problem of morphological diagnosis in HIV infection. HIV infection

and immunosuppression]. Archives of Pathology. 2009;2:31-37. Russian.

4. Bilgrami M, O'Keefe P. Neurologic diseases in HIV-infected patients. Handbook of clinical neurology. 2014 Jan;121:1321-44.

5. Masliah E, DeTeresa RM, Mallory ME, Hansen LA. Changes in pathological findings at autopsy in AIDS cases for the last 15 years. Aids. 2000 Jan; 14(1):69-74.

6. Sonkar SK, Gupta A, Atam V, Chaudhary SC, Tripathi AK, & Sonkar GK. Clinical profile of neurological manifestation in Human Immunodeficiency Virus-

positive patients. N Am J Med Sci. 2012 Nov;4(11):596-9. doi: 10.4103/1947-2714.103329.

7. Everall IP, Luthert PJ, Lantos PL. Neuronal loss in the frontal cortex in HIV infection. The Lancet. 1991;337(8750):1119-21.

8. Bolokadze N, Gabunia P, Ezugbaia M, Gatsere- lia L, Khechiashvili G. Neurological complications in patients with HIV/AIDS. Georgian Med News. 2008;165:34-8.

9. Santosh V, Shankar SK, Das S, Pal L, Ravi V, Desai A, Swamy HS. Pathological lesions in HIV positive patients. Indian J Med Res. 2013 Jun; 37(6):1219-26.

СПИСОК ЛІТЕРАТУРИ

1. ВІЛ-інфекція в Україні // Інформ. бюлетень. – 2017. – № 47. – С. 148.

2. Патологическая анатомия ВИЧ-инфекции по материалам Санкт-Петербурга / В.А. Цинзерлинг, Д.В. Комарова, М.В. Васильева [и др.] // Архив патологии. – 2003. – № 1. – С. 42-45.

3. Цинзерлинг В.А. Самая важная проблема морфологического диагноза / В.А. Цинзерлинг // Архив патологии. – 2005. – № 1. – С. 42; 2009. – № 2. – С. 31-37.

4. Bilgrami M. Neurologic diseases in HIV-infected patients / M. Bilgrami, P. O'keefe // Handbook Clinical Neurology. – 2014. – Vol. 121. – P. 1321-1344.

5. Changes in pathological findings at autopsy in AIDS cases for the last 15 years / E. Masliah, R.M. DeTeresa, M.E. Mallory, L.A. Hansen // Aids.- 2000.- N 14. – P. 69-74.

6. Clinical profile of neurological manifestation in Human Immunodeficiency Virus-positive patients / S.K. Sonkar, A. Gupta, V. Atam [et al.] // North Am. J. Medical Sciences. – 2012. – Vol. 4, N 11. – P. 596.

7. Everall I. P. Neuronal loss in the frontal cortex in HIV infection / I.P. Everall, P.J. Luthert, P.L. Lantos // Lancet. – 1991. – Vol. 337, N 8750. – P. 1119-1121.

8. Neurological complications in patients with HIV/AIDS / P. Gabunia, M. Ezugbaia, L. Gatsere- lia [et al.] // Georgian Med. News. – 2008. – Vol. 165. – P. 34-38.

9. Pathological lesions in HIV positive patients / Vani Santosh, S.K. Shankar, Das Sarala [et al.] // Indian J. Medical Research. – 2013. – Vol. 137, N 37(6). – P. 1219-1226.

Стаття надійшла до редакції
14.11.2017

