



Politecnico di Torino

## Porto Institutional Repository

[Proceeding] Limb reconstruction with knee mega-prosthesis in patients with distal femur primary tumours: gait analysis and alignment evaluation

*Original Citation:*

M. Boffano, C. Bertolo, V. Agostini, M. Carlone, M. Knaflitz, L. Marcantonio, G. Massazza, R. Piana (2014). *Limb reconstruction with knee mega-prosthesis in patients with distal femur primary tumours: gait analysis and alignment evaluation*. In: 27th Annual Meeting of the European Musculo-Skeletal Oncology Society (E.M.S.O.S.), Vienna, Austria, May 21-23, 2014. p. 67

*Availability:*

This version is available at : <http://porto.polito.it/2545344/> since: May 2014

*Publisher:*

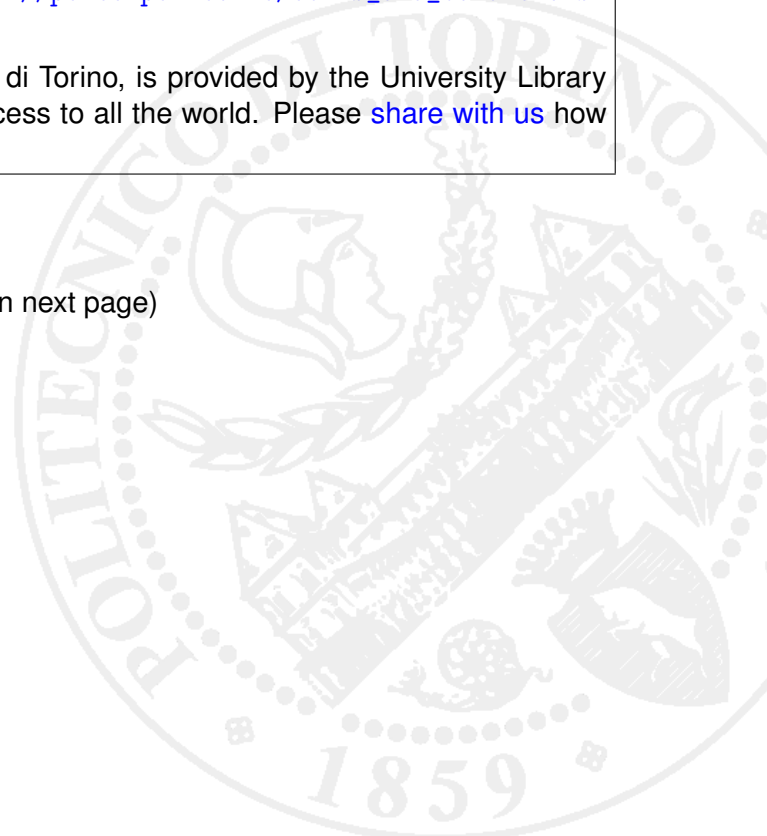
Reinhard Windhager, Philipp Funovics

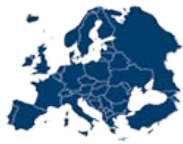*Terms of use:*

This article is made available under terms and conditions applicable to Open Access Policy Article ("Public - All rights reserved") , as described at [http://porto.polito.it/terms\\_and\\_conditions.html](http://porto.polito.it/terms_and_conditions.html)

Porto, the institutional repository of the Politecnico di Torino, is provided by the University Library and the IT-Services. The aim is to enable open access to all the world. Please [share with us](#) how this access benefits you. Your story matters.

(Article begins on next page)





## P11.12

**Proximal femur replacements about primary bone tumors by means of revision endoprostheses, 15 years experience**

**I. Mikailov**, D. Ptashnicov, P. Zasluskiy, P. Grigorev;  
Vreden Russian Reserch Institute of Traumatology and Orthopedics,  
St. Petersburg, Russian Federation.

The purpose of the study was to evaluate medium-term results of treatment of patients with primary tumors of the proximal femur, by means of revision endoprostheses.

Between 1997 and 2012, 76 patients underwent primary limb preservation with use of revision implant systems in the primary total hip arthroplasty. The patients' age ranged from 24 to 78 years. Distribution by nosology is the following: chondrosarcoma 23 (30,2%), GCT 25 (32,9%), osteosarcoma 4 (5,3%), fibrous dysplasia 10 (13,2%), other malignant tumors 14 (18,4%). The size of the defect of the proximal femur after removal of the tumor varied from 6 to 18 cm. Clinical and radiographic outcome of treatment was assessed by the ISOLS system.

Clinical evaluation was performed in 68 patients. We received the following functional outcomes: excellent 24 (35,3%), good 41 (60,2%), satisfactory 3 (4,5%). X-ray evaluation was performed in 62 patients. The results were as follows: excellent 17 (27,4%), good 32 (51,7%), satisfactory 10 (16,1%), unsatisfactory 3 (4,8%). We observed the following complications: dislocation of the endoprosthesis 6 (7,9%), recurrence of the tumor at 5 (6,6%), infectious 4 (5,3%) and there was 1 (1,2%) case of the fracture of the implant. Overall complication rate was 21%.

We applied the revision implant systems of hip in cases of tumors of the proximal femur, and the analysis of medium-term results showed mostly excellent and good results in 95,5%. Therefore we consider these implants give good functional outcome without compromising the oncological treatment component.

## P11.13

**A new prosthetic model of proximal femur after resection for bone metastases: preliminary results**

**N. Salducca**, A. Rita, B. Rossi, C. Zoccali, L. Favale, R. Biagini;  
Istituto Regina Elena, Roma, Italy.

Prosthetic replacement of the proximal femur may be required to treat primary bone tumors or destructive metastases either with impending or established pathological fracture.

We have assessed the clinical and functional outcome of using INTEGRA (Groupe Lépine) modular tumor prosthesis to reconstruct the proximal femur in 10 patients between Feb. 2013 and Dec. 2013. There were 7 females and 3 males with a mean age of 69.6 years (range 55-81 years).

In all patients the procedure was undertaken for metastases and four patients presented with a pathological fracture. In one case occurred failed fixation of previous pathological fracture. The length of resection was between 3 and 14 centimeters. All the prosthesis were cemented. In 3 patients we performed also an acetabular replacement. Functional analysis according to MSTs was performed.

Two patients died due to the oncological disease. No patient needed revision surgery for dislocation. None had implant breakage, loosening or fracture. One infection occurred but no revision was performed and the patient was treated conservatively with antibiotics.

We conclude that the Integra modular prosthesis is an excellent and a low cost device to reconstruct proximal femur because of its versatility, especially in patients who need small resection (3-4 cm) where it's possible to spare the lesser trochanter and the insertion of iliopectus muscles. It's very simple to use this prosthesis because of a low number of components. A low incidence of complications occurred and an acceptable function resulted in patients with metastatic tumors and pathological fractures.

## P11.14

**Results of 70 cemented fixed hinge megaprosthesis of the distal femur after resection of a primary bone tumor**

**C. Heyberger**, A. Babinet, P. Boudou-Rouquette, F. Larousserie, P. Anract, **D. J. Biau**;  
Hopital Cochin, Paris, France.

Introduction: Mechanical failure is one of the main causes of revision after reconstruction with a megaprosthesis of the distal femoral resection. Although most centres use rotating hinges, we kept to the fixed hinge design. We present the medium to long term results of a retrospective case series of fixed hinge cemented megaprostheses. Methods: Seventy patients were included. For 52 patients, this reconstruction was a primary (at the time of resection) and for 18 it was a revision (history of previous resection). The main outcome criterion was the cumulative probability of revision of the implants for any reason. Function and quality of life was assessed at maximum follow-up regardless of the status of the implants.

Results: The cumulative incidences of revision for any reason were 9.8% (3.9-18.8), 13.2% (6.1-23.1) et 20.7% (10.7-33.1) at two, five and 10 years respectively. The cumulative incidences of revision for mechanical reason were 6.6% (2.1-14.8), 6.6% (2.1-14.8) and 14.1% (5.9-25.8) at similar follow-up times. Eight patients underwent a revision of one or more of the components for mechanical reason; three patients were revised for infection. Patient overall survival was 64% (52-79) at 10 years. At last follow-up, the median TESS score was 78% (IQR : 64-87), the median MSTs was 77% (66-91), and the physical component of the SF36 was 44 (36-50) and the mental component of the SF36 was 48 (33-54).

Conclusion: Custom made cemented fixed hinge megaprosthesis of the distal femur provide good mechanical mid to long term results; infection remains a challenge.

## P11.15

**Limb reconstruction with knee mega-prosthesis in patients with distal femur primary tumours: gait analysis and alignment evaluation**

**M. Boffano**<sup>1</sup>, C. Bertolo<sup>1</sup>, V. Agostini<sup>2</sup>, M. Carlone<sup>3</sup>, M. Knaflietz<sup>2</sup>, L. Marcantonio<sup>3</sup>, G. Massazza<sup>3,4</sup>, R. Piana<sup>1</sup>;

<sup>1</sup>S.C. Oncologic and Reconstructive Orthopaedics AO Città della Salute e della Scienza di Torino - CTO Hospital, Torino, Italy,

<sup>2</sup>Department of Electronics and Telecommunication - Polytechnic University of Turin, Torino, Italy, <sup>3</sup>S.C. Physical Medicine and Rehabilitation - AO Città della Salute e della Scienza di Torino - S. Giovanni Battista Hospital, Torino, Italy, <sup>4</sup>University of Turin, Torino, Italy.

Introduction: The aim of this study was the functional evaluation and lower limb alignment assessment of patients with a modular knee prosthesis after distal femur resection for primary bone tumour.

Materials and methods: 15 patients affected by distal femur tumor and treated with a megaprosthesis implant (6 females and 9 males, mean age: 41 years, range: 15-74 years) and 15 controls were recruited for the study. For each subject the function evaluation included an instrumented gait analysis, while only patients underwent a teleradiography and a latero-lateral X-ray projection of the knee.

Results: The duration of the stance phase of gait was shortened in the prosthetic limb with respect to the contralateral limb (57.5±3.6% gait cycle vs. 60.9±4.8% gait cycle, P = 0.01), with a correspondent increase of the swing phase. The prosthetic limb also showed an altered knee joint kinematic curve during gait, with a flexion deficit at load response with respect to the contralateral limb (4.5±3.6° vs. 13.4±5.0°, P = 0.000003). Abnormal timing in the muscle activation intervals were observed for tibialis anterior, gastrocnemius lateralis and rectus femoris of the prosthetic limb. The prosthetic limb was found to be misaligned with respect to the contralateral limb, both for the femorotibial (P<0.05) and the ankle joints (P<0.05).

Conclusions: Gait analysis performed widely in reference centres could lead to a change in the design of megaprostheses to improve the function and prevent degenerative changes in not involved joint. A multicentric expertise is mandatory.