

Contents lists available at ScienceDirect

European Journal of Obstetrics & Gynecology and Reproductive Biology

journal homepage: www.elsevier.com/locate/ejogrb

Full length article

Prenatal ultrasound diagnosis of fetal chest wall cystic lymphangioma: An Italian case series



Gabriele Saccone^{a,b,*}, Lavinia Di Meglio^{a,b}, Letizia Di Meglio^{a,b}, Fabrizio Zullo^a, Mariavittoria Locci^a, Fulvio Zullo^a, Vincenzo Berghella^c, Aniello Di Meglio^{a,b}

^a Department of Neuroscience, Reproductive Sciences and Dentistry, School of Medicine, University of Naples Federico II, Naples, Italy

^b Diagnosi Ecografica e Prenatale di A.Di Meglio, Naples, Italy

^c Division of Maternal-Fetal Medicine, Department of Obstetrics and Gynecology, Sidney Kimmel Medical College of Thomas Jefferson University, Philadelphia, PA, USA

ARTICLE INFO

Article history:

Received 14 March 2019

Accepted 16 March 2019

Available online xxx

Keywords:

MRI

Fetal malformation

Abortion

Genetic

NIPT

ABSTRACT

Fetal lymphangioma is a rare congenital malformation of lymphatic system that involve the skin and the subcutaneous tissue. The vast majority of the lymphangioma occurs in the neck. More rarely lymphangiomas may occur in the axillary region, including chest wall. Our consecutive case series study included three cases of fetal chest wall cystic lymphangiomas. In our cohort, fetal chest wall cystic lymphangiomas were the 18.8% of the all cases of lymphangiomas of axillary region. In all the three cases no other fetal abnormalities were evaluated, and the chest wall cystic lymphangiomas were unilateral, honeycombed in appearance, with multiple echo-free area of varying size in the mass, with no color flow on Doppler sonography, and with a trend to increase during the gestation. The incidence of chromosomal abnormalities was 33.3%, with one case out of the three being trisomy 21. The literature review revealed only seven cases of fetal chest wall cystic lymphangiomas. The cases were not associated with other abnormalities, nor with abnormal karyotype and only one case of fetal death was reported. Three women delivered vaginally. In summary, fetal chest wall cystic lymphangioma is a very rare malformations with only seven cases reported in the literature. This malformation is usually not associated with abnormal karyotype or other abnormalities and the neonatal outcome is favorable after surgical removal. Spontaneous vaginal delivery may be a safe approach for delivery women with fetal chest wall cystic lymphangioma.

Condensation: Fetal chest wall cystic lymphangioma is a very rare malformations with only seven cases reported in the literature. This malformation is usually not associated with abnormal karyotype or other abnormalities and the neonatal outcome is favorable after surgical removal. Spontaneous vaginal delivery may be a safe approach for delivery women with fetal chest wall cystic lymphangioma.

© 2019 Elsevier B.V. All rights reserved.

Introduction

Fetal lymphangioma is a rare congenital malformation of lymphatic system that involve the skin and the subcutaneous tissue. Fetuses with congenital lymphangioma have a significantly increased risk of chromosomal abnormalities, including trisomy 21 [1].

The vast majority of the lymphangioma occurs in the neck, and are usually named as cystic hygromas [2,3]. More rarely lymphangiomas may occur in the axillary region, including

chest wall, trunk, pelvic, extremities, and retroperitoneal area [1,4]. Outcomes of babies with fetal lymphangioma and with normal karyotype is usually good, with success of surgical intervention depends mainly on size and location [1,2]. The chest wall cystic lymphangioma is a rare location of fetal lymphangiomas, with very few cases reported in the literature [5].

Objective

The aim of this case series study, with literature review, was to report all consecutive cases of fetal chest wall cystic lymphangioma referred to our institution from January 2010 to January 2019.

* Corresponding author at: Department of Neuroscience, Reproductive Sciences and Dentistry, School of Medicine, University of Naples Federico II, Naples, Italy.
E-mail address: gabriele.saccone.1990@gmail.com (G. Saccone).

Case series

During the study period, 16 cases of lymphangiomas of axillary region were identified. Of them three (18.8%) were fetal chest wall cystic lymphangiomas.

Case 1. A 29-year-old prima gravida woman was referred to our institution at 32 weeks of gestation for third trimester scan. Previous sonography at 13 weeks was consistent with gestational age, and nuchal translucency was 1.1 mm. Second trimester anatomy scan was regular.

Ultrasound examination showed a multilocular, cyst mass of 48 x 19 mm in size, located laterally in the right side of the fetus in the area of the chest wall, without color flow imaging (Fig. 1). The placenta appeared with no abnormalities, and the amniotic fluid amount was normal. No other anomalies were identified. Amniocentesis revealed normal karyotype (46, XY). 34 weeks scan showed normal fetal growth with enlargement of the cystic mass to 54 x 31 mm. The woman underwent planned cesarean delivery at 39 weeks of gestation due to breech presentation, and a 3,250 g-sized male infant was delivered with APGAR score of 9 and 9, at 1st and 5th minutes, respectively. The patient postoperative course was uncomplicated, and she was discharged at day 4 after cesarean delivery.

The pediatric surgeon decided for a conservative management with observation of the cystic mass. At 6 months follow-up the baby presented for the follow-up, and the lymphangioma had decreased in size (Figs. 2 and 3).

Case 2. A 38-year-old multiparous woman was referred to our institution at 16 weeks of gestation. First trimester scan was consistent with gestational age, and nuchal translucency was 3.9 mm.

16-weeks ultrasound examination showed a multilocular, cyst mass of 13 x 25 x 31 mm in size, located posteriorly on the left side of the fetus in the lower chest wall, without color flow imaging.

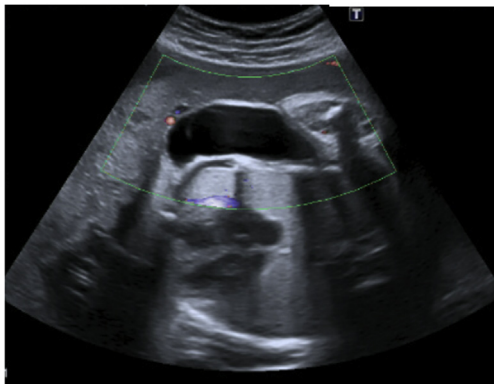
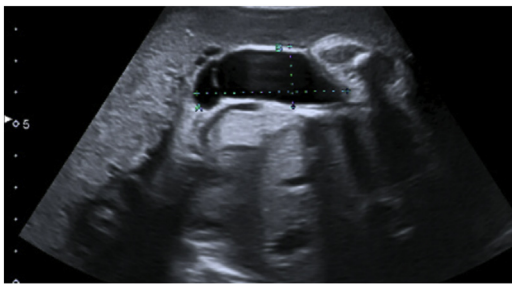


Fig. 1. Sonographic appearance of fetal chest wall cystic lymphangioma at 32 weeks of gestation (Case 1).

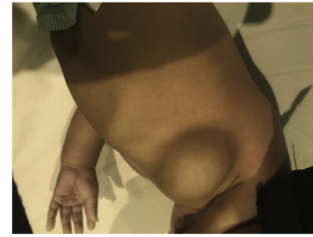

Fig. 2. Appearance of chest wall cystic lymphangioma at the 6-months visit follow-up, later view (Case 1).

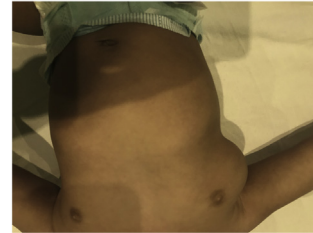


Fig. 3. Appearance of chest wall cystic lymphangioma at the 6-months visit follow-up, frontal view (Case 1).

Ultrasound scan also showed short femur, and common atrioventricular canal.

Amniocentesis revealed trisomy 21, and the patient opted for induced termination of pregnancy. Macroscopic and microscopic evaluations revealed a fetal chest cavernous lymphangioma.

Case 3. A 27-year-old prima gravida woman was referred to our institution at 22 weeks of gestation for second trimester anatomy scan. Previous sonography at 12 weeks was consistent with gestational age, and nuchal translucency was 1.5 mm. At 13 weeks non-invasive prenatal testing using cell-free fetal DNA showed normal karyotype (46, XX).

The 22-week scan showed normal growth, with the amount of amniotic fluid and fetal movements showing no abnormalities. An abnormal unilateral left-side mass connected to the fetal chest of 17 x 29 x 35 mm was identified. The color Doppler revealed no flow. No other abnormalities were identified.

The couple decided to interrupt the gestation because of the abnormal fetal finding and declined amniocentesis, and evaluation of the aborted fetuses.

Literature review

The search for the systematic review was conducted using MEDLINE, EMBASE, Scopus, ClinicalTrials.gov, OVID and Cochrane Library as electronic databases. The citations were identified with the use of a combination of the following text words: “fetal chest,” “lymph,” “lymphangioma,” “chest wall,” “circumscriptum” and “hygromas” from inception of each database through February 2019. Review of articles also included the abstracts of all references retrieved from the search. No restrictions for language or geographic location were applied.

Six studies, [5–10] including seven cases, were identified as relevant and included in the systematic review (Table 1, Fig. 4). Five of the six studies were case reports, while Goldstein et al. [10] included two cases. Gestational age at diagnosis ranged from 15 to 38 weeks of gestation. Three cases were diagnosed in the third trimester, and in all of them second trimester anatomy scan revealed no abnormalities.

Table 1
Studies included in the systematic review.

	Study location	Maternal age	GA at diagnosis	Characteristics of the cyst	Size of the cyst at diagnosis	Size of the cyst at US follow-up	Abnormal karyotype	Associated abnormalities	Pregnancy outcome	Neonatal outcome
Rasidaki 2004 [5]	Greece	25 years	28 weeks	Multilocular unilateral located posteriorly on the left side of the fetal chest	10 × 22 × 29 mm	13 × 33 × 43 at 30 weeks	No	No	Scheduled CD at 38 weeks	Surgical removal at 2 months
Masood 2010 [6]	Pakistan	38 years	38 weeks	Multilocular unilateral mass extending from the scapula to the lumbosacral region on the left side of the fetal chest wall	140 × 110 mm	–	No	No	SVD at 40 weeks	Surgical removal at day 4
Hayashi 2005 [7]	Japan	28 years	18 weeks	Multilocular bilateral located anteriorly on the fetal chest	54 × 30 mm (left); 34 × 30 mm (right)	94 × 45 mm (left); 70 × 48 mm (right); at 24 weeks	No	Syndactyly of the left third and fourth finger	IUD at 25 weeks	–
Kaufman 1996 [8]	USA	30 years	36 weeks	Septated cystic mass in the left fetal chest	7 × 8 × 6 mm	–	No	No	SVD at 38 weeks	Surgical removal at weeks 2
Lu 2015 [9]	China	31 years	19 weeks	Multilocular unilateral located on the left side of the fetal chest	29 × 32 × 31 mm	123 × 92 × 110 mm	No	No	Scheduled CD at 38 weeks	Surgical removal at day 4
Goldstein 2006¹⁰ #1	Israel	25 years	15 weeks	Multilocular bilateral located on the fetal chest	Not reported	Not reported	No	No	I-TOP	–
Goldstein 2006¹⁰ #2	Israel	30 years	22 weeks	Unilateral mass located on fetal chest	Not reported	Not reported	No	No	SVD at 40 weeks	Surgical removal a month 1
Saccone#1	Italy	29	32 weeks	Multilocular unilateral mass located on the right side of the fetal chest	48 × 19 mm	54 × 31 mm at 34 weeks	No	No	Scheduled CD at 39 weeks	Expectant management
Saccone#2	Italy	38	16 weeks	Multilocular unilateral located posteriorly on the left side of the fetal chest	13 × 25 × 31 mm	–	Trisomy 21	Common atrioventricular canal	I-TOP	–
Saccone#3	Italy	27	22 weeks	Multilocular unilateral located posteriorly on the left side of the fetal chest	17 × 29 × 35 mm	–	Not performed	No	I-TOP	–

US, ultrasound; GA, gestational age; SVD, spontaneous vaginal delivery; IUD, intrauterine fetal death; CD, cesarean delivery; I-TOP, induced termination of pregnancy.

In all the cases the mass was described as a multilocular septated cystic mass honeycombed in appearance, with multiple echo-free area of varying size in the mass, and with no color flow on Doppler. Size of the mass ranged from 6 mm to the giant mass of 123 mm described by Lu et al. In all the cases, the masses increased through the gestation.

Spontaneous vaginal delivery was the most common mode of delivery (3/7). Two women underwent planned cesarean delivery at term, one woman opted for induced termination of pregnancy, and in one case at 25 weeks ultrasound examination revealed fetal death with pleural effusion and labor was induced by using laminaria tents and prostaglandin E1.

In all the cases no associated abnormalities were reported at the time of the ultrasound scans, but autopsy of the case reported by Hayashi et al. revealed syndactyly of the left third and fourth finger. No abnormal karyotype was reported in any of the included cases. In the 6 cases of the live-born infant surgical removal was successful performed.

Discussion

Our consecutive case series study included three cases of fetal chest wall cystic lymphangiomas. In our cohort, fetal chest wall cystic lymphangiomas were the 18.8% of the all cases of lymphangiomas of axillary region. In all the three cases no other

fetal abnormalities were evaluated, and the chest wall cystic lymphangiomas were unilateral, honeycombed in appearance, with multiple echo-free area of varying size in the mass, and with no color flow on Doppler sonography. The incidence of chromosomal abnormalities was 33.3%, with one case out of the three being trisomy 21.

The literature review revealed only seven cases of fetal chest wall cystic lymphangiomas. The cases were not associated with other abnormalities, nor with abnormal karyotype and only one case of fetal death was reported. Three women delivered vaginally. Notably, Kaufman et al. performed decompression of the fetal axillary lymphangioma before delivery to prevent dystocia. [8]

Lymphangiomas can occur anywhere in the skin and the mucous membranes. More than 80% of the fetal lymphangiomas are located in the neck, and fetal chest wall cystic lymphangiomas are very rare. Although histologically it is a benign disorder, it has a propensity for rapid growth and local invasion into the muscle, and bone and may lead to decreased quality of life. Fetal chest lymphangiomas may be unilocular or multilocular and the lesions range in size from several millimeters to much larger giant lymphangioma [1,2]. The bigger fetal chest wall cystic lymphangioma reported in the literature was 123 mm (Table 1).

A significant association between lymphangiomas and chromosomal abnormalities have been reported in the literature. The

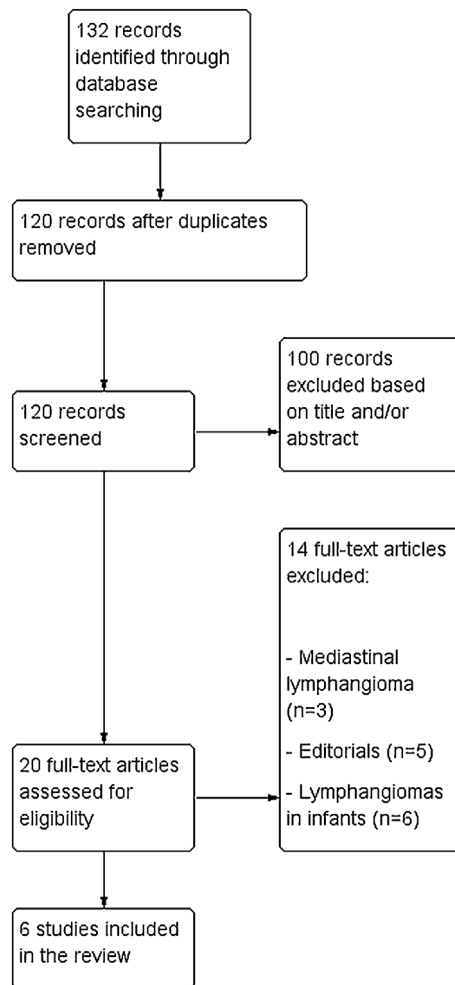


Fig. 4. Systematic review flow chart.

most common type is Turner syndrome and other abnormalities include trisomy 21, trisomy 18, trisomy 13, triploidy, and copy number variants. Therefore, when lymphangiomas were diagnosed in the antenatal period, karyotype examination is recommended along with serial ultrasound examinations. Our in case of fetal chest wall cystic lymphangiomas no cases of abnormal karyotype were reported. In our case series the only one case associated with abnormal karyotype, being trisomy 21, short femur and common atrioventricular canal were noticed.

Regarding the neonatal outcome, the favored treatment for fetal chest lymphangiomas is complete surgical excision. However, expectant management may be offered to the small lymphangiomas. Recent advance in sclerotherapy have expanded contemporary management options.

Conclusion

Fetal chest wall cystic lymphangioma is a very rare malformations with only seven cases reported in the literature. This malformation is usually not associated with abnormal karyotype or other abnormalities and the neonatal outcome is favorable after surgical removal. Spontaneous vaginal delivery may be a safe approach for delivery women with fetal chest wall cystic lymphangioma.

Disclosure

The authors report no conflict of interest.

Financial support

No financial support was received for this study.

References

- [1] Jiao-Ling L, Hai-Ying W, Wei Z, Jin-Rong L, Kun-Shan C, Qian F. Treatment and prognosis of fetal lymphangioma. *Eur J Obstet Gynecol Reprod Biol* 2018;231(December):274–9.
- [2] Li JL, Hai-Ying W, Liu JR, He QM, Chen KS, Yang J, et al. Fetal lymphangioma: prenatal diagnosis on ultrasound, treatment, and prognosis. *Eur J Obstet Gynecol Reprod Biol* 2018;231(December):268–73.
- [3] Molina FS, Avgidou K, Kagan KO, Poggi S, Nicolaidis KH. Cystic hygromas, nuchal edema, and nuchal translucency at 11–14 weeks of gestation. *Obstet Gynecol* 2006;107(March3):678–83.
- [4] Tongsong T, Luewan S, Khorana J, Sirilert S, Charoenratana C. Natural course of fetal axillary lymphangioma based on prenatal ultrasound studies. *J Ultrasound Med* 2018;37(May5):1273–81.
- [5] Rasidaki M, Sifakis S, Vardaki E, Koumantakis E. Prenatal diagnosis of a fetal chest wall cystic lymphangioma using ultrasonography and MRI: a case report with literature review. *Fetal Diagn Ther* 2005;20(November-December6):504–7.
- [6] Masood SN, Masood MF. Case report of fetal axillo-thoraco-abdominal cystic hygroma. *Arch Gynecol Obstet* 2010;281(January1):111–5.
- [7] Hayashi A, Kikuchi A, Matsumoto Y, Tatematsu M, Horikoshi T, Ogiso Y, et al. Massive cystic lymphangiomas of a fetus. *CongenitAnom (Kyoto)* 2005;45(December4):154–6.
- [8] Kaufman GE, D'Alton ME, Crombleholme TM. Decompression of fetal axillary lymphangioma to prevent dystocia. *Fetal Diagn Ther* 1996;11(May-June3):218–20.
- [9] Lu D, Wang Y, Zeng W, Peng B. Giant fetal lymphangioma at chest wall and prognosis: case report and literature review. *Taiwan J Obstet Gynecol* 2015;54(February1):62–5.
- [10] Goldstein I, Leibovitz Z, Noi-Nizri M. Prenatal diagnosis of fetal chestlymphangioma. *J Ultrasound Med* 2006;25(November11):1437–40.