

(Acta Anaesth. Belg., 2018, 69, 119-122)

An awkward fishing expedition

L. MARISSIAUX (*) , M.-L. SCIPPO (**), G. DAUBE (**), S. DENAYER (***), N. BOTTELDOORN (***), S. GOBERT (****), B. SCHOLTES (*****), A. GHUYSEN(*)

Abstract : We report the case of a patient, among a group of five, in a small outbreak of histamine fish poisoning (HFP). The epidemic character of the ailment led us to the correct diagnosis. In this case, the diagnosis was also associated with a Kounis syndrome (KS). Literature concerning this subject is reviewed, reporting recent physiopathological data.

Key words : histamine fish poisoning ; Kounis syndrome.

CASE REPORT

A 50 years-old woman was admitted to the emergency department (ED) complaining of dizziness and discomfort experienced during a business lunch at a restaurant with four colleagues. The meal included a piece of tuna, grilled on one side. The fish was served with lettuce, tomatoes and white wine. Except from being slightly too spicy, the patient and her colleagues had no complaint regarding the taste of the meal. Ten minutes after starting to eat, the patient presented brutal facial flushing, with palpitations, headache, dizziness, and diffuse thoracic oppression. Curiously, the other participants developed concomitant symptoms at the same time, but to a lesser extent. The patient had no relevant past medical history, in particular, no known allergies and was not under any treatment at that time.

At admission to the emergency department, the patient was quite anxious, had marked facial erythema and oedema (Fig. 1). She suffered from mild arterial hypertension with a heart rate of 150/min. Arterial oxygen saturation was under normal range and lung examination was clear. She rapidly developed diffuse erythema, spreading downward without other cutaneous lesion, and her blood pressure fell to 85/40 mmHg.

Arterial blood gas revealed respiratory alkalosis and mild increase in lactates at 170 mg/L. The electrocardiogram at admission (mild arterial hypertension) was abnormal with a sinus tachycardia and altered repolarization phases: ST segment

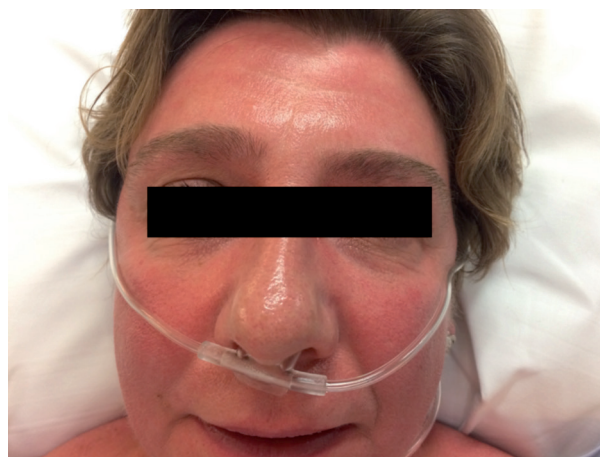

Fig. 1. — Facial erythema, downward diffusing.

depression in the inferior leads (Fig. 2). Point-of-care ultrasound showed a small hyperkinetic left ventricle and collapsed inferior vena cava. Biologic blood tests remained normal except for a discrete troponin T elevation from < 5 ng/L to 14 ng/L. The tryptase level remained normal. Urinary N-methylhistamine (a metabolite of histamine) could not be obtained by our laboratory.

Hemodynamic recovery was rapidly obtained under treatment 0.5 mg intramuscular epinephrine, intravenous methylprednisolone and fluid-challenge. Oral cetirizine was also provided and, six hours later, the patient felt asymptomatic. Skin flushing and tachycardia disappeared and ECG abnormalities relieved.

(*) Emergency Department, Liège University Hospital, Liège, Belgium

(**) Department of Food Sciences, FARAH, University of Liège, Liège, Belgium

(***) National Reference Laboratory of foodborne pathogens, Scientific Institute of Public Health, Brussels, Belgium

(****) Laboratoire d'Océanographie Biologique, MARE, FOCUS, STARESO, University of Liège, Liège, Belgium

(*****) Researcher, Department of Public Health, Nutrition, Environment and Health, University of Liège, Liège, Belgium

Corresponding author : Laurent Marissiaux, MD, Emergency Department, CHU de Liège, av. de l'Hôpital, 1, 4000 Liège, Belgium.

E-mail : laurent.marissiaux@chuliege.be

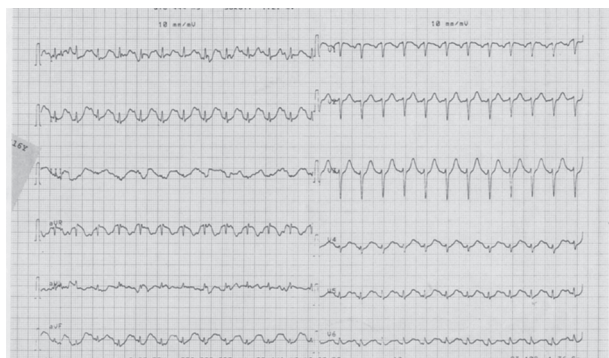


Fig 2. — First ECG.

Further bacteriological cultures and analyses from samples of the tuna fish revealed *Enterobacteriaceae* ($5.8 \cdot 10^3$ CFU/g) and *Pseudomonas* ($> 1.5 \cdot 10^7$ CFU/g) colonisation, together with high histamine level at 4400 mg/kg (4400 parts per million, ppm), 44 times the authorized European upper limit (COMMISSION REGULATION (EC) No 2073/2005 of 15 November 2005 on microbiological criteria for foodstuffs)

DISCUSSION

Physiopathology

Although histamine Fish Poisoning (HFP), or Scombroid Fish Poisoning, was initially described in 1799, it remains under-recognized and often misdiagnosed as IgE-mediated fish allergy (1). This condition is the result of an ingestion of histamine-contaminated fish of the *Scombroidae* and *Scomberesocidae* families, such as mackerel, tuna, bonito or skipjack. Other families of fish (herring, anchovies, sardines) have been also implicated, and, in rare cases, cheese (1). Most of these contain high levels of free histidine, a natural amino acid (2). Due to poor freezing conditions, bacteria from the gills and gastrointestinal tracts or from the surrounding environment may appear to grow, while some types, such as *Morganella*, *Proteus*, *Enterobacter*, *Serratia*, *Citrobacter*, *Pseudomonas*... present histidine-decarboxylase activities, responsible for converting histidine into histamine, that further accumulates in fish's flesh. Once histamine is formed, the compound is very resistant to cooking, freezing, and smoking (1).

Histamine can be absorbed via the patient's gastro-intestinal tract and binds to four different receptor subtypes (H1 to H4) leading to pathological effects (2).

H1 and H2 receptors mediate cutaneous and cardiovascular symptoms while activation of H3

receptors leads to the release of neurotransmitters in the central nervous system, responsible for headaches and vomiting. H4 receptors are the immune system's histamine receptors and their role in HFP is undetermined (2).

While the precise physiopathological mechanisms of HFP remain incompletely understood, several mechanisms of toxicity have been proposed in the literature (2). HFP is not simply a pure histamine intoxication. Scombroid food poisoning has a higher toxicity than equivalent dose-related pure histamine (2). Additionally, other biogenic amines derived from spoiled fish, may play a role as facilitating agents, potentiating histamine absorption in the gut and preventing its metabolism. Agents such as putrescine and cadaverine have been implicated but others may also be involved (3).

Several authors have argued that another hypothesis explaining the dose/response abnormalities of scombroid poisoning could be the presence of unknown histamine receptors agonists in spoiled fish (1, 2). Furthermore, individual HFP sensitivity appears variable, resulting in a wide range of clinical presentations among patients sharing the same meal (2). Such variety could arise from differences in the catabolism rate of histamine, affecting the duration and severity of symptoms. It must be noted that several drugs may exhibit inhibiting effects on histamine-metabolizing enzymes, such as mono-amine oxidase inhibitors and isoniazide (1). Alcoholic beverages may also increase the severity of the episode by enhancing the absorption of histamine contained in the meal (4).

Small amounts of histamine are present in a large number of foodstuffs. In healthy individuals, a normal amount of dietary histamine is well tolerated and metabolized in the gut (11). Some patients have reduced gut enzymatic barriers and may develop histamine-related symptoms with peculiar ailments. Table 1 shows the most common sources of histamine.

Diagnosis

The diagnosis of HFP in the emergency department is mainly based on clinical features. Symptoms usually occur 10 to 60 minutes after meal ingestion, the most common being facial flushing, abdominal pain, diarrhoea and headache (2). Other symptoms may include vomiting, dyspnea, flushing of the torso or the whole body. In rare cases, symptoms may even become more severe, with bronchospasm, respiratory distress, hypotension and shock, mainly in patients with pre-existing

asthma or heart diseases (1). Clinical suspicion should be confirmed through biological dosage, revealing normal tryptase levels, no elevation in urinary PGD-M excretion (a metabolite of the mast cell activation, releasing histamine) but elevated urinary histamine, and N-methyl histamine, its metabolite (5). N-methylhistamine (NMH) is the major metabolite of histamine. Because of its longer half-life, its urinary measurements have superior sensitivity and specificity than histamine, the parent compound, notably in patients with urticarial pigmentosa, systemic mastocytosis, or mast cell activation. While average diet has no effect on urinary NMH, elevations may be observed in case of histamine-rich meal. It should also be mentioned that patients taking monoamine oxydase inhibitors may also have increased levels of urinary NMH.

However, the definitive confirmatory test remains the dosage of histamine in the suspected piece of fish. The higher the level of histamine, the higher the probability that the patient develops HFP symptoms. The European permitted cut-off is 100 ppm. In most studies focussing on this poisoning, levels of histamine as high as 1000 ppm were found (4), but symptoms may develop at lower concentrations, due to the heterogeneity of individual sensibilities.

In Belgium, over the last seven years (2010-2016), 51 cases of confirmed HFP were reported, for a total number of foodborne outbreaks patients of 13,997. During that period, only 10 patients were hospitalized due to HFP and no deaths were attributed to this condition (National Reference Laboratory of foodborne pathogens, scientific institute of public health, WIV-ISP).

When managing cases of HFP, several differential diagnoses should be considered. Distinction between HFP and IgE-mediated allergic reaction to fish (or to other ingredients of the meal) may be challenging. Apart from the epidemic aspect of HFP, usually affecting several patients simultaneously, in allergic reactions the patient frequently has a history of allergies. Symptoms tend to be more prolonged and serum tryptase level is elevated.

HFP is related to the ingestion of fish contaminated by (usually a large amount of) histamine. Other foodstuffs may induce non-allergic adverse food reactions, like tomatoes, chocolate or berries, causing less severe symptoms, related to histamine-like or histamine-releasing compounds. Alcohol may also be the cause of flushing disorders by individuals with Alcohol Dehydrogenase deficiency (10).

Other conditions should also be considered, such as myocardial infarction, flushing disorders

(carcinoid tumors, ...) or rare conditions like IgE mediated anaphylaxis to Anisakia larvae (a parasite infesting a fish's flesh and transmitted to humans via the ingestion of raw fish) (1).

Prevention and treatment

The main issue concerning HFP relies on prevention measures and food safety. In that perspective, fish destined for human consumption should imperatively be stored at low temperatures, uninterrupted from fishing to cooking, to prevent bacterial growth and histamine-decarboxylase activity (1). Complete cooking of fish or shellfish is the only way to avoid Anisakiasis. The best prevention of Ig-E mediated fish allergy is avoidance (6).

With regards to HFP therapy, oral H1 blockers are effective against mild to moderate cases (5). For more severe symptoms, intravenous treatment is preferred, if available. Should the patient present hypotension, intravenous fluids and methylprednisolone may be used, but in more severe reactions with shock, epinephrine (IM or IV) could be needed (1).

Kounis Syndrome

Kounis Syndrome (KS), is an acute coronary syndrome related to coronary vasospasm in the setting of an allergic or hypersensitivity reaction. Cerebrovascular and mesenteric vascular events have also been reported (6). This syndrome is consecutive to an inflammatory cascade involving several mediators such as histamine, PAF, cytokines and chemokines... (6).

There is a possible overlap in the mechanism between vasospasms and other coronary related ischemic cardiac events. Kounis syndrome with plaque rupture and/or stent thrombosis have been described and need to be considered in the event of coronary events during hypersensitivity reactions. Histamine and others inflammatory mediators are found to be elevated in both acute allergic reactions and in patients with acute, non-allergic, coronary syndrome (9).

Various triggers have been recognized that have the potential to prompt this cascade. Among these, food intake (fruits, vegetables, canned food, shellfish and fish) is certainly the most frequent condition associated with the syndrome (7). Other triggers have been described, such as drugs (gelofulsine, vaccines with gelatine, antibiotics, anaesthetic agents, NSAIDs, anti-cancer drugs, losartan and corticosteroids) (6), but also environmental: insect bites (8), latex, etc.

Table 1.
The most common sources of histamine [adapted from . E. Kovacova-Hanuszkova et al. (11)].

Naturally occurring histamine in larger quantities	Tomatoes, eggplant, spinach, fish, chicken and every stored meat. All fermented food (cheeses, sausages, sauerkraut, wine, beer, champagne).
Natural histamine liberators	Pineapple, bananas, citrus fruits, strawberries, nuts, papaya, liquorice, spices, legumes, cocoa, seafood, pork, egg white.
Histamine liberators of artificial origin	Additives (food coloring, preservatives, stabilisers, taste enhancers, flavourings ...).
Natural histamine liberator and inhibitor of its metabolism	Alcohol.
Scombroid poisoning	Spoiled finfish from the Scombroidea and Scomberesocidae families, such as tuna, mackerel, skip-jack, and bonito. Other types of fish, such as mahi-mahi (dolphin fish), bluefish, amberjack, swordfish, marlin, herring, sardines, anchovies, salmon, tilapia, and trout and contaminated Swiss cheese.

The diagnosis of Kounis syndrome is usually based on a clinical examination and further confirmed using various technical exams. The main presenting symptom is chest pain (86%) which may be associated with palpitations and dyspnea and, often, allergic manifestations (8), while ECGs and biological testing reveal cardiac ischemic abnormalities.

Three variants of the Kounis syndrome have sometimes been proposed, and, in that perspective, the occurrence of a Kounis syndrome including histamine food poisoning by fish and food in general, might interrogate the existence of a type IV variant. However, the classical description of Kounis syndrome only stands for a coronary vasospasm in the setting of an allergy or hypersensitivity reaction.

The variant of KS, proposed by Kounis, are the following (8) :

1. Type I is the most common and is characterized by coronary artery spasm. Cardiac biomarkers may remain normal. There is no underlying coronary artery disease
2. Type II is associated with vasospasm and plaque erosion or rupture, in patients with known coronary artery disease or risk factors.
3. Type III is associated with coronary artery stent thrombosis.

The best practice treatment for type I is the management of the associated allergic disorders. Calcium channel blockers or nitrates can be useful in order to release the vasospasm. In type II variant, treatment should associate classical management of the acute coronary syndrome, with coronary angiography and angioplasty if required, and anti-allergic drugs. Intra-stent thrombus aspiration is very important in type III variant. Indeed, apart from coronary artery reperfusion, this approach allows the histological examination of the thrombus, confirming its allergic origin.

CONCLUSIONS

Although HFP is a common food-related poisoning, its diagnosis appears to be frequently ignored and underestimated as it may present like a classical food-allergy. First line practitioners should be aware of this specific condition and should alert food hygiene public services whenever it occurs in order to address the root cause and prevent further cases.

References

1. Feng C, Teubert S. and Gershwin M.E. 2016. Histamine (scombroid) Fish Poisoning : a comprehensive review. *Clinic Rev. Allerg. Immunol.* 50 : 64-69.
2. Hungerford JM. 2010. Scombroid poisoning: a review. *Toxicon.* 56 : 231-243.
3. Anastasius M. and Yannikas J. 2015. Scombroid fish poisoning illness and coronary artery vasospasm. *Australas Med. J.* 8 : 96-99.
4. Colombo F.M., Cattaneo P., Confalonieri E. and Bernadi C. 2018. Histamine food poisonings: A systematic review and meta-analysis . *Crit. Rev. Food Sci. Nutr.*, 58 : 1131-1151.
5. Morrow J.D, Margolies G.R., Rowland J. and Roberts L.J. 1991. Evidence that histamine is the causative toxin of scombroid-fish poisoning. *NEJM* 32 : 716-719.
6. Kounis N.G. 2016. Kounis syndrome: an update on epidemiology, pathogenesis, diagnosis and therapeutic management. *Clin. Chem. Lab. Med.*, 54 : 1545-1559.
7. Kounis N.G., Patsouras N., Grapsas N. and Hahalis G. 2015. Histamine induced coronary artery spasm, fish consumption and Kounis syndrome. *Int. J. Cardiol.* 193 : 39-41.
8. Abdelghany M., Subedi R., Shah S. and Kozman H. 2017. Kounis Syndrome: A review article on epidemiology, diagnostic findings, management and complications of allergic acute coronary syndrome. *Int. J. Cardiol.* 232 : 1-4.
9. Kounis N.G. 2006 Kounis syndrome (allergic angina and allergic myocardial infarction): A natural paradigm? *Int. J. Cardiol.* 11 : 7-14.
10. Sampson H.A. 1986. Differential diagnosis in adverse reactions to foods. *J. Allergy Clin. Immunol.* 78 : 212-219.
11. Kovacova-Hanuszkova E., Buday T., Gavliakova S. and Plevkova J. 2015. Histamine, histamine intoxication and intolerance. *Allergol. Immunopathol.* 43 : 498-506.