



## The efficacy of hydrothermally obtained carbonated hydroxyapatite in healing alveolar bone defects in rats with or without corticosteroid treatment

Uticaj hidrotermalno sintetisanog hidroksiapatita na zarastanje koštanih defekata kod pasa sa ili bez tretmana kortikosteroidima

Dejan Marković\*, Vukoman Jokanović<sup>†</sup>, Bojan Petrović<sup>‡</sup>, Tamara Perić\*, Biserka Vukomanović<sup>§||</sup>

\*Faculty of Dentistry, University of Belgrade, Belgrade, Serbia; <sup>†</sup>Laboratory for Radiation Chemistry and Physics, Institute of Nuclear Sciences Vinča, University of Belgrade, Belgrade, Serbia; <sup>‡</sup>Dentistry Clinic of Vojvodina, Faculty of Medicine, University of Novi Sad, Novi Sad, Serbia; <sup>§</sup>Institute of Pathology, Military Medical Academy, Belgrade, Serbia; <sup>||</sup>Faculty of Medicine of the Military Medical Academy, University of Defence, Belgrade, Serbia

### Abstract

**Background/Aim.** Autogenous bone grafting has been the gold standard in clinical cases when bone grafts are required for bone defects in dentistry. The study was undertaken to evaluate multilevel designed carbonated hydroxyapatite (CHA) obtained by hydrothermal method, as a bone substitute in healing bone defects with or without corticosteroid treatment in rats as assessed by histopathologic methods. **Methods.** Bone defects were created in the alveolar bone by teeth extraction in 12 rats. The animals were initially divided into two groups. The experimental group was pretreated with corticosteroids: methylprednisolone and dexamethasone, intramuscularly, while the control group was without therapy. Posterior teeth extraction had been performed after the corticosteroid therapy. The extraction defects were fulfilled with hydroxyapatite with bimodal particle sizes in the range of 50–250 μm and the sample from postextocational defect

of the alveolar bone was analyzed pathohistologically. **Results.** The histopathological investigations confirmed the biologic properties of the applied material. The evident growth of new bone in the alveolar ridge was clearly noticed in both groups of rats. Carbonated HA obtained by hydrothermal method promoted bone formation in the preformed defects, confirming its efficacy for usage in bone defects. Complete resorption of the material's particles took place after 25 weeks. **Conclusion.** Hydroxyapatite completely meets the clinical requirements for a bone substitute material. Due to its microstructure, complete resorption took place during the observation period of the study. Corticosteroid treatment did not significantly affect new bone formation in the region of postextracational defects.

### Key words:

tooth extraction; alveolar bone loss; transplants; rats; durapatite; adrenal cortex hormones.

### Apstrakt

**Uvod/Cilj.** Autogeni koštani graftovi predstavljaju zlatni standard u stomatologiji za popunjavanje koštanih defekata. Studija je sprovedena kako bi se ispitala efikasnost višefaznog karbonatnog hidroksiapatita (HA), dobijenog hidrotermalnom metodom, kao zamene za kost kod *in vivo* zarastanja koštanih defekata. Procena efikasnosti izvršena je patohistološkom analizom na pacovima (Sprague Dawley). **Metode.** Koštani defekti načinjeni su u alveolarnoj kosti ekstrakcijom bočnih zuba kod 12 pacova. Eksperimentalne životinje prvo su bile podeljene u dve grupe.

Prva, kontrolna grupa, bila je bez terapije, dok je druga, eksperimentalna grupa intramuskularno dobijala kortikosteroidnu terapiju i to metilprednizolon i deksametazon. Ekstrakcija bočnih zuba izvršena je nakon resorpcije izazvane terapijom kortikosteroidima. Ekstrakcione rane ispunjene su hidroksiapatitom čestica veličine 50–250 μm, a uzorci uzeti iz postekstrakcionih defekata alveolarne kosti analizirane su patohistološki. **Rezultati.** Patohistološkom analizom potvrđena su biološka osteokonduktivna svojstva primenjenog materijala. Intenzivni rast nove kosti unutar alveolarnog grebena jasno je uočen u obe grupe eksperimentalnih životinja. Karbonatni HA dobijen hidrotermal-

nim metodom inicirao je formiranje kosti preko površine defekata, potvrđujući efikasnost njegove primene kod koštanih defekata. Do potpune resorpcije materijala došlo je posle 25 nedelja. **Zaključak.** Ispitivani hidroksiapatit u potpunosti zadovoljava kliničke zahteve kao zamena za kost, poštujući ograničenja eksperimentalne namene studije. Zbog mikrostrukture materijala došlo je do komplet-

ne resorpcije tokom perioda posmatranja. Lečenje kortikosteroidima nije značajno uticalo na stvaranje nove kosti u predelu potekstrakcionih defekata.

**Ključne reči:**

**zub, ekstrakcija; alveolna kost, gubitak; graftovi; pacovi; hidroksiapatiti; kortikosteroidni hormoni.**

## Introduction

Autogenous bone grafting has been the gold standard in clinical cases when bone grafts are required for bone defects in dentistry. The proven advantages of autogenous bone grafting are: osteogenic potential, satisfactory mechanical properties and the absence of adverse immunological response<sup>1</sup>, but there are also some limitations, such as: requirement of additional surgery for harvest, reduced availability of adequate quantity and quality of graft material and the risk of patient morbidity<sup>2-4</sup>. In order to overcome these disadvantages, many kinds of synthetic biomaterials have been developed as bone substitutes, such as hydroxyapatite (HA), alumina, zirconia, bioglass, polymers, metal, and organic or inorganic bone substitutes<sup>5-7</sup>.

For biomedical indications, HA has been used extensively as a substitute in bone grafts<sup>5</sup>, because the natural bone is similar to HA. From the 1980s to nowadays, various forms of HA have been used in orthopaedic, dental or maxillofacial surgery<sup>5,6</sup>. For specific form of HA, carbonated calcium hydroxyapatite [CHA;  $\text{Ca}_{10}(\text{PO}_4)_{6-x}\text{CO}_3(\text{OH})_2$ ], osteoconductive properties have been proven<sup>8</sup>. Osteoconductive properties are significantly dependent on the porous structure of CHA, surface area, morphology and size of its particles. Furthermore, it has been shown that the CHA is bioresorbable and more bioactive than stoichiometric HA<sup>4,5,9,10</sup>.

The mechanism of glucocorticoid effect on bone metabolism is rather complex, and its role in arresting wound healing is not clearly described. Glucocorticoids modify osteoblastic cell differentiation, their number and function, thus inhibiting bone formation<sup>11</sup>. Inhibition of bone formation is simultaneously followed by bone resorption and subsequent bone loss. When administered for prolonged periods, glucocorticoid therapy is inevitably associated with bone loss, arrested osteoblast activity and suppressed bone formation *via* the osteoclasts<sup>12</sup>. Data regarding the influence of corticosteroid therapy on the teeth extraction wound healing are scarce.

After surgical procedure of tooth extraction, a coagulum fulfils the alveolar socket and a process of wound healing occurs. The healing never allows *ad integrum* restitution of the alveolar bone ridge, resulting in decreased bone volume and physiological resorption. Bone resorption leads to a decrease of height and width of the alveolar ridge which is a significant clinical problem<sup>13</sup>. Socket preservation is a procedure in which graft material is placed into the alveolar socket of an extracted tooth at the time of extraction in order to maintain the volume of the alveolar ridge<sup>14</sup>. For this purpose, various techniques and materials have been employed, such as alloplast materials, autogenous bone, allograft bone,

atraumatic extraction, immediate placement of dental implants or immediate socket filling with osteoconductive material. In recent years synthetic bone substitutes based on HA are frequently used for this particular clinical indication and are considered as promising materials due to their physical properties and similarity to natural bone.

The aim of the study was to assess the efficacy of hydrothermally obtained CHA in healing alveolar bone defects in rats with or without corticosteroid therapy.

## Methods

Precursors for CHA synthesis were prepared as follows: chicken egg shells were calcined at 900 °C till complete carbon removal and dissociation of  $\text{CaCO}_3$  to  $\text{CaO}$ . The second precursor was Merk's *pro analysis* quality  $(\text{NH}_4)_2\text{HPO}_4$ . A total of 500 mL of 2.32 cmol  $(\text{NH}_4)_2\text{HPO}_4$  solution was poured into 500 mL of 3.02 cmol  $\text{Ca}(\text{OH})_2$  solution and thoroughly mixed. In the end, 0.1 N HCl and  $(\text{NH}_4)\text{OH}$  were added to buffer the pH value of the solution to 7.4 according to the methodology previously described by Jokanović et al.<sup>15,16</sup>. This mixture was covered using a glass plane and put into the autoclave at 150° C and pressure up to 10 bar for 8 h.

After hydrothermal treatment in the autoclave, precipitates were decanted from glasses and dried at 80° C during the period of 48 h, disintegrated, rinsed with deionized water, and centrifuged with the purpose to get the purest possible CHA. After the process of characterization, hydrothermally obtained CHA particles were put into the glass pipettes and sterilized using gamma rays with the dose of 25 Gy.

### *Animal model and surgical procedure*

The experiment was conducted according to the Good Laboratory Practice (GLP) at the Faculty of Dentistry, University of Belgrade, with tried and tested experimental facilities.

A total of 12, 6–8-week-old, 250–275 g weighty, syngeneic female Sprague Dawley rats who had attained sexual maturity, were used in the study. Rats were housed 4 *per* cage with water and food at will. The animals were put in quarantine for at least 10 days prior to intervention. The animals were initially divided into 2 groups. The experimental group was treated with intramuscular glucocorticoids: methylprednisolone (Lemond-Solu<sup>®</sup>, Hemofarm, Vrsac, Serbia) and dexametosane (Dexason<sup>®</sup>, Galenika, Belgrade, Serbia). The control group was without corticosteroid therapy. The dose of glucocorticoids was 2 µg/g of body mass. Both medicines were given every second day. The teeth extraction from posterior region was performed after the corticosteroid therapy. The extraction defects were fulfilled with the CHA

with bimodal particle sizes in the range of 50–100  $\mu\text{m}$  and 200–250  $\mu\text{m}$ . The surgical procedure was performed under general anaesthesia using a halogenous compound, oxygen/isoflurane (Forane R<sup>®</sup>, Abbott Laboratories, Abbott Park, Illinois, USA).

About 0.3 g on average of CHA was put into created wounds with approximately equal diameters and depth of about 0.5 mm. No antibiotic treatment was administrated after the surgical procedure. The animals were sacrificed 5, 15 and 25 weeks after surgery using mechanism of an intracardiac overdose with sodium pentobarbital (Dolethal<sup>®</sup>, Vetoquinol, Lure, France).

The sample for histopathological analysis was the alveolar bone from the region of the artificial postextractional defect of the jaw. The bone was rinsed with a physiological solution, fixed with 10% formalin and decalcified by electrolysis in a solution of concentrated formic acid during the period of 10–12 h. After decalcination, dehydration of the tissue was performed using ethanol solution. Finally, all samples were formed in paraplast, cut using microtome and colored by hemotoxylin-eosin (HE) method.

The histological preparations were histopathologically analyzed by an image analysis software, Lucia 32G (Laboratory Imaging, Prague, Czech Republic) on a microscope (LEICA DMR) with 10 $\times$  magnification (NA = 0.5) and a digital camera (with 640  $\times$  480 pixels).

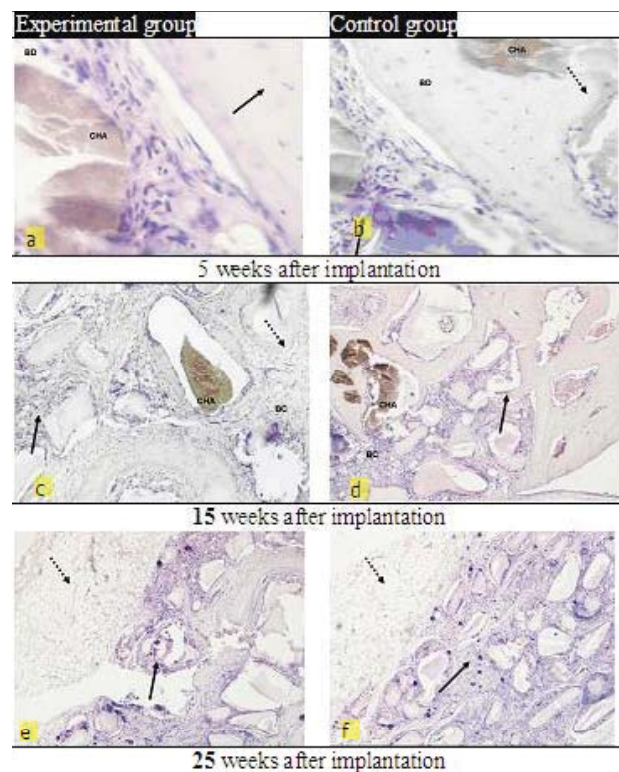
## Results

The signs of the initial osteogenesis were clearly observed in both groups. For animals treated with intramuscular glucocorticoids, the remnants of the implanted materials sized between 200 and 250  $\mu\text{m}$  were visible 5 weeks after implantation of CHA. The interposed capillars, vascular structures and cells typical for a young bone were clearly observed (Figure 1a). Similarly, for the group without therapy, intergrowth of the capillary within the implanted material was evident 5 weeks after the implantation of CHA (Figure 1b). The average particles size of the implanted material in the control group was less than 200  $\mu\text{m}$ .

Fifteen weeks after implantation, infiltration of the implanted CHA with blood vessels and osteoblasts migrating from the surrounding bone was slightly more intensive in the control group. It was evident that the new bone more intensively fulfilled the defects, transforming the CHA granule into a new bone. Remodulation processes in the alveolar defects were observed (Figure 1c). For the control group, the implanted material was saturated by blood capillary and osteoblasts from the surrounding bone as well. Defects were partially fulfilled with newly formed bone (Figure 1d).

After 25 week, implanted CHA was substituted completely by new immature bone in the control group. In the center of the defect, bone slowly became mature, while bone structure fulfilled almost complete defect. The complete integration of the new and existing bone tissue at the connective lines was almost completed in numerous spots (Figure 1f). In the experimental group, defects in the alveolar bone were fulfilled almost completely by the new bone tissue.

When compared with the control group signs of slightly less intensive bone maturation were noticed, and the bone structure was slightly more irregular. (Figure 1e).



**Fig. 1 – a, b) Five weeks after implantation of hydrothermally obtained carbonated hydroxyapatite (CHA), evident intergrowth of the capillary started inside the implanted material. The beginning of the initial osteogenesis was visible in both groups; c, d) Fifteen weeks after implantation, the implanted material (CHA) was saturated by blood capillary and osteoblasts (BC) from the surrounding bone (black arrow). The bony defect (BD) was partially fulfilled with a new bone (dotted arrow); e, f) Twenty five weeks after implantation, alveolar bone defects were fulfilled almost completely by new bone in both groups. Slightly more intensive osteogenesis was noticed in the control group. The integration of new and existing bone tissue was almost completed in the numerous spots.**

## Discussion

Nanostructured bone substitutes such as CHA particles with a high surface area are desirable in many fields including tissue engineering. The synthesis of nanostructured CHA was mostly based on the precipitation reaction developed by Barralet et al.<sup>9</sup> Hasegawa et al.<sup>10</sup> have also successfully produced sintered CHA which can be resorbed by osteoclasts both under *in vitro* and *in vivo* conditions, while classic sintered stoichiometric CHA cannot be resorbed. Apart from particle size and size distribution, the shape of bioactive and reinforcing particles are also important when developing bioactive bone substitute materials based on HA (porous or non-porous) for human tissue repair<sup>10,17</sup>.



Besides the better mechanical properties of sintered materials obtained from nanosized CHA, Evis et al.<sup>18</sup> reported faster osteoblast proliferation and greater osteoclast activity on nano-CHA in comparison with the conventional CHA, which has micron grain sizes. It was proven that in extracellular culture the synthesis of alkaline phosphatase by osteoblast on nano-CHA was faster than on the conventional micron grain size CHA<sup>8</sup>. The nano-CHA integrated in the structure of bone defects also has better osteointegrative properties. Therefore, it could be assumed that CHA with nanosized basic particles integrated in the granule design similar to natural bone would exhibit better biocompatibility<sup>19,20</sup>.

In the present investigation, a longer observation period of 25 weeks following surgery may be a factor of complete CHA reabsorption. In addition, very fine particle size and the small level of impurities in our CHA can act as catalysts of CHA biological activity, and contribute to the significant reabsorption.

A special structure of hydrothermally obtained hydroxyapatite and its potential very high surface activity caused by its nanometric size of apatite crystallite and very small particle size were the basis for the expectation of its substantially improved osteogenic activity on the site of bone defect<sup>19,20</sup>. The pores within the material, sized about 200  $\mu\text{m}$ , cylindrically shaped, and located inside of a CHA granule, have dimension which may enable the proliferation of young connective tissue and provide the environment for osteoblast cell activity expression. It may be assumed that a very small size of CHA crystallites (several nanometers) strongly promoted boundary activity of osteogenic cells with CHA. In the present study, the result of these processes was the higher rate of CHA disintegration, its transformation and osteointegration into a new bone, even in the group of experimental animals that were submitted to the corticosteroid treatment.

The structure of CHA and its pore distribution is multimodal and follows not only the size of the primary particles, the smallest ones, but also the size of the other particles packed into the clustered powder particles. The pores are distributed from the smallest ones in the range of 1.5–15  $\mu\text{m}$  up to the largest with the range of 50–250  $\mu\text{m}$ . The largest pores correspond to the largest particles approximately 250  $\mu\text{m}$  in size, clustered mostly into agglomerated particles 1–5  $\mu\text{m}$  large, which can be seen in SEM micrographs of synthesized CHA, as previously described in detail in the study by Jokanović et al.<sup>16</sup>. These particles are finally joined in the granules with the diameter between 300  $\mu\text{m}$  and 1000  $\mu\text{m}$ .

In the present investigation, the osteogenic potential of CHA was evaluated with regard to corticosteroid treatment. Therefore, the experiments with the rats previously treated with corticosteroid therapy were made, similarly to the previously conducted research<sup>21</sup>. These animals were compared with 6–8-week-old healthy Sprague Dawley rats that attained sexual maturity in which bone mineralization process had been completed. The morphology of postextractional wound healing of the alveolar bone was investigated. The process of new bone formation inside of the defect area was observed in order to compare it with bone formation in the control group

of animals. Newly formed bone with obvious evidences of mature bone characteristics were noticed 25 weeks after implantation in both investigated experimental groups. Inside healthy bone, it was obvious that healing was going on rapidly and very efficiently without any additional stimulation of osteogenesis<sup>21–24</sup>.

In the experimental group of animals, it was noticed that osteointegration of bone tissue had begun, but that this process is in the starting phase. The rate of the process of intergrowth of blood capillarity and activation of the osteoblast was more intensive for the control group of animals during the same observation period.

Opposite, in the subgroup where CHA was implanted for a longer time, in both groups of animals the intensive formation of new bone, increased binding, as well as migration and distribution of blood vessels and osteogenic cells within the remnants of implanted material were noticed, which confirmed the CHA osteoconductive effect<sup>25</sup>.

A significantly higher rate of osteogenesis in rats without corticosteroid treatment, in comparison to the control group, is probably caused by the activity of osteoblast cells which accelerated not only their proliferation and differentiation, but also the formation of new bone<sup>26,27</sup>.

According to the recently published investigations, the bone morphogenetic protein can be produced as the basis for the recruitment of mesenchymal stem cells in the region of defect by means of hemotaxis, initiating further quick proliferation and differentiation into chondroblasts and chondrocytes<sup>21</sup>. These cells later enter the cartilage-like matrix, which is calcified into bone. The final phase is the bone tissue remodeling and formation of mature lamellar bone that was clearly noticed in the present study.

Generally, the examined hydrothermally obtained CHA exhibited strong osteoconductive effect, enabling formation organization of osteons similar to normal bone. That is clear evidence that hydrothermally obtained CHA has a potential to form new bone and to replace bone tissue due to its osteoconductive properties. Therefore, hydrothermally obtained CHA can be used for the surgical treatment of defects caused by the resorption of alveolar bone ridge.

## Conclusion

This histopathological investigation of hydroxyapatite showed that the hydrothermally obtained carbonated hydroxyapatite has a potential to be applied as an osteoconductive material. The intensive growth of new bone tissue in the compact jaw ridge was evidently approved. Corticosteroid treatment did not significantly affect new bone formation in the region of postextractional defects. The hydrothermally obtained carbonated hydroxyapatite shows a significant potential and efficiency for reparation, healing and preservation of alveolar bone defects.

## Acknowledgements

This study was performed within the project financed by the Serbian Ministry of Education, Science and Technological Development ID: 172026.

## R E F E R E N C E S

- Misch CM. Maxillary autogenous bone grafting. *Oral Maxillofac Surg Clin North Am* 2011; 23(2): 229–38.
- Yang P, Quan Z, Li C, Kang X, Lian H, Lin J. Bioactive, luminescent and mesoporous europium-doped hydroxyapatite as a drug carrier. *Biomaterials* 2008; 29(32): 4341–7.
- Yang P, Quan Z, Lu L, Huang S, Lin J. Luminescence functionalization of mesoporous silica with different morphologies and applications as drug delivery systems. *Biomaterials* 2008; 29(6): 692–702.
- Rokn AR, Khodadoostan MA, Reza Rasouli Ghabroudi AA, Motabary P, Kharrazj Fard MJ, Bruyn HD, et al. Bone formation with two types of grafting materials: a histologic and histomorphometric study. *Open Dent J* 2011; 5: 96–104.
- Thornwarth M, Schultze-Mosgau S, Kessler P, Wiltfang J, Schlegel KA. Bone regeneration in osseous defects using a resorbable nanoparticulate hydroxyapatite. *J Oral Maxillofac Surg* 2005; 63(11): 1626–33.
- Pon-On W, Meejo S, Tang IM. Formation of hydroxyapatite crystallites using organic template of polyvinyl alcohol (PVA) and sodium dodecyl sulfate (SDS). *Mater Chem Phys* 2008; 112(2): 453–60.
- Ye F, Guo H and Zhang H. Biomimetic synthesis of oriented hydroxyapatite mediated by nonionic surfactants. *Nanotechnology* 2008; 19(12): 245605–12.
- Kim do K, Lee SJ, Cho TH, Hui P, Kwon MS, Hwang SJ. Comparison of a synthetic bone substitute composed of carbonated apatite with an anorganic bovine xenograft in particulate forms in a canine maxillary augmentation model. *Clin Oral Implants Res* 2010; 21(12): 1334–44.
- Barralet JE, Best SM, Bonfield W. Effect of sintering parameters on the density and microstructure of carbonate hydroxyapatite. *J Mater Sci Mater Med* 2000; 11(11): 719–24.
- Hasegawa M, Ohashi T, Tani T, Doi Y. Osteoconduction and bioresorption of sintered carbonate apatite. *Key Eng Mater* 2001; 192(195): 453–6.
- Canalis E. Mechanism of glucocorticoid-induced osteoporosis. *Curr Opin Rheumatol* 2003; 15(4): 454–7.
- Kim HJ, Zhao H, Kitaura H, Bhattacharyya S, Brewer JA, Muglia LJ, et al. Dexamethasone suppresses bone formation via the osteoclast. *Adv Exp Med Biol* 2007; 602: 43–6.
- Karring T, Lang NP, Lindhe J. *Clinical Periodontology and Implant Dentistry*. 4<sup>th</sup> ed. Oxford: Blackwell Publishing; 2003.
- Park JY, Koo KT, Kim TL, Seol YJ, Lee YM, Ku Y, et al. Socket preservation using deproteinized horse-derived bone mineral. *J Periodontal Implant Sci* 2010; 40(5): 227–31.
- Jokanović V, Izvonar D, Dramicanin MD, Jokanović B, Živojinović V, Marković D, et al. Hydrothermal synthesis and nanostructure of carbonated calcium hydroxyapatite. *J Mater Sci Mater Med* 2006; 17(6): 539–46.
- Jokanović V, Jokanović B, Marković D, Živojinović V, Pašalić S, Izvonar D, et al. Kinetics and sintering mechanisms of hydrothermally obtained hydroxyapatite. *Mater Chem Phys* 2008; 111(1): 180–5.
- Balasundaram G, Sato M, Webster TJ. Using hydroxyapatite nanoparticles and decreased crystallinity to promote osteoblast adhesion similar to functionalizing with RGD. *Biomaterials* 2006; 27(14): 2798–805.
- Evis Z, Sato M, Webster TJ. Increased osteoblast adhesion on nanograined hydroxyapatite and partially stabilized zirconia composites. *J Biomed Mater Res* 2006; 78(3): 500–7.
- Grandjean-Laquerriere A, Laquerriere P, Jallot E, Nedelec JM, Guenounou M, Laurent-Maquin D et al. Influence of the zinc concentration of sol-gel derived zinc substituted hydroxyapatite on cytokine production by human monocytes in vitro. *Biomaterials* 2006; 27(17): 3195–200.
- Grandjean-Laquerriere A, Laquerriere P, Guenounou M, Laurent-Maquin D, Phillips TM. Importance of the surface area ratio on cytokines production by human monocytes in vitro induced by various hydroxyapatite particles. *Biomaterials* 2005; 26(15): 2361–9.
- Pretel H, Lizarelli RF, Ramalho LT. Effect of low-level laser therapy on bone repair: Histological study in rats. *Lasers Surg Med* 2007; 39(10): 788–96.
- Hedner E, Linde A. Efficacy of bone morphogenetic protein (BMP) with osteopromotive membranes—an experimental study in rat mandibular defects. *Eur J Oral Sci* 1995; 103(4): 236–41.
- Andrade JCT, Camilli JA, Kawachi EY, Bertran CA. Behavior of dense and porous hydroxyapatite implants and tissue response in rat femoral defects. *J Biomed Mater Res* 2002; 62(1): 30–6.
- Tsai SW, Hsu FY, Chen PL. Beads of collagen–nanohydroxyapatite composites prepared by a biomimetic process and the effects of their surface texture on cellular behavior in MG63 osteoblast-like cells. *Acta Biomater* 2008; 4(5): 1332–41.
- Laquerriere P, Grandjean-Laquerriere A, Addadi-Rebbah S, Jallot E, Laurent-Maquin D, Frayssinet P, et al. MMP-2, MMP-9 and their inhibitors TIMP-2 and TIMP-1 production by human monocytes in vitro in the presence of different forms of hydroxyapatite particles. *Biomaterials* 2004; 25(13): 2515–24.
- Kim HW, Gu HJ, Lee HH. Microspheres of collagen-apatite nanocomposites with osteogenic potential for tissue engineering. *Tissue Eng* 2007; 13(5): 965–73.
- Thian ES, Zeeshan A, Jie H, Mohan JE, Jayasinghe SN, Ireland DC, et al. The role of electrospayed apatite nanocrystals in guiding osteoblast behaviour. *Biomaterials* 2008; 29(12): 1833–43.

Received on June 3, 2012.

Revised on August 28, 2012.

Accepted on September 27, 2012.