

University of Groningen

Hybrid bronchoscopic and surgical resection of endotracheal angiomatoid fibrous histiocytoma

Bouma, Wobbe; Koning, Kor Johan; Suurmeijer, Albert J H; Slebos, Dirk Jan; Mariani, Massimo A; Klinkenberg, Theo J

Published in:
Journal of cardiothoracic surgery

DOI:
[10.1186/s13019-019-0861-7](https://doi.org/10.1186/s13019-019-0861-7)

IMPORTANT NOTE: You are advised to consult the publisher's version (publisher's PDF) if you wish to cite from it. Please check the document version below.

Document Version
Publisher's PDF, also known as Version of record

Publication date:
2019

[Link to publication in University of Groningen/UMCG research database](#)

Citation for published version (APA):

Bouma, W., Koning, K. J., Suurmeijer, A. J. H., Slebos, D. J., Mariani, M. A., & Klinkenberg, T. J. (2019). Hybrid bronchoscopic and surgical resection of endotracheal angiomatoid fibrous histiocytoma. *Journal of cardiothoracic surgery*, 14(1), [48]. <https://doi.org/10.1186/s13019-019-0861-7>

Copyright

Other than for strictly personal use, it is not permitted to download or to forward/distribute the text or part of it without the consent of the author(s) and/or copyright holder(s), unless the work is under an open content license (like Creative Commons).

Take-down policy

If you believe that this document breaches copyright please contact us providing details, and we will remove access to the work immediately and investigate your claim.


Downloaded from the University of Groningen/UMCG research database (Pure): <http://www.rug.nl/research/portal>. For technical reasons the number of authors shown on this cover page is limited to 10 maximum.

CASE REPORT

Open Access



Hybrid bronchoscopic and surgical resection of endotracheal angiomatoid fibrous histiocytoma

Wobbe Bouma^{1*} , Kor Johan Koning², Albert J. H. Suurmeijer³, Dirk Jan Slebos², Massimo A. Mariani¹ and Theo J. Klinkenberg¹

Abstract

Background: Angiomatoid fibrous histiocytoma (AFH) is a soft-tissue tumor that generally affects the extremities of children and young adults. AFH overlaps with primary pulmonary myxoid sarcoma (PPMS) and can occur in unusual locations.

Case presentation: We present a case of a 22-year-old female with AFH in the distal trachea. In addition to describing the challenge in making a correct diagnosis of AFH, we describe the first case of successful hybrid bronchoscopic and surgical resection of endotracheal AFH. A staged removal procedure was required to quickly secure the airway, allowing a lower-risk elective distal tracheal resection through a cervical approach for complete resection. A more conventional, but more invasive, more painful and cosmetically less satisfying thoracotomy was avoided.

Conclusions: A distal tracheal resection for AFH can be safely performed in young adults through a cervical approach with excellent follow-up results.

Keywords: Angiomatoid fibrous histiocytoma, Bronchoscopy, Tracheal resection

Background

Angiomatoid fibrous histiocytoma (AFH) is a soft-tissue tumor that generally affects the extremities of children and young adults, but occasionally occurs at unusual locations such as the trachea [1–3]. This case-report demonstrates the challenge in making a correct (histological) diagnosis of endotracheal AFH and presents the first case of successful hybrid bronchoscopic and surgical resection of endotracheal AFH.

Case presentation

A 22-year-old female was referred with dyspnea and wheezing and an initial diagnosis of allergic asthma. Several weeks before she was admitted to the intensive care unit with acute respiratory failure due to a presumed severe asthma exacerbation. After weaning from

mechanical ventilation she received formoterol and beclomethasone. Auscultation revealed pulmonary wheezing and a high-pitched stridor. Spirometry showed expiratory airflow obstruction and signs of severe fixed intrathoracic stenosis.

In retrospect, previous chest X-rays showed an intratracheal mass close to the carina (Fig. 1a, blue arrow). Emergency computed tomography (CT) confirmed the presence of a large obstructing intratracheal mass (Fig. 1b, blue arrow). Emergency bronchoscopy was performed under general anesthesia and revealed a large endotracheal tumor, blocking the airway almost completely (Fig. 1c). Bronchoscopic debulking was performed using electrocautery and cryotherapy, leaving a patent airway with a small residual tumor (Fig. 1d). The tumor was located 4 tracheal rings (approximately 2 cm) above the carina. Recovery was uneventful and the patient was discharged the next day without any remaining symptoms.

Histopathological examination showed an unclassifiable atypical myxoid spindle cell neoplasm with focal

* Correspondence: w.bouma@umcg.nl

¹Department of Cardiothoracic Surgery, University of Groningen, University Medical Center Groningen, Groningen, The Netherlands
Full list of author information is available at the end of the article



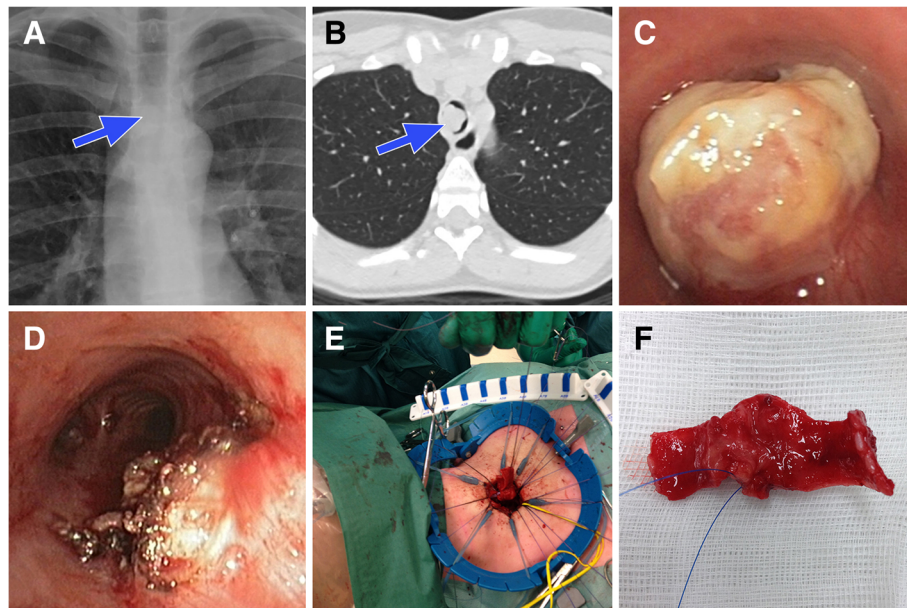


Fig. 1 Endotracheal angiomatoid fibrous histiocytoma imaging and resection

ALK expression and negative staining for keratins, EMA, TLE-1, p63, CD31, CD34, ERG, S100, SOX-10, TTF-1, SMA, desmin, myf4 and MUC4. Molecular analysis showed an EWSR1-CREB1 translocation, which can be found in primary pulmonary myxoid sarcoma (PPMS), AFH and in several other sarcomas. Under the working diagnosis of PPMS the patient underwent magnetic resonance imaging of both brain and kidneys and a whole body fluorodeoxyglucose positron emission tomography and CT. Both did not reveal any distant metastases.

The remaining tumor was removed through a cervical approach with a partial distal tracheal resection and end-to-end anastomosis with interrupted 4–0 PDS sutures (and two lateral interrupted 2–0 Vicryl sutures for approximation and anastomotic tension release) (Fig. 1e,

patient's head is left). The excised part of the trachea was cut open anteriorly and showed a tumor with a diameter of 15 mm located on the membranaceous portion (Fig. 1f). High-frequency jet ventilation was used to allow temporal surgical interruption of the trachea. The patient was extubated immediately after the procedure. Recovery was uneventful and the patient was discharged three days after surgery.

Microscopically, the tumor was removed completely. Histopathological examination at low power magnification showed distinct features of AFH with tumor nodules of variable size surrounded by a thick fibrous capsule with a rim of lymphoplasmacytic cells (Fig. 2a). High power magnification showed solid tumor nodules composed of bland myoid spindle cells (Fig. 2b). On follow-up, three years after surgery, the patient is

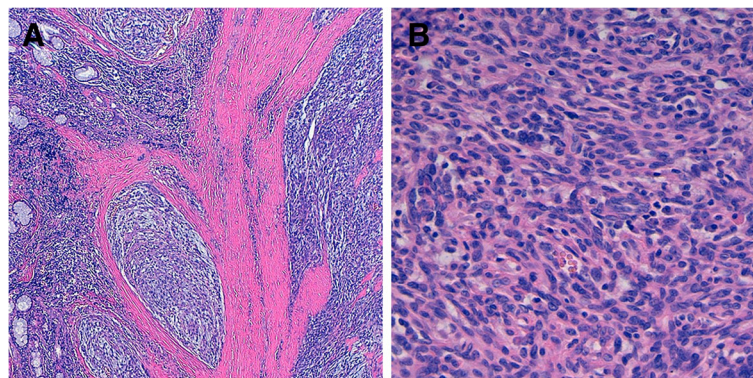


Fig. 2 Histopathological examination of endotracheal angiomatoid fibrous histiocytoma

asymptomatic, uses no asthma medication, has normal spirometry, and does not show any signs of recurrent tumor growth.

Discussion and conclusions

AFH is a mesenchymal neoplasm of intermediate malignancy that generally affects children and young adults [1]. AFH occurs most commonly in the deep dermis or subcutis of extremities, followed by the trunk and head and neck [1]. AFH has a characteristic histological appearance simulating the appearance of a neoplasm occurring in a lymph node [1]. However, due to the variable histological appearance and the lack of consistently positive immunohistochemical markers, the diagnosis can be difficult [1]. Molecular genetic studies have shown three characteristic translocations and nearly 93% of AFH have a rearrangement of EWSR1 (often a EWSR1-CREB1 translocation), which is of diagnostic relevance [1]. However, the EWSR1-CREB1 translocation is also described in other tumors, such as PPMS [1, 4]. Although PPMS and AFH may represent an overlapping histologic spectrum, PPMS is consistently negative for desmin and characterized by a predominately reticular architecture and absence of a lymphoplasmacytic cuff [1, 4]. This case-report confirms the challenge in making a correct (histological) diagnosis of AFH, especially when it occurs at an unusual site.

There is one previous case report that describes endobronchial AFH in two cases [2] and only one case report that describes (upper) endotracheal AFH [3]. To our knowledge, surgical resection of endotracheal AFH has not been described before, nor has a hybrid bronchoscopic and surgical resection strategy. A staged resection was required in this case to quickly secure the airway, allowing a lower-risk planned surgical procedure for complete resection. We chose a cervical approach, instead of a more invasive, painful and cosmetically less satisfying thoracotomy. Although a thoracotomy is generally recommended for distal tracheal resections, we have shown that distal tracheal resection for endotracheal AFH can be safely performed in young adults through a cervical approach with excellent follow-up results.

Abbreviations

AFH: angiomatoid fibrous histiocytoma; CT: computed tomography; PPMS: primary pulmonary myxoid sarcoma

Acknowledgements

Not applicable.

Funding

This study did not receive any financial support.

Availability of data and materials

Please contact the corresponding author for data requests.

Authors' contributions

All authors meet ICMJE guidelines for contribution. WB, KK, and TK collected the data and wrote the manuscript. AS, MM, and TK participated in the design of the manuscript and they revised and critically reviewed the manuscript. All authors have read, critically reviewed, and approved the final manuscript.

Ethics approval and consent to participate

Not applicable.

Consent for publication

The patient provided informed consent for publication of this report and any accompanying images.

Competing interests

The authors declare that they have no competing interests.

Publisher's Note

Springer Nature remains neutral with regard to jurisdictional claims in published maps and institutional affiliations.

Author details

¹Department of Cardiothoracic Surgery, University of Groningen, University Medical Center Groningen, Groningen, The Netherlands. ²Department of Pulmonary Diseases, University of Groningen, University Medical Center Groningen, Groningen, The Netherlands. ³Department of Pathology, University of Groningen, University Medical Center Groningen, Groningen, The Netherlands.

Received: 16 August 2018 Accepted: 17 February 2019

Published online: 28 February 2019

References

1. Thway K, Fisher C. Angiomatoid fibrous histiocytoma: the current status of pathology and genetics. *Arch Pathol Lab Med*. 2015;139:674–82.
2. Thway K, Nicholson AG, Wallace WA, Al-Nafussi A, Pilling J, Fisher C. Endobronchial pulmonary angiomatoid fibrous histiocytoma: two cases with EWSR1-CREB1 and EWSR1-ATF1 fusions. *Am J Surg Pathol*. 2012;36:883–8.
3. Chen W, Shi H, Liu Y, Ke Z, Han A. Endotracheal angiomatoid 'malignant' fibrous histiocytoma: EWSR1 gene rearrangement. *Pathology*. 2013;45:506–8.
4. Thway K, Nicholson AG, Lawson K, Gonzalez D, Rice A, Balzer B, et al. Primary pulmonary myxoid sarcoma with EWSR1-CREB1 fusion: a new tumor entity. *Am J Surg Pathol*. 2011;35:1722–32.

Ready to submit your research? Choose BMC and benefit from:

- fast, convenient online submission
- thorough peer review by experienced researchers in your field
- rapid publication on acceptance
- support for research data, including large and complex data types
- gold Open Access which fosters wider collaboration and increased citations
- maximum visibility for your research: over 100M website views per year

At BMC, research is always in progress.

Learn more biomedcentral.com/submissions

