



# Diagnostic-driven antifungal approach in neutropenic patients at high risk for chronic disseminated candidiasis: preliminary observations on the role of 1,3- $\beta$ -D-glucan antigenemia and multiphasic contrast-enhanced computed tomography

Roberta Della Pepa<sup>1</sup> · Claudio Cerchione<sup>1</sup> · Novella Pugliese<sup>1</sup> · Roberta Colicchio<sup>2</sup> · Paola Salvatore<sup>2,3</sup> · Cesare Sirignano<sup>4</sup> · Ernesto Soccia<sup>4</sup> · Livio Pagano<sup>5</sup> · Maurizio Sanguinetti<sup>6</sup> · Fabrizio Pane<sup>1</sup> · Marco Picardi<sup>7</sup>

Received: 30 December 2016 / Accepted: 2 March 2018 / Published online: 9 March 2018  
© Springer-Verlag GmbH Germany, part of Springer Nature 2018

Dear Editor,

Chronic disseminated candidiasis (CDC) is a critical form of invasive fungal infection (IFI) that affects mainly the liver, spleen, and, occasionally, kidneys [1]. Typical clinical, microbiological, and/or radiological manifestations have late onset, leading frequently to misdiagnosis [1, 2]. A late diagnosis leads to a delay in starting an effective antifungal therapy against *Candida* infection resulting in a severe morbidity and high mortality [3]. Recent studies have shown effective alternatives to traditional microbiological and radiological procedures for the diagnosis of CDC, in particular, 1,3- $\beta$ -D-glucan (BDG) antigenemia and contrast-enhanced computed tomography (CE-CT) [4, 5]. The preemptive approach, based on the routine surveillance with serum BDG and hepatosplenic CE-CT, has been proposed for obtaining a reliable and early diagnosis of CDC, and for establishing a proper

antifungal treatment [6]. However, guidelines give moderate evidence to support recommendation for the use of such approach in clinical practice [7]. In our institution, patients with acute leukemia at high-risk for CDC underwent diagnostic-driven approach, which was based on the identification of the clinical settings requiring intensive diagnostic efforts. Between January 2013 and December 2014, 20 of 24 consecutive patients older than 18 years with several risk factors for *Candida* infection (and on fluconazole prophylaxis), who underwent intensive chemotherapy or autologous stem cell transplantation (SCT), developed febrile neutropenia (FN). In the event of FN, a standard diagnostic work-up (SDWU) was performed as already reported [8]. Patients with persisting fever after 4–6 days of broad-spectrum antibiotics or patients with fever relapsing after 48 h of defervescence underwent a baseline diagnostic work-up (BDWU) including serum BDG antigenemia (Fungitell, manufacturer; Associated of Cape Cod, Inc., East Falmouth, MA). An intensive diagnostic work-up (IDWU) was performed in patients with a positive BDG test ( $\geq 80$  pg/mL). It included multiphasic CE helical CT of the liver and spleen, as already described [9]. Among this series of 24 patients, we report a patient suffering from CDC, which was definitively proven by ultrasonography (US)-guided core needle cutting biopsy (CNCB) of the liver. The most important aspect, revealed by the clinical case herein described, is the crucial role of the serum BDG test and the hepatosplenic multiphasic CE helical CT for the early diagnosis of deep-seated *Candida* infection.

**Clinical case** A 26-year-old patient underwent autologous SCT for acute myeloid leukemia relapsed after first-line antineoplastic therapy. On day 13 after chemotherapy, he developed FN in spite of prophylaxis with fluconazole and levofloxacin. Empiric antibiotic therapy was started. After 3 days, he was

✉ Roberta Della Pepa  
robertadellapepa@gmail.com

<sup>1</sup> Department of Clinical Medicine and Surgery, Federico II University, Via Sergio Pansini, 5, 80131 Naples, Italy

<sup>2</sup> Department of Molecular Medicine and Medical Biotechnology, Federico II University, Naples, Italy

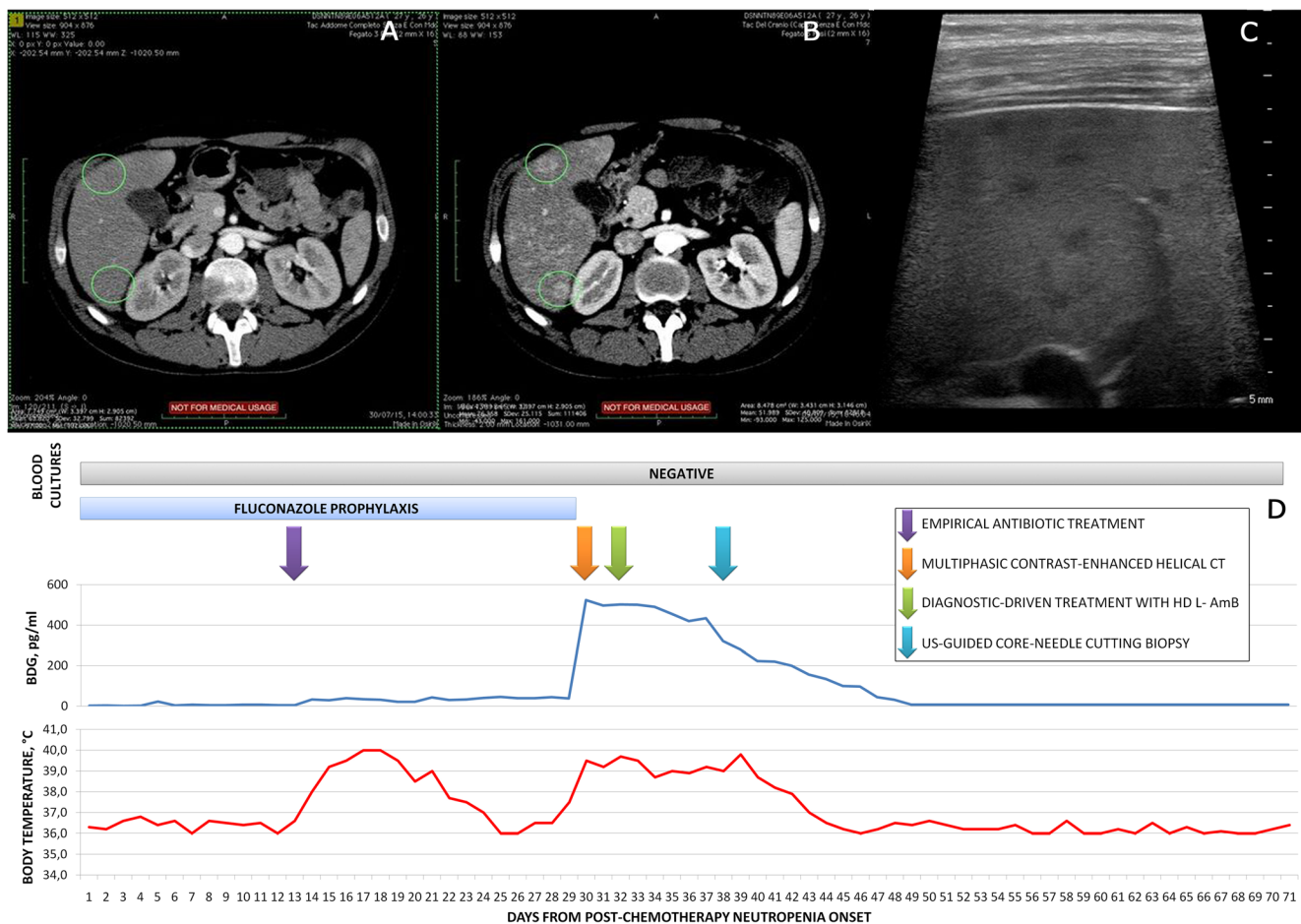
<sup>3</sup> CEINGE, Biotecnologie Avanzate s.c.ar.l., Naples, Italy

<sup>4</sup> Istituto di Biostrutture e Bioimmagini, Consiglio Nazionale delle Ricerche, Naples, Italy

<sup>5</sup> Institute of Hematology, Università Cattolica del Sacro Cuore, Rome, Italy

<sup>6</sup> Institute of Microbiology, Università Cattolica del Sacro Cuore, Rome, Italy

<sup>7</sup> Department of Advanced Biomedical Science, Federico II University, Naples, Italy



**Fig. 1** Serum 1,3- $\beta$ -D-glucan (BDG), multiphasic contrast-enhanced helical computed tomography (CT) and ultrasonography (US) scans of the liver obtained in a 26-year-old patient with acute myeloid leukemia and chronic disseminated candidiasis (CDC). **a** Basal non-contrast-enhanced phase of CT, showing no lesions in the liver. **b** The arterial phase of contrast-enhanced CT, detecting multiple nodules with marked rim-

enhancement (**c**). **c** US detail revealing inhomogeneous pattern, due to the presence of small hypo-echoic lesions between 2 and 4 mm of diameter. **d** Trends of body temperature, serum BDG, and blood cultures are shown, with the timing of diagnostic procedures and antimicrobial therapeutic treatments indicated by the arrows. *HD L-AmB* high-dose (5 mg/kg daily) liposomal amphotericin B

still febrile with abdominal pain and diarrhea. His liver and renal tests were normal, and BDG serum screenings were negative, such as blood cultures and US scans of the liver and spleen; while neutropenia was still severe. About a week later, fever and gastrointestinal symptoms regressed, also thanks to the rise of neutrophils. The patient was discharged to home. On day 29 after chemotherapy, the patient was again accepted at hematology department for the reappearance of fever (39 °C). He was not neutropenic, while it was documented an increase in inflammatory markers; his liver tests were normal. Blood cultures were negative such as US of the liver and spleen, while the serum BDG test was positive (523 pg/mL). Multiphasic CE helical CT showed homogeneous liver parenchyma in the non-enhanced basal phase (Fig. 1a), but in the following arterial phase, it detected millimetric (between 2 and 4 mm of diameter) hypodense nodules in the liver, characterized by a marked rim-enhancement, highly suggestive of micro-abscesses due to fungal infection (Fig. 1b). Ten days later, it was documented an increase in transaminases (AST/

ALT, 54/84 U/L), ALP (207 U/L), and gamma-glutamyl transpeptidase (GGT, 117 U/L). Gray-scale US showed the presence of hepatomegaly, with finely inhomogeneous pattern due to the presence of small hypo-echoic lesions (Fig. 1c). At platelet count recovery, US-guided CNCB of the liver was performed. Histological and microbiological assessments on biopsy specimen documented *Candida albicans* infection. In the meantime, the patient began antifungal treatment with liposomal amphotericin B (L-AmB) at a dose of 5 mg/kg daily, obtaining resolution of fever and complete normalization of serum BDG (Fig. 1d). After a total of 36 days of antifungal therapy, CE-CT scans showed the almost complete disappearance of liver lesions previously reported. At the present, he is alive and in complete hematological remission.

Diagnostic strategy in patients at high-risk for invasive *Candida* infection is still controversial [6, 7]. To improve diagnosis quality, the 2008 European Organization for Research and Treatment of Cancer and Mycoses Study Group (EORTC/MSG) requires the demonstration of fungal elements in

diseased tissue using invasive procedures (proven CDC) [6]. To define a CDC as probable, the imaging detection of lesions with typical *bull's eye* aspect in the liver and/or spleen is required, as well as mycological findings, in particular, an episode of candidemia in the previous 2 weeks. In spite of this re-visitation of EORTC/MSG criteria, diagnosis of CDC is often difficult and challenging, because the above-reported findings may remain negative, and/or biopsy procedure for tissue characterization is not always feasible [1–3]. New non-invasive diagnostic tools against invasive *Candida* infection are now available [4, 5]. Serum BDG antigenemia test in neutropenic patients is useful for the diagnosis of CDC. A study by Tissot et al. in patients with acute leukemia has suggested that BDG may anticipate of a several number of days the diagnosis of invasive candidiasis, when compared with traditional clinical, radiological, and culture-based assessments [10]. It is reported that BDG assay had a specificity rate for invasive *Candida* infection of about 80% at a cutoff value > 80 pg/mL [4, 10]. It is important to know that the use of albumin, gauzes, immunoglobulins, hemodialysis, and/or bloodstream infections due to particular bacteria is associated with false-positive results. When the radiological study of the liver and/or spleen is carried out, a multiphasic CE-CT is considered essential [5, 7]. This technique consists in the acquisition of two different contrast graphic sequences: a first phase prevalently arterial and a second predominantly portal. The two phases have an efficacy in terms of complementary overall accuracy. The technique, for optimal results, requires a strict application, the use of CT fast spirals equipment, preferably multilayered because the arterial parenchyma opacification is very fast, beginning after 15–20 s from the start of contrast injection and it is relatively short, running out after 30–35 s, when the portal phase starts. This kind of acquisition is crucial for the correct visualization of the lesions. In fact, as it is possible to see in Fig. 1a, the baseline CT examination without intravenous contrast injection was not diagnostic, showing a homogeneous liver parenchyma. In our study, among 24 consecutive patients at high-risk for invasive *Candida* infection, 20 (83%) developed FN. The diagnostic-driven antifungal approach was able to obtain a reliable and early diagnosis of CDC in 3 of the 20 patients (one of them described above), establishing a prompt and proper treatment [11]. In these three patients, BDG was the first test appearing positive among the tests performed for the definitive diagnosis of CDC. When BDG result was  $\geq 80$  pg/mL, multiphasic CE-CT was employed obtaining thin scans of the liver and spleen. The discovery of the hepatosplenic nodules (with particular behavior at contrast medium intravenous infusion) in combination with high serum levels of BDG made highly suggestive the diagnosis of CDC and allowed to promptly introduce a specific antifungal therapy, i.e., high-dose L-AmB (5 mg/kg/die), which had led to infection resolution and to continue chemotherapy for the underlying hematological malignant diseases, as planned. In

all three cases with CDC, it was tested the fungal sensitivity on core needle specimens (fluconazole-resistant candidiasis in all of them). In our series, only one patient (4%) received empirical antifungal therapy for worsening of the clinical conditions, while the majority of patients received anti-yeast active prophylaxis with fluconazole in spite of persisting FN. IDWU with CE-CT was required in 9/20 patients (45%) with FN. Our strategy allowed a 77% reduction in antifungal therapy compared with a standard empirical approach. At 3-month follow-up, 95% of patients with FN survived, and no undetected IFI were found. Although in this series, all cases of CDC were due to azole-resistant specimens, our current antifungal prophylaxis practice is based on fluconazole. In fact, 20/24 (83%) patients at high-risk for candidiasis did not develop IFI under fluconazole treatment. Nevertheless, we are ready to change antifungal prophylaxis from fluconazole to echinocandin in the presence of increased number of fluconazole-resistant CDC cases. Finally, our series is too small to give new information to the knowledge of CDC. Multicenter prospective trials on clinically driven antifungal strategy with a predefined diagnostic work-up against invasive *Candida* infection are warranted.

## Compliance with ethical standards

**Conflict of interest** The corresponding author has full control of all primary data and agrees to allow the journal to review their data if requested.

## References

1. Blade J, Lopez-Guillermo A, Rozman C, Graña A, Bruguera M, Bordas J, Cervantes F, Carreras E, Sierra J, Montserrat E (1992) Chronic systemic candidiasis in acute-leukemia. *Ann Hematol* 64(5):240–244
2. Voneiff M et al (1990) Hepatosplenic candidiasis, a late manifestation of *Candida* septicemia in neutropenic patients with hematologic malignancies. *Blutalkohol* 60(4):242–248
3. Garey KW, Rege M, Pai MP, Mingo DE, Suda KJ, Turpin RS, Bearden DT (2006) Time to initiation of fluconazole therapy impacts mortality in patients with candidemia: a multi-institutional study. *Clin Infect Dis* 43(1):25–31
4. Odabasi Z et al (2004) Beta-D-glucan as a diagnostic adjunct for invasive fungal infections: validation, cutoff development, and performance in patients with acute myelogenous leukemia and myelodysplastic syndrome. *Clin Infect Dis* 39(2):199–205
5. Metsers U, Haider MA, Dill-Mackay M, Atri M, Lockwood G, Minden M (2005) Fungal liver infection in immunocompromised patients: depiction with multiphasic contrast-enhanced helical CT. *Radiology* 235(1):97–105
6. De Pauw B et al (2008) Revised definitions of invasive fungal disease from the European Organization for Research and Treatment of Cancer/Invasive Fungal Infections Cooperative Group and the National Institute of Allergy and Infectious Diseases Mycoses Study Group (EORTC/MSG) Consensus Group. *Clin Infect Dis* 46(12):1813–1821

7. Ruhnke M, Böhme A, Buchheidt D, Cornely O, Donhuijsen K, Einsele H, Enzensberger R, Hebart H, Heussel CP, Horger M, Hof H, Karthaus M, Krüger W, Maschmeyer G, Penack O, Ritter J, Schwartz S, Infectious Diseases Working Party in Haematology and Oncology of the German Society for Haematology and Oncology (2012) Diagnosis of invasive fungal infections in hematology and oncology-guidelines from the Infectious Diseases Working Party in Haematology and Oncology of the German Society for Haematology and Oncology (AGIHO). *Ann Oncol* 23(4):823–833
8. Picardi M, Pagliuca S, Chiurazzi F, Iula D, Catania M, Rossano F, Pane F (2012) Early ultrasonographic finding of septic thrombophlebitis is the main indicator of central venous catheter removal to reduce infection-related mortality in neutropenic patients with bloodstream infection. *Ann Oncol* 23:2122–2128
9. Picardi M, Soricelli A, Grimaldi F, Nicolai E, Gallamini A, Pane F (2011) Fused FDG–PET/contrast-enhanced CT detects occult subdiaphragmatic involvement of Hodgkin’s lymphoma thereby identifying patients requiring six cycles of anthracycline-containing chemotherapy and consolidation radiation of spleen. *Ann Oncol* 22:671–680
10. Tissot, F., et al. (2013) beta-glucan antigenemia anticipates diagnosis of blood culture-negative intraabdominal candidiasis. *Am J Respir Crit Care Med* 188(9): p. 1100–9
11. Della Pepa R et al (2016) Successful management of chronic disseminated candidiasis in hematologic patients treated with high-dose liposomal amphotericin B: a retrospective study of the SEIFEM registry. *Support Care Cancer* 24(9):3839–3845