

Clinical Anatomy and Biomechanics of the Ankle in Dance

Jeffrey A. Russell, M.S., A.T.C., Islay McEwan, M.Sc., M.C.S.P., Yiannis Koutedakis, Ph.D., and Matthew A. Wyon, Ph.D.,

Proofs to: jrussell@kardia.org

Abstract

The ankle is an important joint to understand in the context of dance because it is the connection between the leg and the foot that establishes lower extremity stability. Its function coordinates with the leg and foot and, thus, it is crucial to the dancer's ability to perform. Furthermore, the ankle is one of the most commonly injured body regions in dance. An understanding of ankle anatomy and biomechanics is not only important for healthcare providers working with dancers, but for dance scientists, dance instructors, and dancers themselves. The bony architecture, the soft tissue restraints, and the locomotive structures all integrate to allow the athletic artistry of dance. Yet, there is still much research to be carried out in order to more completely understand the ankle of the dancer.

Ankle injuries account for a large percentage of all musculoskeletal conditions suffered by participants in a variety of physical activities,¹ and are the most common of all injuries in many sports.² Some

athletic activities require extremes of ankle motion (e.g., soccer and gymnastics). However, classical ballet alone necessitates the combination of moving the ankle into absolutely maximum dorsiflexion (when a ballerina stands in the demi-plié position) and into absolutely maximum plantar flexion (when she stands in the en pointe position). The very nature of these positions and the repetition with which they are practiced predispose the classical ballet dancer to a host of potential musculoskeletal stresses in the ankle.³⁻¹⁰

Dancers clearly are athletes,¹¹⁻¹⁴ sustain extreme physical stresses like athletes,¹⁵ and experience high injury rates during dance participation.^{3-6,16-25} Various studies place the incidence of ankle injuries between 4.7% and 54% of all injuries suffered by dancers.^{3-5,18,20,21} This review article presents the anatomical and biomechanical principles of the ankle that are relevant to clinicians, scientists, and educators who work with dancers.

Normal Joint Anatomy and Mechanics

Normal Bony Anatomy

The ankle, or talocrural joint, is a trochoid synovial joint. Though it is often considered a hinge, or ginglymus joint,^{26,27} several authors indicate that its axis is more complicated than a simple uniaxial hinge.²⁸⁻³³ The distal tibia and fibula form the joint's box-like mortise; this is an area rather than a specific anatomical structure. The three articular surfaces of the ankle mortise are:

1. Medial: the lateral portion of the medial malleolus,
2. Superior: the tibial plafond,
3. Lateral: the medial surface of the lateral malleolus.

The mortise contains the superior portion of the talus. This includes its articular surface, which is also called the trochlea, or dome. The talar trochlea is wedge-shaped when viewed from the superior direction.³⁴⁻³⁶ It is usually more narrow posteriorly than anteriorly,³⁷ although Barnett and Napier reported that a number of their talar specimens exhibited parallel sides (i.e., the anterior and posterior trochlear widths were equal).²⁸

The talar dome sometimes is described as a truncated cone lying sideways, with the smaller circumference forming the medial edge of the dome and the larger circumference forming the lateral edge.³⁸ Barnett and Napier suggested that the articular surface of the talus is even more complex. They

Jeffrey A. Russell, M.S., A.T.C., is from the University of Wolverhampton School of Sport, Performing Arts and Leisure, Walsall, United Kingdom. Islay McEwan, M.Sc., M.C.S.P., is from Manchester Metropolitan University, United Kingdom. Yiannis Koutedakis, Ph.D., is from the Department of Sport and Exercise Sciences, Thessaly University, Trikala, Greece; and the School of Sport, Performing Arts and Leisure, Wolverhampton University, United Kingdom. Matthew A. Wyon, Ph.D., is from the University of Wolverhampton School of Sport, Performing Arts and Leisure, Walsall, United Kingdom.

Correspondence: Jeffrey A. Russell, M.S., A.T.C., University of Wolverhampton School of Sport, Performing Arts and Leisure, Gorway Road, Walsall WS1 3BD, United Kingdom; jrussell@kardia.org.

identified the arcs of three circles of different radii that demarcate the edges of the dome: one for the lateral edge, one for the anterior one-third of the medial edge, and a third arc for the posterior two-thirds of the medial edge. The smallest of these three is the arc of the anterior medial edge, and the largest is the arc of the posterior medial edge.²⁸ They compared the configuration to two truncated cones lying side-by-side.

The anatomy of the ankle joint, then, precludes the axis of the ankle lying in any of the three cardinal planes (sagittal, coronal, transverse). It is oblique to these planes, due largely to the architecture of the talar dome. A generalized single axis runs through the tips of the malleoli.³⁹ Singh and colleagues reported a single axis running just distal to the tips of the malleoli, but they found sizeable variations in its location among ankles.⁴⁰ Barnett and Napier identified two separate axes in the ankle: one for dorsiflexion and one for plantar flexion.²⁸ Hicks reproduced these findings the following year (1953) and reported that movement of the ankle cannot occur around both of these axes simultaneously.²⁹ More than 35 years later Lundberg's work, using roentgen stereophotogrammetry (a method utilizing x-rays taken in two planes to obtain three-dimensional information about the skeletal system), further developed the observations of Barnett and Napier and Hicks.³⁰⁻³² As seems obvious, dorsiflexion occurs around the dorsiflexion axis and plantar flexion occurs around the plantar flexion axis.^{28,29} These two axes cross in the interior of the talar trochlea. At or near this same point the axes for ankle pronation, supination, medial rotation, and lateral rotation also intersect,^{30,32} a spot Lundberg refers to as a "hub, around which the ankle joint has more freedom of movement than is often assumed."³²

Normal Ligamentous Anatomy and Mechanics

The ankle joint receives its primary support from an array of ligaments that lie medially, laterally, posteri-

orly, and superiorly to the joint. The medial ligament complex is termed the deltoid ligament, a fan-shaped group of four ligaments comprising the anterior talotibial, calcaneotibial, tibionavicular, and posterior talotibial ligaments.⁴¹ These four portions of the deltoid are combined into a substantial expansion of the medial joint capsule.⁴² Siegler and associates noted the relative strength of the deltoid, in spite of their discovery that its calcaneotibial portion could only resist negligible forces before it failed.⁴³ Therefore they disregarded the calcaneotibial ligament in their study, concluding that it is not an important supporting structure of the medial ankle, even though overall the deltoid is quite strong. According to both Siegler and coworkers⁴³ and Attarian and colleagues⁴⁴ the strongest of the main ligaments in the ankle is the deep portion of the deltoid, the anterior and posterior talotibial complex.

The ligament support on the lateral side is not nearly as strong, and this is well known to be the most commonly injured ankle region.^{45,46} The anterior talofibular ligament sits horizontally when the ankle is in anatomical position, running from the anterior edge of the lateral malleolus to the lateral aspect of the neck of the talus.^{42,47} When the ankle is plantar flexed the anterior talofibular ligament moves downward toward a nearly vertical position and tightens;^{45, 47} this results because its talar insertion moves downward. Attarian and associates evaluated several ankle bone-ligament-bone *in vitro* preparations for their capacity to resist force loading.⁴⁴ They found that the anterior talofibular is the weakest of all the ankle ligaments, a conclusion corroborated by other authors.^{42,43,47} The calcaneofibular ligament attaches the distal tip of the lateral malleolus^{46,48} and the lateral tubercle of the calcaneus.^{35,46} (Sarrafian states specifically that this ligament originates from the anterior aspect of the fibular tip.³⁵) The ligament sits obliquely when the ankle is in anatomical position and becomes vertical, or closely parallel to the fibula, in dorsiflexion.⁴⁷ During

plantar flexion its distal attachment moves rearward, which relaxes the ligament and places it into a horizontal position.^{42,47}

Three other ligaments also are important to overall ankle stability: the posterior talofibular ligament, the anterior inferior tibiofibular ligament, and the posterior inferior tibiofibular ligament. The posterior talofibular is a very strong, horizontal ligament that runs between the inside of the posterior lip of the lateral malleolus and the posterolateral tubercle of the talus.⁴⁷ The anterior and posterior inferior tibiofibular ligaments support the syndesmosis of the distal tibia and fibula. Thus, they are proximal to the ankle joint and are significant because the integrity of the mortise is largely dependent on these two ligaments and the interosseous membrane.⁴⁹

In 1950 Bonnin identified the relative weakness of the anterior talofibular ligament and the relative moderate strength of the calcaneofibular ligament.⁴² Makhani suggested that the calcaneofibular ligament "is the most important component of the lateral ligament."⁴⁷ He further indicated that various portions of the lateral ligamenture demonstrate changing orientations and tension forces while the ankle moves through its range of motion, a finding consistent with more recent studies.⁵⁰⁻⁵³ In the often injured lateral ligament complex, it is interesting to consider the characteristics of these ligaments in the positions of demi-plié and en pointe. According to the authors cited above, it is expected that in demi-plié the anterior talofibular ligament will relax and the calcaneofibular ligament will be under tension. The opposite is expected when en pointe. Although no studies to date have examined the ankle ligaments under the extreme position of en pointe, it is clear that strain (a measure of deformation) in the anterior talofibular increases with increasing plantar flexion.⁵⁰⁻⁵⁴ Cawley and France⁵⁴ and Bahr and colleagues⁵⁰ further concluded that the increase in anterior talofibular strain is accentuated during compressive loading through the ankle

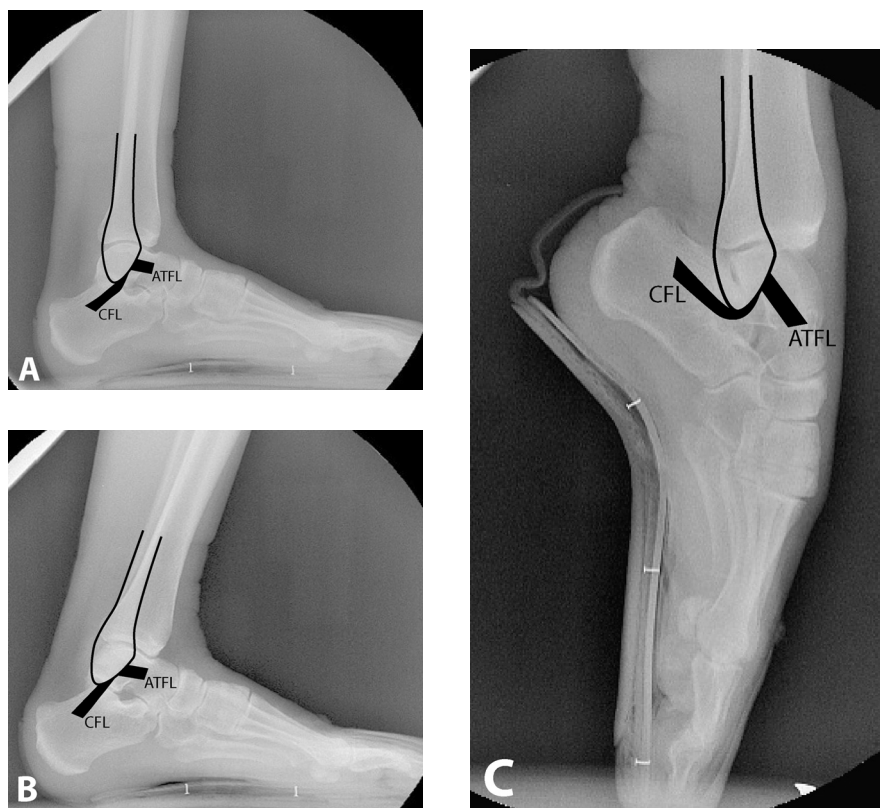


Figure 1 This sequence shows the orientations of the anterior talofibular and calcaneofibular ligaments in different ankle positions. The ligament positions are based on investigations performed in non-dancers^{35,41,42,45-48,77} because these ligaments have not previously been studied in situ in a dancer population. The fibula is outlined for ease of visualization. **A**, In the neutral ankle position the anterior talofibular ligament (ATFL) is essentially horizontal and the calcaneofibular (CFL) is oblique to vertical. **B**, Upon moving to demi-plié the positions of the ligaments do not change appreciably, but their orientations relative to the fibula change. The anterior talofibular ligament's angle with the fibula becomes more acute and the calcaneofibular ligament is nearly parallel to the fibula. **C**, When en pointe the anterior talofibular ligament is virtually parallel to the fibula, while the calcaneofibular swings posteriorly to a somewhat horizontal position.

joint. Maximum plantar flexion en pointe places the anterior talofibular ligament parallel to the fibula; when in this position it functions as the primary stabilizing ligament of the lateral ankle.⁵⁰ Furthermore, based on the observations of the cited researchers, the fully plantar flexed en pointe position presumably places the anterior talofibular ligament at particular risk because it is the weakest ankle ligament, it is at its longest length, and it is under its maximum tension force. Figure 1 show the anticipated positions of the anterior talofibular and calcaneofibular ligaments at three points in ankle range of motion seen in ballet.

Motion at the Ankle Joint *Range of Dorsiflexion and Plantar Flexion*

Dorsiflexion of the ankle is usually described as a uniaxial motion in the sagittal plane. It is the movement of the dorsum of the foot upward toward the leg. This movement places the ankle into its most stable position, when the trochlea of the talus and the articular surfaces of the tibia and fibula are "close-packed."⁵⁵ The

opposite motion, plantar flexion, is usually described as a uniaxial movement of the plantar surface of the foot in an inferior direction (i.e., pointing the foot).²⁶ Parenthetically, the dorsiflexion and plantar flexion labels are preferred because confusion exists when assigning the terms flexion and extension to ankle movements. For instance, some authors use flexion to mean plantar flexion and extension to mean dorsiflexion.^{27,56} Conversely, others give extension as an alternate name for plantar flexion and flexion as an alternate for dorsiflexion.²⁶

Reporting the range of motion of the ankle is subject to various technical considerations. Clinical range of motion measurement uses the anatomical landmarks of the midlines of the fibular shaft and fifth metatarsal and an axis at the lateral malleolus.⁵⁷ Considering anatomical position—or ankle neutral position—as zero, in non-dancers normal active clinical dorsiflexion is 20° and normal active clinical plantar flexion is 50°.^{26,27,36,55,57} However, goniometry of the ankle joint necessarily encompasses movements in joints of the foot,^{31,33,42,58} so that, in fact, accurate clinical measure-

ment of tibiotalar motion alone is not possible.⁵⁹

Lundberg and associates found that as much as 40% of plantar flexion motion occurred in the joints of the midfoot, but the relative amounts attributable to each of these joints varied widely among individuals. They reported mean talocrural motion (i.e., angular motion between the tibia and the talus only) as 23° of dorsiflexion and 28° of plantar flexion.^{30,31}

Backer and Kofoed compared passive ankle range of motion using a manual goniometer with active weightbearing ankle range of motion using a perpendicular pendulum goniometer. Their results for passive motion were 15° of dorsiflexion and 44° of plantar flexion; for active weightbearing motion they measured 38° of dorsiflexion and 50° of plantar flexion.⁶⁰

True ankle joint motion between the tibia and talus is typically measured by x-ray. Bonnin suggested that radiography is the only accurate measurement tool for talocrural motion.⁴² He demonstrated that the arc of the articular surface of the talar dome subtends an angle of 90° to 105°, and that

50° to 55° of this is taken up by the tibial plafond's congruence with the talus. According to his measurements a maximum of 55° is left for total movement of the tibia on the talus, with an additional 5° available if the posterior edge of the tibial articular surface passes the posterior edge of the talar articular surface.⁴²

Backer and Kofoed noted a significant difference between radiographic and clinical measurements in plantar flexion, attributing the difference to the former measuring tibiotalar motion and the latter measuring motion between the leg and the foot.⁶¹ Using an x-ray method, Sammarco and coworkers reported the mean ranges of motion of the ankle in weightbearing as 21° ± 7° for dorsiflexion and 23° ± 8° for plantar flexion in non-dancers.³³ His non-weightbearing findings were 23° ± 8° for dorsiflexion and 23° ± 10° for plantar flexion. The discrepancy in these plantar flexion values when compared to those obtained by clinical goniometry reflects the difference between true tibiotalar range of motion and ankle motion that includes tibiotalar range of motion plus segmental motion between pairs of tarsals and metatarsals.

Weseley and colleagues also studied weightbearing ankle range of motion radiographically.⁵⁶ In their series of 50 ankles maximum tibiotalar dorsiflexion values fell between 0° and 23°, and maximum tibiotalar plantar flexion values fell between 10° and 51°. Their comparative clinical measurements among ankles ranged from a low of 0° to a high of 30° for dorsiflexion, and from a low of 60° to a high of 85° for plantar flexion. This again highlights the difference between clinical range of motion that includes motion at joints in the foot and true ankle range of motion between the tibia and talus.

Assessment of plantar flexion can be technically challenging,⁵⁸ particularly in ballet dancers. This is partly due to the extreme clinical range seen in dancers. Hamilton and associates evaluated 14 female and 14 male professional dancers on a variety of musculoskeletal characteristics that included ankle range of motion.⁶² They

found plantar flexion in females to be 113° from anatomical position and 107° in males. Wiesler and coworkers measured ankle range of motion in 119 female and 29 male dancers.⁶³ Their reported plantar flexion values were 101° ± 2.5° (left) and 96° ± 2.7° (right) in female ankles. For males their results were 99° ± 6.9° (left) and 97° ± 7.3° (right). Dorsiflexion values reported by these investigators were 77° ± 2.2° (left) and 78° ± 2.3° (right) for females and 62° ± 6.1° (left) and 63° ± 5.9° (right) for males.

Novella described a method for assessing maximal plantar flexion in dancers that identifies the angular difference between the dorsal border of the talus and navicular and the anterior border of the tibia using a gravity goniometer (inclinometer).⁶⁴ In his series of 811 dancers he found this mean difference to be 8° ± 3° in females and 5° ± 2.5° in males. Calculations from his technique indicate that relative to the tibia the talus plantar flexes 98° from anatomical position in female dancers and 95° in male dancers. This stands in stark contrast to other authors' findings in non-dancers.

Lin and associates measured ankle plantar flexion in university ballet dancers en pointe using video analysis.⁶⁵ Mean plantar flexion for the right ankle was 52° ± 4.3°; for the left ankle it was 54° ± 6.0°. The proximity of these values to the maximum plantar flexion seen in non-dancers (50°) suggests that the placement of the anatomical markers on their subjects could not approximate the

anatomical landmarks used in ankle goniometry. Supporting this point is the authors' description of the markers' placements: on the mid-shank, the lateral malleolus, the heel, and the dorsum of the foot between the second and third metatarsophalangeal joints (with the subject wearing pointe shoes). Even accounting for differences between weightbearing and non-weightbearing measurement of range-of-motion, their protocol could not have measured tibiotalar motion, and it likely underestimated the clinical range of motion in these ballerinas when compared to the work of other authors.⁶²⁻⁶⁴

Muscles Acting on the Ankle

The muscles that act on the ankle to produce dorsiflexion and plantar flexion can be categorized into primary and secondary movers. Muscles that produce ankle movement also have other, and often primary, functions. They are all extrinsic muscles, meaning that their contractile portions lie outside the ankle itself—in the leg—and the tendons of those muscles insert on bones of the foot in such a way that ankle motion is elicited when the muscles contract. These leg muscles are divided into four compartments bounded by fascial septa: the superficial posterior compartment, the deep posterior compartment, the lateral compartment, and the anterior compartment. The muscles contained in each compartment are listed in Table 1.

The primary plantar flexors are the two calf muscles: gastrocnemius and

Table 1 Muscle Compartments of the Leg

| Muscle Compartment | Muscles |
|-----------------------|--|
| Superficial Posterior | Gastrocnemius Soleus Plantaris |
| Deep Posterior | Flexor hallucis longus Flexor digitorum longus Tibialis posterior |
| Lateral | Peroneus longus Peroneus brevis |
| Anterior | Extensor hallucis longus Tibialis anterior Peroneus tertius (when present) |

soleus.²⁶ These are sometimes referred to as “triceps surae” because of their three origins, or heads: two of the gastrocnemius and one of the soleus. The gastrocnemius is a two-joint muscle that also flexes the knee.²⁶ A third, yet weaker, plantar flexor is the plantaris; it is of less practical consequence in plantar flexion because it is relatively small compared to the triceps surae muscles. It is also somewhat difficult to study because of its location under the gastrocnemius and its variability of morphology and tendon insertion.⁶⁶ Plantaris is absent in nearly 7% of individuals; one-third of these have bilateral absence.⁶⁶

Secondary plantar flexors include muscles whose primary actions are inversion, eversion, or toe flexion. An inverter that assists with plantar flexion is tibialis posterior.^{26,27} Evertors that help plantar flex the ankle are peroneus brevis and peroneus longus.^{26,27} Finally, two toe flexors also contribute to plantar flexion: flexor hallucis longus and flexor digitorum longus.^{26,27}

The primary dorsiflexor of the ankle is tibialis anterior.²⁶ However, the two extrinsic toe extensor muscles—extensor hallucis longus and extensor digitorum longus—also contribute significantly to dorsiflexion because of their course across the anterior aspect of the ankle. Peroneus tertius, sometimes thought of as an offshoot of extensor digitorum longus, also should be considered an assistor of dorsiflexion,²⁷ though it is absent in

10.5% of individuals.⁶⁷ Table 2 summarizes the various functions of the extrinsic leg muscles in the context of plantar flexion and dorsiflexion.

Certain muscles not required for gross movement in a particular dance maneuver may play a role in balance. Although electromyographical studies of dancers are scarce, the first of two investigations by Trepman and colleagues explored first position standing posture and demi-plié.⁶⁸ They found the lateral and medial heads of the gastrocnemius—a plantar flexor—displayed a variety of EMG patterns during demi-plié by professional dancers. Since the demi-plié movement does not require plantar flexion, they suggested the gastrocnemius likely contracts as necessary to preserve balance. Other muscles in which they found similar contractile variability during demi-plié were tibialis anterior, gluteus maximus, the hamstring group, and the adductor group.

These authors also discovered in their first study that the tibialis anterior increases its contractility at the point of changing from lowering to raising in the demi-plié.⁶⁸ In their second study,⁶⁹ tibialis anterior contracted isometrically during the portions of grand-plié when the heel was not in contact with the ground. Thus, the tibialis anterior may stabilize the ankle for proper execution of either maneuver. The real value of the work by Trepman and colleagues is much broader than muscle function

in the lower extremity during specific actions. That is, their investigations highlight an interesting and necessary area of future research because it appears that many assumptions about how muscles contract as movers and stabilizers to produce dance movements may need to be re-evaluated.^{68,69}

Mechanical Levers in Ankle Movement

Motion at the ankle—in dance or any other activity—depends on how forces are applied to the levers of the skeleton. In mechanics there are three types of levers: first, second, and third class. All three types are seen about the ankle; the class depends on what motion is being performed and whether or not the lower extremity is weightbearing. The ankle is a second class lever system when performing relevé.²⁶ In a second class lever, the resistance (body weight) is between the fulcrum and the applied force. Therefore, in relevé the fulcrum is the metatarsophalangeal region on the floor, the resistance is the body weight exerted through the talocrural joint, and the force of action is exerted by the triceps surae inserted at the posterior calcaneus via the Achilles’ tendon (Fig. 2A). Remaining on the toes requires isometric contraction of the musculature while maintaining the center of gravity over the foot’s area of contact with the floor.⁷⁰

Dorsiflexion while weightbearing creates a fulcrum where the heel rests

Table 2 Muscles Acting on the Talocrural Joint (adapted from Floyd and Thompson²⁶ and Magee²⁷)

| Action | Muscles Acting | Primary or Secondary Mover | Additional Actions of Muscle |
|-----------------|---------------------------|----------------------------|-----------------------------------|
| Plantar flexion | Gastrocnemius | P | Knee flexion |
| | Soleus | P | |
| | Plantaris | S | Knee flexion |
| | Flexor hallucis longus | S | Flexion of great toe; Inversion |
| | Flexor digitorum longus | S | Flexion of toes 2–5; Inversion |
| | Tibialis posterior | S | Inversion |
| | Peroneus longus | S | Eversion |
| | Peroneus brevis | S | Eversion |
| Dorsiflexion | Tibialis anterior | P | Inversion |
| | Extensor hallucis longus | S | Extension of great toe; Inversion |
| | Extensor digitorum longus | S | Extension of toes 2–5; Eversion |
| | Peroneus tertius | S | Eversion |

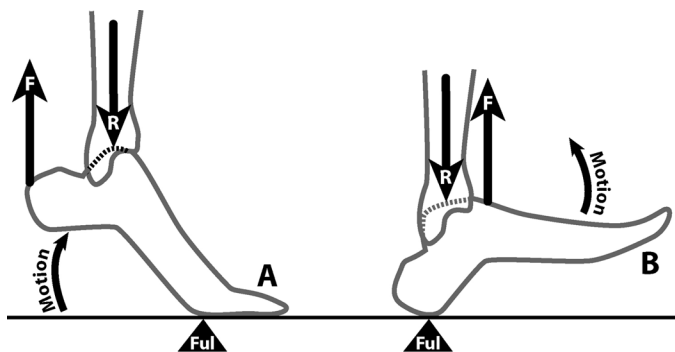


Figure 2 A shows a second class lever system with plantar flexion in relevé. B shows a second class lever system when dorsiflexing to lift the forefoot off the floor. (F = force applied by muscles; R = resistance force of body weight; Ful = fulcrum)

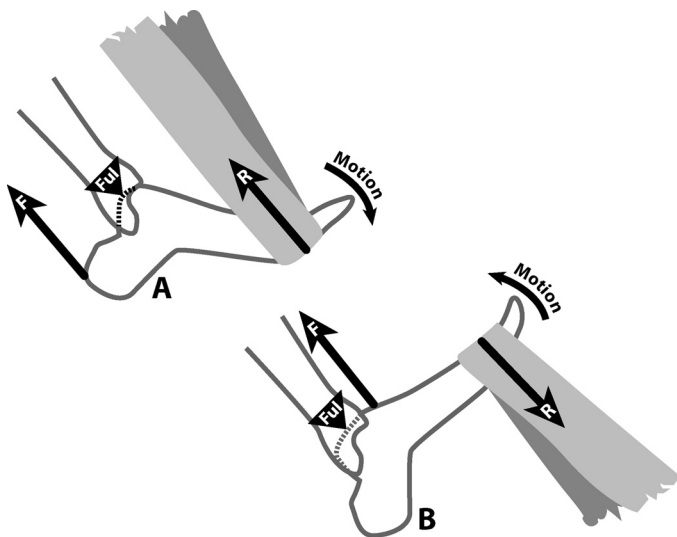


Figure 3 A shows a first class lever system as the ankle is plantar flexed against the resistance of an elastic exercise band. B shows a third class lever system as the ankle is dorsiflexed against the resistance of the elastic band. (F = force applied by muscles; R = resistance of elastic band; Ful = fulcrum)

on the floor. This also is a second class lever system because the force of the dorsiflexors is exerted forward of the resistance (which is again the force of the body weight through the talocrural joint). Note that as in plantar flexion, here the resistance is between the fulcrum and the applied force. This system is shown in Figure 2B.

One more mechanical observation about the lever system of the ankle is worth mentioning because it pertains to ankle strengthening and rehabilitation. Consider the situation of using an elastic resistance band to develop plantar flexion strength. The band passes across the plantar surface of the forefoot, with the dancer holding both ends while plantar flexing against

the resistance of the band. In this case the ankle operates as a first class lever. In such a lever—for example, a see-saw—the fulcrum is positioned between the resistance and the acting force. Thus, the fulcrum is the talocrural joint, the resistance is applied on the plantar forefoot, and the force of the triceps surae acts on the calcaneus. This is shown in Figure 3A.

Conversely, strengthening the dorsiflexors would require the elastic band to pass across the dorsal surface of the forefoot with the free ends of the band secured by an assistant or a piece of apparatus. In this scenario the ankle is a third class lever system, because the force application provided by the dorsiflexors is between the fulcrum

(the talocrural joint) and the resistance on the forefoot. Figure 3B illustrates this.

Compression of Joint Surfaces at Extremes of Ankle Motion

Stormont and coworkers suggest that articular surface contact between the tibia and talus provides a sizeable amount of ankle stability to valgus and varus movement between 15° of dorsiflexion and 20° of plantar flexion in the absence of the ligaments.⁷¹ Clearly the tibiotalar motion of a ballerina moving from demi-plié to en pointe moves through a substantially greater range of motion than this. However, no studies replicate Stormont workers' findings at the extremes of ankle motion seen in ballet. When the ankle is in maximum plantar flexion during demi-pointe or pointe the posterior edge of the tibial plafond articulates with the talus and calcaneus. In spite of the seemingly reduced contact area of the articular surfaces of the tibia and talus (because of the narrower posterior portion of the talus moving into the mortise), standing en pointe is a bony "locked" position of the ankle and subtalar joints^{7,72,73} from which ankle sprains are unlikely.⁷

Brown and Micheli express an alternate opinion, suggesting that in extreme plantar flexion "...only the narrow portion of the talus remains in the mortise—affording only limited bony stability while placing increasing demands on the soft-tissue restraints..."⁷⁴ Certainly the contours of the ankle's articular surfaces, the forces transmitted from the tibia through the ankle to the foot and then the floor, the mechanics of the subtalar joint, and the tension forces applied to the ankle and foot by the ligaments and muscles and tendons all play a role in ankle stability en pointe, and represent topics for future research.

In the forced dorsiflexion of demi-plié an anterior fulcrum is created if the anterior edge of the tibial plafond contacts the dorsal neck of the talus.⁷⁵ The resulting lever system stretches the posterior ankle soft tissues, and posterior distraction of the joint then removes the normally parallel congru-

ence of the tibial and talar articular surfaces. This is a radiographic finding associated with dancers with anterior bony impingement.⁷⁵ Anterior impingement is exacerbated when exostoses either extend the anterior edge of the tibia, raise the dorsum of the talar neck, or both.⁷⁶

Conclusion

A properly functioning ankle is fundamental to success in dance. While the ankle injury rate in dance is high, it may be surprising that it is not even higher given the long hours of rehearsing and performing. Studying clinically-oriented anatomy and biomechanics of the ankle will help dance medicine practitioners, dance scientists, dance instructors, and dancers understand the intricacies of the ankle in this art form. The bones, ligaments, muscles, and tendons, along with the nervous and cardiovascular systems, provide the functional framework for the beauty, artistry, and athleticism of the various genres of dance. There is ample fertile ground for future research into the ankle function of dancers. Particularly in classical ballet, the only physical activity in the world requiring repetitive movement from maximum forced dorsiflexion to maximum forced plantar flexion, there is much knowledge still to be gained beyond the currently available investigations of the ankle in non-dancers and sports participants.

References

- Fong DT-P, Hong Y, Chan L-K, Yung PS-H, Chan K-M. A systematic review on ankle injury and ankle sprain in sports. *Sports Med.* 2007;37(1):73-94.
- Hootman JM, Dick R, Agel J. Epidemiology of collegiate injuries for 15 sports: summary and recommendations for injury prevention initiatives. *J Athl Train.* 2007;42(2):311-9.
- Nilsson C, Leanderson J, Wykman A, Strender L. The injury panorama in a Swedish professional ballet company. *Knee Surg Sports Traumatol Arthrosc.* 2001;9(4):242-6.
- Rovere GD, Webb LX, Gristina AG, Vogel JM. Musculoskeletal injuries in theatrical dance students. *Am J Sports Med.* 1983;11(4):195-8.
- Washington EL. Musculoskeletal injuries in theatrical dancers: site, frequency, and severity. *Am J Sports Med.* 1978;6(2):75-98.
- Garrick JG, Requa R. Ballet injuries: an analysis of epidemiology and financial outcome. *Am J Sports Med.* 1993;21(4):586-90.
- Hamilton WG. Sprained ankles in ballet dancers. *Foot Ankle.* 1982;3(2):99-102.
- Hamilton WG. Stenosing tenosynovitis of the flexor hallucis longus tendon and posterior impingement upon the os trigonum in ballet dancers. *Foot Ankle.* 1982;3(2):74-80.
- Hamilton WG. Foot and ankle injuries in dancers. *Clin Sports Med.* 1988;7(1):143-73.
- Hamilton WG, Geppert MJ, Thompson FM. Pain in the posterior aspect of the ankle in dancers: differential diagnosis and operative treatment. *J Bone Joint Surg Am.* 1996;78(10):1491-500.
- Fitt SS. *Dance Kinesiology* (2nd ed). New York: Schirmer Books, 1996.
- Koutedakis Y, Jamurtas A. The dancer as a performing athlete. *Sports Med.* 2004;34(10):651-61.
- Stretanski MF. Classical ballet: the full contact sport. *Am J Phys Med Rehabil.* 2002;81(5):392-3.
- Stretanski MF. Medical and rehabilitation issues in classical ballet. *Am J Phys Med Rehabil.* 2002;81(5):383-91.
- Conti SF, Wong YS. Foot and ankle injuries in the dancer. *J Dance Med Sci.* 2001;5(2):43-50.
- Bronner S, Ojofeitimi S, Rose D. Injuries in a modern dance company: effect of comprehensive management on injury incidence and time loss. *Am J Sports Med.* 2003;31(3):365-73.
- Bronner S, Ojofeitimi S, Spriggs J. Occupational musculoskeletal disorders in dancers. *Phys Ther Rev.* 2003;8:57-68.
- Byhring S, Bø K. Musculoskeletal injuries in the Norwegian National Ballet: a prospective cohort study. *Scand J Med Sci Sports.* 2002;12(6):365-70.
- Askling C, Lund H, Saartok T, Thorstensson A. Self-reported hamstring injuries in student-dancers. *Scand J Med Sci Sports.* 2002;12:230-5.
- Kerr G, Krasnow D, Mainswaring L. The nature of dance injuries. *Med Prob Perform Artists.* 1992;7:25-9.
- Bowling A. Injuries to dancers: prevalence, treatment and perception of causes. *BMJ.* 1989;298:731-4.
- Laws H. *Fit to Dance 2*. London: Dance UK, 2005.
- Sohl P, Bowling A. Injuries to dancers: prevalence, treatment and prevention. *Sports Med.* 1990;9(5):17-22.
- Olsson I. [A 2-year study of 77 dancers: almost 90 per cent needed help because of injury]. *Lakartidningen.* 1998;95(15):1689.
- Arendt YD, Kerschbaumer F. [Injury and overuse pattern in professional ballet dancers]. *Z Orthop Ihre Grenzgeb.* 2003;141(3):349-56.
- Floyd RT, Thompson CW. *Manual of Structural Kinesiology* (15th ed). Boston: McGraw-Hill, 2004.
- Magee DJ. *Orthopedic Physical Assessment* (4th ed). Philadelphia: Saunders, 2002.
- Barnett CH, Napier JR. The axis of rotation at the ankle joint in man: its influence upon the form of the talus and the mobility of the fibula. *J Anat.* 1952;86(1):1-9.
- Hicks JH. The mechanics of the foot. I. The joints. *J Anat.* 1953;87(4):345-57.
- Lundberg A. Kinematics of the ankle and foot: in vivo roentgen stereophotogrammetry. *Acta Orthop Scand.* 1989;60(Suppl 233):1-24.
- Lundberg A, Goldie I, Kalin B, Selvik G. Kinematics of the ankle/foot complex: plantar flexion and dorsiflexion. *Foot Ankle.* 1989;9(4):194-200.
- Lundberg A, Svensson OK, Németh G, Selvik G. The axis of rotation of the ankle joint. *J Bone Joint Surg Br.* 1989;71:94-9.
- Sammarco GJ, Burstein AH, Frankel VH. Biomechanics of the ankle: a kinematic study. *Orthop Clin N Am.* 1973;4(1):75-96.
- Stiehl JB. Anthropomorphic studies of the ankle joint. *In: Stiehl JB (ed): Inman's Joints of the Ankle* (2nd ed). Baltimore: Williams and Wilkins, 1991, pp. 1-6.
- Sarrafan SK. *Anatomy of the Foot and Ankle: Descriptive, Topographic, Functional* (2nd ed). Philadelphia: J.B. Lippincott Company, 1993.
- Cailliet R. *Foot and Ankle Pain* (3rd ed). Philadelphia: F.A. Davis, 1997.
- Sammarco GJ, Tablante EB. Foot and ankle in dance. *In: Sataloff RT, Brandfonbrener AG, Lederman RJ*

- (eds): *Performing Arts Medicine* (2nd ed). San Diego USA: Singular Publishing Group, 1998, pp. 301-120.
38. Johnson JE. Functional morphology of the trochlea. In: Stiehl JB (ed): *Inman's Joints of the Ankle* (2nd ed). Baltimore: Williams and Wilkins, 1991, pp. 7-13.
 39. Sammarco GJ, Hockenbury RT. Biomechanics of the foot and ankle. In: Nordin M, Frankel VH, eds. *Basic Biomechanics of the Musculoskeletal System* (3rd ed). Philadelphia: Lippincott Williams & Wilkins, 2001, pp. 222-255.
 40. Singh AK, Starkweather KD, Hollister AM, Jatana S, Lupichuk AG. Kinematics of the ankle: a hinge axis model. *Foot Ankle*. 1992;13(8):439-46.
 41. Logan BM, Singh D, Hutchings RT. *McMinn's Color Atlas of Foot and Ankle Anatomy* (3rd ed). Philadelphia: Mosby, 2004.
 42. Bonnin JG. *Injuries to the Ankle (facsimile of the 1950 edition)*. Darien, CT, USA: Hafner Publishing Co., 1970.
 43. Siegler S, Block J, Schneck CD. The mechanical characteristics of the collateral ligaments of the human ankle joint. *Foot Ankle*. 1988;8(5):234-42.
 44. Attarian DE, McCrackin HJ, DeVito DP, McElhaney JH, Garrett WE Jr. Biomechanical characteristics of human ankle ligaments. *Foot Ankle*. 1985;6(2):54-8.
 45. Anderson KJ, LeCocq JF. Operative treatment of the injury to the fibular collateral ligament of the ankle. *J Bone Joint Surg Am*. 1954;36(4):825-32.
 46. Ferran NA, Maffulli N. Epidemiology of sprains of the lateral ankle ligament complex. *Foot Ankle Clin N Am*. 2006;11(3):659-62.
 47. Makhani JS. Lacerations of the lateral ligaments of the ankle. *J Int Coll Surg*. 1962;38(5):454-66.
 48. Stiehl JB. Biomechanics of the ankle joint. In: Stiehl JB (ed): *Inman's Joints of the Ankle* (2nd ed). Baltimore: Williams and Wilkins, 1991, pp. 39-63.
 49. Bartoniček J. Anatomy of the tibiofibular syndesmosis and its clinical relevance. *Surg Radiol Anat*. 2003;25:379-86.
 50. Bahr R, Pena F, Shine J, Lew WD, Engebretsen L. Ligament force and joint motion in the intact ankle: a cadaveric study. *Knee Surg Sports Traumatol Arthrosc*. 1998;6:115-21.
 51. Renstrom P, Wertz M, Incavo S, et al. Strain in the lateral ligaments of the ankle. *Foot Ankle*. 1988;9(2):59-63.
 52. Colville MR, Marder RA, Boyle JJ, Zarins B. Strain measurement in lateral ankle ligaments. *Am J Sports Med*. 1990;18(2):196-200.
 53. Nigg BM, Skarvan G, Frank CB, Yeadon MR. Elongation and forces of ankle ligaments in a physiological range of motion. *Foot Ankle*. 1990;11(1):30-40.
 54. Cawley PW, France EP. Biomechanics of the lateral ligaments of the ankle: an evaluation of the effects of axial load and single plane motions on ligament strain patterns. *Foot Ankle*. 1991;12(2):92-9.
 55. Donatelli RA. Normal anatomy and biomechanics. In: Donatelli RA (ed): *The Biomechanics of the Foot and Ankle* (2nd ed). Philadelphia: F.A. Davis, 1996, pp. 3-33.
 56. Weseley MS, Koval R, Kleiger B. Roentgen measurement of ankle flexion-extension motion. *Clin Orthop*. 1969;65:167-74.
 57. Reese NB, Bandy WD. *Joint Range of Motion and Muscle Length Testing*. Philadelphia: W.B. Saunders, 2002.
 58. Novella TM. Simple techniques for quantifying choreographically essential foot and ankle extents of motion. *J Dance Med Sci*. 2004;8(4):118-22.
 59. Kitaoka HB, Alexander IJ, Adelaar RS, et al. Clinical rating systems for the ankle-hindfoot, midfoot, hallux, and lesser toes. *Foot Ankle Int*. 1994;15(7):349-53.
 60. Backer M, Kofoed H. Weight-bearing and non-weightbearing ankle joint mobility. *Med Sci Res*. 1987;15:1309-10.
 61. Backer M, Kofoed H. Passive ankle mobility: clinical measurement compared with radiography. *J Bone Joint Surg Br*. 1989;71(4):696-8.
 62. Hamilton WG. A profile of the musculoskeletal characteristics of elite professional ballet dancers. *Am J Sports Med*. 1992;20(3):267-73.
 63. Weisler ER, Hunter DM, Martin DF, Curl WW, Hoen H. Ankle flexibility and injury patterns in dancers. *Am J Sports Med*. 1996;24(6):754-7.
 64. Novella TM. An easy way to quantify plantarflexion in the ankle. *J Back Musculoskel Rehabil*. 1995;5:191-9.
 65. Lin C-F, Su F-C, Wu H-W. Ankle biomechanics of ballet dancers in relevé en pointé dance. *Res Sports Med*. 2005;13:23-35.
 66. Daseler EH, Anson BJ. The plantaris muscle: an anatomical study of 750 specimens. *J Bone Joint Surg Am*. 1943;25(4):822-7.
 67. Joshi SD, Joshi SS, Athavale SA. Morphology of peroneus tertius muscle. *Clin Anat*. 2006;19(7):611-4.
 68. Trepman E, Gellman RE, Solomon R, et al. Electromyographic analysis of standing posture and demi-plié in ballet and modern dancers. *Med Sci Sports Exerc*. 1994;26(6):771-82.
 69. Trepman E, Gellman RE, Micheli LJ, De Luca CJ. Electromyographic analysis of grand-plié in ballet and modern dancers. *Med Sci Sports Exerc*. 1998;30(12):1707-20.
 70. Laws K. *Physics and the Art of Dance: Understanding Movement*. New York: Oxford University Press, 2002.
 71. Stormont DM, Morrey BF, An KN, Cass JR. Stability of the loaded ankle: Relation between articular restraint and primary and secondary static restraints. *Am J Sports Med*. 1985;13(5):295-300.
 72. Macintyre J, Joy EA. Foot and ankle injuries in dance. *Clin Sports Med*. 2000;19(2):351-68.
 73. Shah S, Luftman J, Vigil DV. Stress injury of the talar dome and body in a ballerina: a case report. *J Dance Med Sci*. 2005;9(3):91-5.
 74. Brown TD, Micheli LJ. Foot and ankle injuries in dance. *Am J Orthop*. 2004;33(6):303-9.
 75. Kleiger B. Anterior tibiotalar impingement syndromes in dancers. *Foot Ankle*. 1982;3(2):69-73.
 76. O'Donoghue DH. Impingement exostoses of the talus and tibia. *J Bone Joint Surg Am*. 1957;39(4):835-52.
 77. Christman RA. The normal foot and ankle. In: Christman RA (ed): *Foot and Ankle Radiology*. St. Louis: Churchill Livingstone, 2003, pp. 130-42.