

Non degenerative disease in MRI cervical spine of symptomatic patients

Dan B Karki¹, Om Biju Panta², Ghanashyam Gurung³

¹Department of Radiology and Imaging, Patan Academy of Health Sciences, Patan, Nepal

²Department of Radiology and Imaging, Koshi Zonal Hospital, Biratnagar, Nepal

³Department of Radiology and Imaging, TU Teaching Hospital, Kathmandu, Nepal

Correspondence

Dr Dan B Karki

Department of Radiology and Imaging, Patan Academy of Health Sciences, Patan, Nepal

Email:

kedibi@yahoo.com

DOI: <http://dx.doi.org/10.3126/jcmsn.v11i4.14320>

ABSTRACT

Background & Objectives: The most common etiology of neck pain is degenerative disc disease, however non-degenerative disease can be important cause of neck pain. This study aims to study the non-degenerative findings in cervical MRI in symptomatic patients with neck and radicular pain. **Materials & Methods:** The study was a institutional record based retrospective study performed for the duration of 3 years. MRI performed for patients with neck pain and/ or radiculopathy were reviewed. Patients with post operative findings were excluded from the study. Statistical analysis was done using SPSS 21.0. **Results:** A total of 721 MRI were performed for neck pain and radiculopathy, among which 91 (12.13%) cases had non-degenerative changes. Most common non degenerative change was traumatic lesions followed by neoplastic lesions and syrinx. Traumatic lesions were more common in males as compared to females. Infection was more common in females as compared to males. C5 and C6 vertebrae were most common vertebra involved in trauma and infection. Some cases like signal change in spinal cord, and syrinx were also noted in our study. **Conclusion:** Non degenerative cause of neck pain were less common but important cause of neck pain. Traumatic lesions were the most common cause of non degenerative neck pain.

Key words: Cervical Spine, Magnetic Resonance Imaging, Neck pain, Non-degenerative

Citation: Karki DB, Panta OB, Gurung G. Non degenerative disease in MRI cervical spine of symptomatic patients . JCMS Nepal. 2015;11(4):20-23.

INTRODUCTION

Neck and radicular pain radiating to upper limbs are the common symptoms for which patients seek medical consultation.¹ The most common cause of these symptoms is degenerative disc disease. However there are many other conditions that may be associated with the pain such as marrow signal changes in vertebrae with various causes, diffuse signal changes in cervical cord, neoplastic lesion, traumatic lesion, infective process etc.² Sometimes there may be different findings that may be just an incidental and may not be associated with the pain such as hemangioma. MRI is the choice of investigation for identifying degenerative disc disease as well as non-degenerative pathologies.² It could delineate the spinal pathology as well as soft tissue intensity and cord lesions. It is sometimes important to know the conditions that may be evident in MRI of the cervical spine such as syrinx, which may lead us to seek the pathology in other levels. The non-degenerative lesions may be found

simultaneously along with the degenerative disc disease. This study was carried out to study the non-degenerative findings in cervical MRI, which is performed in symptomatic patients with chronic neck pain and/or radiculopathy.

MATERIALS AND METHODS

The study was a retrospective and descriptive study conducted in symptomatic patient who were referred for MRI of cervical spine at Kathmandu Imaging in Kathmandu, Nepal. All MRI of cervical spine from May 2010 to May 2013 were reviewed. Only those MRI performed for chronic neck pain and/or radiculopathy to upper limbs with complete clinical form and report were included in the study. MRI performed for other indication like postoperative cases were excluded from the study. MR images were acquired by 0.35 Tesla Siemens MRI machine (Magnetom C – an open MRI system from Germany). MRI images were acquired using head and neck (medium /large sized) combination

coil with read matrix of 256. Images were acquired in sagittal plane in T1 weighted spin echo (Repetition time (TR)/ Echo time (TE) – 610 /14) and T2 weighted spin echo (TR/TE -3500 /117 ms) with slice thickness of 3.5 mm; gap of 20% of slice thickness and FOV of 260 mm. Images obtained in axial plane consists of T1 weighted spin echo (TR/ TE - 610/ 14 ms) and T2 weighted gradient echo (TR/TE - 1100/26 ms) with slice thickness of 3.5 mm; slice gap of 10 % of slice thickness and FOV of 230 mm. Coronal images and Short Tau Inversion Recovery (STIR) sequences (TI – 110 ms) were acquired in some cases for further evaluation.

Three experienced radiologists, one senior with more than 10 years experience in Spine MRI, reported the MRI images with mutual consensus in disputed issues. MRI images demonstrating degenerative disc disease and normal MRI examination was excluded from the study.

The data were plotted in SPSS sheet and statistical analysis was obtained from SPSS version 19.

RESULT

Out of total 721 MRI that were performed for neck pain and radiculopathy only 91(12.13) patients had non-degenerative pathologies of the cervical spine. The mean age was 44.04 ± 17.17 years and median was 45 years (interquartile range -29). The study population comprised of 60(65.9%) males and 31 (34.1%) females.

Traumatic lesions includes hyperflexion/hyperextension injuries, compression fractures and wedge fractures. Table 1 showed that the traumatic lesions were the most common non-degenerative pathology (24; 26.6%). Tumors accounted for 16 (17.6%) and infection accounted for 13(14.3%).

In traumatic lesions, involvement of multiple levels or single level was noted. The most common level involved was C6 (16; 17.6%) followed by C5 (12; 13.2%). (Figure 1, Table 2) Spinal cord compression along with cord contusion was seen in 5(20.8%) patients among all traumatic lesions. Traumatic lesions were significantly more common in males than in females with odd's ratio of 2.58. (Table 3)

Vertebral neoplastic lesion and nerve sheath tumor accounted for 7(43.75%) cases each, while spinal cord neoplasm accounted for only 2(12.5%) cases. No significant difference in sex distribution of the lesions was noted.

All infective lesions on MRI were spondylodiscitis

Table 1: Non degenerative pathologies of cervical spine in symptomatic patients.

Non degenerative pathologies	Number (%) N=91
Traumatic lesion	24(26.6)
Neoplastic Lesion	16(17.6)
Syrinx	15(16.5)
Infection	13(14.3)
Diffuse high signal in cervical spinal cord	10(11.0)
Hemangioma of vertebra	8 (8.8)
Diffuse marrow signal change in vertebrae	5(5.5)

Table 2: Level of Involvement of vertebrae in non-degenerative pathologies.

Level	Infective pathology	Traumatic lesions
C1	1	0
C2	2	3
C3	5	2
C4	8	4
C5	9	12
C6	8	16
C7	6	4

involving one or more vertebral levels. The commonest vertebra involved was C5 (9; 9.9%) followed by C4 and C6 each involving 8(8.8%) patients (Table 2). Epidural component was seen in only 2(2.2%) cases, however no significant nerve root or spinal cord compression was noted even in these cases.

Diffuse marrow signal change in vertebrae was noted in 5 (5.5 %) patients, 10 (11.0 %) patients had nonspecific signal changes in the cervical cord. Hemangioma was noted as an incidental finding in 8(8.8%) patients and 15 (16.5 %) patients had syrinx in their cervical cord. (Table 1)

DISCUSSION

The etiology of neck pain is discussed at some study in two broad heading: degenerative and traumatic. Traumatic causes include those with gross trauma and those with ligamentous injury associated with whiplash injury. There is no consensus statement regarding the usefulness of MRI in degenerative and ligamentous injury.^{3,4} However, MRI is useful in patients with other

Table 3: Variation of Various Pathologies according to Sex

	Males (n=60)	Females (n=31)	p-value
Traumatic lesion	20(33.3)	4(12.9)	$\chi^2=4.39$; $p=0.04$ OR-2.58 (1.0 -6.9)
Neoplastic Lesion	12(20.0)	4(12.9)	$\chi^2=0.71$ $p=0.40$
Syrinx	10(16.7)	5(16.1)	$\chi^2=0.04$; $p=0.95$
Infection	4(6.7)	9(29.0)	$\chi^2=8.4$; $p=0.004$ OR-1.31 (CI-1.04-1.66)
Non Specific High signal in cervical spinal cord	6(10.0)	4(12.9)	$\chi^2=0.72$; $p=0.39$
Hemangioma of vertebra	5(8.3)	3(9.7)	$\chi^2=0.05$; $p=0.83$
Diffuse marrow signal change in vertebra	3(5.2)	2(6.5)	$\chi^2=0.083$; $p=0.77$

abnormalities, including disk herniations, canal encroachment by osteophytes, tumor or infection, fractures, and posttraumatic ligament ruptures of the lower cervical column.²

Traumatic lesions were the most common non degenerative cause of neck pain. Neck pain is associated with traumatic lesions due to accelerated degeneration secondary to post traumatic malalignment.² Males were more likely to have traumatic lesions as compared to females as a cause of neck pain and radiculopathy. The reason behind this might be males being involved in more physical and strenuous activities than females.

There was equal prevalence of vertebral neoplastic and nerve sheath tumor in our study while spinal cord tumor was rare. The result might be because of the selection of sample in which only patients with neck pain and /or radiculopathy. The incidence also reflect the rare nature of the intramedullary tumors.⁵ Hemangioma was seen in 8(6.6%) patients. Hemangiomas are usually discovered as an incidental finding on MRI in up to 10% of cases however aggressive hemangioma with destruction, pain and even cord compression has been reported.⁵ Not any of the hemangioma seen on MRI showed destructive features in our study. So, attribution of neck pain to hemangioma may not be justified and hemangiomas may just represent an incidental finding.

Infective spondylodiscitis was a radiological diagnosis in our study defined as involvement of the intervertebral disc and adjacent vertebral body. MRI is the best imaging tool for evaluation of spondylodiscitis due to its excellent soft tissue and marrow change depiction. MRI aids in diagnosis, identifying the cause of infection and also help to differentiate between pyogenic and tubercular infection to some extent.⁶ Cervical spondylodiscitis

was uncommon conditions and the fourth in the list as the cause of non-degenerative cervical pain and radiculopathy.^{7,8} Considering both degenerative and non degenerative cases in our study, cervical spondylodiscitis accounted for only (13/721) 1.8% cases which showed it as uncommon cause of cervical pain.

We encountered diffuse marrow signal change in 5 (4.13%) patients. Diffuse marrow signal intensity change is a result of replacement of marrow fat by cellular tissue or edema. Differential diagnosis of diffuse marrow signal change can be benign processes like hematopoietic marrow hyperplasia and hemosiderin deposition, inflammatory conditions like sarcoidosis, gout or spondyloarthropathy due to extensive involvement of bone and malignant conditions like hematopoietic malignancy and metastasis.⁹ We did not follow up the patient till final diagnosis so the cause of these diffuses marrow signal change is unclear in our study.

Diffuse spinal cord signal change was also noted in 9% patients. These patients did not have any

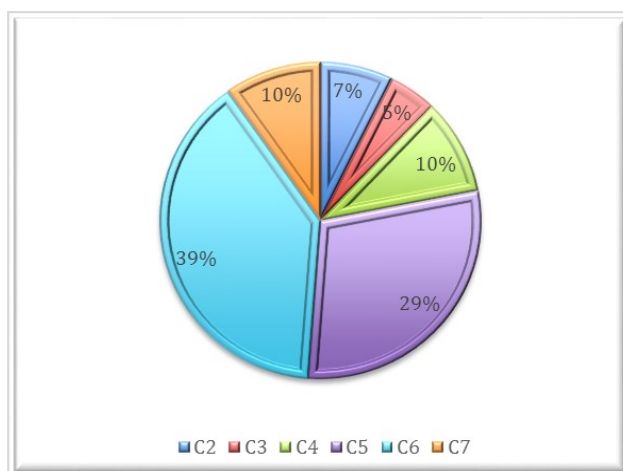


Fig 1: Level of involvement of traumatic lesions in cervical spine

findings to suggest compression by spondylotic changes, fractures or any other cause and nor did the signal abnormality had the characteristics of a tumor. The cause of non compressive myelopathy can be varied ranging from infectious transverse myelitis, parainfective acute demyelinating disseminated encephalomyelitis (ADEM), vascular causes like anterior or posterior spinal artery syndrome, toxic, degenerative, metabolic and paraneoplastic.^{10,11,12}

We had many limitations in our study. The patients were not followed up for the final diagnosis especially in cases of neoplastic lesions, marrow signal change and non-compressive myelopathy. The treatment used and resolution or persistence of pain was not taken into account in our study.

CONCLUSION

Non-degenerative causes of neck pain were less common but important cause of neck pain and radiculopathy. Traumatic lesions were the common cause of neck pain. Some atypical lesions like non-specific signal change in cord and syrinx were seen in our study. Hemangioma is seen as an incidental finding.

Considering the limitations in the study, a prospective cohort study with short and long-term follow up is suggested for further elaboration of these problems in general population.

REFERENCES

1. Hashemi H, Firouznia K, Soroush H, Orang JA, Foghani A, Pakravan M. MRI findings of cervical spine lesions among symptomatic patient and their risk factors. *Iran J Radiol.* 2003;1(3):133-6.
2. Daffner RH. Radiologic evaluation of chronic neck pain. *American family physician.* 2010;82(8):959-64. PMID:20949890.
3. Siivola S, Levoska S, Tervonen O, Ilkko E, Vanharanta H, Keinänen-Kiukaanniemi S. MRI changes of cervical spine in asymptomatic and symptomatic young adults. *Eur Spine J.* 2002;11(4):358-63. DOI:10.1007/s00586-001-0370-x; PMID:12193998; PMCID:PMC3610480.
4. Vetti N, Kråkenes J, Eide GE, Rørvik J, Gilhus NE, Espeland A. MRI of the alar and transverse ligaments in whiplash-associated disorders (WAD) grades 1–2: high-signal changes by age, gender, event and time since trauma. *Neuroradiology.* 2009;51(4):227-35. DOI:10.1007/s00234-008-0482-7; PMID:19083212.
5. Garg A. Imaging of Spinal Neoplasms. In: Khandelwal N, Chowdhury V, Gupta AK, editors. *Diagnostic Radiology Neuroradiology Including Head and Neck Imaging.* 3rd ed. New Delhi: Jaypee Brothers Medical Publishers (P) Ltd. p. 571-86.
6. Gouliouris T, Aliyu SH, Brown NM. Spondylodiscitis: update on diagnosis and management. *Journal of Antimicrobial Chemotherapy.* 2010;65(suppl 3):iii11-iii24. DOI:10.1093/jac/dkq303; PMID:20876624.

7. Ruiz A, Post JD, Ganz WI. Inflammatory and infectious processes of the cervical spine. *Neuroimaging clinics of North America.* 1995;5(3):401-25. PMID:7551577.
8. Shousha M, Heyde C, Boehm H. Cervical spondylodiscitis: change in clinical picture and operative management during the last two decades: a series of 50 patients and review of literature. *Eur Spine J.* 2015;24(3):571-6. DOI:10.1007/s00586-014-3672-5; PMID:25432097.
9. Hanrahan CJ, Shah LM. MRI of Spinal Bone Marrow: Part 2, T1-Weighted Imaging-Based Differential Diagnosis. *American Journal of Roentgenology.* 2011;197(6):1309-21. DOI:10.2214/AJR.11.7420; PMID:22109284.
10. Granados Sanchez AM, Garcia Posada LM, Ortega Toscano CA, Lopez Lopez A. Diagnostic approach to myelopathies. *Rev Colomb Radiol.* 2011;22(3):1-21.
11. Edwards Ii CC, Riew KD, Anderson PA, Hilibrand AS, Vaccaro AF. Cervical myelopathy: current diagnostic and treatment strategies. *The Spine Journal.* 2003;3(1):68-81. DOI:10.1016/S1529-9430(02)00566-1.
12. Seidenwurm DJ. Myelopathy. *American Journal of Neuroradiology.* 2008;29(5):1032-4. PMID:18477657.