

Anterior Cruciate Ligament Reconstruction with LARS Artificial Ligament—Clinical Results after a Long-Term Follow-Up

Paolo Domenico Parchi¹ Gianluca Ciapini¹ Carlo Pagliarlunga¹ Michele Giuntoli¹ Carmine Picece¹
Fabio Chiellini¹ Michele Lisanti¹ Michelangelo Scaglione¹

¹ 1st Orthopedic Division of Pisa University, Department of Translational Research and New Technologies in Medicine and Surgery, University of Pisa, Pisa, Italy

Address for correspondence Paolo Parchi, MD, PhD, 1st Orthopedic Division of Pisa University, Department of Translational Research and New Technologies in Medicine and Surgery, University of Pisa, via Paradisa 2, Pisa 56100, Italy (e-mail: paolo.parchi@unipi.it).

Joints

Abstract

Purpose The aim of this retrospective study was to evaluate the subjective and functional outcome of anterior cruciate ligament (ACL) reconstruction with the synthetic Ligament Advanced Reinforcement System (LARS) ligament.

Methods Twenty-six patients were reviewed at an average follow-up of 11.6 years. Objective clinical evaluation was performed with stability tests. Patient-reported outcomes (Visual Analogue Scale, Knee Injury and Osteoarthritis Outcome Score, and Cincinnati Knee Rating Scale) were used to assess subjective and functional outcomes.

Results Overall satisfactory results were obtained in 22 cases (84.6%). Four patients (15.4%) showed mechanical failure of the graft. No cases of synovitis or infection were reported.

Conclusion LARS ligament can be considered a safe and suitable option for ACL reconstruction in carefully selected cases, especially elderly patients needing a rapid postoperative recovery.

Level of Evidence Level IV, retrospective case series.

Keywords

- ▶ anterior cruciate ligament
- ▶ reconstruction
- ▶ ligament reinforcement
- ▶ artificial ligament
- ▶ LARS ligament

Introduction

Four-strand hamstring tendons or bone-patellar tendon-bone are the most commonly used autograft and actually represent the gold standard for the anterior cruciate ligament (ACL) reconstruction.^{1,2} The main complications reported with the use of tendon autografts are related to graft harvesting and donor site morbidity.³

Synthetic grafts have been proposed to overcome the problems related to the use of autografts. The first attempt to use an artificial ligament for ACL reconstruction was made in 1918 by Smith, who proposed a graft made up of multiple silk sutures fastened with staples.⁴ Unfortunately, the procedure was unsuccessful with a complete graft failure within the first 3 months from the implantation.

Between 1970s and 1980s, there was a progressive new interest in the use of artificial ligaments, supported by the development of new materials and new devices such as Teflon, carbon fibers, Gore-Tex, Dacron, and subsequently Leeds-Keio and Kennedy-ligament augmentation device (LAD). During the years, these materials have all been abandoned due to the high rate of complications related with their use, like reactive synovitis and graft breakage in short or medium term, and in the 1990s the use of synthetic grafts was completely abandoned.^{5–8}

In the last years of 1990s, a new generation of synthetic graft for ligament reconstruction has been proposed, with the introduction of the Ligament Advanced Reinforcement System (LARS; LARS Company, Arc sur Tille, France). Despite being introduced in the market since several years ago, it is

received
August 21, 2017
accepted after revision
April 8, 2018

DOI <https://doi.org/10.1055/s-0038-1653950>.
ISSN 2282-4324.

Copyright © Georg Thieme Verlag KG
Stuttgart · New York

License terms



not widely used yet.⁹ This is probably due to the small number of long-term studies and the negative previous experiences with the last generation of synthetic ligaments.

The aim of this study was to evaluate the safety and the efficacy of ACL reconstruction with the LARS ligament at long-term follow-up. The hypothesis of the study was that ACL reconstruction with the LARS artificial ligament is a safe and effective procedure.

Methods

Participants

This study was designed as a retrospective analysis of patients who have undergone primary, isolated ACL reconstruction using the LARS ligament in a single institution between 2003 and 2005. The study was authorized by the internal revision board and was performed in accordance with the ethical standards of the 1964 Declaration of Helsinki as revised in 2000.

The use of a synthetic graft for the ACL reconstruction was proposed to all patients older than 30 years with a symptomatic isolated ACL injury that required a quick return to their previous sport activity level as a possible alternative to the autograft. All patients were clearly informed about the advantages and the possible complications related to the use of a synthetic graft.

All patients gave informed consent before being included into the study.

Interventions

All the procedures were performed under regional anesthesia by the same surgeon. In all cases, the ACL reconstruction was performed with an arthroscopically assisted technique. Two types of LARS ligament were used: the AC50DB with a strength of 2,300 Newton and a diameter of 5 mm and the AC40DB with a strength of 1,700 Newton and a diameter of 4 mm. The choice between these two types of LARS was related mainly to the patients' weight (we used the AC50DB for patients weighing more than 80 kg).

The LARS ligament was placed into the native femoral and tibial ACL footprint. The tibial tunnel was created using a cannulated reamer matching the diameter of the graft (7.5 mm for the AC40DB and 8 mm for the AC50DB). The tibial guide was angled at 55° to the tibial plateau. The femoral reamer was, then, introduced through the tibial tunnel at 90° of knee flexion, and the half femoral tunnel was reamed under arthroscopic control reaching a depth of 35 to 40 mm. The doubled LARS ligament was then introduced and fixed to the femur using a suspensory crosspin fixation device (Transfix; Arthrex, Naples, Florida, United States) and to the tibia using a metal interference screw.

Postoperative rehabilitation started from the first postoperative day by performing active and passive knee range of motion (ROM) exercises. Patients were discharged on the second postoperative day and partial weight-bearing on the operated limb was allowed for 2 weeks. After that period, patients were progressively allowed to increase the weight-bearing reaching the full weight-bearing 4 weeks after surgery.

Outcome Measures

All the patients were clinically evaluated for pain, swelling, stability, and ROM. Knee stability was tested using the Rolimeter knee tester (Aircast; DJO Global, Vista, California, United States)¹⁰ for the anterior drawer test and the Lachman test. Both tests were performed three times on both knees and the average side-to-side (SSD) difference at maximal manual traction was recorded. Instrumental evaluation of anterior knee stability was scored as excellent (SSD < 2 mm), good (SSD = 2–4 mm), or poor (SSD > 4 mm).

Subjective and functional evaluation was based on three patient-reported outcomes (PROs): the Visual Analogue Scale (VAS), the Knee Injury and Osteoarthritis Outcome Score (KOOS), and the Cincinnati knee rating scales.

The VAS is used to quantify the pain perceived by the patient on the affected limb.

The KOOS is a PRO measurement instrument, developed to assess the patients' opinion about their knee and associated problems. The KOOS evaluates both short-term and long-term consequences of knee injury including ACL ligament injuries. It holds 42 items in 5 separately scored subscales: pain, symptoms, function in daily living (KOOS-ADL), function in sport and recreation (KOOS-Sport/Rec), and knee-related quality of life (KOOS-QOL).¹¹

The Cincinnati knee rating scales evaluates eight subjective parameters (pain, swelling, giving way, overall activity level, walking, stairs, running, jumping, or twisting) to assess the patient's functional recovery.¹²

Results

From January 2003 to December 2005, we performed 29 ACL reconstructions using the LARS ligament. The mean age of patients was 38.5 years (range, 32–52 years). Gender distribution was 20 males and 6 females. Average time between injury and surgery was 2 months (range, 1–5 months). All patients returned to sports activities after an average of 4 months (range, 1.5–7 months).

Three patients were lost at the follow-up, but we were unable to establish the reasons for their loss, because we could not contact them. The remaining 26 patients were examined at an average follow-up of 139.3 months (range, 129–154 months).

We recorded four cases of mechanical graft failure that occurred after a new sports injury. In one case, it occurred after 4 years from the implantation and in three cases over 10 years after surgery (→ Fig. 1). All the cases of LARS failure were documented by a magnetic resonance imaging (MRI) evaluation. Only two cases required a surgical revision for a persistent knee instability. The torn graft was removed arthroscopically and replaced with a new LARS ligament using the same surgical technique. In the other two cases, the MRI showed graft breakage, but the patients did not suffer from knee instability.

Clinical assessment did not reveal signs of graft-related problems like knee reactive synovitis. Absence of reactive knee synovitis was also confirmed by MRI evaluations that were available at follow-up in 15 patients.

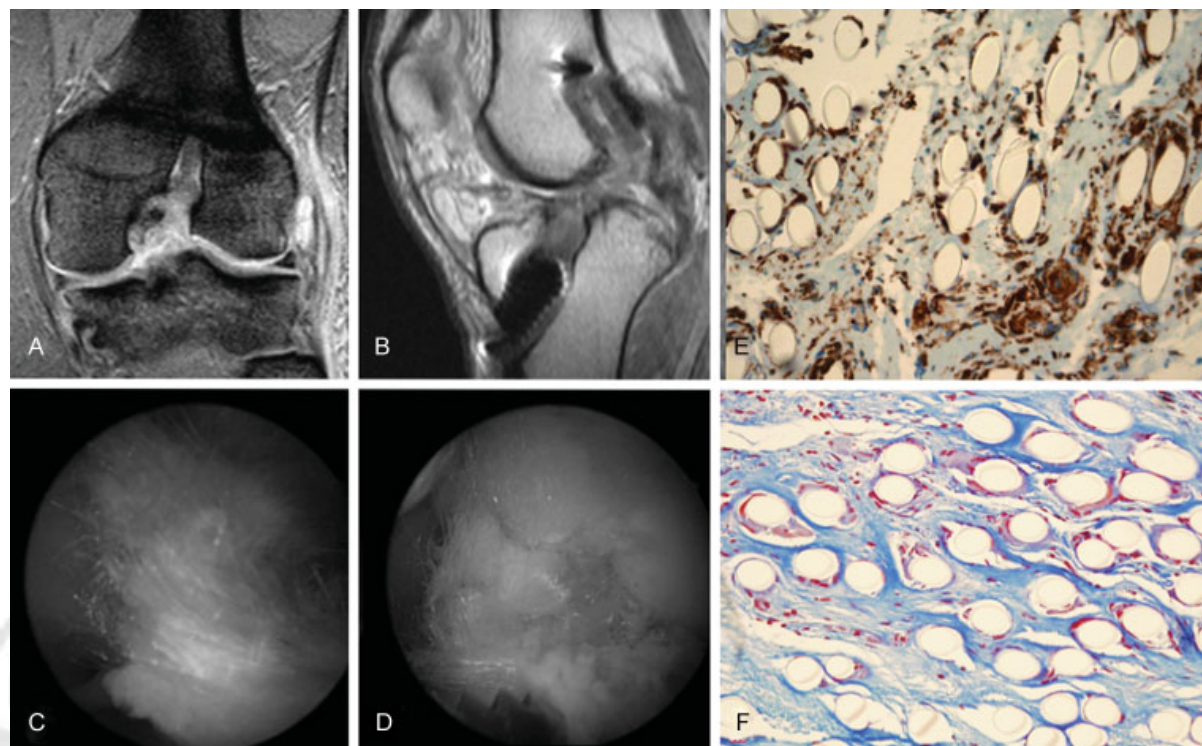


Fig. 1 Mechanical graft failure occurred at 4 years in a 38-year-old man during sport activity (soccer). (A, B) Magnetic resonance imaging (MRI) evaluation showed Ligament Advanced Reinforcement System (LARS) rupture without signs of knee synovitis. (C, D) Intraoperative findings. (E) Immunostaining with anti-vimentin antibody that shows connective tissue, fibroblastic cells, and multinucleated giant cells around the polyethylene terephthalate (PET) fibers. (F) Masson's trichrome stain that shows connective tissue, fibroblastic cells, and multinucleated giant cells around the PET fibers.

ROM of the treated knee did not differ from the contralateral one in 15 patients (57.7%). Loss of knee flexion of less than 10° was observed in 7 patients (26.9%) and between 10° and 15° in 4 patients (15.4%).

Instrumented analysis of anterior knee laxity with the Rolimeter knee tester showed an excellent result (SSD < 2 mm) in 15 patients (57.7%), good (SSD = 2–4 mm) in 7 cases (26.9%), and poor (SSD > 4 mm) in 4 cases (15.4%).

The mean VAS was 1.69. Score distribution was 0 to 2 points in 17 patients (65.4%), 3 to 5 points in 6 patients (23.1%), and 6 to 8 points in 3 patients (11.5%).

Global mean KOOS was 80 with 13 (50%) excellent results, 9 good results (34.6%), and 4 poor result (15.4%) (► **Table 1**).

Functional evaluation with the Cincinnati knee rating scale showed a mean score of 84.5 points (range, 53–100 points) with 15 excellent results (57.7%), 7 good results (26.9%), and 4 poor results (15.4%).

Discussion

Artificial substitutes of ACL gained popularity in the 1970s and 1980s, but the high failure rate (reactive synovitis and mechanical breakdown) led to a complete stop in their use in the 1990s.¹³ During the past 15 years, the development of biocompatible materials and a better understanding of the knee kinematics led to the development of a new generation of synthetic grafts.⁹

The LARS ligament consists of fibers made of polyethylene terephthalate (PET) composed of two parts: an intraosseous segment composed of longitudinal fibers bound together by a transverse knitted structure and an intra-articular segment composed of parallel longitudinal free fibers twisted at 90°. The PET fibers of the intra-articular segment are designed to encourage tissue ingrowth due to the porosity of the material, allowing ingrowth from the surrounding bony tunnels as shown from in vitro studies.¹⁴

Table 1 KOOS results

	Mean value (range)	Excellent > 90 N (%)	Good 70–89 N (%)	Poor < 69 N (%)
Symptoms	83 (35–100)	14 (53.8)	8 (30.8)	4 (15.4)
Pain	89 (66–100)	16 (61.5)	8 (30.8)	2 (7.7)
Function daily living	83 (59–100)	16 (61.5)	6 (23.1)	4 (15.4)
Sport/recreation function	82 (45–100)	13 (50)	7 (26.9)	6 (23.1)
Quality of life	77 (18–100)	10 (38.4)	8 (30.8)	8 (30.8)
Global	80 (53–100)	13 (50)	9 (34.6)	4 (15.4)

Abbreviation: KOOS, Knee Injury and Osteoarthritis Outcome Score.

The first clinical report on the use of LARS in ACL reconstruction was made by Dericks in 1995.¹⁵ He reported encouraging results in 220 cases with a mean follow-up of 2.5 years, with no cases of knee synovitis.

In a previous work published in 2013, we made a literature review of all the papers that reported clinical results of the LARS ligament for knee ligament reconstruction, searching in four different databases (Pubmed, Scopus, Embase, and Google Scholar).⁹ We found 35 papers for a total number of 1,245 cases with a follow-up ranging from 3 months to 9 years. We focused our attention on the number of graft ruptures and the number of cases of knee synovitis that were complications historically related to the use of artificial ligaments. We recorded 12 graft ruptures (0.96%) and only 3 cases of knee synovitis (0.24%).⁹

These data are confirmed by the results of this study and by two recent systematic reviews.^{16,17} Anderson et al¹⁶ reported comparable outcomes between the use of LARS ligament and the use of autografts after a medium-term follow-up. Batty et al¹⁷ compared the LARS ligament and others artificial ligaments (Leeds-Keio, Kennedy-LAD, Dacron, Gore-Tex, and Trevira) in terms of complications and clinical results. The authors reported the lowest cumulative rates of failure with the LARS device (2.6% for ACL and 1% for posterior cruciate ligament surgery). Rates of noninfective synovitis and effusion ranged from 0.2% for LARS to 27.6% for Gore-Tex. Revision rates ranged from 2.6% for LARS to 11.8% for Trevira.

Although the LARS ligament has been used for ACL reconstruction since the late 1990s, there are very few studies that analyzed the long-term results and sometimes the reported data are discordant.¹⁸⁻²¹ Cerulli et al¹⁸ reported the results obtained with the use of LARS ligament in ACL reconstruction in a group of 25 patients after 9 years of follow-up. The authors reported satisfactory results in over 95% of the cases with no cases of knee synovitis. Jia et al¹⁹ reported the results of 91 patients at 7-year follow-up. They reported a failure rate of 4.4%, and an overall complication rate of 2.2% with 86.6% of the patients returning to their sports activities. Wang et al²⁰ reported on 26 cases of ACL reconstruction with LARS after a mean follow-up of 11.9 years. The authors reported a complication rate of 28.6% with two cases of knee synovitis. In this cases series, one of the highlighted causes of graft failure was the loosening of the fixation system. Tiefenboeck et al²¹ reported a low rate of patient satisfaction (55.6%) and a high rate of complications (56%) after a minimum follow-up of 10 years. Complications consisted of graft breakage during sport activity in 3 cases, surgical site infection in 3 cases, and residual knee instability in 4 cases. The authors did not report cases of knee reactive synovitis.

Differences between this study and that by Tiefenboeck et al²¹ might be related to the method of graft fixation method. As reported by Viateau et al,²² the LARS ligament has a very poor capacity of osteointegration in the bone tunnels. For this reason, fixation should not be achieved with absorbable devices.

To overcome the problem of the LARS ligament's osteointegration, several authors worked in the last years to enhance the biologic fixation of the graft using nanotechnologies.²³⁻²⁶

Another important way to reduce the risk of long-term failure and debris formation that can led to reactive knee synovitis is to preserve the ACL stumps, as suggested by Trieb et al.¹⁴ Preservation of the torn ligament reduces the friction stress on the LARS fibers at the level of the bone tunnels and between the fibers themselves and promotes fibroblast ingrowth.

This study has some limitations, mainly related to its retrospective design. Moreover, the sample size is small and all the patients were enrolled at the same hospital and operated by the same surgeon. Finally, no baseline outcome measures were available and therefore no data analysis on improvement of baseline conditions was possible.

In conclusion, even if the long-term results of the use of LARS are encouraging, the use of autologous grafts remain the gold standard in ACL reconstruction, especially in young people. LARS ligament can be considered a suitable option for ACL reconstruction in carefully selected cases, especially for older patients needing a fast functional recovery.

References

- Budny J, Fox J, Rauh M, Fineberg M. Emerging trends in anterior cruciate ligament reconstruction. *J Knee Surg* 2017;30(01):63-69
- Kim HS, Seon JK, Jo AR. Current trends in anterior cruciate ligament reconstruction. *Knee Surg Relat Res* 2013;25(04):165-173
- Samuelsson K, Andersson D, Karlsson J. Treatment of anterior cruciate ligament injuries with special reference to graft type and surgical technique: an assessment of randomized controlled trials. *Arthroscopy* 2009;25(10):1139-1174
- Smith SA. The diagnosis and treatment of injuries to the crucial ligaments. *Br J Surg* 1918;6(22):176-189
- Bolton CW, Bruchman WC. The GORE-TEX expanded polytetrafluoroethylene prosthetic ligament. An in vitro and in vivo evaluation. *Clin Orthop Relat Res* 1985;(196):202-213
- Richmond JC, Manseau CJ, Patz R, McConville O. Anterior cruciate reconstruction using a Dacron ligament prosthesis. A long-term study. *Am J Sports Med* 1992;20(01):24-28
- Rading J, Peterson L. Clinical experience with the Leeds-Keio artificial ligament in anterior cruciate ligament reconstruction. A prospective two-year follow-up study. *Am J Sports Med* 1995;23(03):316-319
- Fujikawa K, Iseki F, Seedhom BB. Arthroscopy after anterior cruciate reconstruction with the Leeds-Keio ligament. *J Bone Joint Surg Br* 1989;71(04):566-570
- Parchi PD, Gianluca C, Dolfi L, et al. Anterior cruciate ligament reconstruction with LARS™ artificial ligament results at a mean follow-up of eight years. *Int Orthop* 2013;37(08):1567-1574
- Schuster AJ, McNicholas MJ, Wachtl SW, McGurty DW, Jakob RP. A new mechanical testing device for measuring anteroposterior knee laxity. *Am J Sports Med* 2004;32(07):1731-1735
- Collins NJ, Misra D, Felson DT, Crossley KM, Roos EM. Measures of knee function: International Knee Documentation Committee (IKDC) Subjective Knee Evaluation Form, Knee Injury and Osteoarthritis Outcome Score (KOOS), Knee Injury and Osteoarthritis Outcome Score Physical Function Short Form (KOOS-PS), Knee Outcome Survey Activities of Daily Living Scale (KOS-ADL), Lysholm Knee Scoring Scale, Oxford Knee Score (OKS), Western Ontario and McMaster Universities Osteoarthritis Index (WOMAC), Activity Rating Scale (ARS), and Tegner Activity Score (TAS). *Arthritis Care Res (Hoboken)* 2011;63(Suppl 11):S208-S228
- Barber-Westin SD, Noyes FR, McCloskey JW. Rigorous statistical reliability, validity, and responsiveness testing of the Cincinnati knee rating system in 350 subjects with uninjured, injured, or anterior cruciate ligament-reconstructed knees. *Am J Sports Med* 1999;27(04):402-416

- 13 Savarese A, Lunghi E, Budassi P, Agosti A. Remarks on the complications following ACL reconstruction using synthetic ligaments. *Ital J Orthop Traumatol* 1993;19(01):79–86
- 14 Trieb K, Blahovec H, Brand G, Sabeti M, Dominkus M, Kotz R. In vivo and in vitro cellular ingrowth into a new generation of artificial ligaments. *Eur Surg Res* 2004;36(03):148–151
- 15 Dericks G Jr. Ligament advanced reinforcement system anterior cruciate ligament reconstruction. *Oper Tech Sports Med* 1995; 3:187–205
- 16 Anderson MJ, Browning WM III, Urband CE, Kluczynski MA, Bisson LJ. A systematic summary of systematic reviews on the topic of the anterior cruciate ligament. *Orthop J Sports Med* 2016;4(03): 2325967116634074
- 17 Batty LM, Norsworthy CJ, Lash NJ, Wasiak J, Richmond AK, Feller JA. Synthetic devices for reconstructive surgery of the cruciate ligaments: a systematic review. *Arthroscopy* 2015;31 (05):957–968
- 18 Cerulli G, Antinolfi P, Bruè S, et al. Esperienza clinica nell'uti- lizzo di biomateriali nel ginocchio. *GIOT* 2011;37(Suppl 1):159–166
- 19 Jia Z, Xue C, Wang W, Liu T, Huang X, Xu W. Clinical outcomes of anterior cruciate ligament reconstruction using LARS artificial graft with an at least 7-year follow-up. *Medicine (Baltimore)* 2017;96(14):e6568
- 20 Wang C-L, Hsiao C-K, Ku M-C, Chang C-H. Arthroscopic anterior cruciate ligament reconstruction with LARS artificial ligament: an 8–15-year follow-up. *J Mech Med Biol* 2013;13(02): 1350046
- 21 Tiefenboeck TM, Thurmaier E, Tiefenboeck MM, et al. Clinical and functional outcome after anterior cruciate ligament reconstruction using the LARS™ system at a minimum follow-up of 10 years. *Knee* 2015;22(06):565–568
- 22 Viateau V, Manassero M, Anagnostou F, Guérard S, Mitton D, Migonney V. Biological and biomechanical evaluation of the ligament advanced reinforcement system (LARS AC) in a sheep model of anterior cruciate ligament replacement: a 3-month and 12-month study. *Arthroscopy* 2013;29(06):1079–1088
- 23 Li H, Chen S, Wu Y, et al. Enhancement of the osseointegration of a polyethylene terephthalate artificial ligament graft in a bone tunnel using 58S bioglass. *Int Orthop* 2012;36(01):191–197
- 24 Li H, Ge Y, Wu Y, et al. Hydroxyapatite coating enhances polyethylene terephthalate artificial ligament graft osseointegration in the bone tunnel. *Int Orthop* 2011;35(10):1561–1567
- 25 Cho S, Li H, Chen C, Jiang J, Tao H, Chen S. Cationised gelatin and hyaluronic acid coating enhances polyethylene terephthalate artificial ligament graft osseointegration in porcine bone tunnels. *Int Orthop* 2013;37(03):507–513
- 26 Antonini S, Meucci S, Parchi P, et al. Human mesenchymal stromal cell-enhanced osteogenic differentiation by contact interaction with polyethylene terephthalate nanogratings. *Biomed Mater* 2016;11(04):045003



THIEME