

# UNIVERSITY OF BIRMINGHAM

University of Birmingham  
Research at Birmingham

## Mitigating respiratory motion in radiotherapy: rapid, shallow, non-invasive mechanical ventilation for internal thoracic targets

West, Nicholas S.; Parkes, Michael J.; Snowden, Christopher; Prentis, James; Mckenna, Jill; Iqbal, Muhammad Shahid; Walker, Christopher

DOI:

[10.1016/j.ijrobp.2018.11.040](https://doi.org/10.1016/j.ijrobp.2018.11.040)

### Document Version

Peer reviewed version

### Citation for published version (Harvard):

West, NS, Parkes, MJ, Snowden, C, Prentis, J, Mckenna, J, Iqbal, MS & Walker, C 2018, 'Mitigating respiratory motion in radiotherapy: rapid, shallow, non-invasive mechanical ventilation for internal thoracic targets', *International Journal of Radiation: Oncology - Biology - Physics*. <https://doi.org/10.1016/j.ijrobp.2018.11.040>

[Link to publication on Research at Birmingham portal](#)

### General rights

Unless a licence is specified above, all rights (including copyright and moral rights) in this document are retained by the authors and/or the copyright holders. The express permission of the copyright holder must be obtained for any use of this material other than for purposes permitted by law.

- Users may freely distribute the URL that is used to identify this publication.
- Users may download and/or print one copy of the publication from the University of Birmingham research portal for the purpose of private study or non-commercial research.
- User may use extracts from the document in line with the concept of 'fair dealing' under the Copyright, Designs and Patents Act 1988 (?)
- Users may not further distribute the material nor use it for the purposes of commercial gain.

Where a licence is displayed above, please note the terms and conditions of the licence govern your use of this document.


When citing, please reference the published version.

### Take down policy

While the University of Birmingham exercises care and attention in making items available there are rare occasions when an item has been uploaded in error or has been deemed to be commercially or otherwise sensitive.

If you believe that this is the case for this document, please contact [UBIRA@lists.bham.ac.uk](mailto:UBIRA@lists.bham.ac.uk) providing details and we will remove access to the work immediately and investigate.

# Accepted Manuscript



Mitigating respiratory motion in radiotherapy: rapid, shallow, non-invasive mechanical ventilation for internal thoracic targets

Nicholas S. West, MSc, Michael J. Parkes, PhD, Christopher Snowden, MD, James Prentis, MBBS, Jill McKenna, DCR(R), Muhammad Shahid Iqbal, FRCR, Christopher Walker, BSc

PII: S0360-3016(18)34026-4

DOI: <https://doi.org/10.1016/j.ijrobp.2018.11.040>

Reference: ROB 25412

To appear in: *International Journal of Radiation Oncology • Biology • Physics*

Received Date: 20 September 2018

Revised Date: 6 November 2018

Accepted Date: 19 November 2018

Please cite this article as: West NS, Parkes MJ, Snowden C, Prentis J, McKenna J, Iqbal MS, Walker C, Mitigating respiratory motion in radiotherapy: rapid, shallow, non-invasive mechanical ventilation for internal thoracic targets, *International Journal of Radiation Oncology • Biology • Physics* (2018), doi: <https://doi.org/10.1016/j.ijrobp.2018.11.040>.

This is a PDF file of an unedited manuscript that has been accepted for publication. As a service to our customers we are providing this early version of the manuscript. The manuscript will undergo copyediting, typesetting, and review of the resulting proof before it is published in its final form. Please note that during the production process errors may be discovered which could affect the content, and all legal disclaimers that apply to the journal pertain.

## Title

Mitigating respiratory motion in radiotherapy: rapid, shallow, non-invasive mechanical ventilation for internal thoracic targets

## Short title

Rapid, shallow, non-invasive mechanical ventilation for radiotherapy

## Authors

Nicholas S West, MSc,\* Michael J. Parkes, PhD,†, Christopher Snowden, MD,‡ James Prentis, MBBS,‡ Jill McKenna, DCR(R),§ Muhammad Shahid Iqbal, FRCR,‡ Christopher Walker, BSc,\*

## Affiliations

\*Department of Radiotherapy Physics, Northern Centre for Cancer Care, The Newcastle upon Tyne Hospitals NHS Foundation Trust, Newcastle upon Tyne, UK

† School of Sport and Exercise Sciences, University of Birmingham, Birmingham, UK

‡ Departments of Perioperative and Critical Care Medicine, Freeman Hospital, The Newcastle upon Tyne Hospitals NHS Foundation Trust, Newcastle upon Tyne, UK

§ Department of Therapeutic Radiography, Northern Centre for Cancer Care, The Newcastle upon Tyne Hospitals NHS Foundation Trust, Newcastle upon Tyne, UK

‡ Department of Clinical Oncology, Northern Centre for Cancer Care, The Newcastle upon Tyne Hospitals NHS Foundation Trust, Newcastle upon Tyne, UK

## Corresponding author

Nicholas West, Northern Centre for Cancer Care, Freeman Hospital, Newcastle upon Tyne, United Kingdom, NE7 7DN (telephone: +44 191 2448743; email: [nick.west@nuth.nhs.uk](mailto:nick.west@nuth.nhs.uk))

## Author responsible for statistical analysis

Nicholas West, Northern Centre for Cancer Care, Freeman Hospital, Newcastle upon Tyne, United Kingdom, NE7 7DN (telephone: +44 191 2448743; email: [nick.west@nuth.nhs.uk](mailto:nick.west@nuth.nhs.uk))

## Conflict of interest

None declared for all authors

## Acknowledgments

To Hamilton Medical AG (Bonaduz, Switzerland) for the loan of the MR compatible ventilator, the supply of masks and circuits, to Dennis Brown for his continued support and encouragement and to Stephen Hedley for his image processing skills.

## Source of Financial Support / Funding Statement

This work was carried out as part of our day to day research and development duties incorporated in our roles. No external or supplementary financial support or funding was required.

Motion due to normal respiration increases the volume of healthy tissue irradiated during radiotherapy. The authors propose a simple method to reduce the motion associated with respiration by utilising a standard non-invasive ventilator operated at higher frequencies with reduced ventilation volumes. Results from a healthy subject study demonstrate promise in achieving large reductions in respiratory motion around the lower thoracic and upper abdominal regions. This reduction in motion has the potential to increase access to therapeutic regimes of radiotherapy for a patient cohort that has been traditionally poorly served by radiotherapy.

ACCEPTED MANUSCRIPT

**Abstract:**

**Purpose:** Reducing respiratory motion during the delivery of radiotherapy reduces the volume of healthy tissues irradiated and may decrease radiation induced toxicity. The purpose of this study was to assess the potential for rapid shallow non-invasive mechanical ventilation to reduce internal anatomy motion for radiotherapy purposes.

**Material and methods:** Ten healthy volunteers (age 22-54years; mean 38years; 6 female and 4 male) were scanned on an MR scanner during normal breathing and at 2 ventilator induced frequencies; 20 and 25 breaths per minute for 3 minutes. Sagittal and coronal cinematic datasets, centred over the right diaphragm were used to measure internal motions across the lung–diaphragm interface; repeat scans assessed reproducibility. Physiological parameters and participant experiences were recorded to quantify tolerability and comfort.

**Results:** Physiological observations and experience questionnaires demonstrated rapid shallow non-invasive ventilation technique was tolerable and comfortable. Motion analysis of the lung-diaphragm interface demonstrated respiratory amplitudes and variations reduced in all subjects using rapid shallow non-invasive ventilation compared to spontaneous breathing; mean amplitude reductions of 56% and 62%, for 20 and 25 breaths per minute respectively. The largest mean amplitude reductions were found in the posterior of the right lung; 40.0mm during normal breathing to 15.5mm ( $p<0.005$ ) and 15.2mm ( $p<0.005$ ) when ventilated with 20 and 25 breaths per minute respectively. Motion variations also reduced with ventilation; standard deviations in the posterior lung reduced from 14.8mm during normal respiration to 4.6mm and 3.5mm at 20 and 25 breaths per minute respectively.

**Conclusion:** To our knowledge, this is the first study to measure internal anatomical motion using rapid shallow mechanical ventilation to regularise and minimise respiratory motion, over a period long enough to image and deliver radiotherapy. Rapid frequency, shallow, non-invasive ventilation generates large reductions in internal thoracic and abdominal motions, the clinical application of which could be profound; enabling dose escalation (increasing treatment efficacy) or high dose ablative radiotherapy.

## Introduction

A major limitation in radiotherapy is that patients continue to breathe during treatment delivery. This respiratory related motion affects all organs in the thorax and abdomen, from oesophagus to prostate, constraining access to hypofractionated treatment and the efficacy of the treatment [1]. A number of strategies are used to mitigate respiratory motion; doing nothing other than increasing treatment margins, treatment gating, abdominal compression and multiple short (~20 second) breath-holds [2] [2] or single prolonged (>5 minute) breath-holds [3]. All approaches have associated technological challenges and limitations, prolonging the length of treatment and risking missing the target unless some form of target tracking is implemented. At present there is no consensus on how to best manage or compensate for respiratory motion [4].

This study explores the potential of a completely different approach. Here, non-invasive mechanical ventilation safely, easily and comfortably takes over breathing of the conscious, unmedicated patient, delivering with regularity the same respiratory minute ventilation but with an increased ventilation frequency and a reduced inflation volume for periods sufficient to image and deliver radiotherapy.

The use of non-invasive mechanical ventilation to healthy, unmedicated volunteers has significant potential for controlling breathing patterns during radiotherapy and diagnostic imaging. Although controlled mechanical ventilation is often considered only in an anaesthesiology domain, the development of non-invasive ventilation techniques and the availability of simple, user friendly ventilators have facilitated more widespread adoption of such techniques.

Previous studies have demonstrated that it is feasible to, ventilate conscious, unmedicated subjects and breast cancer patients non-invasively for up to one hour [3][5][6][7] and to reduce breathing-related positional variability of a surface marker [8]. However, a reduction in internal respiratory motion has not yet been investigated. The objective of this study was to demonstrate whether non-invasive ventilation was acceptable to awake volunteers during MRI scanning and whether reduced internal organ motion.

To our knowledge, this is the first study to evaluate internal anatomical motion using rapid shallow non-invasive ventilation to regularise and minimise respiratory variations over a period long enough to image and to deliver complex high dose radiotherapy.

### Subjects

Ten healthy volunteer subjects (age range 22-54 years; mean 38 years; 6 female and 4 male) were recruited to be part of the study at our cancer centre. This work was carried out under a development protocol approved by the Trust. As an innovative pilot study to investigate tolerability and potential respiratory motion reduction, no data exists on expected results, therefore this study could not use formal sample size calculations based on standard deviations to inform the number of participants required.

### *Rapid shallow non-invasive ventilation*

Without any previous ventilator or MRI training or experience, on the day of the experiment each subject was allowed sufficient time (~5 minutes) to become comfortable breathing spontaneously via a facemask and connected to an MR compatible non-invasive ventilator (MR1 Hamilton Medical AG, Bonaduz, Switzerland). Subjects then acclimatised to lying on an MR couch (Siemens Espree, Siemens AG, Erlangen, Germany) whilst breathing spontaneously with the ventilator using air/oxygen mix ( $F_{iO_2} < 0.4$ ). Baseline end tidal partial pressure of carbon dioxide ( $P_{ET}CO_2$ ) levels, non-invasive pulse oximetry and heart rate were measured at the start and monitored throughout, with pre-defined limits set to ensure subject safety during the procedure [7]. The ventilator was then switched to take over their breathing non-invasively with positive pressure, controlling the rate and level of breathing, by causing all the usual and normal cycles of inflation and deflation. Two arbitrary ventilation rates of 20 and 25 breaths per minute were set, whilst simultaneously reducing inflation volume to match or exceed their metabolic rate such that  $P_{ET}CO_2 > 2.7$  kPa,  $sPO_2 > 94\%$  and heartrate  $< 100$  bpm [5][6][7].

Participant experience of the procedure was assessed through a non-validated questionnaire, using 5 questions each scoring between 1 and 5 points; maximum comfort / experience scoring 5 points.

### *MR scanning*

Cinematic datasets, at 3 frames per second, were acquired in sagittal and coronal planes centred over the apex of the right diaphragm. Scans were acquired during normal breathing, in the 2 non-invasive mechanically ventilated frequencies and again in normal breathing after turning off pressure support (Figure 1). We acquired cinematic datasets of diaphragm motion for 6 minutes (3 minutes in the coronal and 3 minutes in the sagittal plane) for all breathing modes. Respiratory amplitudes were estimated using the high contrast region of the lung-diaphragm interface, making measurements over a 30 second period, from seconds 60 to 90 in each scan (Figure 2). The same protocol was then applied during a subsequent appointment, at least 2 weeks after the initial session, to assess the inter-session reproducibility of the technique.

*Tolerability*

All subjects completed the rapid, shallow protocol using mechanical ventilation without interruption and were happy to return to undergo the procedure for a second occasion. There was only 1 occasion out of the 20 sessions that a subject felt “uncomfortable” and was “close to stopping the procedure”. However, results from the questionnaire on average demonstrated very positive results; low levels of anxiety before and during the procedure. There were also no signs of any physiological stresses; all continuous observations of heart rate, end tidal CO<sub>2</sub> (P<sub>ET</sub>CO<sub>2</sub>) and peripheral oxygen saturation (SpO<sub>2</sub>) levels were found to be well inside the pre-determined safety limits.

*Intra-session analysis*

Visual assessment of the right lung-diaphragm interface motion over a 30 second period in both the sagittal and coronal planes demonstrated that mean respiratory amplitudes were systematically reduced in 100% of cases using rapid shallow non-invasive ventilation compared to subject initiated normal respiration. Objective measurements demonstrated that respiratory amplitudes reduced by 54±20% and 61±15%, at 20 and 25 breaths per minute respectively (Figure 3) in the sagittal plane and 58±14% and 62±14% in the coronal plane, at 20 and 25 breaths per minute respectively. Diaphragmatic motion with rapid shallow non-invasive ventilation were evaluated against normal breathing using paired t-tests with statistical significance assigned at  $p < 0.05$ . All amplitude reductions with both rapid shallow modes of mechanical ventilation, at all points in both the sagittal and coronal planes were found to be significant;  $p$  values  $< 0.005$ . Mean respiratory amplitudes and associated standard deviations for the initial normal breathing phase, the mechanically ventilated modes and the return to normal breathing are summarised in Table 1. Respiration was also regularised using mechanical ventilation; maximum interface excursion reducing from 71.5mm during normal breathing to 21.3mm and 20.3mm under rapid shallow ventilatory control at 20 and 25 breaths per minute respectively.

*Inter-session analysis*

The pattern of amplitude and breathing variation reduction with rapid shallow ventilation compared to normal breathing was found to be consistent between MRI sessions; mean respiratory amplitude in the coronal orientation of the lung-diaphragm interface was 9.4±2.5mm at the first session and 10.5±2.6mm at 20 breaths per minute, and 8.0±2.5mm at the first session and 8.6±2.4mm at 25 breaths per minute. Similar regularisation of breathing motions were repeated and demonstrated in the sagittal plane (Figure 4).

*Abdominal motion*

Performing simple image analysis (pixels set to white if grey value  $>$  average, to black if grey value  $<$  average, then superimposing the resultant cinematic images), visibly demonstrates the motion reduction potential to abdominal as well as thoracic anatomy by employing rapid shallow non-invasive ventilation (Figure 5).



**Discussion**

We demonstrate that for healthy subjects rapid shallow non-invasive ventilation is tolerable during MRI and achieves large reductions in mean respiratory amplitudes, regularised breathing patterns (i.e. reduces variability) and was consistent between the first and second sessions for all subjects.

All subjects tolerated the procedure and were happy to return for a repeat ventilation session. On 1 occasion a subject felt uncomfortable and was close to removing the mask, although it was reported that the MR scanning environment had much to do with the discomfort felt. Questionnaire results demonstrated subjects experienced a very low level of anxiety before and during the first ventilation procedure despite subjects having no previous experience of mechanical ventilation and the experiment being performed in an MR scanner, an environment known to induce anxiety, especially in those with claustrophobic tendencies. The enforced breathing patterns and associated anatomical motions obtained with rapid shallow ventilation would be favourable in the context of radiotherapy [9][10][11]. There is no consensus on the optimal method to correct for errors related to breathing [12] and the variety of devices available to compensate for respiratory intrafraction motion all have financial, technical or patient discomfort implications. Mechanical ventilation could offer a simple, cheap alternative, reducing target volumes and thereby doses to organs at risk or enabling patients with large breathing amplitudes access to more therapeutic hypofractionated radiotherapy regimes.

Abdominal compression is popular choice for controlling motion, particularly for thoracic and upper abdominal targets [13]; it is easy, cheap and can be used with all manufacturers of CT and linac. It has been reported to significantly reduce craniocaudal motion [14] especially for lower lobe lesions [15]. However, it is not a gold standard; patients report it to be uncomfortable [16], it is limited in its ability to reduce upper thoracic motion and there are concerns regarding target residual excursion and associated amplitude reproducibility [14]. Attempts have been made to improve abdominal compression using the dual vacuum bag approach (BodyFIX system, Elekta,) which mitigates reproducibility issues and is reported to be more comfortable [16].

Breath holding with room air using multiple short breath-holds is commonplace and used routinely for breast radiotherapy where the external 'markers' closely represent and correlate with target anatomy. Utilising breath holding for more complex, high dose techniques has three main issues: (i) internal anatomy demonstrates a large settlement during the first 20 seconds of breath holding [17], (ii) most patients are only able to comfortably hold their breath for ~30 seconds so complex radiotherapy would require multiple breath holds and (iii) a reliable method by which to estimate target position using an external surrogate has not been established. Recently, single prolonged breath holds (>5 minutes) have been demonstrated possible in patients with breast cancer [3], but no MRI data quantifying internal motion is yet available.

Gating employs the assumption that target motion can be predicted by using either an external respiration signal or internal fiducial markers [18][19]. Although more rare and not always clinically possible, internal surrogates have repeatedly demonstrated a superiority in terms of correlation to target motion [20][21]. Free breathing respiratory motion is known to be naturally irregular, therefore the target – external surrogate correlation changes during treatment. Some commercial target tracking solutions also monitor internal motion and verify the validity of the model with the acquisition of fluoroscopic images, modifying the model if required [22]. Irregular breathing and target excursion invalidates internal and external correlation, reducing the tracking accuracy [23]. Latency in this tracking system is an additional source of uncertainty, prolonging treatment whenever the model is refreshed.

MRI guided radiotherapy, although expensive and in its infancy, appears to be a viable approach for mitigating respiratory motion albeit with motivated, engaged and actively compliant patients. Suitable patients can then use their own internal anatomy to control treatment gating, avoiding an external surrogate which should be more closely related to tumour position and therefore more likely to generate a superior surrogate - target correlation.

Due to the lack of randomised control trials there is no standardised approach or a consensus of opinion on how best to manage intrafraction motion as a consequence of respiration. More studies with large cohorts of patients are required to fully justify and quantify the benefits that different approaches may offer.

Here we demonstrate that rapid shallow non-invasive ventilation achieves large reductions in internal measures of breathing amplitude and variability using diaphragm motion *versus* normal breathing, and with inter-session consistency in healthy subjects. We have already established that mechanical ventilation at 16 breaths per minute is feasible and well tolerated by conscious unmedicated breast cancer patients [3][8], so we envisage no difficulties in routinely mechanically ventilating patients at 20 or 25 breaths per minute. Future work will address whether this approach is tolerable, and can produce similar results in patients referred for high dose radiotherapy to a thoracic target.

To our knowledge, this is the first demonstration that non-invasive, rapid shallow mechanical ventilation produces large reductions in the magnitude and variability of internal diaphragm motion due to respiration in healthy conscious subjects. The clinical application of such large motion reductions could be beneficial for patients where respiration otherwise impacts on target volume and associated dose distributions for a number of sites such as lung, liver and pancreas to a degree that makes it clinically unacceptable to proceed with radiotherapy.

At present there are no commercial systems that implement ventilation to control respiratory motion in a radiotherapy context. Utilising rapid shallow non-invasive ventilation is a potential approach to control motion for hypofractionated radiation treatment, mitigating many of the issues found with abdominal compression, gating using external surrogates and short breath hold techniques.

## References

- [1] Stereotactic Ablative Body Radiation Therapy (SABR): A Resource V5.1. UK SABR Consortium  
<https://sabr.org.uk/wp-content/uploads/2016/04/UKSABRConsortiumGuidelinesv51.pdf>
- [2] Bartlett FR, Colgan RM, Carr K et al The UK HeartSpare Study: randomised evaluation of voluntary deep-inspiratory breath-hold in women undergoing breast radiotherapy. *Radiother Oncol.* 2013 Aug;108(2):242-7
- [3] Parkes MJ, Green S, Stevens A, Parveen S, Stephens R, Clutton-Brock T. Safely prolonging single breath-holds to >5 min in patients with cancer; feasibility and applications for radiotherapy. *Br J Radiol* 2016; 89 20160194
- [4] Schwarz M, Cattaneo CM, Marrazzo. Geometrical and dosimetrical uncertainties in hypofractionated radiotherapy of the lung: A review. *Physica Medica* 2017; 36:126-39
- [5] Cooper HE, Clutton-Brock TH, Parkes MJ (2004). Contribution of the respiratory rhythm to sinus arrhythmia in normal unanesthetized subjects during mechanical hyperventilation with positive pressure. *Am J Physiol* 2004; 286:H402-11
- [6] Rutherford JJ, Clutton-Brock TH, Parkes MJ. Hypocapnia reduces the T wave of the electrocardiogram in normal human subjects. *Am J Physiol Regul Integr Comp Physiol* 2005; 289:R148-55
- [7] Parkes MJ, Green S, Stevens CD, & Clutton-Brock TH (2014). Assessing and ensuring patient safety during breath-holding for radiotherapy. *Br J Radiol* 87, 20140454
- [8] Parkes, M.J., Green, S., Stevens, A., Parveen, S., Stephens, R., & Clutton-Brock, T. (2016). Reducing the within-patient variability of breathing for radiotherapy delivery in conscious, unседated cancer patients using a mechanical ventilator. *Br J Radiol* 89, 20150741
- [9] Hill R. Radiation effects on the respiratory system. *Br J Radiol* 2005:75–81
- [10] Marks LB, Bentzen SM, Deasy JO, et al. Radiation dose–volume effects in the lung. *Int J Radiat Oncol Biol Phys* 2010;76:S70–76
- [11] Timmerman RD. An overview of hypofractionation and introduction to this issue of seminars in radiation oncology. *Semin Radiat Oncol.* Oct 2008;18(4):215-222
- [12] Caillet V, Booth JT, Keall P. IGRT and motion management during lung SBRT delivery. *Physica Medica* 2017; 44:113-22
- [13] Daly ME, Perks JR, Chen AM. Patterns-of-care for thoracic stereotactic body radiotherapy among practicing radiation oncologists in the United States. *J Thorac Oncol* 2013;8:202–7.
- [14] Wunderink W, Romero AM, De Kruijf W, De Boer H, Levendag P, Heijmen B. Reduction of respiratory liver tumor motion by abdominal compression in stereotactic body frame, analyzed by tracking fiducial markers implanted in liver. *Int J Radiat Oncol Biol Phys* 2008;71:907–15.
- [15] Bouilhol G, Ayadi M, Rit S, Thengumpallil S, Schaerer J, Vandemeulebroucke J, et al. Is abdominal compression useful in lung stereotactic body radiation therapy? A 4DCT and dosimetric lobe-dependent study. *Physica Med* 2013;29:333–40.
- [16] Han K, Cheung P, Basran PS, Poon I, Yeung L, Lochray F. A comparison of two immobilization systems for stereotactic body radiation therapy of lung tumors. *Radiother Oncol* 2010;95:103–8.
- [17] Lens E, Gurney-Champion OJ, Van der Horst A, Tekelenburg DR, van Kesteren Z, Parkes MJ, Van Tienhoven G, Nederveen AJ, & Bel A Towards an optimal breath-holding procedure for radiotherapy: differences in organ motion during inhalation and exhalation breath-holds *Med Phys* 43, 3711

- [18] Giraud PME, Claude L, Mornex F, Le Pechoux C, Bachaud JM, Boisselier P, et al. STIC Study Centers. Respiratory gating techniques for optimization of lung cancer radiotherapy. *J Thorac Oncol* 2011, Dec:2058–68
- [19] Van den Begin R, Engels B, Gevaert T, et al. Impact of inadequate respiratory motion management in SBRT for oligometastatic colorectal cancer. *Radiother Oncol* 2014;113:235–9
- [20] Korreman S, Mostafavi H, Le Q-T, Boyer A. Comparison of respiratory surrogates for gated lung radiotherapy without internal fiducials. *Acta Oncol* 2006;45:935–42. <http://dx.doi.org/10.1080/02841860600917161>.
- [21] Li R, Mok E, Chang DT, Daly M, Loo BW, Diehn M, et al. Intrafraction verification of gated rapidarc by using beam-level kilovoltage X-ray images. *Int J Radiat Oncol Biol Phys* 2012;83:e709–15. <http://dx.doi.org/10.1016/j.ijrobp.2012.03.006>.
- [22] Hoogeman M, Prévost JB, Nuyttens J, Pöll J, Levendag P, Heijmen B. Clinical accuracy of the respiratory tumor tracking system of the cyberknife: assessment by analysis of log files. *Int J Radiat Oncol Biol Phys* 2009;74:297–303. <http://dx.doi.org/10.1016/j.ijrobp.2008.12.041>.
- [23] Sharp GC, Jiang SB, Shimizu S, Shirato H. Prediction of respiratory tumour motion for real-time image-guided radiotherapy. *Phys Med Biol* 2004;49:425–40. <http://dx.doi.org/10.1088/0031-9155/49/3/006>.

Figure 1 A schematic representation of the experimental non-invasive ventilation protocol for the normal and mechanically ventilated breathing modes.

Figure 2 Mean respiratory amplitudes were determined through multiple measurements, over a 30- second period, across the lung-diaphragm interface for normal and non-invasive ventilation breathing modes.

Figure 3 Respiratory motion for 10 subjects in normal breathing and under rapid shallow non-invasive ventilatory control. Motion displayed as the mean, minimum and maximum respiratory amplitudes with the associated standard deviations. Mechanical ventilation at 20 and 25 breaths per minute demonstrated significant reductions in diaphragm motion ( $p < 0.005$ ), at all 3 measured points in both the sagittal and coronal planes.

Figure 4 Sagittal inter session reproducibility of the lung-diaphragm interface motion for 8 subjects; during normal and ventilated breathing at 20 and 25 breaths per minute over 2 sessions.

Figure 5 Performing simple image analysis (setting pixel values greater than the average to white, less than the average to black, then superimposing the resultant image) demonstrates the motion reduction possible by employing rapid shallow non-invasive ventilation in anatomy both superior and inferior to the diaphragm.

	Respiratory amplitudes (mm)			
	Sagittal		Coronal	
	Mean	Std Dev	Mean	Std Dev
<b>Normal breathing</b>	28.9	9.9	23.1	5.4
<b>20 breaths / minute</b>	11.8	3.4	9.7	3.1
<b>25 breaths / minute</b>	10.6	3.0	8.4	2.3
<b>Normal breathing</b>	29.2	11.9	24.2	8.9

Table 1 Mean respiratory amplitudes and standard deviations, measured at the lung-diaphragm interface in the sagittal and coronal plane MR datasets; for normal breathing and under rapid shallow ventilatory control.

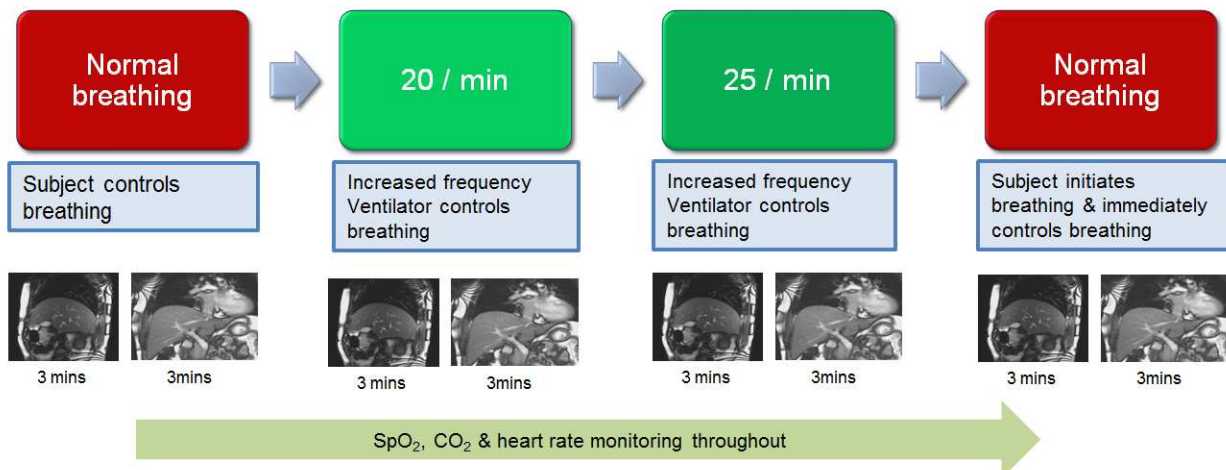


Figure 1 A schematic representation of the experimental non-invasive ventilation protocol for the normal and mechanically ventilated breathing modes.



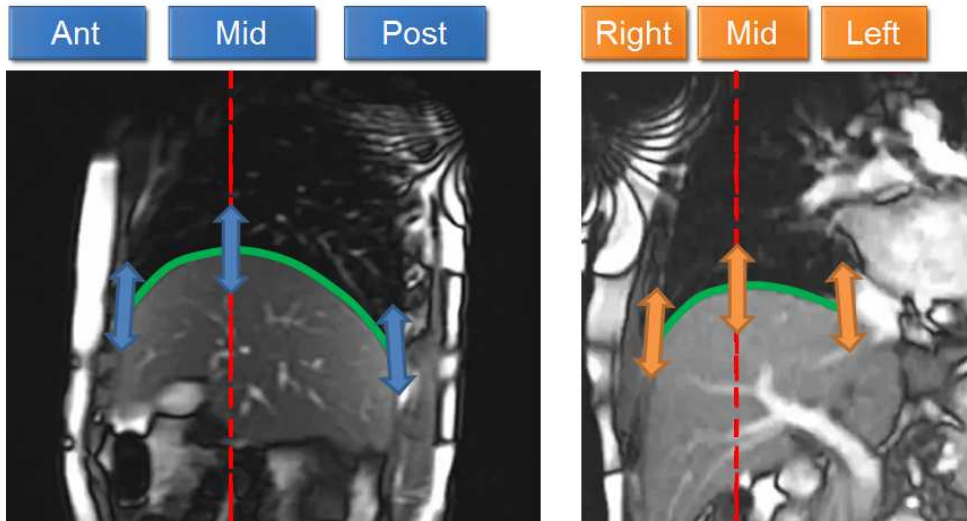


Figure 2 Mean respiratory amplitudes were determined through multiple measurements, over a 30- second period, across the lung-diaphragm interface for normal and non-invasive ventilation breathing modes.

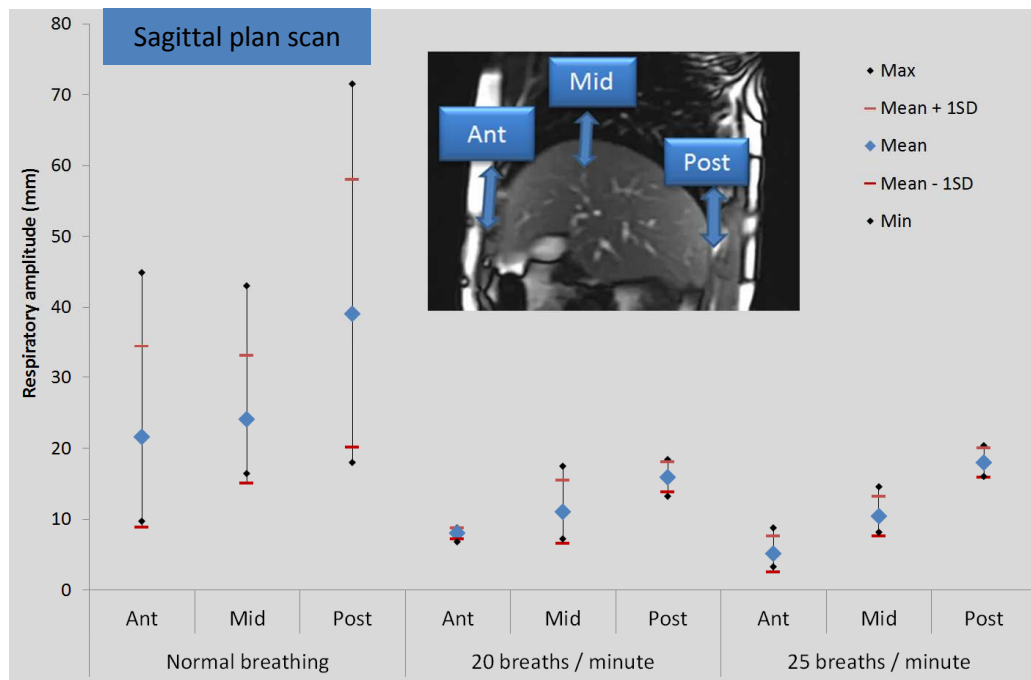


Figure 3 Respiratory motion for 10 subjects in normal breathing and under rapid shallow non-invasive ventilatory control. Motion displayed as the mean, minimum and maximum respiratory amplitudes with the associated standard deviations. Mechanical ventilation at 20 and 25 breaths per minute demonstrated significant reductions in diaphragm motion ( $p < 0.005$ ), at all 3 measured points in both the sagittal and coronal planes.

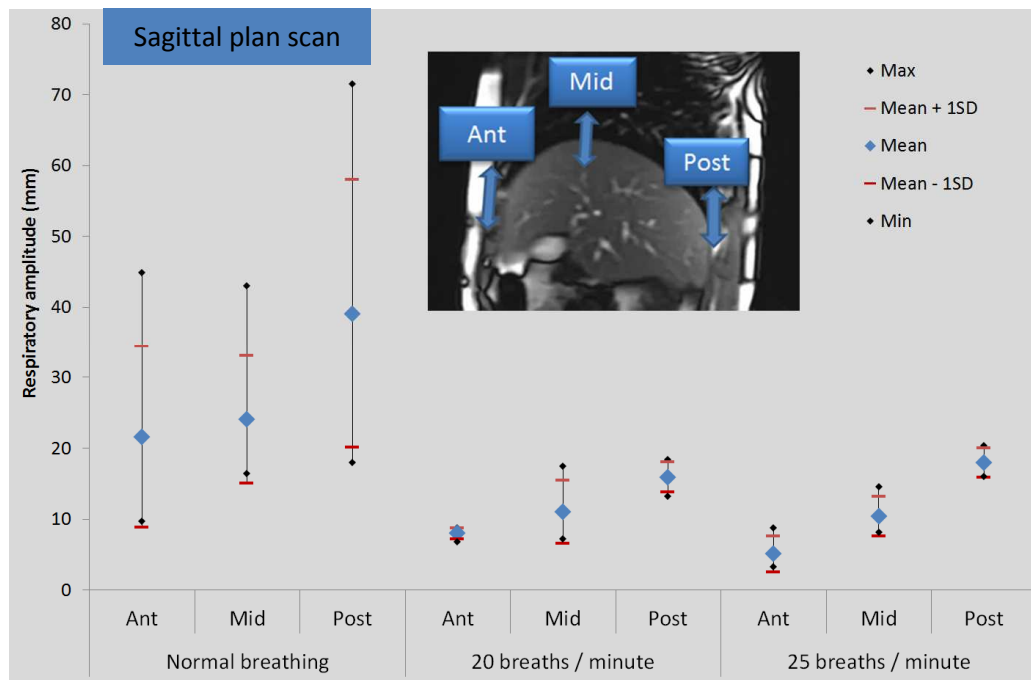


Figure 3 Respiratory motion for 10 subjects in normal breathing and under rapid shallow non-invasive ventilatory control. Motion displayed as the mean, minimum and maximum respiratory amplitudes with the associated standard deviations. Mechanical ventilation at 20 and 25 breaths per minute demonstrated significant reductions in diaphragm motion ( $p < 0.005$ ), at all 3 measured points in both the sagittal and coronal planes.

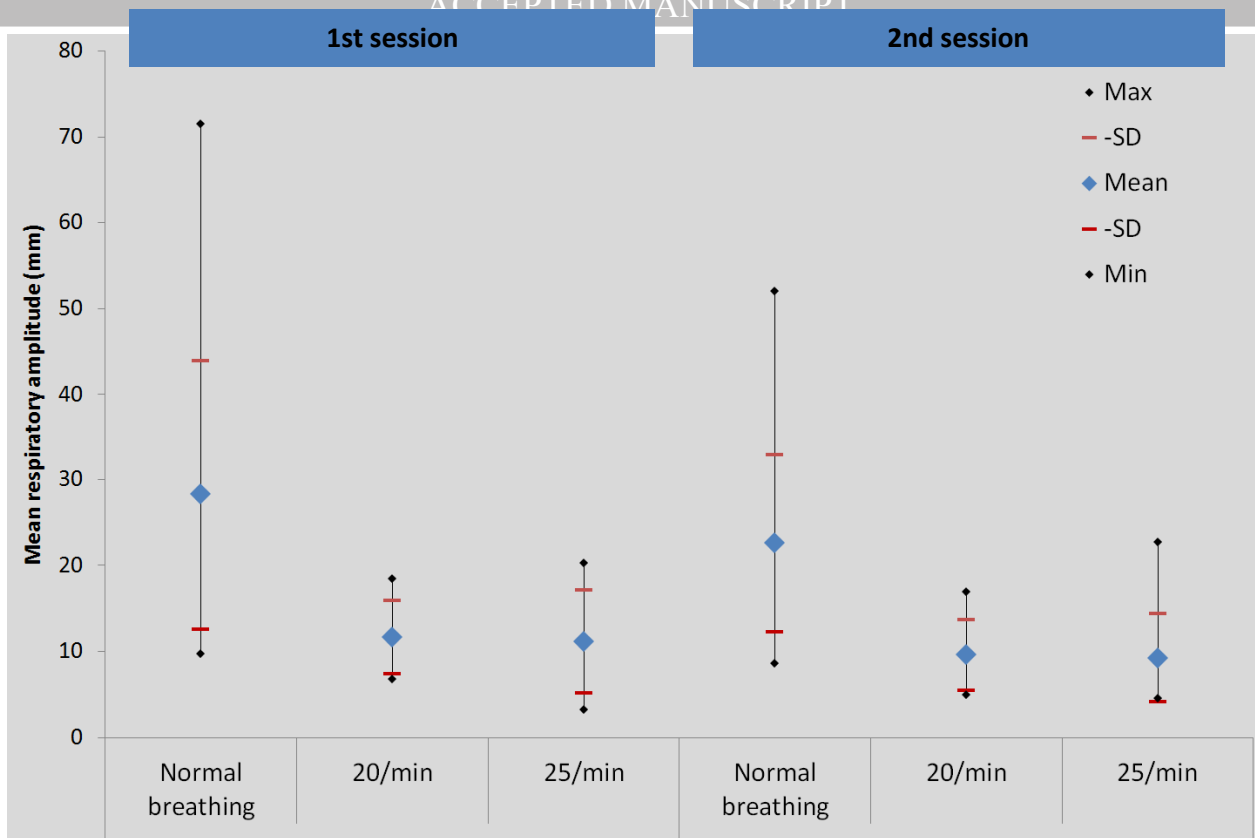
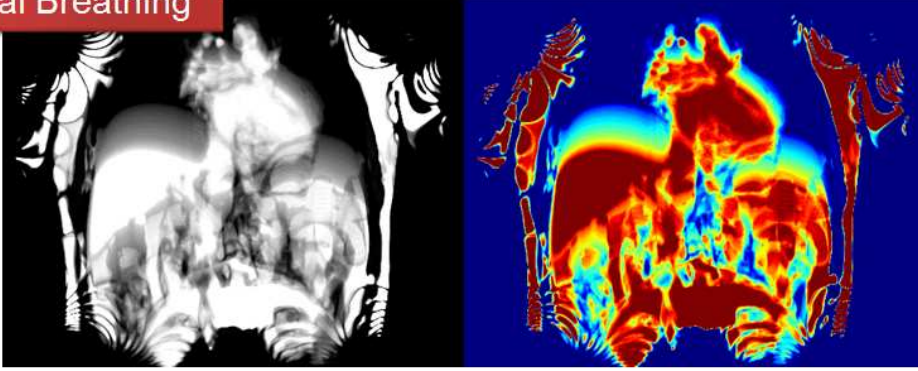


Figure 4 Sagittal inter session reproducibility of the lung-diaphragm interface motion for 8 subjects; during normal and ventilated breathing at 20 and 25 breaths per minute over 2 sessions.

Normal Breathing



rsNIV 20 / min

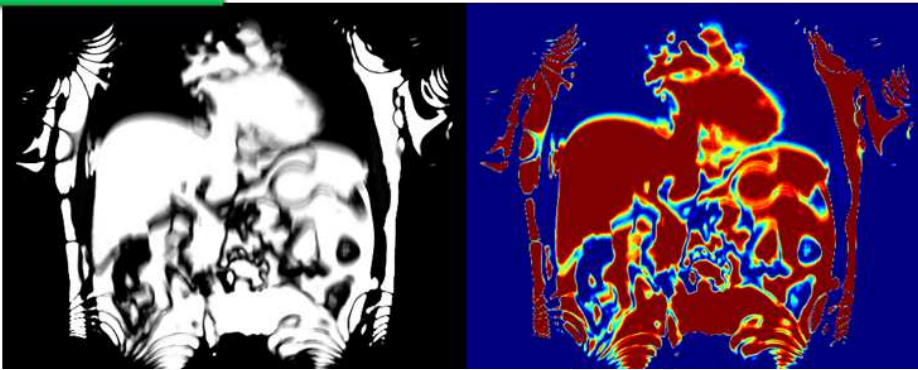


Figure 5 Performing simple image analysis (setting pixel values greater than the average to white, less than the average to black, then superimposing the resultant image) demonstrates the motion reduction possible by employing rapid shallow non-invasive ventilation in anatomy both superior and inferior to the diaphragm.