

Biotechnology in Animal Husbandry 28 (4), p 835-843 , 2012
Publisher: Institute for Animal Husbandry, Belgrade-Zemun

ISSN 1450-9156
UDC 636.09'65

DOI: 10.2298/BAH1204835M

FOOT-PAD DERMATITIS IN COMMERCIAL BROILERS

B. Miljković¹, Z. Škrbić², Z. Pavlovski², M. Lukić², V. Ivetić¹, B. Kureljušić¹, V. Petričević²

¹Scientific Institute of Veterinary Medicine of Serbia, Vojvode Toze 14, 11000 Belgrade, Republic of Serbia.

²Institute for Animal Husbandry, Autoput 16, P. Box 23, 11080, Belgrade, Republic of Serbia

Corresponding author: biljamiljkovic55@gmail.com

Original scientific paper

Abstract: In the present experiment, the presence of mycological agents in chickens with skin lesions on foot pads was investigated, in order to improve the health of broiler chickens. Foot-pad dermatitis (FPD) is described in the literature as dermatitis caused by multifactor causes. The presence of irritating chemical substances in the litter, genetic predispositions of hybrids, immune suppressive diseases of chickens, as well as the composition of commercial broiler diets that influence the occurrence of wet litter, are proven factors that contribute to a more intensive incidence of foot-pad dermatitis. Foot-pad dermatitis is a condition characterised by lesions on metatarsal and digital ventral skin of poultry feet. It is type of contact dermatitis which in severe cases shows slower weight gain, poor health condition and welfare. Taking into consideration the literature data, chickens reared in closed facilities where the bacterial and mycological agents are present partly in the litter if not properly disinfected, but also in the food or the chicken plumage, we wanted to investigate their presence in the skin of foot pads. The study was focused on incidence of foot-pad dermatitis in 500 one day old broiler chickens of Hubbard genotype, in two feeding (standard/economical) programs for broilers available on our market. Chopped straw was used as litter. At the end of fattening, all chickens were examined for the presence of lesions on the skin of the feet. Total of 39 chickens were allocated to the intensity of the lesion on foot pads rated as 2 (mild) and 3 (severe). In the mycological examination of the 9 samples of autoclaved chicken legs with lesions on the feet, we have isolated and identified the presence of fungi /mould *Aspergillus fumigatus*. The histopathology investigation, during which the tissue section from mild and severe skin foot pads was collected and stained using Hematoxylin and eosin, revealed the *hyperkeratosis, panniculitis, ballooning degeneration and dermis inflammation*. No fungal elements were observed in the sections of pads stained with Gomori methenamine silver. Birds are especially susceptible to infection with *Aspergillus fumigatus*. That species of fungus is also classified as allergenic factor.

Key words: Broiler, foot-pad dermatitis, histology

Introduction

In recent years, in commercial broiler production most cases of documented lesions are severe ulceration of feet (*metatarsal and digital foot pads*) or pododermatitis. Lesions on the ventral foot-pads of poultry are a type of contact dermatitis often present in broiler production, in an early mild stage visible as brown or black coloured skin and in severe cases the inflammation may progress to skin ulceration (*Greene et al., 1985*).

A direct correlation exists between contact irritation associated with poor litter quality, wet litter (*Martland 1984; 1985; Bilgili, 2009; Škrbić et al., 2012*), increased stocking density, increased flock age, using of particular feeds and winter conditions. FPD associated with nutritional deficiencies can be considered an unlikely aetiology in industrial livestock production. Dermatitis on turkey poultry has been linked to feeding rations deficient in riboflavin, biotin and pantothenic acid, as well as 40% or more soy bean meal (*Jensen et al., 1970*).

Lukić et al. (2009) stated in their work that complete feed mixtures available on the market vary in quality because of cheaper raw materials, supplements and additives. Also, contact dermatitis is considered as measure of poor broiler welfare (*Škrbić et al., 2011*). The overall incidence of reported avian mycotic dermatitis is relatively low. Interesting case has been described by *Quesada et al., (2007)* when *Mucor ramosissimus* was found associated with feather losses in canaries (*Serinus canarius*).

Also, *Candida albicans* has been isolated from foot-pad lesions in Japanese quail (*Coturnix coturnix japonica*) between 5 and 30 weeks of age (*Sah et al., 1982*). According to *Simon et al., (2009)* mycotic pododermatitis and mycotic pneumonia have been found in commercial turkey poultry in northern California. However, the role of other factors is less clear. Bearing in mind this data, our objective was to take out pathogenic opportunistic environmental fungi-dermatophytes which are most frequently isolated in our country, from skin and on/in feather follicles of clinically healthy birds, *Miljković et al., (2011)* and affected Japanese quails, *Sah et al., (1982)*. Gross erosive pathologic lesions usually are nonspecific and not suspected for mycosis until culture isolation of agents and histopathology examination of tissue section are carried out.

In this paper, we investigated the possible presence of opportunistic mycological agents in addition to those described so far.

Materials and Methods

Chicken legs were from experiments performed by *Škrbić et al., (2012)*. During the experiment, by clinical observation of chicks in boxes with regular monitoring of the technological mortality rate through patho-morphological

examination, the presence of intestinal infections, or the presence of other pathogens was not established. At the end of the fattening, the changes in skin of foot pads were recorded by Škrbić *et al.*, (2012), and in this study their intensity was graded 2 (mild) and 3 (severe). A total of 39 pairs of legs with recorded lesions was separated and used for further examination. In the histopathology examination, samples of skin from the foot pad of one leg (size 1x1x0, 5 cm) were taken for testing, while the other leg was kept in the freezer before to testing. Samples were grouped into biohazard bags and autoclaved at the temperature of 121 ° C under the pressure of the water vapour from 1.2 to 1.5 bars, for 30 minutes (Autoclave, Sutjeska F300).

Cultivation

Changed parts of the skin on the foot pads were inoculated in the blood agar (BA), Sabouraud's-dextrosa agar (SDA), Sabouraud's maltose agar (SMA) (Torlak), with and without antibiotics (*Penicillin*, *Streptomycin Cycloheximide*). Agar was held on room temperature (25°C) in aerobic conditions. Primary isolation was successful for 5 days. Subcultures were made on SDA and SMA with antibiotics (5 to 5 days). Cultures were stained with *Lactophenol-cotton-blue* (Hi Media) drops. The identification was based on macroscopic examination of colonies, their colour and the length of culturing. The identification was done according to the description in available literature (*Frey et al*, 1981; *Quinn et al.*, 2002).

Histopathology examination

In the histopathology examination of skin samples taken from the foot pads of legs were fixed in buffered formalin, processed using the standard procedure and embedded in paraffin blocks. Paraffin tissue slices, thickness of around 5 micrometers, were stained with *Hematoxylin-eosin* (HE) and *Gomori methenamine-silver* (GMS).

The photography was taken with the digital camera *Sony CD Mavica*, 3.3 mega pixels, *Carl Zeiss Vario-Sonnar*. The microphotography was made by (*Olimpus BH*, *Image Analysis and Leica*).

Results and Discussion

Clinical findings

At the end of the experiment 39 pairs of legs of chickens were separated, whose intensity of lesions were scored 2 (mild) and 3 (severe). Black coloured erosions and ulcers occur on the foot skin in 6-week-old chickens (Fig. 1a, b).

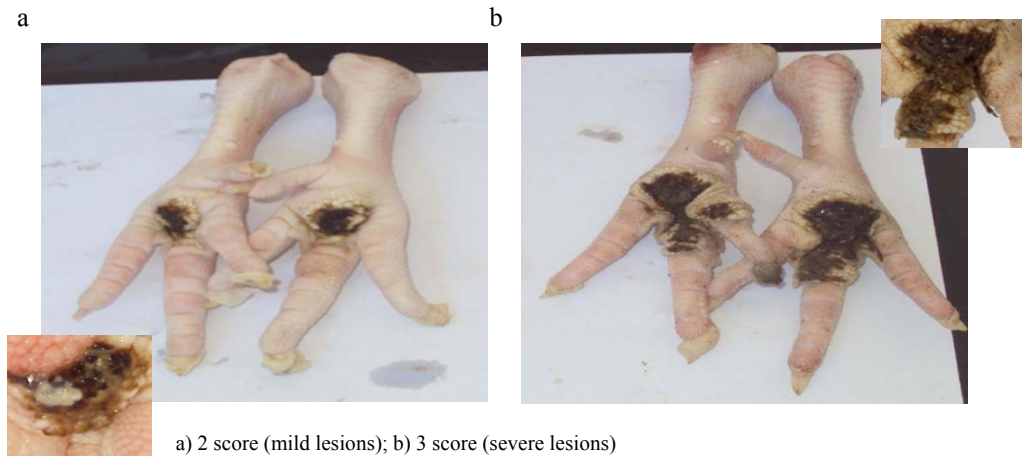
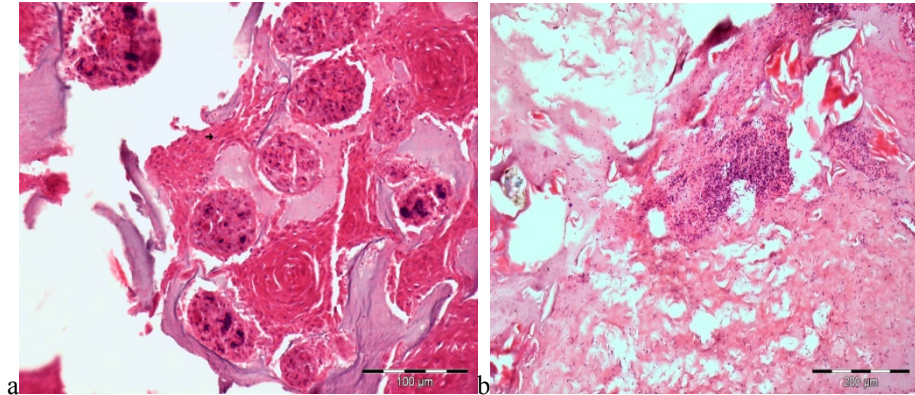
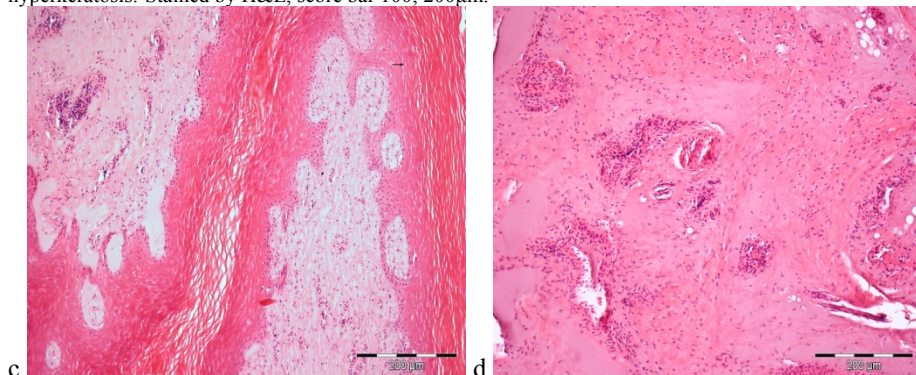


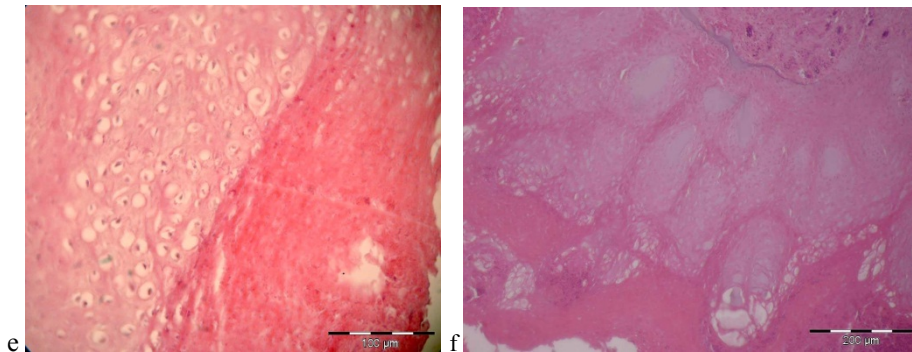
Figure 1. Ventral aspect of the feet with foot pad pododermatitis. Intensity of foot-pad lesions. There were no lesions on the dorsal surface.



Ulceration with cluster of degenerated granulocytes. b Exocytosis, migration of leukocytes into epidermis and hyperkeratosis. Stained by H&E, score bar 100; 200μm.




c. Keratin structure changes (hyperkeratosis) and inflammation in dermis; d) Panniculitis-inflammation in dermis. Stained by H&E, score bar 200μm.



e,f Ballooning degeneration. Stained by H&E, score bar 100; 200 μ m.

Figure 2. Histopathology of Foot-pads skin



a. A colony of *A.fumigatus* on SMA

Figure 3 Macroscopic view of fungal culture from FPD lesions

In our study affected footpads of broilers had epidermal surface erosions and ulcerations (Fig 1, 2). In the clinical observation during the fattening, deficiencies caused by lack of riboflavin, biotin and pantothenic acid were not established. Škrbić *et al.*, (2012) have recorded intense lesions in chickens in group D2 ("economic feeding program") because of the occurrence of wet litter due to more liquid faeces content compared to chickens of D1 group ("standard feeding program") where mild lesions were observed.

A review of leg weakness in Australian poultry flocks has been described by Nairn and Watson (1972). It has been suggested that the most common and important forms of leg weakness in fattening chickens are focal osteodystrophy, bacterial osteomyelitis, twister leg, foot pad pododermatitis, deviated toe and in laying flocks Marek's disease and osteoporosis. In the present study, the authors' opinion is that soybean based rations may be involved in producing an irritant deep litter. Also, Jensen *et al.*, (1970) have reported about foot-pad dermatitis in turkey poults. This foot-pad dermatitis was reported to be related to factors in the faeces from birds fed diets containing a high level of soybean meal. It was reported that

poults fed diets containing 40% or more of soybean meal exhibited a high incidence of foot-pad dermatitis, while birds fed diets containing little or no soybean meal had little or no such dermatitis. In the present experiment, we do not have data on the amount of soy that is likely to be present in the diet; it should definitely be investigated as well as its influence on the pathogenesis of FPD in broilers fed commercial feed mixtures available on the market.

Histological pad dermatitis may be seen to consist of an ulcerative skin lesion (Fig. 1a, b) suggestive of an external irritant. *Greene et al., (1985)* observed complete destruction of keratin and epidermal layer in the centre of the lesion. In the present study it was established that keratin structure changes (hyperkeratosis) and diffuse infiltration of dermis by inflammatory cells (Fig. c, d). Hyperkeratosis refers to a rapid turnover of keratinocytes that are undergoing apoptosis to produce keratin, resulting in a thickened layer of underdeveloped keratin. This is thought to be in response to an external trauma. Vesiculation of the epidermis in (Fig. 2e, f.) was also evident in our study consistent with results presented by *Martland (1984)*.

In the present experiment, finding of *Aspergillus fumigatus* in only 9 samples of total of 39 analysed, could indicate the potential presence of this pathogen, the type of dermatophytes that can contribute to more intensive lesions on the feet skin. The disease starts in the skin as a result of injuries, initially, clinical feature is contact dermatitis. *Aspergillus spp.* is ubiquitous, in dust, earth, plants, contaminated feed and food stuffs. The fungus is a thermo-tolerant species, and grows within the temperature range of 30-45°C. It is capable of degrading cellulose and hemicelluloses, occurring in large amounts in plant material, as well as proteins, including keratin.

Birds are especially susceptible to infection with *A. fumigatus*. This species is also classified in the group of *allergenic factors* and may be the cause of allergic pulmonary alveolitis in humans. Numerous cases of aspergillosis in humans were described (*Baillet et al., 2001*).

In the case of chickens a frequent source of infection with *A. fumigatus* may be food contaminated with the fungus and contact with the wet litter during feeding.

In our environment this agent was isolated in *Coracias cyanogaster-Coraciiformes* and *Fringillidae-Passeriformes* imported as a free-living birds in quarantine in Serbia, described by *Miljković et al., (2011)*.

Contrary to *Kureljušić et al., (2010)* who pointed out in their work to the application of a certain methodology of histology proving of *A. fumigatus* causers after isolation, the presence of fungal forms of *A. fumigatus* in the examined tissue was not demonstrated in the present study. The present finding is consistent with the confirmed findings in clinical cases in human and veterinary medicine by *Ustin et al., (2006)* and *Ozturk et al., (2009)* who also have isolated the cause, but have not shown the presence of fungal forms in the tissue.

In the paper by *Simone et al.*, (2009), mycotic pododermatitis and mycotic pneumonia in commercial turkey poultry were reported. The fungal hyphae in footpad epidermis and subcutis have been identified but *no fungal cultures* were undertaken at the time of the necropsy. By polymerase chain reaction amplification of part of the large subunit ribosomal RNA gene, using broad-range fungal primers and DNA sequencing in footpads, sequences matching *Cryptococcus saitoi* and *Cladosporium* and *Cudoniella* species were identified.

Our finding suggests that it was probably secondary pathogens that are present in the food and the environment, especially in the litter on which the chickens move. We think that by autoclaving of legs we managed to avoid numerous bacterial contaminants present on the skin, and were able to isolate and identify *Aspergillus fumigatus* from deep foot pad lesions. In the literature there are many referred and proven predisposing factors but also environmental pollution with chemical compounds-pesticides. Certainly the genetic selection for resistance against the FPD, i.e. to the predisposing factors, is one of the possible solutions that would help improve the health and welfare of chickens.

Conclusion

In this paper, the incidence of *Aspergillus fumigatus* in pathology of FPD was discussed. The fungal culture of *Aspergillus fumigatus* was identified. A lack of fungal form in histology section for definitive diagnosis represents a limitation of the present report.

Acknowledgment

This research is part of the Project EVB: TR-31033 financial supported by Ministry of Education, Science and Technological Development of the Republic of Serbia.

Dermatitis tabanskih jastučića kod komercijalnih brojlera

B. Miljković, Z. Škrbić, Z. Pavlovski, M. Lukić, V. Ivetić, B. Kureljušić V. Petričević

Rezime

U ogledu je ispitivano prisustvo mikoloških agenasa kod pilića sa lezijama na koži tabanskih jastučića, u cilju poboljšanja zdravlja brojlerskih pilica. Dermatitis na tabanskim jastučićima (DTJ) je u literaturi multifaktornog porekla.

Postojanje iritantnih hemijskih supstanci u prostirci, genetske predispozicije hibrida, imunosupresivne bolesti pilića, kao i sastav komercijalnih smeša za ishranu brojlera koje utiču na pojavu vlažne prostirke, su dokazani faktori koji doprinose intenzivnijoj pojavi DTJ. Imajući u vidu ove podatke iz literature, pilići koji se gaje u zatvorenom prostoru u kome su prisutni bakterijski i mikološki agensi delom u prostirci ako nije na adekvatan način dezinfikovana, u hrani ili na perju pilića, želeli smo da ispitamo njihovo prisustvo u koži tabanskih jastučića. Ispitivanje je bazirano na pojavi DTJ u ogledu 500 jednodnevni pilića Hubbard genotipa, koji su hranjeni na 2 načina (standardnim/ekonomičnim) krmnim smešama koje su prisutne na našem tržištu. Seckana slama je korišćena kao prostirka. DTJ se karakteriše lezijama na metatarzalnim i digitalnim ventralnim delovima kože tabana živine. To je kontaktni dermatitis koji kod težih slučajeva utiče na prirast, zdravlje i dobrobit. Na kraju tova pilića, svi pilići su pregledani na prisustvo lezija na koži tabana. U ovom radu, ispitano je 39 pilića sa intenzitetom lezija na tabanskim jastučićima. Intenzitet lezija je ocenjen sa 2 (blage) i sa 3 (izražene) lezije. Mikološkim ispitivanjem utvrđeno je prisustvo gljivice/plesni *Aspergillus fumigatus*, kod 9 autoklaviranih promenjenih pilećih nogica. Histološkim ispitivanjem utvrdili smo postojanje *hiperkeratoze*, *panikulitisa*, *zapaljenje dermisa i balonirajuću degeneraciju*. Nismo utvrdili prisustvo *fungalnih elemenata* u koži tabana, nakon bojenja *Gomory methenamin silver bojenjem*. Ptice su posebno osetljive na infekciju *A. fumigatus* koji je klasifikovan kao alergijski uzročnik.

References

- BAILLOT D., MANNONE LB., COUAILLIER J.F. (2001). Role of early diagnosis and aggressive surgery in the management of invasive pulmonary aspergillosis in neutropenic patients. *Clin Micro and Infec*, 7, Suppl. 2, 54-61.
- BILGILI, S. F., J. B. HESS, J. P. BLAKE, K. S. MACKLIN, B. SAENMAHAYAK, and J. L. SIBLEY (2009). Influence of bedding material on footpad dermatitis in broiler chickens. *J. Appl Poul Res* 18:583-589.
- FREY D., OLDFIELD R. J., BRIDGER R.C. (1981). *Color Atlas of Pathogenic Fungi*, Published by Wolfe Medical Publications Ltd, Printed by Smeets-Weert, Holland ISBN 07234 0744 4.
- GREENE J. A., McCracken R. M., EVANS R. T. (1985). A contact dermatitis of broilers- clinical and pathological findings. *A Path*, 14, 23-38.
- JENSEN L. S., MARTINSON R., SCHMAIER G. (1970). A foot pad dermatitis in turkey poult associated with soyabean meal. *Poul Sci* 49, 76-82.
- KURELJUŠIĆ B., SAVIĆ B., PRODANOVIĆ R., ĐEKIĆ J., ADAMOV V., JAKIĆ-DIMIĆ D., MILJKOVIĆ B., RADANOVIĆ O., IVETIĆ V. (2011).

Primena različitih histohemijskih metoda u dijagnostici Aspergiloze mozga kod ćuraka, *Vet. Glasnik* 65 (1-2): 43-49.

LUKIĆ M., PAVLOVSKI Z., ŠKRBIĆ Z. (2009). Savremeni aspekti ishrane živine. 18. Savetovanje živinara, *Živinarstvo*, 44, 9, 15-26.

MARTLAND M. F. (1984). Wet litter as a cause of plantar pododermatitis, leading to foot ulceration and lameness in fattening turkeys. *A Path* 13: 241-252.

MARTLAND M. F. (1985). Ulcerative dermatitis in broiler chickens: The effects of wet litter. *A Path* 14:3,353-364.

MILJKOVIĆ B., PAVLOVSKI Z., JOVIČIĆ D., RADANOVIĆ O., KURELJUŠIĆ B. (2011). *Originalni rad*. Fungi on feathers of common clinically healthy birds in Belgrade, *Biotech in Animal Hus.* Vol.27,1: p 45-55.

NAIRIN M. E. AND WATSON. R. A. (1972). Leg weakness of poultry-A clinical and pathological characterisation. *A Vet J*, Vol.48, Dec.; 645-656.

OZTURK D., ADANIR R., TURUTOGLU H. (2009). Superficial skin infection with *Scopulariopsis brevicaulis* in two goats. A case report. *Bull Vet Pulawy* 53,361-363.

QUESADA O., RODRIGUEZ F., HERRAEZ P. (2007). *Mucor ramosissimus* associated with feather loss in canaries (*Serinus canarius*). *Avian Dis* 51:643-645.

QUINN P.J., MARKEY B.K., CARTER M.E., DONNELLY W.J.C. LEONARD F.C. (2002) *Veterinary microbiology and microbial disease*, Blackwell Science Ltd., Iowa State University Press.

SAH R.L., MALL M. P., & MOHANTY G. C. (1982). Cutaneous candidiasis in Japanese quail (*Coturnix coturnix japonica*). *Mycopathologia* 80, 33-37.

SIMONE T. S., ARTHUR A. B., RICHARD L. W., BRUCE R.CH. (2009). Micotic pododermatitis and mycotic pneumonia in commercial turkey poults in northern California. *J Vet. Diagn. Invest.* 21: 554-557.

ŠKRBIĆ Z., PAVLOVSKI Z., LUKIĆ M., PETRIČEVIĆ V., ĐUKIĆ -STOJČIĆ M., ŽIKIĆ D. (2011). The effects of stocking density on individual broiler welfare parameters 2. Different broiler stocking densities. *Biotech in Animal Hus.*, 27, 1, 17-25.

ŠKRBIĆ Z., PAVLOVSKI Z., LUKIĆ M., PETRIČEVIĆ V., MILJKOVIĆ B., MARINKOV G. (2012). The effects of the diet on incidence of foot-pad lesions and productivity of broilers. *Biotech in Animal Hus*, 28, 2, 353-360.

STOUTE, T. SIMONE., BICKFORD, RICHARD L., CHARLTON, R. BRUCE. (2009). Mycotic pododermatitis and mycotic pneumonia in commercial turkey poults in northern California. *J Vet. Diagn. Invest.* 21, 554-557.

USTIN C., HULS G., STEWART M. MARR K. A. (2006). Resistant *Microascus cirrosus* pneumonia can be treated with a combination of surgery, multiple anti-fungal agents and a growth factor. *Mycopathologia* 162; 299-302.