



Images in cardio-thoracic surgery

Acute Leriche syndrome due to the thrombus in the left ventricle

Denis A. Berdajs*, Patrick Ruchat, Piergiorgio Tozzi, Ludwig K. von Segesser

Department of Cardiovascular Surgery, Centre Hospitalier Universitaire Vaudois (CHUV), Lausanne, Switzerland

Received 16 June 2010; received in revised form 11 July 2010; accepted 14 July 2010; Available online 6 October 2010

Keywords: Acute occlusion of abdominal aorta; Acute Leriche syndrome; Left ventricular thrombus

A 50-year-old patient with acute paresis, paralysis and the absence of femoral pulses in both legs was admitted to emergency. Computed tomography (CT) scan revealed a total occlusion of infrarenal abdominal aorta and of the iliac arteries (Fig. 1). Thrombus in the left ventricle as the source of embolus (Fig. 2) was identified.

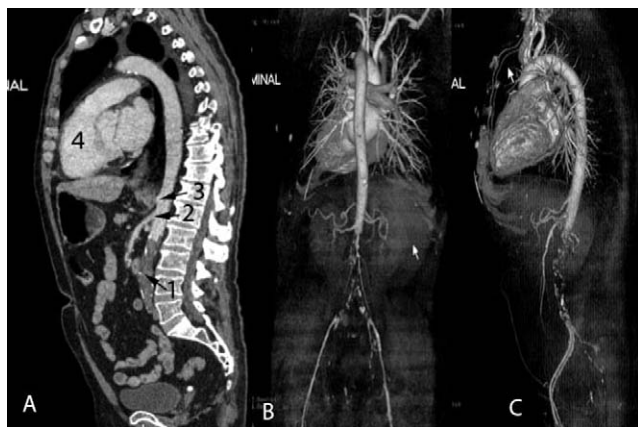

Fig. 1. CT scan, in early arterial phase, shows a total occlusion of the infrarenal aorta including, both left and right common iliac arteries. Superior mesenteric artery and celiac trunk were not occluded. (A) The 3D reconstruction of the late arterial phase of CT scan shows from the posterior (B) and lateral (C) view the occlusion of the abdominal aorta. 1: Embolus in infrarenal aorta, 2: superior mesenteric artery, 3: coeliac trunk and 4: right ventricle.

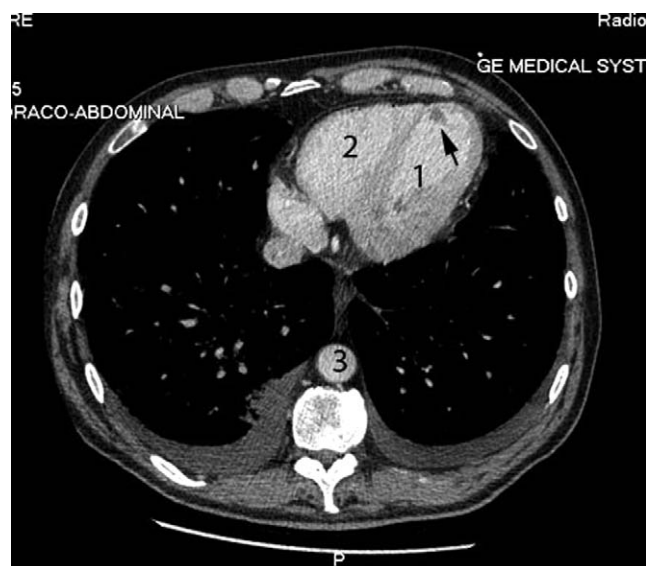


Fig. 2. Contrast CT scan, of late arterial phase, shows a cross-section image at the level of the left ventricle. The arrow indicates the thrombus in the apex of the left ventricle. 1: Left ventricle, 2: right ventricle and 3: thoracic aorta.

* Corresponding author. Address: Department of Cardiovascular Surgery, Centre Hospitalier Universitaire Vaudois (CHUV), Rue du Bugnon 46, Lausanne, 1011, Switzerland. Tel.: +41 21 314 26 95; fax: +41 21 314 22 78.

E-mail address: denis.berdajs@chuv.ch (D.A. Berdajs).