

Зборник Матице српске за природне науке / Proc. Nat. Sci., Matica Srpska Novi Sad,
№ 113, 267—270, 2007

UDC 582.282.123.4:616.992

Milena V. Kataranovski^{1,2}, *Jasmina M. Glamočlija*¹,
*Marina D. Soković*¹, *Milica V. Ljaljević-Grbić*³,
Dragan S. Kataranovski^{1,2}

¹ Institute for Biological Research “Siniša Stanković”,
Bulevar despota Stefana 142, Belgrade, Serbia

² Faculty of Biology, Studentski trg 16, University of Belgrade, Serbia

³ Institute of Botany, Faculty of Biology, University of Belgrade,
Takovska 43, Serbia

TOXIGENIC AND PATHOGENIC FUNGI IN NORWAY RAT (*RATTUS NORVEGICUS* BERK., 1769) FROM NATURAL POPULATIONS IN SEMIAGRICULTURAL HABITATS

ABSTRACT: In this study, the presence of toxigenic and pathogenic fungi was detected in individuals of natural populations of Norway rats from semiagricultural habitats. The presence of fungi was noted in 19 out of 30 (63%) individuals examined. Six fungal species were isolated and identified, of which majority belonged to *Hyphomycetes* (*Deuteromycotina*) and *Mucor racemosus* from *Zygomycotina*. All of detected species are of public health importance and some of them might influence animals health.

KEY WORDS: fungi, lung homogenates, Norway rats, SMA medium

INTRODUCTION

Norway rat is a common pest rodent species with wide distribution (Hrgović, Vukićević and Kataranovski, 1991). Rats are synantropic animals, that live near humans who provide them shelter and food. Owing to their life style (omnivorous, active whole day, feeding everywhere) wild rat populations are constantly exposed to various microbe species including viruses, helminths, bacteria and fungi. For many of these microbial agents rodents are reservoirs and vectors, serving thus as an important indicator of the epizootic and epidemic situation of their living environment (Winiewicz, 2002). While there is considerable knowledge of viral, bacterial and helminth burden in natural populations of rodents, there are virtually no data regarding presence of fungal components in animal organisms. Spores of fungi float in the air, and may be found in different environmental substrates. Fungal spores

may colonize rodent tissues in contact, establishing biological sources of these agents. In this way, rodents might act as reservoirs of these agents contributing to their spreading. Great number of fungal species cause diseases known as mycoses and mycotoxicosis. Presence of fungi and their metabolic products, mycotoxins, in foods and grains contaminated by rat excrements, presents a potential hazard to human and animal health (B u s b y and W o g a n, 1986).

Having in mind the potential of rodents to serve as fungal reservoirs and subjects of fungal components spreading, a research has been undertaken in order to examine the presence of fungi in wild rat populations.

MATERIALS AND METHODS

Wild rats (*Rattus norvegicus*) were captured by living traps in semiagricultural habitats (Omoljica, Kovin, Leštane and Ovča). Swabs from external area of nose were taken and lung tissue homogenates prepared under sterile conditions. Swabs and specimens of lung tissue homogenates were inoculated on Sabouraud Maltose Agar (SMA) medium with streptomycin to avoid bacterial infection (T a r r a n d et al., 2005). After incubation, micromycetes were identified on the basis of micro- and macrocharacteristics of fungal isolates.

RESULTS AND DISCUSSION

Of 30 individuals examined, in 19 individuals (63%) fungi were detected in lung homogenates. Six fungal species were isolated and identified, of which five belonged to classes Hyphomycetes (Deuteromycotina) and *Mucor racemosus* from Zygomycotina. *Aspergillus* and *Penicillium* species were detected in homogenates of lungs of five and six individuals, respectively. (Figure 1). *Paecilomyces varioti* was isolated from six individuals. Swabs from nasal skin of 15 (50%) out of 30 individuals were found positive for fungi (4 for *Aspergillus*, 4 for *Penicillium*, 6 for *Paecilomyces varioti* and one for *M. racemosus*) However, in only 9 cases presence of fungi on nasal skin and in lungs coincided. Some of the fungal isolates were not identified at the species level, because of the atypical fungal elements. This particularly refers to *Penicillium* species (atypical characteristics of spores with changed shape and size could be observed at elongated phialides with branched conidiophores).

A. fumigatus is the most frequent pathogenic species that causes pulmonary aspergillosis with high mortality level. *A. flavus* is a known toxigenic species, which produces Aflatoxin B1, the most carcinogenic human mycotoxin causing hepatocellular carcinoma. *A. repens* is osmophilic species well adapted to dry substrates and commonly causes farmer's lung disease and other pulmonary infections. *Paecilomyces varioti* may cause paecilomycosis, which can be manifested as endocarditis, sinusitis and pulmonary infections at rodents and humans (B y r d et al., 1992), *M. racemosus* (known as an allergenic agent causing pulmonary infections) was isolated from one sample of rat's lung's homogenate.

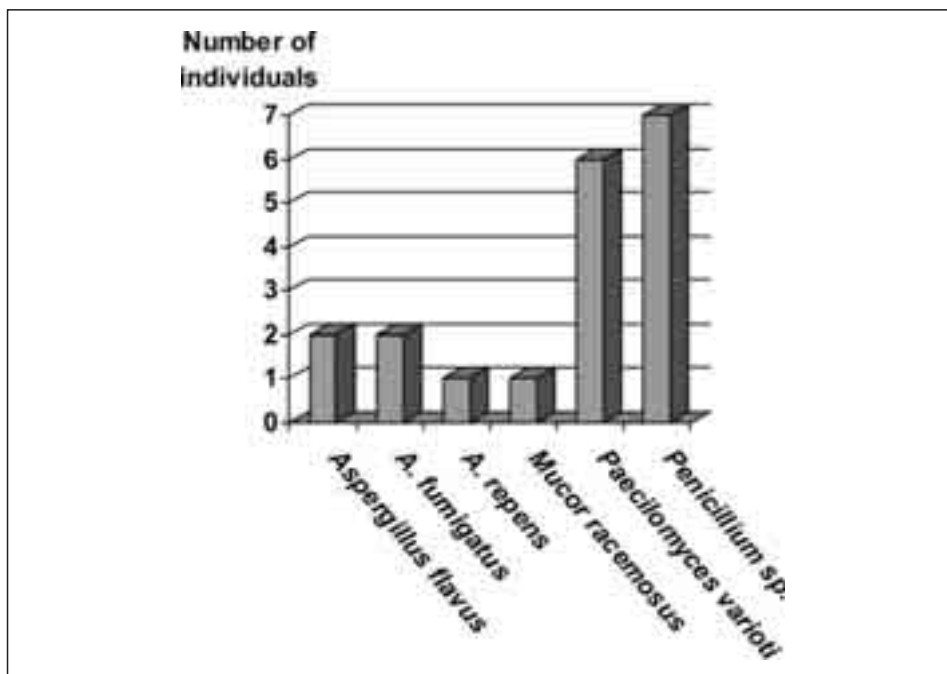


Fig. 1 — Mycological examination of lung homogenate

Of special interest is *A. fumigatus*, the most common invasive mold which is the cause of opportunistic infections in individuals with weakened immune system (patients on chemotherapy, AIDS patients, in individuals on prolonged antibiotic treatment, children and elderly people). Beside risk for human health, presence of these fungi might influence animal health as well, influencing, thus, the characteristics of rodent's natural population.

ACKNOWLEDGMENTS.

This study was supported by the Ministry of Science and Environmental protection, Grant# 143038.

REFERENCES

- Busby, W. F., Wogan, J. G. N. (1985): *Aflatoxins*. In: S. E. Searle (ed.), *Chemical carcinogens*, Am. Chem. Soc., Washington, D.C, 487—539.
- Byrd, R. P., Roy, T. M., Fields, C. L., Lynch, J. A. (1992): *Paecilomyces with diabetes mellitus*, *J. Diab. Com.* 6, 150—153.
- Hrgović, N., Vukićević, Z., Kataranovski, D. (1991): *Basic bioecological characteristics of pest rodent populations*. In: D. Perović (ed.) *Control of pest rodent populations-DERATIZATION*, Dečje novine, 13—28.

- Tarrand, J. J., Han, X. Y., Dimitrios, P., Kontoyiannis, D. P., May, G. S. (2005): *Aspergillus hyphae in infected tissue: Evidence of physiologic adaptation and effect of culture recovery*, J Clin Microbiol 43: 382—386.
- Winiewicz, E. (2002): *Microbiological examination of wild rats living in various environments in the epizootic aspect*, Electronic Journal of Polish Agricultural Universities, Veterinary Medicine, 5 (1), 1—25.

ТОКСИГЕНЕ И ПАТОГЕНЕ ГЉИВЕ КОД СИВОГ ПАЦОВА
(*RATTUS NORVEGICUS* BERK., 1769) ИЗ ПРИРОДНИХ ПОПУЛАЦИЈА
СА ПОЛУПОЉОПРИВРЕДНИХ СТАНИШТА

Милена В. Катарановски^{1, 2}, Јасмина М. Гламочлија¹, Марина Д. Соковић¹,
Милица В. Љаљевић-Грбић³ и Драган С. Катарановски^{1, 2}

¹ Институт за биолошка истраживања „Синиша Станковић”,
Булевар деспота Стефана 142, Београд, Србија

² Биолошки факултет, Студентски трг 16, Универзитет у Београду, Србија

³ Институт за ботанику, Биолошки факултет, Универзитет у Београду,
Таковска 43, Србија

Резиме

У овом раду су приказана истраживања присуства токсигених и патогених гљива у јединкама сивог пацова (*Rattus norvegicus* BERK., 1769) из природних популација са полупољопривредних станишта (Омољица, Ковин, Лештане, Овча). Детекција присуства гљива у биолошком материјалу (брис коже носне шупљине и хомогенат плућа) је вршена на селективној Sabouraud Maltose Agar (SMA) подлози. Истраживање је показало присуство шест врста гљива од којих пет припада класи *Hyphomyceta* (*Deuteromycotina*), а *Mucor racemosus* класи *Zygomycotina*. Врсте рода *Aspergillus* су детектоване у хомогенатима плућа шест јединки а *Penicillium* код пет јединки. *Paecilomyces varioti* је изолован из ткива шест јединки сивог пацова. Брисеви коже носне шупљине су дали позитивне резултате у 15 (50%) од 30 јединки (четири позитивна за *Aspergillus*, четири за *Penicillium*, шест за *Paecilomyces varioti* и једна за *Mucor racemosus*). Међутим, у само 9 случајева забележено је поклапање присуства гљива у кожи носне шупљине и плућа.

Налази који показују присуство патогена, изазивача тешких гљивичних обољења, указују на сивог пацова као на потенцијални резервоар ових агенаса. Добијени подаци представљају, према нашем сазнању, прве податке о присуству гљива код пацова из природне средине забележене код нас.