

Зборник Матице српске за природне науке / Proc. Nat. Sci., Matica Srpska Novi Sad,  
№ 113, 243—247, 2007

UDC 599.323.4:616.24-092]:579.6

*Jelena S. Živanović<sup>1</sup>, Marina D. Soković<sup>1</sup>,  
Jasmina M. Glamočlija<sup>1</sup>, Lidija D. Zolotarevski<sup>3</sup>,  
Milena V. Kataranovski<sup>1,2</sup>,  
Dragan S. Kataranovski<sup>1,2</sup>*

<sup>1</sup> Institute for Biological Research “Siniša Stanković”,  
Bulevar despota Stefana 142, Belgrade, Serbia

<sup>2</sup> Faculty of Biology, University of Belgrade, Studentski trg 16, Belgrade, Serbia

<sup>3</sup> Military Medical Academy, Crnotravska 17, Belgrade, Serbia

## CHARACTERISTICS OF LOCAL PULMONARY RESPONSE FOLLOWING INTRANASAL APPLICATION OF *ASPERGILLUS FUMIGATUS* CONIDIA

**ABSTRACT:** In this study, histopathology of local pulmonary response following intranasal inoculation of different doses of *Aspergillus fumigatus* conidia in laboratory rats was evaluated. Development of response was evaluated on days seven and twenty one, following conidia inoculation by cell infiltration and by presence of *A. fumigatus* conidia in homogenates of lung tissue. Total and differential peripheral blood leukocyte counts and state of leukocyte adhesion/aggregation were monitored to estimate the presence of systemic response in infected individuals. Mycological examination revealed the presence of conidia in lung tissue homogenates of infected animals, with high number of non-germinating spores on day twenty one, following the inoculation of lower conidia dose. Histopathological examination revealed the presence of lymphocytes perivascularly and in vascular lumen in the lungs. Presented data demonstrate pulmonary immune response following *A. fumigatus* conidia administration.

**KEY WORDS:** *Aspergillus fumigatus*, histopathology, laboratory rats, lung homogenates, lungs, lymphocytes

### INTRODUCTION

The genus *Aspergillus* includes more than 200 species, which are abundant in every region in the world. *Aspergillus* can be differentiated from other fungi by the presence of thin, parallel walls, dichotomous branching, septate hyphae, and characteristic conidiophores. The most species of *Aspergillus* cause infections/diseases (aspergilloses), but 90% of aspergillosis are caused by opportunistic fungi *Aspergillus fumigatus* (L a t g e, J. P., 1999). *A. fumigatus* has conidia 2—3 μm in diameter which enter the respiratory tract by inha-

lation and reach distal alveoli (the lungs are the most common site of infection).

Pulmonary aspergillosis is the most common and involves allergic bronchopulmonary aspergillosis, aspergilloma and invasive pulmonary aspergillosis (Shibuya, K. et al., 2004). As manifestations of the infection depend on host's immune response, the increase in numbers of immunocompromised and susceptible hosts fueled interest in aspergillosis. The interaction between weakened defense mechanisms and pathogenic conidia of *A. fumigatus* cause pulmonary lesions. *A. fumigatus* is not pathogenic in immunocompetent individuals, where innate immunity is considered as the main defense against this fungus (Romani, L., 2004).

In almost all investigations of *A. fumigatus* infections and aspergillosis, immunocompromised/immune suppressed animals were used. The aim of this study is to get the initial data about local host lung immune response in a model of experimental pulmonary infection in apparently healthy, immunocompetent rats. With this aim, local pulmonary response to intranasal inoculation of *A. fumigatus* conidia was evaluated by histological evaluation and by determining the number of germinating spores in lung tissue homogenates. The state of peripheral blood leukocytes was evaluated to monitor the presence of systemic response.

## MATERIALS AND METODS

Conventionally housed Dark Agouti (DA) male rats, bred at the Institute for Biological Research "Siniša Stanković" were used. Animal treatment has been carried out in adherence with the Ethical Committee of Institute for Biological Research "Siniša Stanković".

Human isolate *A. fumigatus* Fresenius (Institute of Public Health of Serbia "Dr Milan Jovanović Batut") was subcultured on standard mycology slant. Inoculum was prepared by flooding the surface of agar slants with sterile 0,85% of NaCl/0,1% of Tween 80. The suspension containing  $10^6$  and  $10^7$  conidia was applied intranasally, which reflects the natural route of *Aspergillus* infection in humans. The animals were assigned to two groups and sacrificed on days 7 and 21, following the inoculation.

Blood was collected (in citrate buffer 1:5 as anticoagulant) for counting peripheral blood leukocytes and leukocyte adhesion/aggregation assay (LAA). Cell counts were performed by differentiating 500 cells from blood smears stained with May-Grünwald-Giemsa.

Following exsanguination lung lobes were removed. One of the lobes was fixed in 4% of buffered formaline (pH 6.9), embedded in paraffin and 5mm sections were stained with hematoxylin and eosin for histopathological examination. The other was homogenized (in 1ml PBS/PMSF) in order to check the presence of *Aspergillus* by standard mycological identification method (Sabouraud Maltose Agar, SMA, medium) and micromycete identification. Homogenates were prepared in PBS (1:1 and 1:2) and seeded on solid (SMA) and liquid medium for quantitation of germinating and non-germinating spores.

Statistical evaluation of the data was performed using the Student's *t*-test. *P* values less than 0.05 were considered significant.

## RESULTS

In this study, histological data revealed the presence of local pulmonary response 7 days after the inoculation at both doses: predominance of lymphocytes perivascularly and in vascular lumen with increased bronchial secretion and tickened interstitium. No histologically evident changes were noted 21 days following the inoculation. Histopathological changes in lungs were presented in Figure 1.




Fig. 1 — Histological picture of lungs from rats following application of  $10^7$  spores of *A. fumigatus* (A) and healthy (immunocompetent) animal (B)

Application of *A. fumigatus* led to increased, but not statistically significant dose dependent on peripheral blood leukocyte activity (adhesion and aggregation) 7 days following the inoculation. No such changes were noted on day 21 following the infection. There were no differences in total and differential peripheral blood leukocyte numbers between the control and the inoculated animals.

Mycological evaluation of lung homogenates documented the presence of both germinating and non-germinating spores of *A. fumigatus* in all rats, excluding the controls. On day seven, significant number of non-germinating spores was noted at both applied doses of conidia (Figure 2). On day 21, numbers of non-germinating conidia increased further in group of animals which received  $10^6$  conidia, while rise in germinating spores was noted in individuals challenged with  $10^7$  conidia.

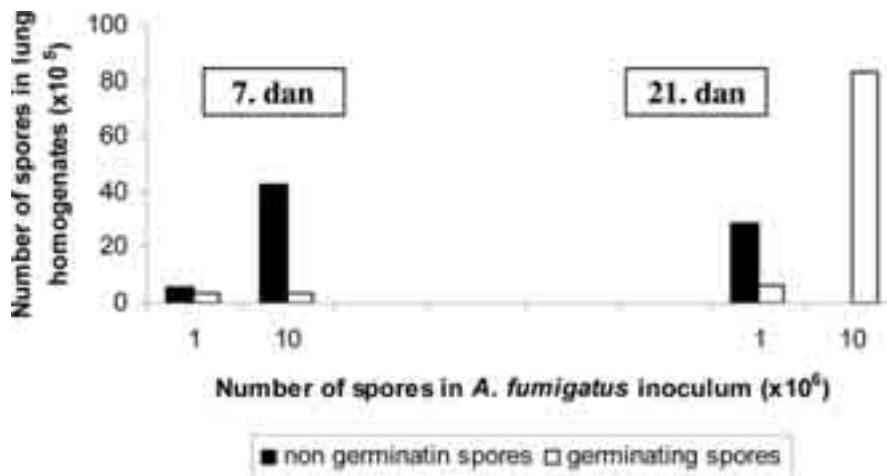


Fig. 2 — Number of spores in lung homogenates on Sabouraud Maltose Agar medium 7 and 21 days following *A. fumigatus* inoculation

## DISCUSSION

The increased number of non-germinating spores, on day seven, in lung homogenates at both conidia doses, and on day 21 at lower dose, could be explained by the presence of lymphocytes in cell infiltrate in lungs and their activity *in situ*. The presence of increased number of germinating conidia at higher dose on day 21 reflects, presumably, the capacity of small fraction of spores to germinate later in lung microenvironment. Investigation of possibility to over-ride local immune mechanisms deserves future attention.

Although no quantitative changes were noted in peripheral blood leukocytes, qualitative changes were noted. Increased state of leukocyte aggregation/adhesion (LAA) suggest that local leukocyte lung response was accompanied by systemic response as well.

## CONCLUSION

The presented data demonstrated histologically evident lung immune response following intranasal *A. fumigatus* conidia inoculation. This response is a possible mechanism of decreased numbers of germinating conidia at lower applied conidia dose.

## ACKNOWLEDGEMENTS

This study was supported by the Ministry of Science and Environmental protection, Grant# 143038

## REFERENCES

- Denning, W. David (1998): *Invasive Aspergillosis*, *Clinical Infectious Diseases* 26: 781—805.
- Latge, J. P. (1999): *Aspergillus fumigatus and aspergillosis*, *Clin Microbiol Rev* 12(2): 310—350.
- Romani, L. (2004): *Immunity to fungal infections*, *Nature Rev Immunol* 4: 11—23.
- Shibuya, K., Ando, T., Hasegawa, C., Wakayama, M., Hamatani, S., Hatori, T., Nagayama, T., Nonaka, H. (2004): *Pathophysiology of pulmonary aspergillosis*, *J Infect Chemother* 10: 138—145.
- Tarrand, J. J., Han, X. Y., Kontoyiannis, D. P., May, G. S. (2004): *Aspergillus hyphae in infected tissue: Evidence of physiologic adaptation and effect on culture recovery*, *J Clin Microbiol* 43(1): 382—386.

### КАРАКТЕРИСТИКЕ ЛОКАЛНОГ ОДГОВОРА У ПЛУЋИМА ПАЦОВА НАКОН ИНТРАНАЗАЛНЕ АПЛИКАЦИЈЕ КОНИДИЈА *ASPERGILLUS FUMIGATUS*

Јелена С. Живановић<sup>1</sup>, Марина Д. Соковић<sup>1</sup>,  
Јасмина М. Гламочлија<sup>1</sup>, Лидија Д. Золотаревски<sup>3</sup>,  
Милена В. Катарановски<sup>1, 2</sup>, Драган С. Катарановски<sup>1, 2</sup>

<sup>1</sup> Институт за биолошка истраживања „Синиша Станковић”,  
Булевар деспота Стефана 142, Београд, Србија

<sup>2</sup> Факултет за биологију, Универзитет у Београду,  
Студентски трг 16, Београд, Србија

<sup>3</sup> Војно-медицинска академија, Црнотравска 17, Београд, Србија

#### Резиме

*Aspergillus fumigatus* је опортунистичка гљива која најчешће доводи до пулмонарних аспергилоза код имунокомпромитованих организама. У овом раду су приказани резултати истраживања изазивања инфекције аспергилусом код пацова. У циљу добијања података о присуству и карактеристикама локалног инфламаторног одговора у плућима одређен је диференцијални састав леукоцита периферне крви и тестирана је њихова активност, извршени су хистопатолошки преглед плућа и провера присуства спора *A. fumigatus* у хомогенатима плућа. Наши подаци су показали присуство локалног одговора у плућима после 7 дана, док подаци добијени после 21 дан не показују значајне разлике у односу на контролну групу. Повећани број неклијајућих спора у хомогенату плућа седмог дана након инокулације може да се објасни присуством лимфоцитног инфилтрата у плућима и активношћу лимфоцита *in situ*. Повећан број клијајућих спора 21. дана након инокулације може да буде последица капацитета малог броја преосталих спора да клијају.