

University of Groningen

Unilateral Maxillary First Molar Extraction in Class II Subdivision

Booij, J. W.; Livas, Christos

Published in:
Case reports in dentistry

DOI:
[10.1155/2016/2168367](https://doi.org/10.1155/2016/2168367)

IMPORTANT NOTE: You are advised to consult the publisher's version (publisher's PDF) if you wish to cite from it. Please check the document version below.

Document Version
Publisher's PDF, also known as Version of record

Publication date:
2016

[Link to publication in University of Groningen/UMCG research database](#)

Citation for published version (APA):

Booij, J. W., & Livas, C. (2016). Unilateral Maxillary First Molar Extraction in Class II Subdivision: An Unconventional Treatment Alternative. Case reports in dentistry, [2168367].
<https://doi.org/10.1155/2016/2168367>

Copyright

Other than for strictly personal use, it is not permitted to download or to forward/distribute the text or part of it without the consent of the author(s) and/or copyright holder(s), unless the work is under an open content license (like Creative Commons).

Take-down policy

If you believe that this document breaches copyright please contact us providing details, and we will remove access to the work immediately and investigate your claim.

Downloaded from the University of Groningen/UMCG research database (Pure): <http://www.rug.nl/research/portal>. For technical reasons the number of authors shown on this cover page is limited to 10 maximum.

Case Report

Unilateral Maxillary First Molar Extraction in Class II Subdivision: An Unconventional Treatment Alternative

J. W. Booij¹ and Christos Livas²

¹Private Practice, Schelluinsevljet 5, 4203 NB Gorinchem, Netherlands

²Department of Orthodontics, University of Groningen, University Medical Center Groningen, Hanzeplein 1, Triadegebouw, Ingang 24, 9700 RB Groningen, Netherlands

Correspondence should be addressed to Christos Livas; c.livas@umcg.nl

Received 9 December 2015; Accepted 28 March 2016

Academic Editor: Gilberto Sammartino

Copyright © 2016 J. W. Booij and C. Livas. This is an open access article distributed under the Creative Commons Attribution License, which permits unrestricted use, distribution, and reproduction in any medium, provided the original work is properly cited.

The asymmetrical intra-arch relationship in Class II subdivision malocclusion poses challenges in the treatment planning and mechanotherapy of such cases. This case report demonstrates a treatment technique engaging unilateral extraction of a maxillary first molar and Begg fixed appliances. The outcome stability and the enhancing effect on the eruption of the third molar in the extraction segment were confirmed by a 4-year follow-up examination.

1. Introduction

Class II subdivision malocclusion is a dentofacial deformity, estimated to account for up to 50% of Class II malocclusions [1]. It possesses characteristics of both Class I and Class II malocclusion resulting in asymmetry between the right and the left sides of the dentition. Depending on the location of asymmetry, unilateral mechanics is performed to achieve distalization of the mesially positioned maxillary first molar or protraction of the opposing segment. Asymmetrical head-gear, coil springs coupled with Class II elastics or TADs [2], fixed functional appliances [3], or asymmetrical premolar extraction patterns [4, 5] are commonly applied in growing patients to correct the Class II occlusion on the affected side.

A less typical treatment strategy combining single extraction of a maxillary first molar and Begg light-wire appliances showed favourable outcomes in terms of occlusion, facial profile, and midline esthetics on average in 2.5 years after appliance removal [6].

This case report describes the orthodontic management of a Class II subdivision patient treated with the abovementioned protocol.

2. Case Report

A 14-year-old female was diagnosed with Class II subdivision malocclusion on the right side and a maxillary-to-facial midline discrepancy of 2 mm (Figures 1 and 2). During the intake, the patient expressed her concerns in complying with extraoral anchorage devices, cumbersome orthodontic accessories, or intermaxillary elastics for a long period. Clinical examination revealed fully erupted maxillary second molars and persistent 55, 74, and 75. With the exception of 48, no tooth agenesis was confirmed by the orthopantomogram (Figure 3). To meet the patient's demands, extraction of the right maxillary first molar was proposed instead.

Before extracting 16 and persistent deciduous molars, bands with 6 mm single 0.022-inch round buccal tubes and palatal sheaths were placed on 17 and 26. After a healing period of 3 weeks, Begg brackets were placed on the anterior maxillary and mandibular teeth. To prevent second molar rotation, a transpalatal arch (TPA) was inserted. Second molar anchorage was reinforced by anchor bends on a customized 0.016-inch premium plus pull-straightened Australian archwire (Wilcock, Whittlesea, Australia) mesial of

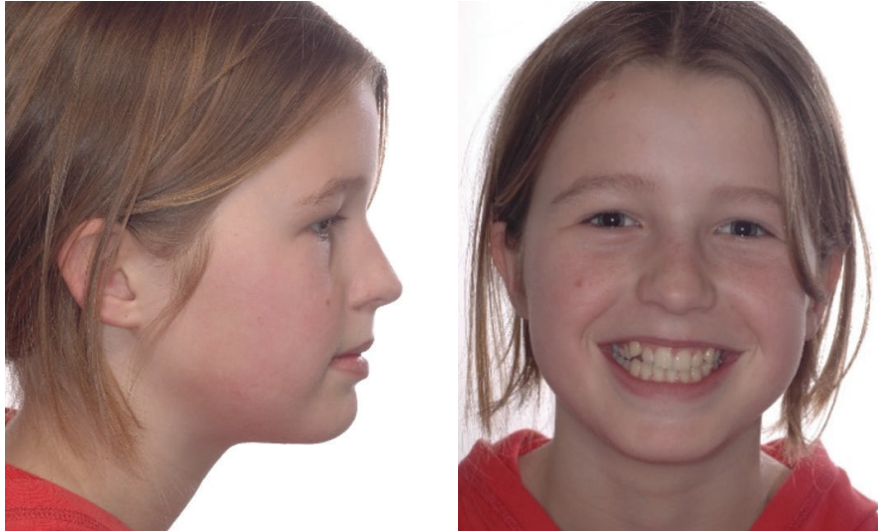

FIGURE 1: Pretreatment extraoral photographs.

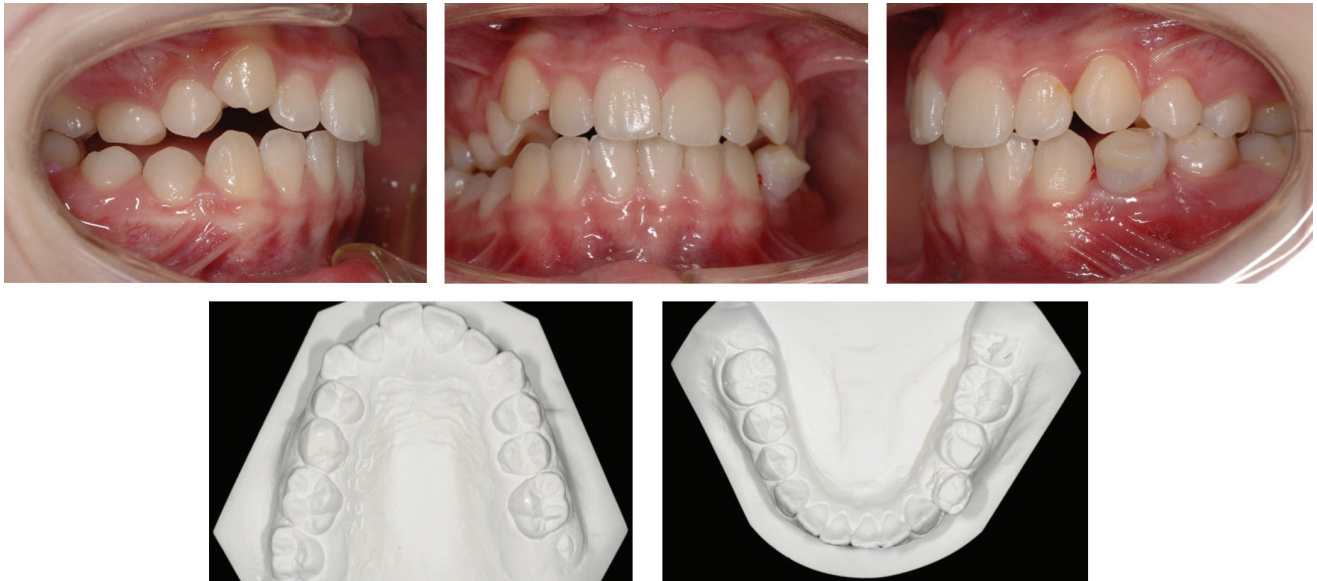

FIGURE 2: Pretreatment intraoral photographs and study casts (occlusal view).

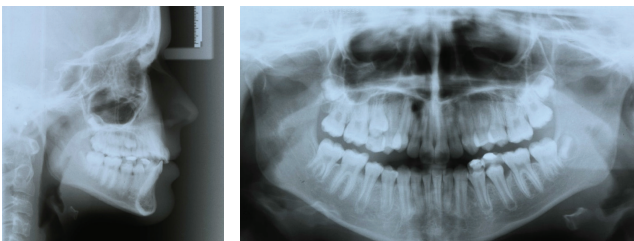


FIGURE 3: Pretreatment radiographs.

the molar tube to counteract unwanted mesial movement of 16 into the extraction space (Figure 4(a)). High hat lock pins (TP Orthodontics, Westville, IN, USA) were placed

on maxillary canines and partially bent mesially to receive light 8 mm horizontal elastics (5/16 inches) on the Class II buccal segment extending to the buccal hook on the maxillary second molar band (Figures 4(a)–4(c)). The patient was instructed to replace the Class I elastics on a weekly basis. By bending circle-shaped loops mesial to the canine brackets, controlled retraction of the anterior teeth was achieved. Visits were scheduled 6- to 8-week intervals. The initially malpositioned 12 was engaged to the archwire until adequate space had been created by canine distalization (Figures 4(b) and 4(c)). After 6 months, Class I premolar occlusion was achieved, the premolars were also bonded with light-wire brackets, and Class II elastic wear was instructed for nighttime. After alignment of the maxillary premolars, the 0.016-inch starting wire was replaced by a 0.018-inch premium

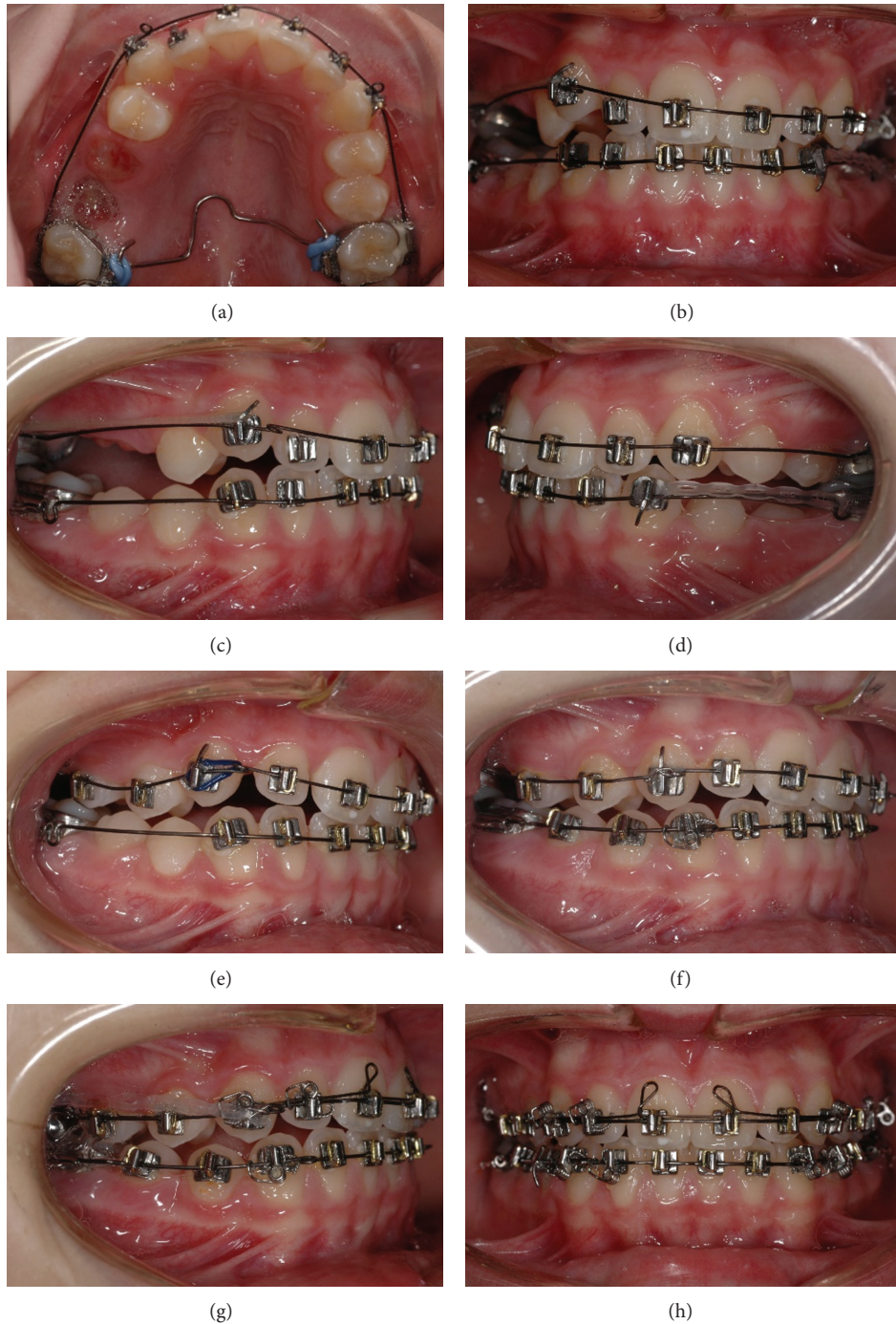


FIGURE 4: (a–d) Class II correction on the right side using TPA anchorage and horizontal elastics. In this phase, premolars were not bonded to facilitate sliding mechanics. (e–f) After achieving Class I premolar relationship, the remaining teeth were bonded. (g) Space closure with elastic power chain. (g, h) Torque correction by means of a customized two-spur torque auxiliary of 0.014-inch regular wire and uprighting springs on the maxillary canine brackets.

plus archwire (Wilcock). Additionally, an individual two-spur torque auxiliary of 0.014-inch regular wire (Wilcock) was inserted in the anterior maxillary region to produce proper palatal root torque. For the same reason, uprighting springs (TP, La Porte, Indiana, USA) were fixed in the vertical slots of the canine brackets (Figures 4(g) and 4(h)). Closure of

the residual extraction spaces in the maxillary right buccal segment was carried out with elastic power chains. In the final treatment stage, adjustments were made in the archwires and uprighting springs independently for each tooth for detailed finishing. Completing treatment, canine-to-canine retainers made of multistranded wire were bonded in both arches.



FIGURE 5: Posttreatment extraoral photographs.

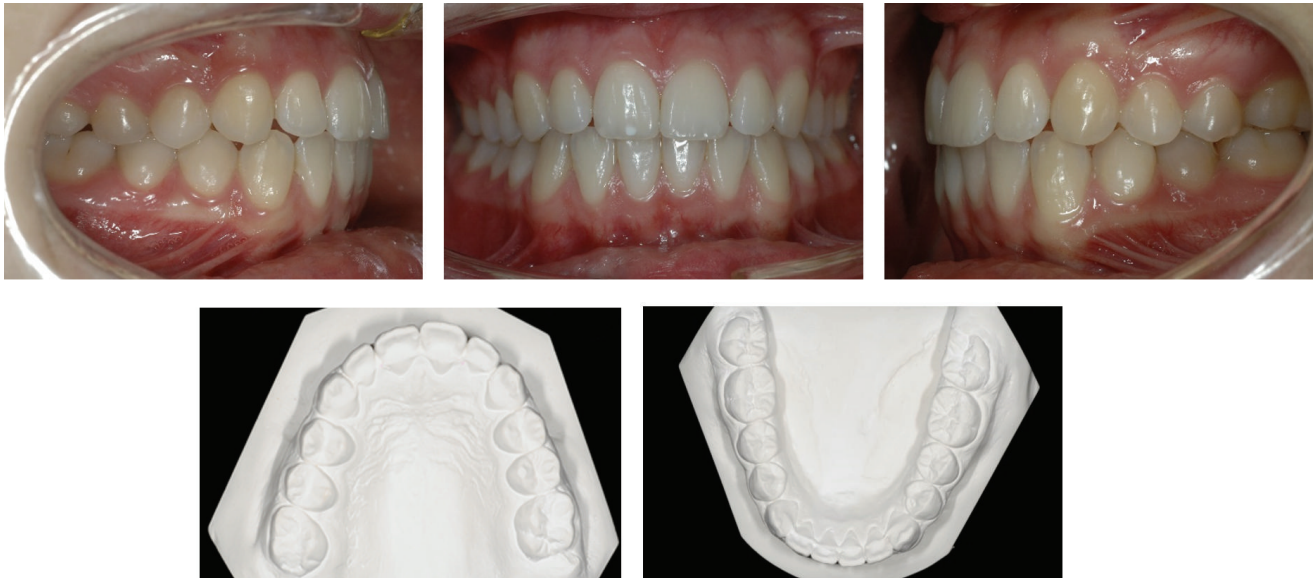

FIGURE 6: Posttreatment intraoral photographs and study casts (occlusal view).

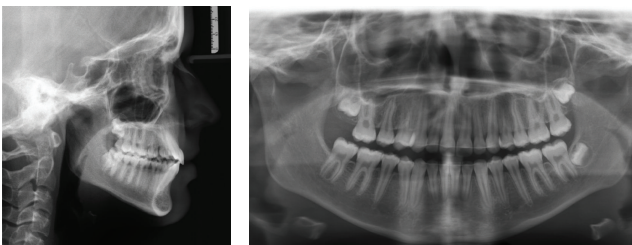


FIGURE 7: Posttreatment radiographs.

The active treatment lasted 26 months. Class I occlusion, tooth alignment, and midline correction were maintained for 4 years after appliance removal (Figures 6 and 9). Anterior

tooth retraction did not compromise the soft tissue profile (Figures 5 and 8). Eruption of 18 was accelerated reaching occlusal contact with the antagonist, while the contralateral molar remained unerupted (Figures 7 and 10).

3. Discussion

Our Class II subdivision technique led to good occlusal and esthetic outcomes, which were preserved for 4 years after active treatment had been completed. Besides stable end results in the long term [6], a positive effect on the axial inclination of maxillary third molars was demonstrated in Class II subdivision cases treated with unilateral maxillary first molar extraction and low friction fixed appliances [7]. Maxillary third molars in the extraction side became 3.1–3.4



FIGURE 8: Four-year follow-up extraoral photographs.

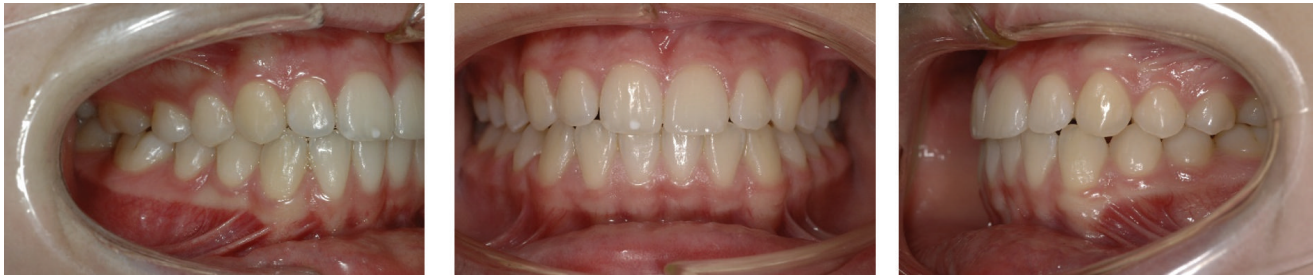

FIGURE 9: Four-year follow-up intraoral photographs.

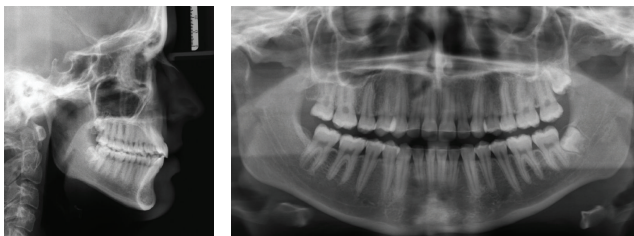


FIGURE 10: Four-year follow-up radiographs.

times more upright than the contralateral teeth [7]. Likewise in this case report, eruption of the maxillary third molar in the extraction segment was strikingly enhanced.

Patient cooperation was restricted to oral hygiene measures and once-per-week replacement of elastics, which may render this method suitable for patients with poor compliance [8]. Modification of this treatment method with bilateral extraction of maxillary first molars has been previously described as “less-compliance therapy” [8].

Longer treatment duration has been observed in asymmetric premolar extraction protocols [4, 5] compared to orthodontic therapy with either unilateral maxillary first molar extraction [6] or Herbst and fixed appliances [3].

Nonetheless, with respect to the end molar occlusion, Class III in the original Class I side may be expected in Class II subdivision patients treated with fixed functional appliances [3].

Without doubt, the popularity of Begg or similar techniques declined dramatically during the last 30 years [9]. However, orthodontic mechanics including application of light elastic forces, anchorage bends, or delayed bonding of premolars during space closure may be integrated in the philosophy of contemporary straight-wire techniques.

Premolar extraction schemes are prescribed by orthodontists in the United States in 85% of extraction cases [9]. From the ethical point of view, a decision to electively extract healthy premolar teeth for orthodontic purposes may not be warranted in cases with compromised first molars. As a general rule, presence of extensive caries lesions, large restorations, endodontic or periodontal problems, or hypoplastic enamel should be taken into account when extraction treatment has been chosen. The first permanent molar has the shortest caries-free survival under the age of 8 years [10]. It also represents the most caries prone tooth in children older than 11 years [11]. In addition to this, first molars can suffer from developmental enamel hypomineralisation of unknown aetiology often affecting permanent incisors. Lately published rates vary between 4.2 and 21.4% depending on the country

and examination method [12–14]. Prognosis of endodontics in multirrooted teeth may be also questionable. In this context, the first molar has been reported as the most commonly extracted tooth due to endodontic complications [15]. Under such circumstances and in presence of fully erupted maxillary second molars, well-formed third molar at the Class II buccal segment, maxillary dental asymmetry, and fairly aligned mandibular arch, extraction of a maxillary first molar may be a viable option in treating asymmetrical Class II malocclusion cases.

4. Conclusion

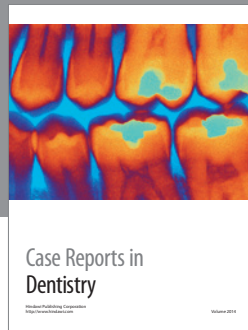
This 4-year follow-up case report indicates that unilateral extraction of a maxillary first molar in selected cases might be a rewarding treatment alternative in Class II subdivision subjects and especially in those with compliance issues.

Competing Interests

The authors declare that they have no competing interests.

References

- [1] D. A. Sanders, P. H. Rigali, W. P. Neace, F. Uribe, and R. Nanda, "Skeletal and dental asymmetries in Class II subdivision malocclusions using cone-beam computed tomography," *American Journal of Orthodontics and Dentofacial Orthopedics*, vol. 138, no. 5, pp. 542.e1–542.e20, 2010.
- [2] C. Livas, "Mini-implant anchorage in a unilateral Class II patient," *Journal of Clinical Orthodontics*, vol. 46, no. 5, pp. 293–298, 2012.
- [3] N. C. Bock, B. Reiser, and S. Ruf, "Class II subdivision treatment with the Herbst appliance," *The Angle Orthodontist*, vol. 83, no. 2, pp. 327–333, 2013.
- [4] G. Janson, E. A. Dainesi, J. F. C. Henriques, M. R. de Freitas, and K. J. R. S. de Lima, "Class II subdivision treatment success rate with symmetric and asymmetric extraction protocols," *American Journal of Orthodontics and Dentofacial Orthopedics*, vol. 124, no. 3, pp. 257–264, 2003.
- [5] G. Janson, N. C. Branco, J. F. Morais, and M. R. Freitas, "Smile attractiveness in patients with Class II division 1 subdivision malocclusions treated with different tooth extraction protocols," *European Journal of Orthodontics*, vol. 36, no. 1, pp. 1–8, 2014.
- [6] C. Livas, N. Pandis, J. W. Booij, C. Katsaros, and Y. Ren, "Long-term evaluation of Class II subdivision treatment with unilateral maxillary first molar extraction," *The Angle Orthodontist*, vol. 85, no. 5, pp. 757–763, 2015.
- [7] C. Livas, N. Pandis, J. W. Booij, D. J. Halazonetis, C. Katsaros, and Y. Ren, "Influence of unilateral maxillary first molar extraction treatment on second and third molar inclination in Class II subdivision patients," *The Angle Orthodontist*, vol. 86, no. 1, pp. 94–100, 2016.
- [8] J. W. Booij, A. M. Kuijpers-Jagtman, and C. Katsaros, "A treatment method for Class II division 1 patients with extraction of permanent maxillary first molars," *World Journal of Orthodontics*, vol. 10, no. 1, pp. 41–48, 2009.
- [9] R. G. Keim, E. L. Gottlieb, D. S. Vogels, and P. B. Vogels, "2014 JCO study of orthodontic diagnosis and treatment procedures. Part I. results and trends," *Journal of Clinical Orthodontics*, vol. 48, no. 10, pp. 607–630, 2014.
- [10] J. E. Todd and T. Dodd, "Children's dental health in the United Kingdom 1983: a survey carried out by the social survey division of OPCS, On behalf of the United Kingdom health departments," in *Collaboration with the Dental Schools of the Universities of Birmingham and Newcastle Editions*, Stationery Office, 1st edition, 1985.
- [11] J. Suni, H. Vähänikkilä, J. Pääkilä, L. Tjäderhane, and M. Larmas, "Review of 36,537 patient records for tooth health and longevity of dental restorations," *Caries Research*, vol. 47, no. 4, pp. 309–317, 2013.
- [12] R. Balmer, J. Toumba, J. Godson, and M. Duggal, "The prevalence of molar incisor hypomineralisation in Northern England and its relationship to socioeconomic status and water fluoridation," *International Journal of Paediatric Dentistry*, vol. 22, no. 4, pp. 250–257, 2012.
- [13] T. P. Martínez Gómez, F. Guinot Jimeno, L. J. Bellet Dalmau, and L. Giner Tarrida, "Prevalence of molar-incisor hypomineralisation observed using transillumination in a group of children from Barcelona (Spain)," *International Journal of Paediatric Dentistry*, vol. 22, no. 2, pp. 100–109, 2012.
- [14] M. Grošelj and J. Jan, "Molar incisor hypomineralisation and dental caries among children in Slovenia," *European Journal of Paediatric Dentistry*, vol. 14, no. 3, pp. 241–245, 2013.
- [15] N. E. Tzimpoulas, M. G. Alisafis, G. N. Tzanetakis, and E. G. Kontakiotis, "A prospective study of the extraction and retention incidence of endodontically treated teeth with uncertain prognosis after endodontic referral," *Journal of Endodontics*, vol. 38, no. 10, pp. 1326–1329, 2012.



Hindawi
Submit your manuscripts at
<http://www.hindawi.com>

