

University of Groningen

## Covering of an exposed vascular graft in the groin with an external oblique muscle rotational flap

Vierhout, Bastiaan P.; Smit, Jeroen M.; Zeebregts, Clark J.

*Published in:*  
Journal of surgical case reports

*DOI:*  
[10.1093/jscr/rjx009](https://doi.org/10.1093/jscr/rjx009)

**IMPORTANT NOTE: You are advised to consult the publisher's version (publisher's PDF) if you wish to cite from it. Please check the document version below.**

*Document Version*  
Publisher's PDF, also known as Version of record

*Publication date:*  
2017

[Link to publication in University of Groningen/UMCG research database](#)

*Citation for published version (APA):*

Vierhout, B. P., Smit, J. M., & Zeebregts, C. J. (2017). Covering of an exposed vascular graft in the groin with an external oblique muscle rotational flap. *Journal of surgical case reports*, 2017(2).  
<https://doi.org/10.1093/jscr/rjx009>

**Copyright**

Other than for strictly personal use, it is not permitted to download or to forward/distribute the text or part of it without the consent of the author(s) and/or copyright holder(s), unless the work is under an open content license (like Creative Commons).

**Take-down policy**

If you believe that this document breaches copyright please contact us providing details, and we will remove access to the work immediately and investigate your claim.

*Downloaded from the University of Groningen/UMCG research database (Pure): <http://www.rug.nl/research/portal>. For technical reasons the number of authors shown on this cover page is limited to 10 maximum.*

## CASE REPORT

# Covering of an exposed vascular graft in the groin with an external oblique muscle rotational flap

Bastiaan P. Vierhout<sup>1,\*</sup>, Jeroen M. Smit<sup>2</sup>, and Clark J. Zeebregts<sup>3</sup><sup>1</sup>Department of Surgery, Wilhelmina Hospital Assen, Europaweg-Zuid 1, 9400RA Assen, The Netherlands,<sup>2</sup>Department of Plastic Surgery, Catharina Hospital, 5602 ZA Eindhoven, The Netherlands, and <sup>3</sup>Department of Surgery (Division of Vascular Surgery), University Medical Center Groningen, University of Groningen, 9700RB Groningen, The Netherlands

\*Correspondence address. Department of Surgery, Wilhelmina Hospital Assen, Europaweg-Zuid 1, 9400 RA Assen, The Netherlands. Tel: +31-592-325-443; Fax: +31-592-325-307; E-mail: bas.vierhout@wza.nl

## Abstract

Abdominal muscles, such as the oblique- and transverse muscles, find their blood supply from multiple segmental pedicles from the iliac artery. Besides its superior vascularization, its release is simple, leaving two abdominal muscles for securing abdominal wall strength. The release of the muscle and coverage of the graft requires partial muscle mobilization and is a minor reconstruction, but extension of the mobilization cranially enables coverage of larger defects. We present a case of an infected vascular graft in the groin successfully preserved through coverage with an external oblique muscle flap.

## INTRODUCTION

Vascular graft salvage is successfully manageable with a muscle flap, following wound debridement and targeted antimicrobial therapy, in 78–84% of groin infections [1–3]. In this context, four types of flaps have been described, including transposition of the sartorius muscle [4, 5], the gracilis muscle [5, 6], the rectus abdominis and rectus femoris muscle [5]. In complicated cases these flaps may, however, not be feasible because of previous use or a compromised vascular supply as their pedicle is distally from the groin. We report a case in which the external oblique muscle was used to salvage an infected vascular graft.

## CASE REPORT

An 81-year-old woman, who had been given an aortobifemoral Dacron prosthesis in 2007 for occlusive aortoiliac disease, was seen at our clinic with a persisting medial malleolar wound in September 2014. The wound was the result of a fall 2 months

earlier. Thrombosis of the left iliac part of the aorta-bifemoral graft explained the insufficient healing. An unsuccessful attempt to recanalize the graft percutaneously required a reconstruction with a femoro-femoral crossover bypass in October 2014. She recovered well from this procedure and was discharged home 9 days later.

She was readmitted after blood loss had occurred from her right groin, 6 weeks after the crossover operation. Because of the risk of exsanguination due to anastomotic rupture, an emergency exploration was performed and showed incorporation of the largest part of the graft with surrounding tissue. An infected hematoma in contact with the graft was found at the anterior side of her right quadriceps muscle. This low-grade infection must have been there since the first operation. The hematoma was removed and the wound was irrigated with povidone iodine. The sartorius muscle was proximally released and the proximal part of the graft was covered. Subcutaneous tissue was closed with a running absorbable suture (Polysorb 3-0, Covidien, Mansfield, USA) and the skin was left open (Fig. 1). Vacuum-assisted closure

Received: November 17, 2016. Accepted: January 13, 2017

Published by Oxford University Press and JSCR Publishing Ltd. All rights reserved. © The Author 2017.

This is an Open Access article distributed under the terms of the Creative Commons Attribution Non-Commercial License (<http://creativecommons.org/licenses/by-nc/4.0/>), which permits non-commercial re-use, distribution, and reproduction in any medium, provided the original work is properly cited. For commercial re-use, please contact [journals.permissions@oup.com](mailto:journals.permissions@oup.com)

(VAC) (KCI Medical, San Antonio, USA) therapy was started immediately postoperatively.

Bacterial culture confirmed infection with aerobic- and anaerobic bacteria (*Proteus vulgaris*, *Citrobacter koseri* and *Bacteroides fragilis*). In line with the sensitivity of these microorganisms, treatment was started with Piperacilline/Tazobactam. Duplex ultrasound examination 1 week later showed a patent bypass and computed tomography 10 days thereafter did not show any fluid surrounding the graft. White blood cell count remained normal, and C-reactive protein (CRP) dropped from 111 mg/l to 52 mg/l after 2 months. However, a recurrent hematoma developed distally from the wound in the right groin.

Subsequently, a re-exploration of the right groin was performed. The hematoma did not seem macroscopically infected; it was drained through the previous incision and through a new incision laterally, thus diverting the infection away from the graft. The wounds were left open.

Anticoagulation for atrial fibrillation was temporarily interrupted, but the wound did not heal well and CRP rose to 224 mg/l. A third exploration was performed 3 days later and again the remainder of a hematoma was removed. A part of the graft was not covered by the sartorius muscle. In a second attempt to cover the graft, the external oblique muscle was released medially from the linea alba and rotated laterally and caudally, into the groin (Fig. 2).

VAC-therapy was continued after application in the operating theater. Granulating tissue showed better vascularization 3 days thereafter, and again CRP dropped to 42 mg/l (Fig. 3). Bacterial cultures showed the presence of *enterococcus faecalis* bacteria and antibiotics were changed to amoxicillin with clavulanic acid, combined with ciprofloxacin and was continued for 6 weeks.

The patient was discharged home 6 days postoperatively and VAC-therapy was continued for 2 months, partially at home. The wound was closed and antibiotics were discontinued.

Fourteen months after wound closure the patient was well and walked small distances. She had a completely healed groin

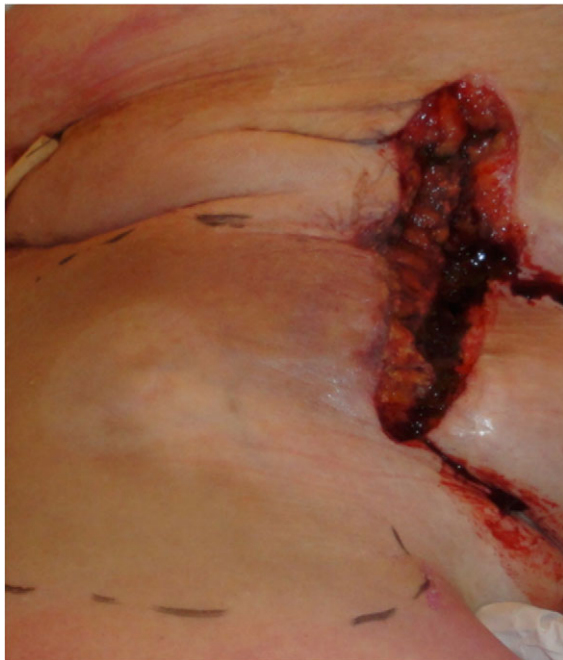

Figure 1: Macroscopic appearance after draining the hematoma and muscle transposition of the sartorius muscle.

(Fig. 4) and the distal wound at the left lateral malleolus healed nicely.

## DISCUSSION

This report indicates that in complicated cases coverage of an infected vascular graft in the groin with the external oblique

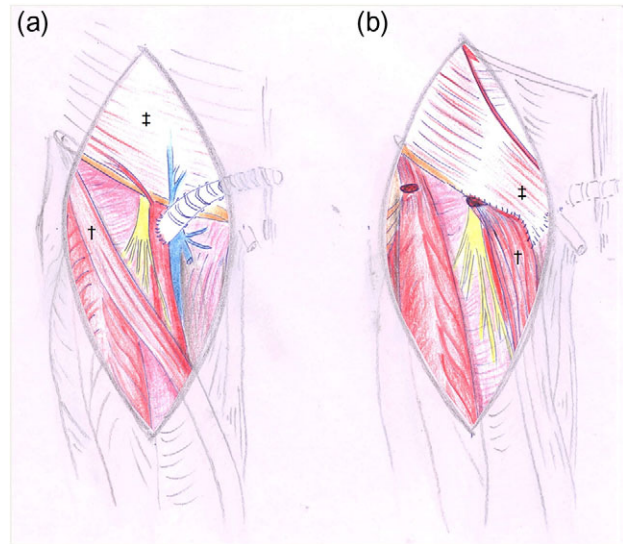


Figure 2: Drawings before (a) and after (b) reconstruction with sartorius†- and oblique external‡ flap.

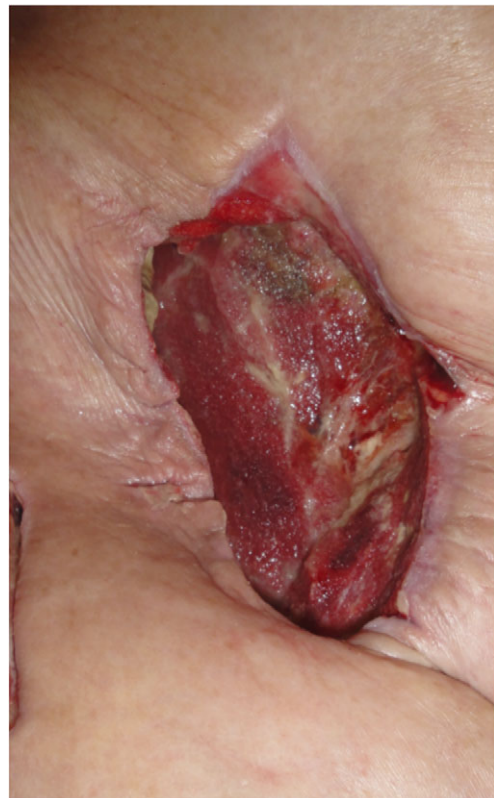

Figure 3: Appearance of the wound after removal of negative pressure, 4 days after the oblique external flap.

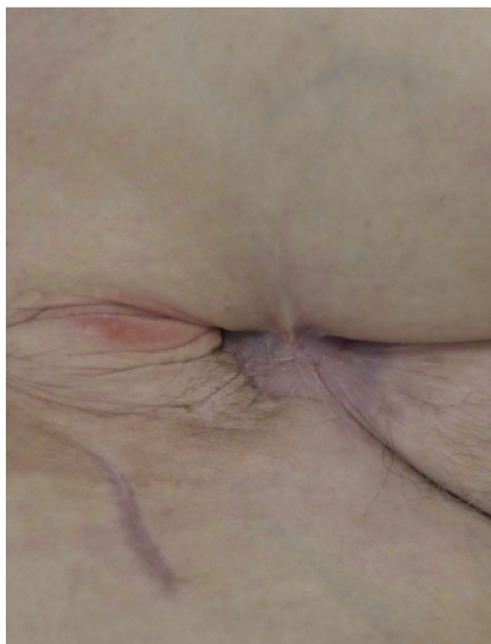

Figure 4: Approximately half a year post oblique flap; the wound is fully healed without a fistula.

muscle flap can help preserve the graft and assist in wound closure. The external oblique muscle is a Type V muscle with both dominant and multiple segmental vascular pedicles [7]. The dominant pedicles are one or two branches of either the deep circumflex iliac artery (94.7%) or the iliolumbar artery (5.3%) [8]. The segmental vascular supply is derived from the 5th through 12th posterior intercostal arteries. The use of the external oblique muscle has predominantly been described for chest wall reconstruction [9].

Advantages that the external oblique muscle flap offers are its simple release and its lateral vascularization, facilitating rotation. Even though it is a very thin muscle, it seems to have the ability to grow in an infected environment to form a large bulky protection of the synthetic bypasses. Three days after muscle rotation, the wound of our patient had significantly improved. The vascularization of the external oblique muscle and the non-smoking status of the patient contributed to the favorable outcome [10].

Because of the extension of the external oblique muscle cranially, further mobilization is possible, thus enabling coverage of larger areas in the infected groin.

One other advantage may be derived from its cranial position and its blood supply; the viability of the flap does not depend on the vascularization through a (infected) bypass graft, as is the case in sartorius-, rectus femoris- and gracilis flaps. Also, its blood supply is not dependent on the epigastric artery, essential for rectus femoris flaps. This epigastric/mammary artery is often used in coronary artery bypass surgery (CABG) in patients with peripheral artery disease.

To the best of our knowledge, external oblique muscle coverage of a vascular graft has not been described previously and is a feasible, effective, technically simple and safe procedure. It is an

attractive option in complicated cases, in which previous muscle transpositions were unsuccessful. It can cover large vascular grafts in the groin, particular in patients with poor vascularization distally and in post-CABG patients. A larger series including functional long-term outcomes are required to confirm the above.

## FUNDING

None of the authors has a financial interest in any of the products, devices or drugs mentioned in this manuscript.

## ACKNOWLEDGEMENTS

We thank Paulien van Twuyver for proof reading and correcting the grammar and spelling in this article.

## REFERENCES

1. Fischer JP, Mirzabeigi MN, Sieber BA, Nelson JA, Wu LC, Kovach SJ, et al. Outcome analysis of 244 consecutive flaps for managing complex groin wounds. *Plast Reconstr Surg* 2013;**66**:1396–404.
2. Alkon JD, Smith A, Losee JE, Illig KA, Green RM, Serletti JM. Management of complex groin wounds: preferred use of the rectus femoris muscle flap. *Plast Reconstr Surg* 2005;**115**:776–83.
3. Landry GJ, Carlson JR, Liem TK, Mitchell EL, Edwards JM, Moneta GL. The sartorius muscle flap: an important adjunct for complicated femoral wounds involving vascular grafts. *Am J Surg* 2009;**197**:655–9.
4. Schutzer R, Hingorani A, Ascher E, Markevich N, Kallakuri S, Jacob T. Early transposition of the sartorius muscle for exposed patent infrainguinal bypass grafts. *Vasc Endovascular Surg* 2005;**39**:159–62.
5. Seify H, Moyer HR, Jones GE, Busquets A, Brown K, Salam A, et al. The role of muscle flaps in wound salvage after vascular graft infections: the Emory experience. *Plast Reconstr Surg* 2006;**117**:1325–33.
6. Morasch MD, Sam AD, Kibbe R, Hijjawi J, Dumanian GA. Early results with use of gracilis muscle flap coverage of infected groin wounds after vascular surgery. *J Vasc Surg* 2004;**39**:1277–83.
7. Mathes SJ, Nahai F. Classification of the vascular anatomy of muscles: experimental and clinical correlation. *Plast Reconstr Surg* 1981;**67**:177–87.
8. Schlenz I, Burggasser G, Kuzbari R, Eichberger H, Gruber H, Holle J. External oblique abdominal muscle: a new look on its blood supply and innervation. *Anat Rec* 1999;**255**:388–95.
9. Matros E, Disa JJ. Uncommon flaps for chest wall reconstruction. *Semin Plast Surg* 2011;**25**:55–9.
10. Cavallo JA, Roma AA, Jasielc MS, Ousley J, Creamer J, Pichert MD, et al. Remodeling characteristics and collagen distribution in synthetic mesh materials explanted from human subjects after abdominal wall reconstruction: an analysis of remodeling characteristics by patient risk factors and surgical site classifications. *Surg Endosc* 2014;**28**:1852–65.