

University of Groningen

## A Successful Approach to Kidney Transplantation in Patients With Enteric (Secondary) Hyperoxaluria

Roodnat, Joke I.; de Mik-van Egmond, Anneke M. E.; Visser, Wesley J.; Berger, Stefan P.; van der Meijden, Wilbert A. G.; Knauf, Felix; van Agteren, Madelon; Betjes, Michiel G. H.; Hoorn, Ewout J.

*Published in:*  
Transplantation direct

*DOI:*  
[10.1097/TXD.0000000000000748](https://doi.org/10.1097/TXD.0000000000000748)

**IMPORTANT NOTE: You are advised to consult the publisher's version (publisher's PDF) if you wish to cite from it. Please check the document version below.**

*Document Version*  
Publisher's PDF, also known as Version of record

*Publication date:*  
2017

[Link to publication in University of Groningen/UMCG research database](#)

*Citation for published version (APA):*

Roodnat, J. I., de Mik-van Egmond, A. M. E., Visser, W. J., Berger, S. P., van der Meijden, W. A. G., Knauf, F., ... Hoorn, E. J. (2017). A Successful Approach to Kidney Transplantation in Patients With Enteric (Secondary) Hyperoxaluria. *Transplantation direct*, 3(12), [331].  
<https://doi.org/10.1097/TXD.0000000000000748>

**Copyright**

Other than for strictly personal use, it is not permitted to download or to forward/distribute the text or part of it without the consent of the author(s) and/or copyright holder(s), unless the work is under an open content license (like Creative Commons).

**Take-down policy**

If you believe that this document breaches copyright please contact us providing details, and we will remove access to the work immediately and investigate your claim.

*Downloaded from the University of Groningen/UMCG research database (Pure): <http://www.rug.nl/research/portal>. For technical reasons the number of authors shown on this cover page is limited to 10 maximum.*

## OPEN

# A Successful Approach to Kidney Transplantation in Patients With Enteric (Secondary) Hyperoxaluria

Joke I. Roodnat, MD, PhD,<sup>1</sup> Anneke M. E. de Mik-van Egmond,<sup>2</sup> Wesley J. Visser,<sup>2</sup> Stefan P. Berger, MD, PhD,<sup>3</sup> Wilbert A. G. van der Meijden, MD,<sup>4</sup> Felix Knauf, MD,<sup>5</sup> Madelon van Agteren, MD,<sup>1</sup> Michiel G.H. Betjes, MD, PhD,<sup>1</sup> and Ewout J. Hoorn, MD, PhD<sup>1</sup>

**Background.** Enteric hyperoxaluria due to malabsorption may cause chronic oxalate nephropathy and lead to end-stage renal disease. Kidney transplantation is challenging given the risk of recurrent calcium-oxalate deposition and nephrolithiasis.

**Methods.** We established a protocol to reduce plasma oxalic acid levels peritransplantation based on reduced intake and increased removal of oxalate. The outcomes of 10 kidney transplantation patients using this protocol are reported. **Results.** Five patients received a living donor kidney and had immediate graft function. Five received a deceased donor kidney and had immediate (n = 1) or delayed graft function (n = 4). In patients with delayed graft function, the protocol was prolonged after transplantation. In 3 patients, our protocol was reinstated because of late complications affecting graft function. One patient with high-output stoma and relatively low oxalate levels had lost her first kidney transplant because of recurrent oxalate depositions but now receives intravenous fluid at home on a routine basis 3 times per week to prevent dehydration. Patients are currently between 3 and 32 months after transplantation and all have a stable estimated glomerular filtration rate (mean, 51 ± 21 mL/min per 1.73 m<sup>2</sup>). In 4 of 8 patients who underwent for cause biopsies after transplantation oxalate depositions were found. **Conclusions.** This is the first systematic description of kidney transplantation in a cohort of patients with enteric hyperoxaluria. Common complications after kidney transplantation impact long-term transplant function in these patients. With our protocol, kidney transplantation outcomes were favorable in this population with unfavorable transplantation prospects and even previous unsuccessful transplants.

(*Transplantation Direct* 2017;3: e331; doi: 10.1097/TXD.0000000000000748. Published online 8 November, 2017.)

Secondary or enteric hyperoxalemia leading to hyperoxaluria can be caused by several disorders including short-bowel syndrome,<sup>1</sup> pancreatic insufficiency,<sup>2</sup> gastric bypass surgery,<sup>3-5</sup> cystic fibrosis,<sup>6</sup> and celiac disease.<sup>7</sup> The common denominator in these disorders is fat malabsorption.

Free fatty acids complex with calcium, thereby hampering the formation of insoluble calcium-oxalate, leaving oxalic acid free to be absorbed.<sup>8</sup> In addition, both bile acids and free fatty acids increase the permeability of the intestinal mucosa to oxalic acid.<sup>9</sup> Oxalic acid is primarily absorbed in the

Received 5 August 2017. Revision requested 22 September 2017.

Accepted 23 September 2017.

<sup>1</sup> Division of Nephrology and Transplantation, Department of Internal Medicine, Erasmus Medical Center, Rotterdam, The Netherlands.

<sup>2</sup> Department of Dietetics, Erasmus Medical Center, Rotterdam, The Netherlands.

<sup>3</sup> Department of Internal Medicine, University Medical Center Groningen, The Netherlands.

<sup>4</sup> Department of Internal Medicine, Radboud University Medical Center, The Netherlands.

<sup>5</sup> Department of Nephrology and Hypertension, Friedrich-Alexander-Universität Erlangen-Nürnberg (FAU), Germany.

The authors declare no funding or conflicts of interest.

J.I.R. participated in the conception and design of the work, the acquisition, analysis, and interpretation of data for the work, drafting the work and writing of the article. A.M.E.d.M.-v.E. gave substantial contributions to the conception and design of the work, critically revising the work for important intellectual content. W.J.V. participated in the substantial contributions to the conception and design of the work, critically revising the work for important intellectual content. S.P.B. participated in the acquisition of data for the work, revising the work critically for important intellectual content. W.A.G.v.d.M. participated in the acquisition of data

for the work, revising the work critically for important intellectual content. F.K. participated in the interpretation of data for the work, revising the work critically for important intellectual content. M.v.A. participated in the design of the work, revising the work critically for important intellectual content. M.G.H.B. participated in the design of the work, revising the work critically for important intellectual content. E.J.H. participated in the design of the work and writing of the article, revising the work critically for important intellectual content. All authors gave their final approval of the version to be published and had an agreement to be accountable for all aspects of the work in ensuring that questions related to the accuracy or integrity of any part of the work are appropriately investigated and resolved.

Correspondence: Joke I. Roodnat, MD, PhD, Room D427, 3000 CA, PO Box 2040, Rotterdam, The Netherlands. (J.Roodnat@erasmusmc.nl).

Copyright © 2017 The Author(s). *Transplantation Direct*. Published by Wolters Kluwer Health, Inc. This is an open-access article distributed under the terms of the Creative Commons Attribution-Non Commercial-No Derivatives License 4.0 (CCBY-NC-ND), where it is permissible to download and share the work provided it is properly cited. The work cannot be changed in any way or used commercially without permission from the journal.

ISSN: 2373-8731

DOI: 10.1097/TXD.0000000000000748

colon. Therefore, patients with malabsorption but with intact colons are particularly prone to high oxalic acid levels.<sup>8</sup> As oxalic acid is eliminated by the kidney, another cause of high oxalic acid levels is chronic kidney disease.<sup>10</sup> Conversely, high concentrations of oxalic acid in combination with high calcium levels in the urine may cause calcium-oxalate deposition and stones. Treatment of patients with enteric hyperoxaluria with kidney stones and/or deteriorating kidney function should rely on restriction of oxalic acid intake, and avoidance of dehydration.<sup>11</sup> Dietary oxalic acid intake varies between 200 and 400 mg with excessive intakes up to 600 to 800 mg per day. Dietitians usually recommend avoiding oxalic acid rich foods, eg rhubarb (541 mg/125 g), spinach (755 mg/125 g), and almonds (122 mg per handful). This advice was not successful in patients with gastric bypasses.<sup>12</sup> In addition, patients are usually allowed to continue drinking tea, which contains 14 mg per cup and may, even in healthy individuals, lead to enteric hyperoxaluria and renal function decline when intake is excessive.<sup>13</sup> A diet limiting intake of oxalic acid to 30 to 50 mg per day was shown to reduce urine oxalate in patients with enteric hyperoxaluria.<sup>14</sup>

When native kidney function is lost because of enteric hyperoxaluria, it is even more difficult to preserve transplanted kidney function because the recurrence rate of calcium-oxalate crystal deposition and kidney stones is high, especially when no adequate measures are taken to decrease plasma and urine oxalic acid concentrations.<sup>15</sup> Recently, a review on the pathophysiology and scarce literature on therapy showed that there is no consensus on treatment of enteric hyperoxaluria.<sup>16</sup> We developed a protocol based on lowering plasma oxalic acid levels before and immediately after transplantation to lower the risk of recurrence (Table 1). We report our preliminary experience with this protocol in 10 patients with hyperoxaluria who underwent kidney transplantation.

## PATIENTS AND RESULTS

Between January 2014 and January 2016, 17 (3%) of 611 patients that presented for prekidney transplant evaluation had enteric hyperoxaluria. Six of these patients opted for a retransplant. Earlier transplantations had been performed before the implementation of the oxalate lowering protocol, and all but 1 transplants failed (0, 18 months, 2

and 3 years and 8 years after transplantation). The latter is 5 years after transplantation and used an oxalic acid limited diet on his own initiative since transplantation (present estimated glomerular filtration rate [eGFR], 20 mL/min). In all 6 patients, oxalate depositions were shown in the biopsy. Only 3 of 17 patients (2 with a former transplant) received nutritional counseling regarding prevention of hyperoxaluria before referral for transplantation.

Our center specializes in complex transplantation problems as part of our academic center of excellence.<sup>18</sup> Though challenging, after conscientious preparations and approval, well-informed and consenting secondary hyperoxaluria patients were accepted for transplantation. From the 17 patients with enteric hyperoxaluria 4 patients decided not to proceed with retransplantation because of fear of complications. One patient is currently awaiting kidney transplantation. Two patients have been prepared and are keeping low oxalic acid diet, but they TEMPORARILY are on a nontransplantable urgency because of comorbidity. Ten patients have been transplanted and are reported in more detail below and in Table 2. In 6 of the 10 transplanted patients with enteric hyperoxaluria, oxalate nephropathy or stones were identified in native or in former transplant kidneys, whereas in the remaining patients, enteric hyperoxaluria was considered probable, but not proven (patients 4, 8, 9, and 10).

Plasma oxalic acid levels were measured in these patients by capillary gas chromatography with a method modified according to Wolthers (upper normal level, 5  $\mu\text{mol/L}$ ).<sup>19</sup> Samples were taken during the patients' visit to the outpatient department (oxalic acid before diet) and pretransplantation. Oxalate concentration in 24-hour urine was measured enzymatically. Stone formation is probable above a urinary concentration of 0.5 mmol/L. Although all patients had elevated plasma oxalic acid levels, this level clearly depended on the presence of an intact colon: patients with complete colon in continuity with small bowel having the highest levels (Figure 1).

Preparations in patients with secondary hyperoxaluria (Table 1): A period of 6 months was used to introduce and acquaint patients with the low oxalic acid diet. In addition, patients were treated with calcium supplementation during meals (to bind oxalic acid in the gut), cholestyramine (to bind fatty acids in the gut), and sodium bicarbonate (Table 1). The latter is used to increase urinary pH, thereby diminishing

**TABLE 1.**

### Protocol to reduce plasma oxalic acid levels

Initial measures (months before transplantation) <sup>11,17</sup>	One week before (living donor) or at transplantation (deceased donor)	Direct posttransplantation period	When urine output is >2 L/day
Low-oxalic acid diet (40-50 mg/day) <sup>a</sup>	Oxalic acid-free drip-feed	Continuation of drip-feed and hemodialysis	Stop drip-feed, start low-oxalic acid diet
Cholestyramine (3 times 4 g)	Daily 6-h hemodialysis sessions <sup>b</sup>	Standard immunosuppressive regimen <sup>c</sup>	Stop hemodialysis
Sodium bicarbonate (3 times 500-1000 mg)		No loop diuretics	Sufficient fluid intake to maintain urinary output > 2 L/day
Calcium carbonate (3 times 500 mg during meals)			No loop diuretics

<sup>a</sup> <https://regipi.bwh.harvard.edu/health/Oxalate/files>.

<sup>b</sup> Other settings: high flux membrane (2.2 m<sup>2</sup>), Qb 350 mL/min, bicarbonate 28 to 30 mmol/L, calcium 1.0 mmol/L.

<sup>c</sup> Standard immunosuppressive regimen in our center is basiliximab induction, tacrolimus, mycophenolate mofetil, and prednisone.

**TABLE 2.****Characteristics on 10 patients with enteric, secondary hyperoxaluria that were transplanted according to our protocol**

Patient number	Patient characteristics				Transplantation				Follow-up						
	Sex and age at transplantation	Native kidney disease	Cause hyperoxaluria	Group <sup>a</sup>	Oxalic acid level before diet	Oxalic acid at transplantation	Donor type	DFG, protocol continued	Complication	Treatment	Time since transplant (months)	last eGFR ml/min	last plasma oxalic acid (μmol/l)	Urine oxalic acid level (mmol/l)	Renal biopsy
1	M 66	Oxalate depositions	M Crohn's, resection of 150 cm small intestine at age 25 y	1	108	23	LD	No	Sepsis at 2 mo	RP for 4 mo	32	38	12.9	0.66	Month 3: CaOx
2	M 63	Nephrolithiasis	M Crohn's with extensive ileocecal resection and hemicolectomy at age 42 y	2	78	13	2nd LD	No	Recurrent native kidney stones	Temporary IV fluid and antibiotics	31	36	7.3	0.13	Month 24: UTI, CABMR, small amount CaOx
3	M 63	Oxalate depositions	M Crohn's with extensive ileocecal resection and ileotransversostomy at age 52 y	2	48	48	DCD	3 wk	Persistent UTI and hydronephrosis	Temporary IV fluid, antibiotics and PCN	27	31	5	0.08	Week 6: UTI, small amount CaOx
4	M 39	Hereditary nephronophthisis	Gastric bypass at age 30 y	1	43	38	DCD	1 wk	ABMR	RP for 1 wk, methylprednisolone and atemizumab	18	43	6.3	0.09	Day 18: ABMR, no CaOx
5	F 60	Nephrosclerosis	M Crohn's, resection colon transversum at age 41 y	2	64	63	2nd DCD	2 d	Rejection: TMA	3 d intensive HD, Methyl prednisolone	14	99	2.9	0.09	Day 10: TMA, no CaOx
6	F 53	Dehydration, no biopsy	M Crohn's, High-output ileostoma. At age 27 y	3	16	9.2	2nd LD	No	Dehydration caused by high-output stoma	Routine IV fluid 3 nights per week 2 L	14	37	4.7	0.11	Month 3: ATN, small amount CaOx
7	M 67	Calcium oxalate kidney stones	M Crohn's, resections, ileoscendostomy at age 36-46 y	1	72	32	DCD	4 mo	Wound bleeding, myocardial infarction, hydronephrosis	Temporary IV fluid and antibiotics. Ureter-bladder re-anastomosis	12	35	5.4	0.11	Day 10: ATN, no CaOx
8	F 31	FSGS, before pancreatitis	Pancreatitis, pancreatic insufficiency at age 24 y	1	89	24.5	LD	No	Urine leakage	Temporary PCN	6	79	7.8	0.29	
9	M 72	Unknown, no biopsy	M Crohn's, ileocecal resections at age 50-57 y	1	67	54	DCD	No	Ileus	Temporary IV fluid	3	69	9.0	0.62	

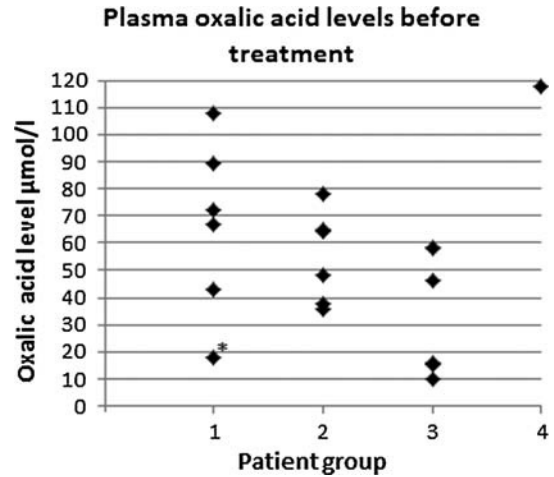
*Continued next page*

**TABLE 2. (Continued)**

Patient characteristics			Transplantation			Follow-up									
Patient number	Sex and age at transplantation	Native kidney disease	Cause hyperoxaluria	Group <sup>a</sup>	Oxalic acid level before diet	Oxalic acid at transplantation	Donor type	DGF, protocol continued	Complication	Treatment	Time since transplant (months)	last eGFR ml/min	last plasma oxalic acid (μmol/l)	Urine oxalic acid level (mmol/l)	Renal biopsy
10	M 53	Focal glomerulosclerosis	Liver transplantation 21 y before, M Crohn's, subtotal colectomy, ileostoma at age 43 y	3	46	3.0	LD	No	Sepsis	RP	Died day 14				Day 9: ATN, no CaOx

<sup>a</sup> Group: (1) complete colon in continuity with gut; (2) partial colectomy; (3) no functional colon/ileostomy (see also Figure 1).

RP, reinstitution of protocol; ABMR, antibody mediated rejection; CABMR, chronic antibody mediated rejection; UTI, urinary tract infection; CaOx, calcium oxalate deposition; F, female; M, male; FSGS, focal segmental glomerulosclerosis; TMA, thrombotic microangiopathy.



**FIGURE 1.** Plasma oxalic acid levels in eighteen patients with hyperoxaluria divided into 4 groups: group 1: Six patients with intact colon, including patients with chronic pancreatitis (1 patient), gastric bypass (1 patient), and Crohn's disease requiring short bowel resections (4 patients); group 2: Six patients with partial colectomy, including patients with resections for Crohn's disease who underwent partial colectomy (5 patients) or resections because of encapsulating peritoneal sclerosis (one patient); group 3: Five patients without a functional colon, including patients with ileostomy because of resections for Crohn's disease (4 patients) or small bowel perforation (1 patient); group 4: One patient with primary hyperoxaluria. \* Patient not on dialysis with eGFR 27 mL/min and on a low oxalic acid diet when samples were taken.

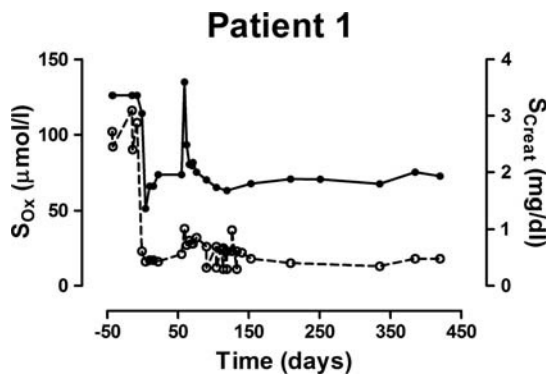
the uptake of filtered citrate by the proximal tubular cells and raising urinary citrate excretion. All patients suffered from diarrhea or loose stools. With dietary advice, both volume and frequency of diarrhea were reduced. All group 3 patients presented with stoma production of about 2 L per day. Through intensive counseling by our dietician this volume could be reduced to about 1200 mL. In recipients of a living donor transplantation, protocol started 1 week before transplantation with intensive hemodialysis (IHD) (6 days, 6 hours) and oxalic acid-free drip feed. In recipients of a deceased donor kidney, drip feed and IHD were started at transplantation. Independent of donor type, IHD and drip feed were continued until kidney function was adequate and urine production was more than 2 L per day. Loop diuretics were prohibited as they cause hypercalciuria that may promote calcium oxalate formation in the kidney. After transplantation, low oxalic acid diet was continued and oxalic acid levels in plasma and urine as well as citrate, calcium and magnesium in urine were determined.

**Cases Transplanted According to Protocol**

**Patient 1** was on hemodialysis for 7 years when he was referred to our center for second opinion, after being declined because of enteric hyperoxaluria and recurrent D-lactate acidosis. Two months after transplantation he was readmitted because of *Escherichia coli* pneumonia with sepsis and anuria. Mycophenolate mofetil (MMF) was stopped, the dose of prednisone was decreased and protocol was reinstated. Figure 2 shows how serum creatinine and plasma oxalic acid levels drop sharply before transplantation and remain low until sepsis intervenes at month 2 (see Table 2 for details).

**Patient 2** lost his first malfunctioning renal transplant after 18 months, the biopsy showed oxalate deposition. His second kidney transplantation was uneventful. From 6 months



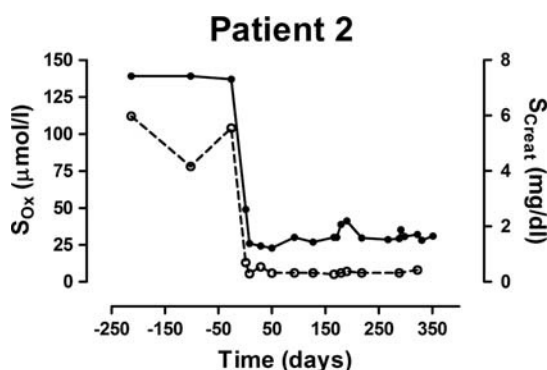


**FIGURE 2.** Development of serum creatinine and plasma oxalic acid levels after LD transplantation in patient 1. Levels dropped sharply before transplantation and remained low until sepsis intervened at month 2 when protocol was reinstated.

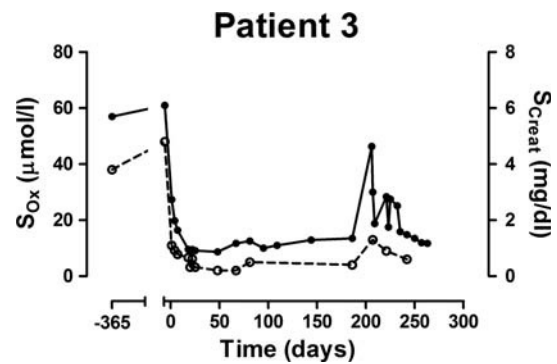
after transplantation onward, he suffered from passing native kidney stones and urinary tract infections. Ultrasonography did not show stones or calcification in the transplanted kidney. Although plasma and urine oxalic acid levels remained low, his kidney function slowly deteriorated with each episode of infection. After urological intervention, actively removing native kidney stones combined with long-term antibiotic treatment his renal function improved and stabilized. Serum creatinine and plasma oxalic acid levels are shown in Figure 3. (see Table 2 for details).

**Patient 3** had delayed graft function but, at discharge, her eGFR was 47 mL/min. Because of low levels, weekly magnesium administrations at home were started on a routine basis. Six months after transplantation, she suddenly developed hydronephrosis caused by stenosis of the ureter-bladder anastomosis. A nephrostomy drain was inserted. A kidney biopsy only showed signs of a urinary tract infection and 2 small oxalate crystals but no rejection. After treatment of the urinary tract infection, the nephrostomy drain could be removed and serum creatinine returned to baseline value. Serum creatinine and oxalic acid levels are shown in Figure 4. (see Table 2 for details).

**Patient 4** had lost 36 kg after his gastric bypass, but his kidney function deteriorated progressively and hemodialysis had to be started. He was referred for second opinion after being turned down for transplantation in his own center



**FIGURE 3.** Development of serum creatinine and plasma oxalic acid levels after LD transplantation in patient 2. Serum creatinine rose with recurrent urinary tract infections, oxalic acid levels increase slightly. Renal function and oxalic acid levels stabilized after infections were controlled.



**FIGURE 4.** Development of serum creatinine and plasma oxalic acid levels after DD transplantation in patient 3. Because of DGF protocol was continued after transplantation. When renal function improved, oxalic acid levels remain low after transplantation but increase parallel to creatinine during her urinary tract infection with hydronephrosis.

because of perceived high risk. Transplantation was complicated by bleeding and vascular reconstructions (see Table 2 for details).

**Patient 5** lost her first renal transplant after 8 years because of chronic allograft nephropathy with oxalate crystal deposition. Her second DCD kidney transplantation was complicated by short-term delayed graft function (DGF) for 2 days and thrombotic microangiopathy (see Table 2 for details).

**Patient 6** had a high-output ileostomy that produced 1.5 to 2 L per day. In 2011 she received a first kidney transplantation from her brother. High stoma production (2 L/day) decreased urine output and kidney function deteriorated quickly. A Noro virus infection with diarrhea caused permanent loss of graft function at 3 years after transplantation. The renal biopsy showed oxalate crystals from 1 year onward. In preparation for the next transplantation, she was intensively coached by dieticians to decrease stoma production (maximally 100 mL drinking during meals, no hypo- or hypertonic fluids, only isotonic fluids, fluid intake in small portions divided over the day, extra NaCl during meals). With that regimen stoma output decreased to 1.2 L/day. A second living donor (LD) kidney transplantation was performed with a kidney from her niece. Standard thrice weekly hemodialysis instead of daily hemodialysis (because of low oxalic acid levels) was combined with oxalic-acid-free drip feed. Transplantation was uneventful and stoma output remained stable at 1.2 L per day. However, with oral intake of 3 L per day urine production stabilized at 1.4 L/day and eGFR decreased, especially on warm days to 20 mL/min. Intravenous (IV) fluid (2 L) and magnesium administrations at home were started on a routine basis for 3 nights per week. Since then renal function improved and stabilized (see Table 2 for details).

**Patient 7** was treated with external shock wave lithotripsy to reduce calcium oxalate kidney stone load as much as possible to prevent stone related complications posttransplantation. Because there was no adequate transplant function, the protocol was continued after transplantation, but at the patient's request, hemodialysis was decreased to 3 times per week 6 hours and gastric tube and drip feed were replaced by low oxalic acid diet. He suffered from recurrent urinary tract infections and hydronephrosis. After removal of native kidney ureter stones and ureter-bladder re-anastomosis at 8 months after transplantation, his renal function improved and stabilized (see Table 2 for details).

**Patient 8** had been declined for transplantation by another transplantation center because of recurrent chronic pancreatitis. At presentation her plasma oxalic acid level was 89  $\mu\text{mol/L}$ . She did not use her pancreatic enzyme supplementation. Enzyme supplements were restarted, and pancreatic outflow was improved to extinguish bouts of pancreatitis. Besides, low oxalic acid diet was started. Tacrolimus and mycophenolic acid test doses were tried that did not provoke pancreatitis. Transplantation was uneventful, but urinary leakage was observed and a percutaneous nephrostomy (PCN) was introduced and moved into the bladder. After healing up of the defect in ureter bladder anastomosis the PCN could be removed. Since then, eGFR stabilized. She did not develop pancreatitis (see Table 2 for details).

**Patient 9** started his low oxalic acid diet 1 year before his uneventful DCD renal transplantation. At day 6, he developed ileus caused by a known stenotic trajectory in the neoterminal ileum. With conservative treatment ileus subsided and feeding could be restarted. Renal function remained stable.

**Patient 10** had extensive comorbidity. Apart from general measures, pretransplant preparations comprised dietary restrictions to decrease stoma production from 2 L to 1.2 L. One week before transplantation, daily hemodialysis sessions were combined with low oxalic acid diet on patients' request. He received an LD renal transplantation with direct function. However, from day 1 onward, renal function and general

condition deteriorated. Daily hemodialysis sessions and low oxalic acid diet were continued. He developed erysipelas of his right leg. Ongoing *E. coli* sepsis intervened, probably bile tree derived, and he developed multiorgan failure. He died on day 14 after transplantation (see Table 2 for details).

## DISCUSSION

We report 10 consecutive patients with enteric hyperoxaluria in whom a protocol aimed at reducing plasma oxalic acid levels resulted in favorable short-term outcomes after kidney transplantation in 9 of them (Table 1). Patient 10 died at day 14 because of complications unrelated to enteric hyperoxaluria. Although intensive monitoring and support is necessary for these patients to maintain a low oxalic acid diet (40-50 mg/day), all patients reported to adhere to their diet, denied gastrointestinal complaints, and maintained stable body weight. Drip feed and daily dialysis sessions were experienced as burdensome by the patients, but in our experience, and that of the patients, it is compensated for by the final success. All patients with LD transplantation were treated with low oxalic acid diet followed by IHD and 4 of 5 patients with oxalic-acid-free drip feed. Pretransplantation oxalic acid levels had decreased considerably in all of them, and graft function was immediate (Table 2). Four of 5 patients with a DD transplantation were acquainted with low oxalic acid diet but diet was not very

**TABLE 3.**

Literature: case reports on kidney transplantation in patients with secondary hyperoxaluria

Reference	Age and sex	Cause secondary hyperoxaluria	Cause of ESRD	Donor type	Measures taken posttransplantation	DGF	Biopsy	Graft failure	Observation period
19	65 y, M	Short bowel	CaOx	DD	Diet, Ca	No	N.D.	No	10 mo
20	62 y, F	Short bowel	CaOx stones	DD	Diet, Ca, citrate, daily HD	17 d	CaOx	No	7 y
21	37 y, M	Pancreatic insufficiency	Renal dysplasia No CaOx	DD	3w HD	NFG	CaOx	Yes	7 mo
21	37 y, M	Pancreatic insufficiency	Renal dysplasia No CaOx	DD 2nd transplant	3w HD. After 18 mo: start lipase, Ca	11 mo	CaOx	No	3 y
22	74 y, M	Short bowel	CaOx stones	N.R.	After recurrence high urine volume	N.R.	CaOx	No	3 y
23	40 y, M	Short bowel	CaOx stones	DD	Daily HD	2 wk	CaOx	Yes	10 mo
24	60 y, M	Short bowel	Renal stones	DD	Diet, Ca, K, citrate	No	No CaOx	No	3 y
25	70 y, M	Chronic pancreatitis	Diabetic nephropathy	DD	None	No	CaOx	Yes	8 y
26	51 y, M	MMF (only after transplantation)	Diabetic nephropathy	DD kidney pancreas	After 6 mo MMF stopped	No	CaOx	Yes	8 mo
7	57 y, F	Celiac disease	CaOx	LD	After 14 wk gluten restriction	No	CaOx	No	7 mo
27	70 y, M	Gastric bypass	N.R.	DD	After 1 y diet, Ca	No	CaOx	No	14 mo
27	67 y, M	Gastric bypass	CaOx stones	DD	None	1 mo	CaOx	Yes	11 mo
28	56 y, F	Short bowel	CaOx stones	DD	Small bowel transplantation	No	N.D.	No	67 mo
28	41 y, F	Short bowel	CaOx stones	DD	Small bowel transplantation	No	N.D.	No	11 mo
16	38 y, F	Short bowel	CaOx stones	LD	Ca, K, citrate,	No	CaOx	Yes	6 y
16	39 y, F	Short bowel	CaOx stones	LD 2nd transplant	Ca, citrate, loperamide, pancreatic enzymes	No	N.D.	No	1 y
16	48 y, M	Short bowel	CaOx stones	DD	N.R.	No	N.D.	No	3 y
16	47 y, F	Short bowel	CaOx stones	DD	N.R.	No	CaOx	Yes	2 y

3w, thrice weekly; Ca, calcium supplementation; ESRD, end-stage renal disease; DD, deceased donor; HD, hemodialysis; K, potassium supplementation; N.D., not determined; N.R., not reported.

strict because time to transplantation was uncertain. Decrease in oxalic acid levels was less pronounced and 3 of 5 patients were treated with IHD and drip feed after transplantation. Patient 7 had the least strict treatment, and he needed most time for recovery of the kidney, suggesting that the intensity of the program did influence results. It is not certain however whether IHD or oxalic acid free drip feed alone would have had the same effect.

As shown in the recipients of an LD transplantation, plasma oxalic acid levels could be decreased adequately after intensive treatment. A directly functioning kidney transplant decreased levels even further, reaching near normal levels within a few days. However, without a functioning transplant, oxalic acid levels increased parallel with increasing serum creatinine values.

Despite malabsorption, tacrolimus levels were adequate in all patients. In 2 patients, mycophenolic acid through levels were low but area under the curves were adequate.

Our aim to maintain urinary output above 2 L/day seems low regarding the risk for recurrence of oxalate depositions. However, these patients lose fluid via diarrhea or via their high-output stoma, decreasing urinary production. A fluid intake above 3 L per day is hardly feasible for these patients especially because high oral fluid volumes often trigger diarrhea and increase stoma production. When dehydration is suspected, we typically give a trial of IV fluid during admission. When kidney function improves, IV fluid administration at home on a regular basis may be an option (patient 6).

Although surgery for Crohn's disease or gastric bypass and other reasons for malabsorption are quite common, the current literature on kidney transplantation in patients with secondary hyperoxaluria is limited to 12 articles covering 16 patients with 18 kidney transplantations<sup>7,16,20-29</sup> (Table 3). In 2 years, we gathered 17 patients with enteric hyperoxaluria showing that it is more prevalent than expected. One possible explanation for the relatively low number of reported cases may be that enteric hyperoxaluria is underrecognized. Indeed, in 6 of the previously reported patients, enteric hyperoxaluria was only considered sometime after transplantation<sup>7,22,26-28</sup> (Table 1). Apart from the 2 patients with short bowel transplantation, only 6 of 18 patients had been treated with diet or medication or IHD in the direct postoperative phase. In our 17 patients with enteric hyperoxaluria (Figure 1), only 3 patients had nutritional counseling regarding prevention of oxalate nephropathy before referral for transplantation. This suggests that patients with secondary hyperoxaluria were not optimally treated during the phase their native kidney function deteriorated. This may have contributed not only to accelerated native function decline but also to increased risk of systemic oxalosis.<sup>30,31</sup> Because most patients with hyperoxaluria are primarily seen by gastroenterologists and urologists, kidney function decline may have progressed unnoticed for some time. Another reason for underreporting may be that poor outcomes have not been reported (publication bias) or patients with secondary hyperoxaluria may have been declined for kidney transplantation because of the high recurrence rate. Actually, 3 of our 10 transplanted patients had been declined for transplantation in other transplantation centers in The Netherlands (patients 1, 4, and 8).

In our population, the highest oxalic acid levels were found in group 1 with intact colon in continuity with small

bowel. Though levels tend to be lower in the population without a colon (group 3) variability was high (Figure 1). Despite currently low levels, patient 6 had lost her first kidney transplant because of oxalate deposition. The reason probably is that urine oxalic acid levels were high because of low urine volume, but plasma levels may also have been higher at that time. In patients with ileostomy, stones contain both uric acid and calcium oxalate.<sup>32</sup> For group 3 patients, the main purpose of treatment is to keep urine volume as high as possible while keeping plasma oxalic acid levels low according to our protocol.

Even long-term functioning kidney transplants may experience a "second hit" that disturbs oxalic acid homeostasis and results in (temporary) loss of function.<sup>26</sup> This "second hit" may be an infectious gastroenteritis, symptomatic kidney stones, sepsis with anuria, inadequate pancreatic enzyme supplementation, decreased fluid intake or increased fluid loss, or rejection of the transplant. Slow recovery (11 months) of graft function in a patient with enteric hyperoxaluria has been reported previously.<sup>22</sup> In 4 patients our protocol was prolonged after transplantation (patients 3, 4, 5, 7), whereas the protocol was reinstated in 3 patients with a second hit (patients 1, 4, 10). In 5 other patients with compromised renal function, direct anticipation with fluid administration resulted in improved urine output and decreasing serum creatinine (patients 2, 3, 6, 7, 9). Patient 6 still receives IV fluid administration 3 times per week to prevent dehydration. In patient 10, IHD was continued until it became clear that the prognosis was very unfavorable because of ongoing sepsis and multi organ failure unrelated to hyperoxaluria.

This population is vulnerable because most of them suffer from serious comorbidity threatening overall survival. Besides, a sudden decrease in kidney function causes oxalate deposition that results in potentially irreversible damage threatening graft function.

Though urine oxalate levels have been measured at a regular basis, posttransplant data regarding urinary calcium, and citrate excretions are incomplete. Although we only describe 10 patients of whom 3 with follow-up of more than 2 years, we feel that the strength of our protocol is the favorable short-term results, even in the patients with DGF and after recurrence of oxalate deposition. Compared with the existing literature, our study is the largest and first systematic description of kidney transplantation in a cohort of patients with enteric hyperoxaluria. In an ongoing study, we found oxalate deposition within 3 months after transplantation in 17% of the patients (without enteric hyperoxaluria) with for cause renal biopsy. Follow-up biopsies became negative for oxalate deposition suggesting reversibility of deposition in certain cases. Most probably, depositions may wax and wane depending on the oxalic acid load. Irreversible kidney function decline may result from excessive oxalic acid loads when crystals have permanently damaged kidney structure.

In conclusion, enteric, secondary hyperoxaluria is an underestimated cause of kidney function decline in native and transplanted kidneys. A protocol to decrease plasma oxalic acid levels and increase urinary volume is feasible and may be considered to prevent the occurrence of oxalate nephropathy in native kidneys and recurrence and subsequent graft failure after transplantation.



## REFERENCES

- Hueppelshaeuser R, von Unruh GE, Habbig S, et al. Enteric hyperoxaluria, recurrent urolithiasis, and systemic oxalosis in patients with Crohn's disease. *Pediatr Nephrol*. 2012;27:1103–1109.
- Beloncle F, Sayegh J, Duveau A, et al. An unexpected cause of progressive renal failure in a 66-year-old male after liver transplantation: secondary hyperoxaluria. *Int Urol Nephrol*. 2013;45:1209–1213.
- Cornelis T, Bammens B, Lerut E, et al. AA amyloidosis due to chronic oxalate arthritis and vasculitis in a patient with secondary oxalosis after jejunoileal bypass surgery. *Nephrol Dial Transplant*. 2008;23:3362–3364.
- Froeder L, Arasaki CH, Malheiros CA, et al. Response to dietary oxalate after bariatric surgery. *Clin J Am Soc Nephrol*. 2012;7:2033–2040.
- Nasr SH, D'Agati VD, Said SM, et al. Oxalate nephropathy complicating Roux-en-Y Gastric Bypass: an underrecognized cause of irreversible renal failure. *Clin J Am Soc Nephrol*. 2008;3:1676–1683.
- Lefaucheur C, Nochy D, Amrein C, et al. Renal histopathological lesions after lung transplantation in patients with cystic fibrosis. *Am J Transplant*. 2008;8:1901–1910.
- Capolongo G, Abul-Ezz S, Moe OW, et al. Subclinical celiac disease and crystal-induced kidney disease following kidney transplant. *Am J Kidney Dis*. 2012;60:662–667.
- Dobbins JW, Binder HJ. Importance of the colon in enteric hyperoxaluria. *N Engl J Med*. 1977;296:298–301.
- Knauf F, Asplin JR, Granja I, et al. NALP3-mediated inflammation is a principal cause of progressive renal failure in oxalate nephropathy. *Kidney Int*. 2013;84:895–901.
- Latta K, Brodehl J. Primary hyperoxaluria type I. *Eur J Pediatr*. 1990;149:518–522.
- Nightingale JM. Hepatobiliary, renal and bone complications of intestinal failure. *Best Pract Res Clin Gastroenterol*. 2003;17:907–929.
- Gregory JG, Park KY, Schoenberg HW. Oxalate stone disease after intestinal resection. *J Urol*. 1977;117:631–634.
- Syed F, Mena-Gutierrez A, Ghaffar U. A case of iced-tea nephropathy. *N Engl J Med*. 2015;372:1377–1378.
- Earnest DL, Johnson G, Williams HE, et al. Hyperoxaluria in patients with ileal resection: an abnormality in dietary oxalate absorption. *Gastroenterology*. 1974;66:1114–1122.
- Karaolanis G, Lionaki S, Moris D, et al. Secondary hyperoxaluria: a risk factor for kidney stone formation and renal failure in native kidneys and renal grafts. *Transplant Rev (Orlando)*. 2014;28:182–187.
- Nazzal L, Puri S, Goldfarb DS. Enteric hyperoxaluria: an important cause of end-stage kidney disease. *Nephrol Dial Transplant*. 2016;31:375–382.
- Buchman AL, Scolapio J, Fryer J. AGA technical review on short bowel syndrome and intestinal transplantation. *Gastroenterology*. 2003;124:1111–1134. 11–34.
- Laging M, Kal-van Gestel JA, van de Wetering J, et al. HYPERLINK "https://www.ncbi.nlm.nih.gov.eur.idm.oclc.org/pubmed/26516673" A high comorbidity score should not be a contraindication for kidney transplantation. *Transplantation*. 2016;100:400–406.
- Wolthers BG, Hayer M. The determination of oxalic acid in plasma and urine by means of capillary gas chromatography. *Clin Chim Acta*. 1982;120:87–102.
- Roberts RA, Sketris IS, MacDonald AS, et al. Renal transplantation in secondary oxalosis. *Transplantation*. 1988;45:985–986.
- Kistler H, Peter J, Thiel G, et al. Seven-year survival of renal transplant for oxalate nephropathy due to short-bowel syndrome. *Nephrol Dial Transplant*. 1995;10:1466–1469.
- Cuvelier C, Goffin E, Cosyns JP, et al. Enteric hyperoxaluria: a hidden cause of early renal graft failure in two successive transplants: spontaneous late graft recovery. *Am J Kidney Dis*. 2002;40:E3.
- Lim PB, Klebe B, Kon SP. Nephrocalcinosis in a patient with secondary hyperoxaluria. *Nephrol Dial Transplant*. 2004;19:1325.
- Bernhardt WM, Scheffold JC, Weichert W, et al. Amelioration of anemia after kidney transplantation in severe secondary oxalosis. *Clin Nephrol*. 2006;65:216–221.
- Rifkin SI. Transplantation for renal failure secondary to enteric hyperoxaluria: a case report. *J Med Case Rep*. 2007;1:31.
- Rankin AC, Walsh SB, Summers SA, et al. Acute oxalate nephropathy causing late renal transplant dysfunction due to enteric hyperoxaluria. *Am J Transplant*. 2008;8:1755–1758.
- Hamidian Jahromi A, Roberts IS, Winearls CG, et al. Acute renal failure secondary to oxalosis in a recipient of a simultaneous kidney-pancreas transplant: was mycophenolate the cause? *Nephrol Dial Transplant*. 2008;23:2409–2411.
- Troxell ML, Houghton DC, Hawkey M, et al. Enteric oxalate nephropathy in the renal allograft: an underrecognized complication of bariatric surgery. *Am J Transplant*. 2013;13:501–509.
- Ceulemans LJ, Nijs Y, Nuytens F, et al. Combined kidney and intestinal transplantation in patients with enteric hyperoxaluria secondary to short bowel syndrome. *Am J Transplant*. 2013;13:1910–1914.
- Salyer WR, Hutchins GM. Cardiac lesions in secondary oxalosis. *Arch Intern Med*. 1974;134:250–252.
- O'Callaghan JW, Arbuckle SM, Craswell PW, et al. Rapid progression of oxalosis-induced cardiomyopathy despite adequate haemodialysis. *Miner Electrolyte Metab*. 1984;10:48–51.
- Evan AP, Lingeman JE, Coe FL, et al. Intra-tubular deposits, urine and stone composition are divergent in patients with ileostomy. *Kidney Int*. 2009;76:1081–1088.