

University of Groningen

## Using the Long Head of Biceps Tendon Autograft as an Anatomical Reconstruction of the Rotator Cable

Veen, Egbert J D; Koorevaar, Cornelis T; Diercks, Ronald L

*Published in:*  
 Arthroscopy techniques

*DOI:*  
[10.1016/j.eats.2018.03.002](https://doi.org/10.1016/j.eats.2018.03.002)

**IMPORTANT NOTE: You are advised to consult the publisher's version (publisher's PDF) if you wish to cite from it. Please check the document version below.**

*Document Version*  
 Publisher's PDF, also known as Version of record

*Publication date:*  
 2018

[Link to publication in University of Groningen/UMCG research database](#)

*Citation for published version (APA):*

Veen, E. J. D., Koorevaar, C. T., & Diercks, R. L. (2018). Using the Long Head of Biceps Tendon Autograft as an Anatomical Reconstruction of the Rotator Cable: An Arthroscopic Technique for Patients With Massive Rotator Cuff Tears. *Arthroscopy techniques*, 7(7), E699-E703.  
<https://doi.org/10.1016/j.eats.2018.03.002>

**Copyright**

Other than for strictly personal use, it is not permitted to download or to forward/distribute the text or part of it without the consent of the author(s) and/or copyright holder(s), unless the work is under an open content license (like Creative Commons).

**Take-down policy**

If you believe that this document breaches copyright please contact us providing details, and we will remove access to the work immediately and investigate your claim.

*Downloaded from the University of Groningen/UMCG research database (Pure): <http://www.rug.nl/research/portal>. For technical reasons the number of authors shown on this cover page is limited to 10 maximum.*



# Using the Long Head of Biceps Tendon Autograft as an Anatomical Reconstruction of the Rotator Cable: An Arthroscopic Technique for Patients With Massive Rotator Cuff Tears

Egbert J. D. Veen, M.D., Cornelis T. Koorevaar, M.D., Ph.D., and Ronald L. Diercks, M.D., Ph.D.

**Abstract:** The treatment of massive rotator cuff tears (MRCT) is challenging. Insufficient tissue quality, size, and retraction of the cuff often lead to failures of repair. Different techniques like direct repair, partial repair, and graft applications have been developed, but results are not yet predictable. In this arthroscopic technique the objective is not to reconstruct the rotator cuff as a tissue layer but to restore the biomechanical function of the rotator cable with an autograft of the long head of the biceps tendon. After glenohumeral inspection, the long head of the biceps tendon is harvested and the retracted cuff is released and, if possible, closed partially side-to-side. The biceps graft is positioned from the posterior aspect of the greater tubercle to the superior part of the lesser tubercle and fixed with 2 biotenodesis anchors. Finally, the cuff remnants are securely sutured to the biceps graft with standard cuff repair sutures. This arthroscopic technique has several advantages because the biceps autograft is easily harvested, autologous, and rich in collagen. Previous studies show use of the biceps tendon differently for reconstruction of the rotator cuff, with promising results. Future studies are needed to evaluate clinical outcomes.

Massive rotator cuff tears (MRCTs) often cause impairment, pain, and loss of function. These tears are defined as 2 or more tendons involved and/or more than 5 cm retraction.<sup>1</sup> As a result of the retraction it is not always possible to fix the rotator cuff to the original footprint at the greater tubercle. To overcome these difficulties, several techniques have been developed with variable outcomes. These include xenograft, synthetic patches, and allografts. All are costly and do not stimulate ingrowth.<sup>2</sup> Graft reactions are also seen. Other extensive

surgeries like latissimus dorsi or teres minor muscle transfer are described but have limited indications.<sup>3</sup>

When treating rotator cuff tears, a tenotomy or tenodesis of the long head of the biceps is often part of the surgical procedure. In some studies the intra-articular portion is used as a graft for bridging the gap in MRCTs. In those techniques, the tendon is longitudinally incised and used to fill the gap or as augmentation.<sup>4</sup> What we propose is using the long head of the biceps tendon to restore the rotator cable. The rotator cable, a thickening in the rotator cuff, was reported by Burkhart et al.,<sup>5</sup> who described a structure in the superior articular capsule that acts like a loaded suspension bridge cable and serves as a primary load-bearing structure between the rotator cuff and the humerus. This function has been clearly identified in biomechanical cadaveric studies.<sup>6,7</sup>

We developed a technique to treat MRCT by reconstructing the rotator cable with a long head of the biceps tendon autograft.

## Surgical Technique

### Indications

This technique is indicated for patients with an MRCT and failure after conservative treatment with injections

From the Department of Orthopedic Surgery, University of Groningen, University Medical Center (E.J.D.V., R.L.D.), Groningen; and Department of Orthopedic Surgery and Traumatology, Deventer Hospital (E.J.D.V., C.T.K.), Deventer, the Netherlands.

The authors report that they have no conflicts of interest in the authorship and publication of this article. Full ICMJE author disclosure forms are available for this article online, as [supplementary material](#).

Received January 11, 2018; accepted March 4, 2018.

Address correspondence to Egbert J. D. Veen, M.D., Hanzeplein 1, Postbus 30.001, 9700 RB Groningen, the Netherlands. E-mail: [ejdveen@gmail.com](mailto:ejdveen@gmail.com)

© 2018 by the Arthroscopy Association of North America. Published by Elsevier. This is an open access article under the CC BY-NC-ND license (<http://creativecommons.org/licenses/by-nc-nd/4.0/>).

2212-6287/1857

<https://doi.org/10.1016/j.eats.2018.03.002>

**Table 1.** Inclusion and Exclusion Criteria for Using Biceps Autograft Technique

Inclusion Criteria	Exclusion Criteria
Massive rotator cuff tear (2-3 tendons)	Previous surgery on the shoulder
Conservative treatment failed	Symptomatic acromioclavicular osteoarthritis
Age <70 years	Glenohumeral osteoarthritis
Retraction (Patte stage 3 or lower)	Rheumatoid arthritis
	Degenerated biceps tendon
	Fatty infiltration (Goutallier stage 3 or higher)
	Primary cuff repair feasible at surgery

and/or physiotherapy for >3 months. Patients should not have any previous surgery on the affected shoulder or signs of symptomatic acromioclavicular/glenohumeral osteoarthritis (Table 1).

### Preparation

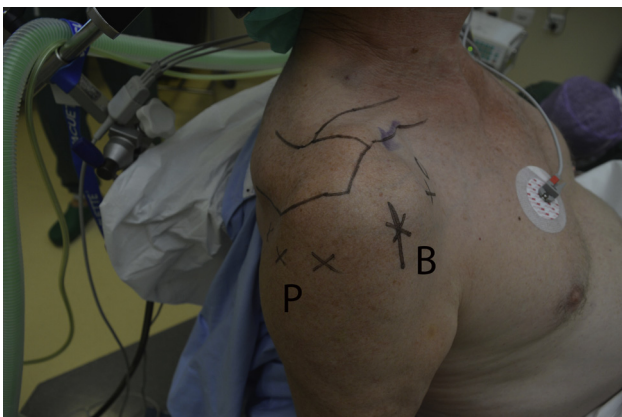
Patients are operated in the beach chair position with an interscalene block of the brachial plexus and general anesthesia. The anatomical landmarks and position of the portals are marked (Fig 1). After disinfection with chlorhexidine and standard sterile draping, the arthroscopic procedure is performed with a 30° arthroscope.

### Routine Intra-articular Procedure

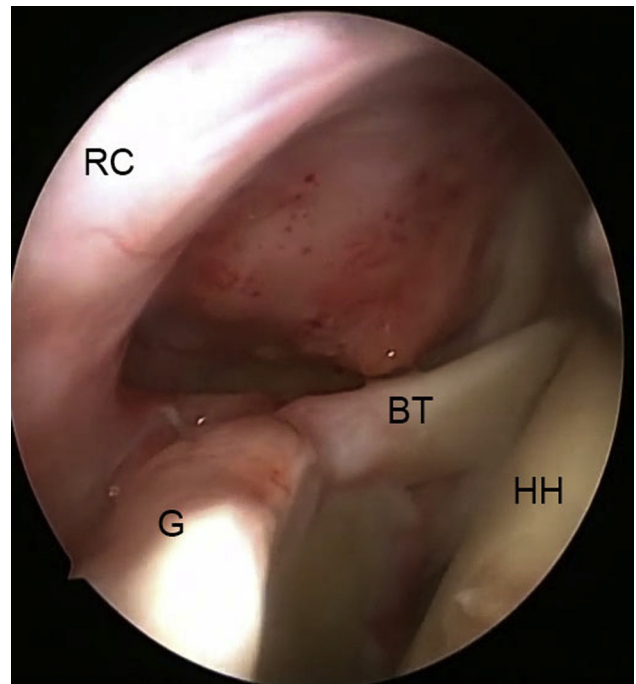
The standard procedure starts by introducing the scope through the posterior portal. The anterior portal is created under direct vision. The quality of the cartilage is recorded, and the different tendons of the cuff are inspected (Fig 2). A primary cuff repair is performed, if possible.

### Long Head of the Biceps Tendon Tenotomy

After confirming the diagnosis of MRCT, the intra-articular portion of the biceps is tenotomized just

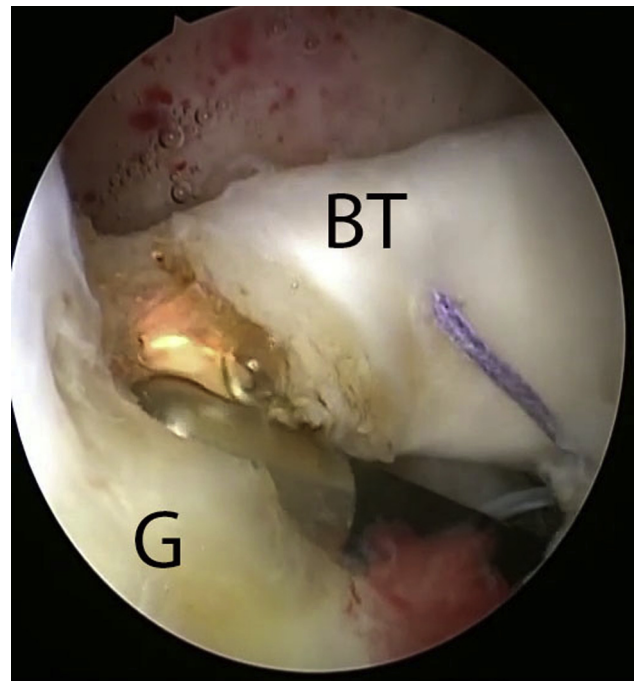


**Fig 1.** Patient in beach chair position seen from lateral side with anatomy and portals marked on the right shoulder. (B, biceps graft harvest incision; P, posterior side.)




**Fig 2.** Intra-articular inspection seen from posterior portal of a right shoulder. (BT, biceps tendon; G, glenoid; HH, humeral head; RC, rotator cuff.)

distal to the insertion on the superior labrum (Fig 3). If the subscapularis is ruptured, a primary repair to the lesser tubercle with suture anchor(s) is performed.



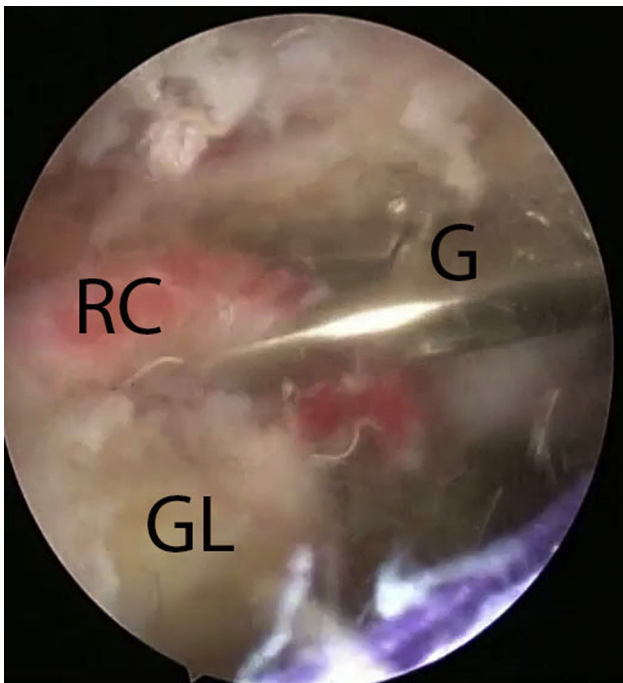
**Fig 3.** Tenotomy of biceps tendon close to insertion on the glenoid. Seen from a posterior portal of a right shoulder. (BT, biceps tendon; G, glenoid.)



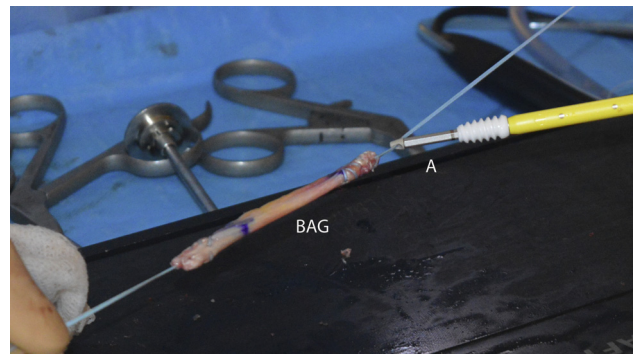
**Fig 4.** Preparation of the biceps autograft with a length of 70 mm and marked at both ends, which will be inserted with the anchors. (BAG, biceps auto graft.)

### Harvesting the Long Head of the Biceps Tendon

A small anterolateral incision is made at the bicipital sulcus. The long head of the biceps tendon is released, and the proximal portion is pulled out. While tensioning the proximal biceps tendon, the distal part can be mobilized and cut with scissors approximately 2 cm into the muscle. The tendon can now be prepared in a similar fashion as the hamstring tendons in anterior cruciate ligament reconstruction (Fig 4). Generally, a minimal length of 70 mm is harvested in all, with a diameter of approximately 6 mm.



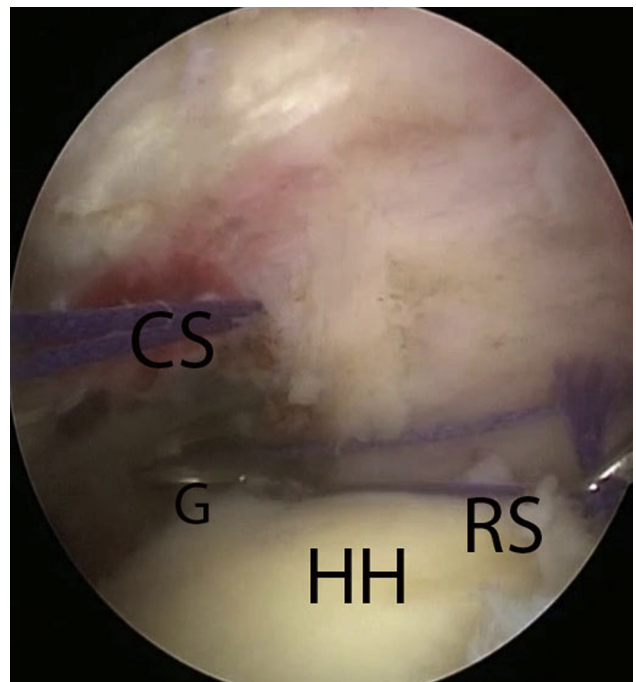
**Fig 5.** Mobilizing of the rotator cuff seen from a posterior portal of a right shoulder and the grasper inserted from a lateral portal. (G, grasper; GL, glenoid; RC, rotator cuff.)



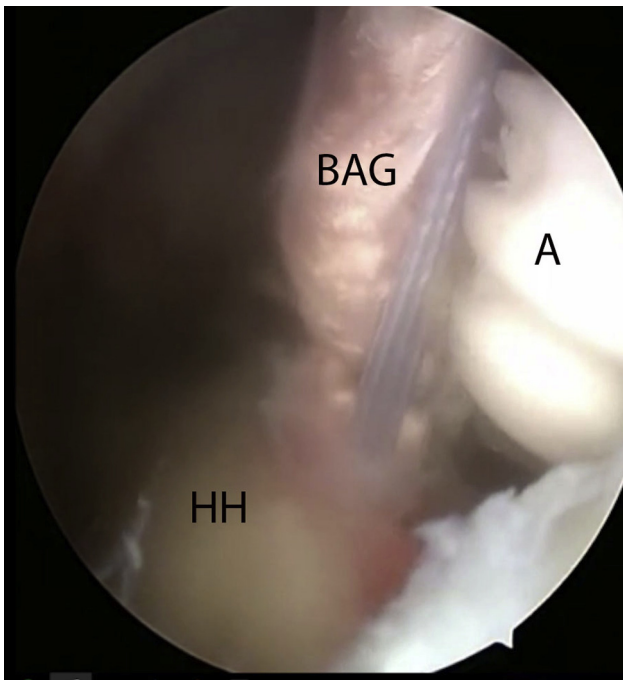
**Fig 6.** Measurement of the needed length of the biceps graft with help of a suture. Seen from a posterior portal. (CS, cuff suture; G, grasper; HH, humeral head; RS, ruler suture.)

### Cuff Preparation and Mobilization

The subacromial space is inspected, and a bursectomy is performed through a lateral portal to create a clear view of the remnants of the rotator cuff. Size and level of retraction are identified. A supporting suture is passed through the supraspinatus tendon and pulled laterally to see whether mobilizing close to the footprint is possible (Fig 5). An extensive release of the cuff is performed subacromially and between the cuff and the superior labrum with close attention to the suprascapular nerve, which passes approximately 10 mm medial to the glenoid rim.



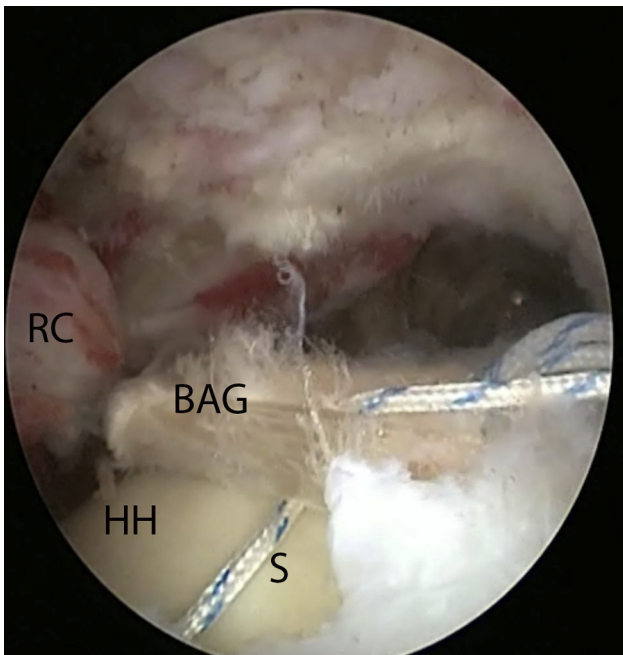
**Fig 7.** Final preparation of the biceps autograft with the anchor attached to the graft seen from a posterior portal of a right shoulder. (A, Swivellock tenodesis biocomposite anchor (7 × 19.1 mm; Arthrex); BAG, biceps autograft.)



**Fig 8.** Insertion of anchor with biceps autograft attached into the humeral head after drilling. Seen from a posterior portal of a right shoulder. (A, anchor; BAG, biceps autograft; HH, humeral head.)

### Partial Cuff Repair

In case of an L-shaped or reverse L-shaped rupture, one or more side-to-side sutures with nonabsorbable



**Fig 9.** Attaching the cuff to the new reconstructed rotator cable using sutures. Seen from a posterior portal of a right shoulder. (BAG, biceps autograft; HH, humeral head; RC, rotator cuff; S, suture.)

polyethylene sutures (Ultrabraid, Smith and Nephew, Andover, MA) is placed to achieve a partial cuff repair.

### Biceps Graft Preparation

After debridement of the footprint, a suture tensioned over the humeral head and marked at the planned locations of the tenodesis screws is used to measure the length of the biceps graft. (Fig 6). It usually measures around 30 mm. The tendon is prepared and marked, with 20 mm of tendon left on each side to be inserted into the humeral bone with the biotenodesis screws. In most cases, a tendon graft of 70 mm is needed (Fig 7). Swivellock tenodesis biocomposite anchors (7 × 19.1 mm) are used (Arthrex).

### Biceps Graft Fixation

An additional posterolateral portal is made to drill a hole for the posterior screw with a diameter equal to the tendon, approximately in the middle of the footprint of the infraspinatus on the greater tubercle. With the biceps autograft under tension, this posterior screw is tightly inserted until the premarked portion of the biceps tendon (20 mm; Fig 8). After positioning of the graft, a drill hole is made in the biceptal groove at the superior part of the lesser tubercle. The anterior tenodesis screw is placed while maintaining adequate traction on the graft. This results in a tensioned biceps autograft in posterior-to-anterior direction over the humeral head. We emphasize the tightening of the graft to prevent medialization during the cuff repair.

### Final Rotator Cuff Repair to Rotator Cable

The final step is the actual cuff repair. Nonabsorbable polyethylene sutures (Ultrabraid, Smith and Nephew) are used. The sutures are passed transversely around and through the biceps tendon autograft (Fig 9) The medial part of the sutures is passed through the infraspinatus and supraspinatus tendons with a suture device (Scorpion, Arthrex). An average of 5 sutures are needed in order to bring the rotator cuff to the biceps tendon autograft. The whole construct is tested for stability. The biceps tendon autograft is not fixed to the original footprint of the rotator cuff. Wounds are closed transcutaneously, and the arm is put in a shoulder sling immobilizer.

**Table 2.** Pearls and Pitfalls for Reconstruction of the Rotator Cable in Massive Rotator Cuff Tears

Pearls and Pitfalls
Harvest a biceps tendon of at least 70 mm
Harvest the biceps tendon as distally as possible
Use a suture as a measurement tool
Extensive release of the rotator cuff
Secure the biceps tendon tight over the humeral head
Use at least 4 sutures to secure the cuff to the reconstructed rotator cable

**Table 3.** Possible Advantages and Disadvantages of Using Biceps Autograft for Reconstruction Rotator Cable in Massive Rotator Cuff Tears

Advantages	Disadvantages
Anatomical reconstruction of the rotator cable	No fixation cuff to footprint
Biceps tendon is rich in collagen	Possible degenerative biceps tendon
Easy to harvest	High tension on cuff and tendon graft
Use of an autograft (biceps tendon)	Not possible in end-stage fatty infiltration
Arthroscopic technique	Not possible in end-stage retraction
No graft reactions	Extensive arthroscopic technique
Fixation of cuff to reconstructed rotator cable and not to footprint	
May prevent cuff arthropathy	

## Rehabilitation

The shoulder is immobilized for 6 weeks, during which passive movements were allowed under guidance of a physiotherapist. After 6 weeks, active training is started. Patients are seen 6 weeks and 3, 6, and 12 months postoperatively.

## Discussion

[Video 1](#) demonstrates an arthroscopic technique for functional reconstruction of massive, symptomatic rotator cuff tears by recreating the rotator cable with a biceps tendon autograft. The pearls and pitfalls are shown in [Table 2](#). Using the biceps tendon has several advantages.

As noted before, with this technique the natural rotator cable is restored using an autograft, avoiding graft reactions. Previous studies show that the biceps is rich in collagen, even when tendinopathy is present.<sup>8</sup> In all patients treated with this technique, the cuff tendons could be approximated to the graft after extensive mobilization with a tissue ablation device. The medialization of the biceps graft under tension may contribute to successful attachment of the cuff. This technique may also prevent proximalization of the humeral head in order to delay development of cuff arthropathy.

A possible risk is insufficient ingrowth into the graft. Tenocytes of the biceps tendon are pointed in a different direction than the rotator cuff tendons, but this is also seen in the natural rotator cable. Care should be taken for the suprascapular nerve when mobilizing the cuff past the glenoid rim; as mentioned before, this nerve can be as close as 10 mm. The fatty infiltration and retraction are part of the MRCT, yet they can make the surgery more challenging. Also, the unavoidable tension on the construct may contribute to a delayed healing process. When tensioned inadequately the forces of the cuff may result in insufficient leverage. One other limitation is the absence of the biceps tendon inside the glenohumeral joint if the biceps tendon is ruptured spontaneously or has severe tendinosis. In those cases a

hamstring graft can be used. The advantages and disadvantages are shown in [Table 3](#).

Reconstruction of the rotator cable using a biceps tendon autograft can be an option for the treatment of MRCTs. After harvesting, the biceps tendon is positioned as a cable using tenodesis screws and the remains of the cuff are secured to the graft. The graft is easy to harvest, and a more biomechanical reconstruction is created.

## Acknowledgment

The authors thank Tom Tieman for editing the video.

## References

- Läderrmann A, Denard PJ, Collin P. Massive rotator cuff tears: Definition and treatment. *Int Orthop* 2015;39:2403-2414.
- Deprés-Tremblay G, Chevrier A, Snow M, Hurtig MB, Rodeo S, Buschmann MD. Rotator cuff repair: A review of surgical techniques, animal models, and new technologies under development. *J Shoulder Elbow Surg* 2016;25:2078-2085.
- Gerber C, Maquieira G, Espinosa N. Latissimus dorsi transfer for the treatment of irreparable rotator cuff tears. *JBJS* 2006;88:113-120.
- Rhee YG, Cho NS, Lim CT, Yi JW, Vishvanathan T. Bridging the gap in immobile massive rotator cuff tears: Augmentation using the tenotomized biceps. *Am J Sports Med* 2008;36:1511-1518.
- Burkhart SS, Esch JC, Jolson RS. The rotator crescents and rotator cable: An anatomic description of the shoulder's "suspension bridge". *Arthroscopy* 1993;9:611-616.
- Mesiha MM, Derwin KA, Sibole SC, Erdemir A, McCarron JA. The biomechanical relevance of anterior rotator cuff cable tears in a cadaveric shoulder model. *J Bone Joint Surg Am* 2013;95:1817-1824.
- Rahu M, Kolts I, Pöldoja E, Kask K. Rotator cuff tendon connections with the rotator cable. *Knee Surg Sports Traumatol Arthrosc* 2017;25:2047-2050.
- Mazzocca AD, McCarthy MB, Ledgard FA, et al. Histomorphologic changes of the long head of the biceps tendon in common shoulder pathologies. *Arthroscopy* 2013;29:972-981.