

University of Groningen

## Education, Practice, and Competency Gaps of Anesthetists in Ethiopia

Kibwana, Sharon; Teshome, Mihereteab; Molla, Yohannes; Carr, Catherine; Akalu, Leulayehu; van Roosmalen, Jos; Stekelenburg, Jelle

*Published in:*  
Journal of perianesthesia nursing

*DOI:*  
[10.1016/j.jopan.2017.02.001](https://doi.org/10.1016/j.jopan.2017.02.001)

**IMPORTANT NOTE: You are advised to consult the publisher's version (publisher's PDF) if you wish to cite from it. Please check the document version below.**

*Document Version*  
Publisher's PDF, also known as Version of record

*Publication date:*  
2018

[Link to publication in University of Groningen/UMCG research database](#)

*Citation for published version (APA):*

Kibwana, S., Teshome, M., Molla, Y., Carr, C., Akalu, L., van Roosmalen, J., & Stekelenburg, J. (2018). Education, Practice, and Competency Gaps of Anesthetists in Ethiopia: Task Analysis. *Journal of perianesthesia nursing*, 33(4), 426-435. <https://doi.org/10.1016/j.jopan.2017.02.001>

**Copyright**

Other than for strictly personal use, it is not permitted to download or to forward/distribute the text or part of it without the consent of the author(s) and/or copyright holder(s), unless the work is under an open content license (like Creative Commons).

**Take-down policy**

If you believe that this document breaches copyright please contact us providing details, and we will remove access to the work immediately and investigate your claim.

*Downloaded from the University of Groningen/UMCG research database (Pure): <http://www.rug.nl/research/portal>. For technical reasons the number of authors shown on this cover page is limited to 10 maximum.*



## HUMAN RANDOMIZED CONTROLLED TRIAL

# The influence of different soft-tissue grafting procedures at single implant placement on esthetics: A randomized controlled trial

Elise G. Zuiderveld<sup>1</sup> | Henny J.A. Meijer<sup>1,2</sup> | Arjan Vissink<sup>1</sup> | Gerry M. Raghoobar<sup>1</sup>

<sup>1</sup>Department of Oral and Maxillofacial Surgery, University Medical Center Groningen, University of Groningen, Groningen, The Netherlands

<sup>2</sup>Department of Implant Dentistry, Dental School, University Medical Center Groningen, University of Groningen, Groningen, The Netherlands

**Correspondence**

EG Zuiderveld, Department of Oral and Maxillofacial Surgery, University Medical Center Groningen, PO Box 30.001, NL-9700 RB Groningen, The Netherlands.  
Email: e.zuiderveld@umcg.nl

**Abstract**

**Background:** Soft-tissue grafting to thicken the soft tissue around dental implants was proposed to ameliorate the esthetic outcome. Traditionally, connective tissue is used as a grafting material, but a xenogeneic collagen matrix was introduced as an alternative to reduce patient morbidity.

**Methods:** A total of 60 patients randomly received either no graft ( $n = 20$ , NG group), a connective tissue graft ( $n = 20$ , CTG group), or a xenogeneic collagen matrix ( $n = 20$ , XCM group) when an implant was placed in a preserved alveolar ridge. Changes in mid-buccal mucosal level (MBML) at 1 ( $T_1$ ) and 12 ( $T_{12}$ ) months after final implant crown placement were compared to the pre-extraction level. Additionally, esthetics, marginal bone level, clinical peri-implant parameters, and patient satisfaction were assessed.

**Results:** At  $T_{12}$ , mean changes in MBML were  $-0.48 \pm 1.5$  mm,  $-0.04 \pm 1.1$  mm, and  $-0.17 \pm 1.3$  mm in the NG, CTG, and XCM groups ( $P = 0.56$ ), respectively. Regarding the other outcome variables, no significant intergroup differences were observed.

**Conclusions:** Soft-tissue grafting at single implant placement in preserved alveolar ridges does not result in a better esthetic outcome or in better peri-implant health and should not be considered as a standard procedure.

**KEYWORDS**

alveolar ridge augmentation, connective tissue, esthetics, gingival recession, single-tooth implants

## 1 | INTRODUCTION

Single-implant treatment in the maxillofacial esthetic zone to replace a single failing tooth is a valuable treatment modality.<sup>1,2</sup> However, long-term data demonstrate stable esthetics in just 37% of the cases.<sup>3</sup>

It is presumed that, to achieve stable esthetics, the implant should be inserted in an optimal three-dimensional position in the available bone dimensions, with preservation of sufficient buccal bone volume for a proper soft-tissue support.<sup>4,5</sup> Because the buccal bone wall in most sites of the maxillary esthetic zone is very thin ( $\leq 1$  mm)<sup>6</sup> and associated with significant buccal bone resorption following tooth removal,<sup>7,8</sup> correct three-dimensional implant placement might be impaired. Therefore, to reduce bone dimensional

changes, augmentation of the extraction socket prior to implant placement was proposed to preserve both the alveolar ridge<sup>9,10</sup> and buccal soft tissue.<sup>11</sup> However, bone loss in width and height is still expected, despite alveolar ridge preservation, as are soft-tissue changes.<sup>11,12</sup>

To compensate for soft-tissue changes, the application of a connective tissue graft (CTG) was proposed to increase soft-tissue volume<sup>13,14</sup> and establish a better soft-tissue profile. According to the literature, grafting the buccal peri-implant soft tissue with a CTG effectively increases the soft tissue contour.<sup>15–19</sup> Additionally, connective tissue grafting (CT grafting) was demonstrated to be effective in preserving the mid-buccal mucosal level.<sup>16,19,20</sup> In contrast to this, a retrospective study<sup>21</sup> showed that CT grafting resulted in minimal changes in soft-tissue volume and level without



significant difference compared to no soft-tissue grafting over 5 years of follow-up.

As an alternative to CTG as the gold standard for soft-tissue augmentation,<sup>22,23</sup> the use of a xenogeneic collagen matrix (XCM) was introduced to decrease patient morbidity caused by the harvesting procedure of the CTG.<sup>24,25</sup> In several studies, applying a XCM to increase soft-tissue thickness was found to be as effective as a CTG.<sup>26–28</sup> XCM was also demonstrated to be effective in the long term, with stable esthetics.<sup>29</sup> In contrast to this, Cairo et al.<sup>30</sup> observed a more effective increase in soft-tissue thickness with the application of CTG than with XCM. In terms of recession reduction using a coronally advanced flap with either a CTG or XCM, both achieved comparable and stable results.<sup>31,32</sup>

As far as we know, Froum et al.<sup>33</sup> is the only study comparing the effect of applying a XCM with no soft tissue graft during implant placement. They found no differences between the groups, but intragroup comparisons revealed that, compared to baseline levels, patients receiving the XCM showed a significant thickening of the buccal keratinized tissue. There is a paucity of papers evaluating the effect of applying a CTG or XCM on mid-buccal mucosa recession, although CT grafting has been demonstrated to be effective and XCM was judged to be comparable to CTG. Therefore, we assessed whether grafting the buccal peri-implant mucosa using either a CTG or XCM at implant placement in preserved alveolar ridges resulted in less mid-buccal mucosa recession compared to no grafting.

## 2 | MATERIALS AND METHODS

### 2.1 | Study design

Between December 2012 and July 2015, all consecutive patients (aged  $\geq 18$  years) referred for implant treatment due to a single failing maxillary tooth (incisor, canine, first premolar) were invited to participate in this randomized controlled clinical study. The study was approved by our Medical Ethical Committee (NL43085.042.13) and registered in the Dutch trial register ([www.trialregister.nl](http://www.trialregister.nl): NTR3815; 01-23-2013). The following inclusion and exclusion criteria had to be fulfilled: adequate oral hygiene (i.e., modified plaque and sulcus bleeding index  $\leq 1$ );<sup>34</sup> diastema width  $\geq 6$  mm and sufficient interocclusal space for a non-occluding temporary crown, no medical and general contraindications for the surgical procedure (i.e., ASA score  $\geq III$ );<sup>35</sup> no active and uncontrolled periodontal disease (probing pocket depths  $\geq 4$  mm and bleeding on probing (index score  $> 1$ ); non-smoker; no head and neck radiation; not pregnant (Fig. 1). Patients provided written informed consent before enrollment.

According to a preoperative cone beam computed tomography scan, insufficient bone volume on the palatal side was

present to place an implant with primary stability. Additionally, all patients presented with a vertical buccal bone wall defect  $> 5$  mm of the extraction socket, assessed after extraction by a bone sounding technique. Therefore, all extraction sockets were augmented prior to implant insertion and closed with a mucosa graft. Four months thereafter, patients were treated with an implant\* and then randomly distributed, via sealed envelopes opened by an uninvolved research nurse, to receive either:

- No soft tissue graft (no graft [NG] group;  $n = 20$ ),
- A connective tissue graft harvested from the palate (connective tissue graft [CTG] group,  $n = 20$ ),
- A xenogeneic collagen matrix<sup>†</sup> (xenogeneic collagen matrix [XCM] group,  $n = 20$ ).

### 2.2 | Intervention procedure

One day prior to implant surgery, patients began taking antibiotics (amoxicillin 500 mg, three times daily for 7 days or clindamycin 300 mg, four times daily for 7 days in case of amoxicillin allergy) and used a 0.2% chlorhexidine mouthwash (twice daily for 7 days) for oral disinfection.

All surgical procedures were performed under local anesthesia by the same oral and maxillofacial surgeon (GMR). In all groups, the extraction socket was augmented with the tuberosity bone graft shaped to match the buccal bone defect and inserted with the cortical side facing the periosteum (Fig. 2A). A mixture of autologous bone and spongy bone substitute<sup>‡</sup> (0.25–1.0 mm) was tightly packed into the extraction socket (Fig. 2B). The extraction socket was then closed with a full-thickness mucosa graft (Fig. 2C), which was also harvested from the maxillary tuberosity region.

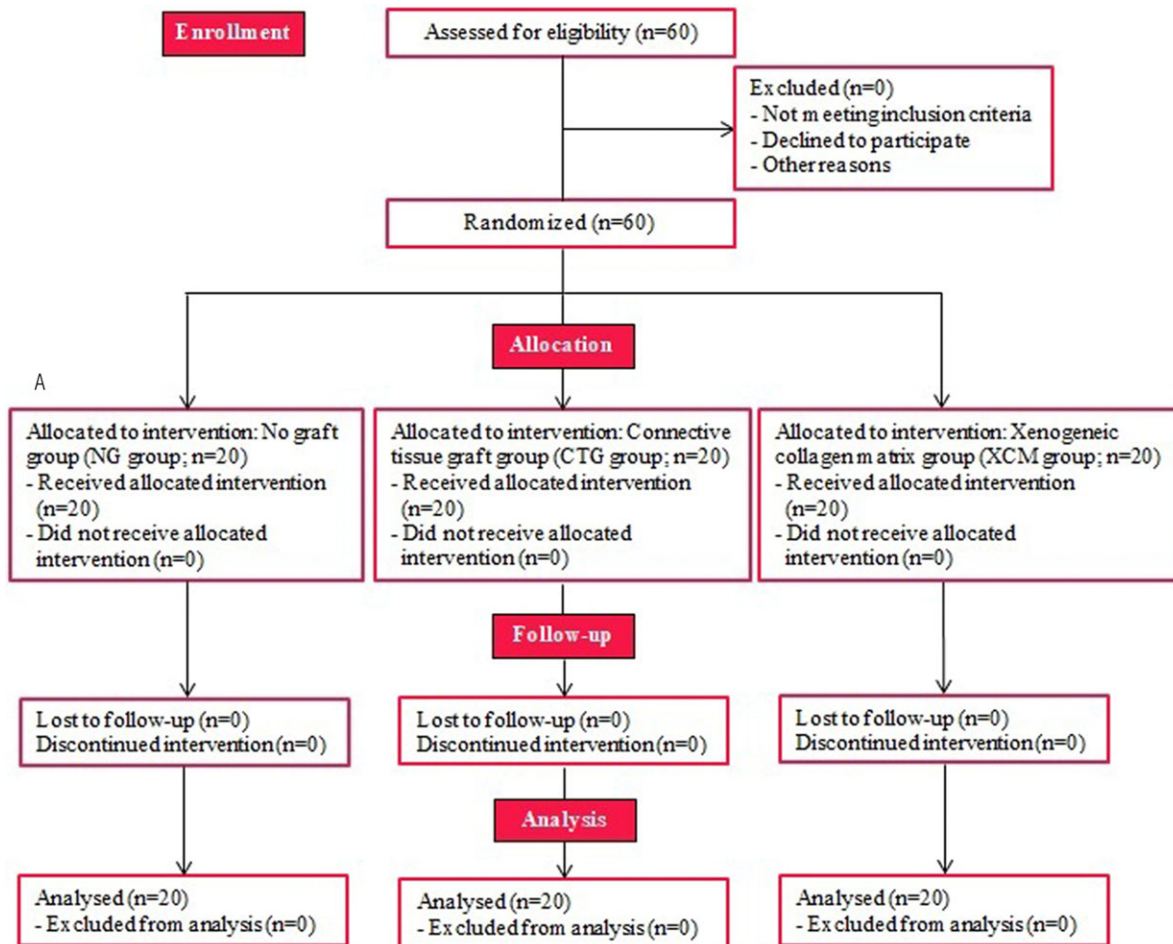
The implant was inserted 4 months after the augmentation procedure (Fig. 3A). A small palatal crest incision was made to expose the alveolar ridge, followed by extensions through the buccal and palatal sulcus of the adjacent teeth and a divergent relieving incision at the distal tooth to elevate the minimal mucoperiosteal flap. The implant site was prepared according to the manufacturer's manual and with a surgical template representing the ideal position of the prospective implant crown. All implants were installed with a torque controller with 45 Ncm and provided with a cover screw. The implant shoulder was placed 3 mm apical to the most facial and cervical aspect of the prospective clinical crown to ensure a proper emergence profile, including being at the level as the alveolar bone.

The randomization procedure was done immediately after implant installation. Regarding the CTG group, the CTG was

\* Nobel Replace CC, Nobel Biocare, Gothenburg, Sweden

<sup>†</sup> Mucograft, Geistlich Pharma AG, Wolhusen, Switzerland

<sup>‡</sup> Bio-Oss, Geistlich Pharma AG, Wolhusen, Switzerland



**FIGURE 1** Cohort flow diagram

harvested from the palate (Fig. 3B). Both the CTG and the XCM (XCM group) were placed in the prepared mucoperiosteal flap at the facial site and secured with 4-0 acrylic vertical and horizontal mattresses\* (Fig. 3C-F).

The control group did not have a graft placed in the prepared mucoperiosteal flap. In all groups, the wound at the implant site was closed with 5-0 nylon sutures.† All sutures were removed 2 weeks after surgery. During the healing phase, patients wore a removable partial denture that did not interfere with the wound.

After 3 months, the implants were uncovered and an implant-level impression was made for the fabrication of a screw-retained provisional crown in the dental laboratory. All implants had been installed with a corresponding healing abutment. The provisional crown was fitted that same day onto the implant with 20 Ncm by a manual torque wrench and adjusted to function free from centric and eccentric contact with the antagonist teeth. Patients were instructed to follow a soft diet and to avoid exerting force on the provisional restoration.

Three months later, a final, open-tray implant-level impression was taken using polyether impression material.‡ An individualized zirconia abutment§ was made from the digitally designed final implant crown. Depending on the location of the screw access hole, the final crown was screw retained or cement retained. Abutment screws were torqued with 35 Ncm.

All prosthetic procedures were accomplished by two prosthodontists (HJAM and CS).

### 2.3 | Photographic assessment

The primary outcome measure was the change in mid-buccal mucosal level (MBML), assessed from standardized intra-oral photographs¶ taken before tooth extraction ( $T_{pre}$ ) and 1 ( $T_1$ ) and 12 months ( $T_{12}$ ) after final implant crown placement. Changes in interproximal mucosal levels (IML) were measured the same way.

\* VICRYL, Ethicon, Johnson & Johnson, Amersfoort, The Netherlands

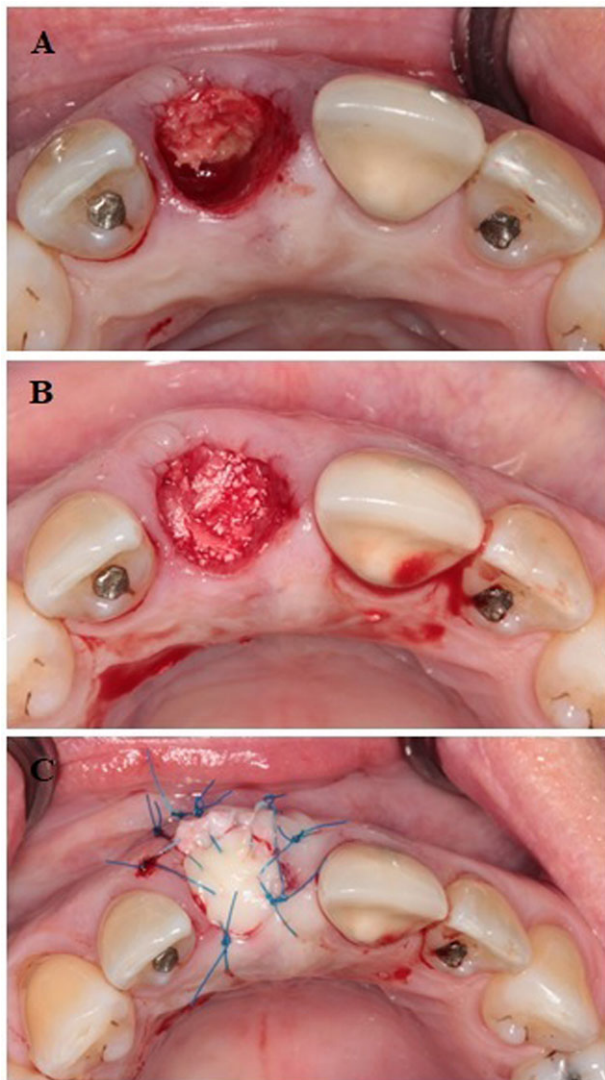
† Ethilon, Ethicon, Johnson & Johnson, Amersfoort, The Netherlands

‡ Impregum Penta, 3M ESPE, Seefeld, Germany

§ NobelProcera, Nobel Biocare AB, Gothenburg, Sweden

¶ Canon EOS 650D with ring flash, Tokyo, Japan



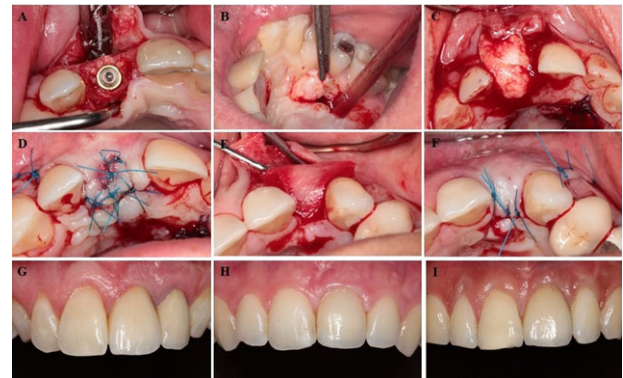


**FIGURE 2** (A) Clinical view of the tuberosity bone graft in the extraction socket grafting the buccal bone defect (B) Clinical view of a mixture of autologous bone and spongy bone substitute tightly packed into the extraction socket (C) Clinical view of the extraction socket closed with a full-thickness mucosa graft

The photographs were calibrated by a periodontal probe\* held close to and parallel to the long axis of the tooth next to the implant. Full-screen analysis was done using a digital picture editing program.† MBML changes were measured at  $T_{pre}$  and  $T_1$  by drawing a horizontal line through the incisal edges of the adjacent teeth, and the distance between this line and the mucosal margin was calculated (Supplementary Figure 1A, B). The  $T_1$  to  $T_{12}$  MBML changes were assessed from the length of the implant crown (Supplementary Figure 1 C, D). MBML changes between  $T_{pre}$  and  $T_{12}$  were calculated by adding both measurements.<sup>20</sup>

\* Williams color-coded probe, Hu-Friedy, Chicago, IL

† Adobe Photoshop CS5.1, Adobe Systems Inc., San Jose, CA



**FIGURE 3** (A) Clinical view of implant placed in the preaugmented alveolar ridge (B) Harvesting procedure of connective tissue graft from the palate (C) Placement of the connective tissue in the prepared mucoperiosteal envelope (D) Connective tissue graft secured with horizontal and vertical mattresses (E) Placement of the XCM in the prepared mucoperiosteal envelope (F) XCM secured with horizontal and vertical mattress sutures (G) Clinical situation 1 year after rehabilitation of the left central incisor with an implant supported crown in the NG group (H) Clinical situation 1 year after rehabilitation of the left central incisor with an implant supported crown in the CTG group (I) Clinical situation 1 year after rehabilitation of the left central incisor with an implant supported crown in the XCM group

Peri-implant mucosa and implant crown esthetics were assessed from photographs taken at  $T_{12}$  using the Pink Esthetic Score-White Esthetic Score (PES/WES).<sup>36</sup>

## 2.4 | Radiographic assessment

At  $T_1$  and  $T_{12}$ , the marginal bone level was measured on standardized digital intraoral radiographs taken with an individualized device.<sup>37</sup> The distance between the implant platform and first bone-to-implant contact along the implant was measured using specifically designed software. Bone above the implant platform was scored as no bone loss.

## 2.5 | Clinical assessments

Clinical data of any implant was collected by a single examiner (EGZ), who was blinded regarding group allocation, at  $T_1$  and  $T_{12}$ . The following parameters were assessed: 1) gingival biotype, as measured by means of transparency of a periodontal probe through the gingival margin of the failing tooth (only at  $T_{pre}$ );<sup>38</sup> 2) probing pocket depth using a periodontal probe at the mesio-buccal, mid-buccal, and disto-buccal and mid-palatal aspect; 3) amount of plaque (modified plaque index);<sup>34</sup> 4) bleeding after probing (modified sulcus bleeding index);<sup>34</sup> 5) gingival condition (gingival-index);<sup>39</sup> 6) width of the keratinized mucosa: no keratinized mucosa, <1 mm of keratinized mucosa, 1–2 mm of keratinized mucosa,  $\geq 2$  mm of keratinized mucosa; 7) volume of the interproximal papilla, using the papilla index;<sup>40</sup> 8) implant

survival; 9) implant success, defined as  $\leq 1$  mm marginal bone loss one year after loading and  $\leq 0.2$  mm thereafter and the absence of pain, infection, mobility, peri-implant radiolucency, and alteration in sensitivity.<sup>41</sup>

## 2.6 | Patient satisfaction

The Oral Health Impact Profile-14 (OHIP-14) questionnaire,<sup>42</sup> including questions about overall satisfaction with the current dentition and compared to the preoperative situation to be answered on a 10-cm Visual Analog Scale (VAS), were completed at  $T_{pre}$ ,  $T_1$ , and  $T_{12}$ . Additionally, questions regarding esthetics and satisfaction with the treatment procedure to be answered on a 10-cm VAS were provided. All questionnaires were handed out and filled in privately before collecting the clinical data.

## 2.7 | Statistical analysis

Sample size was calculated using software.\*<sup>43</sup> A recession of the mid-buccal mucosa of 0.5 mm from implant placement to 12 months after placement of the final implant crown was considered to be a clinically relevant difference between the groups. With an expected standard deviation of 0.6 mm, as derived from the literature,<sup>44</sup> and a power of 80%, a minimum of 18 patients per group would be needed. We decided to include 20 patients per group in case of any withdrawals from the study.

The Shapiro-Wilk test was used to assess the normal distribution of the continuous variables and Normal Q-Q-plots were depicted. Normal distributed data were analysed using analysis of variance. Non-normal distributed data were evaluated with Kruskal-Wallis tests. Within-group comparisons were done using Wilcoxon tests. Analysis of categorical data was performed with  $\chi^2$  or Fisher exact tests.

The Pearson correlation coefficient was calculated to explore the influence of gingival biotype on the mid-buccal mucosal level.

All analyses were done using a  $P$  value of 0.05 to indicate statistical significance and were performed using statistical software.<sup>†</sup>

## 3 | RESULTS

Baseline characteristics of the 60 included patients are depicted in Table 1. No significant differences between the groups were noticed for sex, age, gingival biotype, implant site location, implant length, or implant diameter. All patients received their assigned treatment (Fig. 1). Figure 3G-I shows

the clinical situation 1 year after placement of the final implant crown in the NG, CTG, and XCM groups, respectively. No signs of soft-tissue complication, extensive bleeding, or perforation through the maxillary sinuses were noted at the donor site. During follow-up, no objective signs of infection were observed. No implants had been lost at  $T_{12}$  (implant survival rate of 100%) and none displayed marginal bone loss in excess of 1 mm; they also fulfilled all the other success criteria (success rate of 100%).

### 3.1 | Reliability of photographic and radiographic measurements

Interclass correlations (ICCs) for the photographic measurements were high: 0.88 (95% CI 0.72-0.95) and 0.83 (95% CI 0.60-0.93) for the intra- and interobserver agreements, respectively. The same applied for radiographic measurements: 0.71 (95% CI 0.32-0.87) and 0.9 (95% CI 0.75-0.96) for the intra- and interobserver agreements. The ICCs for esthetic assessments were 0.86 (95% CI 0.68-0.94) and 0.90 (95% CI 0.77-0.96) for the intra- and interobserver agreements, respectively.<sup>20</sup>

### 3.2 | Change in mid-buccal and interproximal mucosal level

No significant differences in MBML changes between the groups were observed (Table 2). At  $T_{12}$ , the MBML showed an average loss, compared to baseline levels, of  $0.48 \pm 1.5$  mm in the NG group,  $0.04 \pm 1.1$  mm in the CTG group, and  $0.17 \pm 1.3$  mm in the XCM group ( $P = 0.56$ ). The changes in MBML between  $T_{pre}$  and  $T_1$  and between  $T_1$  and  $T_{12}$  were negligible in all groups ( $P = 0.67$ ;  $P = 0.15$ , respectively). Pretreatment gingival biotype had no influence.

IML changes at  $T_{12}$  of both implant sides were comparable for the control and both test groups (mesial:  $P = 0.63$ ; distal:  $P = 0.85$ ; Table 2).

### 3.3 | Change in radiographic marginal bone level

Between  $T_1$  and  $T_{12}$  median (IQR) marginal bone level changes were 0.00 (−0.18 to 0.00) for the mesial side and 0.00 (−0.02 to 0.39) for the distal side in the NG group, respectively. For the CTG group changes were 0.00 (−0.13 to 0.01) and 0.00 (−0.29 to 0.06) and for the XCM group changes were 0.00 (−0.21 to 0.27) and 0.00 (−0.08 to 0.15), respectively. Changes were comparable between the groups (mesial side:  $P = 0.67$ , distal side:  $P = 0.24$ ; Table 2).

### 3.4 | Clinical outcome

Outcomes concerning probing pocket depths and papilla volume around the implant crown at  $T_1$  and  $T_{12}$  are depicted

\* G\*power 3.1, Heinrich-Heine University, Düsseldorf, Germany

† SPSS Statistics 23.0, SPSS Inc., IBM Corporation, Chicago, IL

**TABLE 1** Patient characteristics per study group

Variable	NG group n = 20	CTG group n = 20	XCM group n = 20
Male/female ratio	7/13	11/9	7/13
Age (years) (mean ± SD [range])	42.0 ± 15.7 (18–71)	38.2 ± 16.7 (18–69)	45.4 ± 17.0 (18–73)
Gingival biotype thin/thick	15/5	13/7	10/10
Implant site location I <sub>1</sub> /I <sub>2</sub> /C/P <sub>1</sub>	9/8/0/0	16/3/1/0	11/4/3/2
Implant length (mm) 13/16	10/10	11/9	12/8
Implant diameter (mm) 3.5/4.3	9/11	4/16	5/ 15

in Table 2. None of the implant crowns displayed plaque at T<sub>12</sub>. Upon probing, 55% of the patients in the NG and CTG groups and 45% of the XCM group demonstrated no bleeding (score 0). 30% of the NG and CTG patients and 40% of XCM patients had an isolated bleeding spot (score 1). A score of 2 (confluent red line) was encountered in 15% of the patients across all the groups.

At T<sub>12</sub>, the peri-implant mucosa was healthy in almost all patients; the exceptions were one patient in the NG group and one in the CTG group who showed signs of mild inflammation. 90%, 75%, and 70% of the patients in the NG, CTG, and XCM groups, respectively, displayed more than 2 mm of keratinized mucosa (score 3). A 1- to 2-mm-wide zone of keratinized mucosa (score 2) was seen in 5%, 15%, and 10% of patients in the NG, CTG, and XCM groups, respectively. In the XCM group, 5% of the patients had a keratinized mucosa of up to 1 mm (score 1). In the NG, CTG, and XCM groups, 5%, 10%, and 15%, respectively, of the patients showed no keratinized mucosa (score 0).

### 3.5 | Esthetic assessment

No significant intergroup differences were found with respect to PES and WES total scores or the separate scoring items (Table 2). With respect to the peri-implant mucosa, acceptable levels of esthetics (PES/WES-score ≥6) were reached in 75% of the NG group, 80% of the CTG group, and 65% of the XCM group. With respect to the implant crown, acceptable levels were reached in 100% of the NG group, 100% of the CTG group, and 95% of the XCM group.

### 3.6 | Patient satisfaction

At T<sub>12</sub>, VAS scores showed no difference in patient satisfaction, except for satisfaction with the implant and implant crown (Table 3). Satisfaction with the current dental situation improved significantly between baseline and T<sub>1</sub> ( $P = 0.00$ ), whereas no further improvement was observed up to 1 year after placement of the final crown (T<sub>12</sub>;  $P = 0.94$ ). No intergroup differences were found for the total OHIP questionnaire scores. Within-group comparisons showed a favorable

improvement between T<sub>pre</sub> and T<sub>1</sub> ( $P = 0.00$ ), which continued between T<sub>1</sub> and T<sub>12</sub> ( $P = 0.00$ ).

## 4 | DISCUSSION

This randomized controlled trial suggests that neither the application of a CTG nor the application of a XCM at implant placement in healed and preserved extraction sites results in better retention of the level of the mid-buccal mucosa or to a better esthetic outcome compared to the application of no soft-tissue graft at implant placement.

The observed recession of the mid-buccal mucosa in all groups in this study was minor and within clinically acceptable levels.<sup>21</sup> Changes in MBML in the NG group and CTG group were in line with recent literature.<sup>16,44,45</sup> Comparing the application of a CTG to no soft-tissue graft, we observed no difference for change in MBML, which is in line with a recent study.<sup>21</sup> The interpretation of their results, however, is limited by the retrospective study design and a small sample size. Froum et al.,<sup>33</sup> evaluated the effect of a XCM in a randomized controlled clinical trial compared to no soft-tissue graft and reported an outcome comparable to ours regarding the change in height and thickness of the peri-implant soft tissue. However, that study has limitations. Only patients with a thin and deficient keratinized mucosa needing an implant in the posterior region were included and were followed for just 3 months after surgery. This is in contrast to our study, which evaluated single implant placement in the anterior maxilla up to 1 year after loading, without selecting patients according to volume and width of the keratinized mucosa.

The fact that we observed no significant difference between the groups in change in MBML might be explained by the augmentation surgery of fresh extraction sockets with slowly resorbing grafting material and sealing the socket with a mucosa graft, which has been demonstrated to be beneficial in preserving the buccal bone and soft tissue contour.<sup>46,47</sup> We hypothesize that this augmentation technique already may have contributed to the preservation of sufficient peri-implant soft tissue, which in turn may have led to no further effect when applying a soft-tissue graft at implant placement.



**TABLE 2** Changes in marginal soft tissue level, marginal bone level and clinical outcome measures from baseline to 12 months after final crown placement

Variable	NG group (n = 20) T <sub>pre</sub> -T <sub>1</sub> Mean ± SD	CTG group (n = 20) T <sub>1</sub> -T <sub>12</sub> Mean ± SD	XCM group (n = 20) P value	NG group (n = 20) T <sub>1</sub> -T <sub>12</sub> Mean ± SD	CTG group (n = 20) P value	XCM group (n = 20) T <sub>pre</sub> -T <sub>12</sub> Mean ± SD	NG group (n = 20) P value	CTG group (n = 20) Mean ± SD	XCM group (n = 20) P value
<b>MBML (mm)</b>	-0.34 ± 1.5	-0.01 ± 1.1	-0.001 ± 1.3	0.67	0.15	-0.15 ± 0.2	-0.03 ± 0.2	-0.16 ± 0.2	0.15
<b>IML (mm)</b>									
Mesial of implant	-0.9 ± 1.2	-0.9 ± 0.8	-0.4 ± 0.9	0.14	0.08	0.2 ± 0.4	0.1 ± 0.4	-0.1 ± 0.6	0.08
Distal of implant	-0.9 ± 1.1	-0.9 ± 0.8	-0.9 ± 1.0	0.95	0.29	0.1 ± 0.6	0.3 ± 0.5	0.02 ± 0.4	0.29
<b>MBL (mm)</b>									
Mesial of implant	NA	NA	NA						
Distal of implant	0.5 (0.0-0.9)	0.3 (0.0-0.9)	0.7 (0.3-1.6)	0.07	0.96	0.4 (0.0-1.1)	0.5 (0.0-1.0)	0.6 (0.0-1.1)	0.96
<b>PES total (0-10)</b>									
Mesial papilla	6.6 ± 1.5	7.0 ± 2.4	6.1 ± 1.7	0.71					
Distal papilla	1.5 ± 0.5	1.7 ± 0.5	1.4 ± 0.6	0.38					
Curvature of facial mucosa	1.4 ± 0.5	1.4 ± 0.6	1.3 ± 0.4	0.36					
Level of facial mucosa	1.4 ± 0.6	1.6 ± 0.5	1.5 ± 0.5	0.85					
Root convexity/soft tissue color and texture	1.3 ± 0.8	1.4 ± 0.6	1.1 ± 0.8	0.34					
<b>WES total (0-10)</b>									
Tooth form	1.1 ± 0.8	1.0 ± 0.7	1.0 ± 0.6	0.61					
Outline/volume	8.7 ± 0.9	8.9 ± 1.2	8.3 ± 1.6	0.39					
Color (hue/value)	1.8 ± 0.4	1.8 ± 0.4	1.6 ± 0.5	0.26					
Surface texture	1.9 ± 0.2	1.9 ± 0.4	1.8 ± 0.4	0.51					
Translucency/characterization	1.7 ± 0.5	1.8 ± 0.5	1.7 ± 0.6	0.49					
	1.7 ± 0.5	1.8 ± 0.4	1.8 ± 0.4	0.80					
	1.6 ± 0.5	1.7 ± 0.5	1.5 ± 0.7	0.57					

(Continues)





TABLE 2 (Continued)

Variable	NG group (n = 20) T <sub>pre</sub> -T <sub>1</sub> Mean ± SD	CTG group (n = 20) Mean ± SD	XCM group (n = 20)	P value	NG group (n = 20) T <sub>1</sub> -T <sub>12</sub> Mean ± SD	CTG group (n = 20) Mean ± SD	XCM group (n = 20)	P value	NG group (n = 20) T <sub>pre</sub> -T <sub>12</sub> Mean ± SD	CTG group (n = 20) Mean ± SD	XCM group (n = 20)	P value
<b>PES/WES total (0-20)</b>												
<i>Probing pocket depth (mm)</i>	-	-	-	-					15.3 ± 1.9	15.9 ± 2.2	14.4 ± 2.8	0.30
Mesial of implant	2.5 ± 1.1	2.4 ± 1.3	2.8 ± 1.2	0.43	2.9 ± 1.3	3.0 ± 1.3	3.0 ± 1.9	0.87	2.9 ± 1.3	3.1 ± 1.2	2.3 ± 1.0	0.03
Mid-buccal of implant	2.7 ± 1.2	3.3 ± 1.2	2.8 ± 1.6	0.24	2.9 ± 0.9	3.0 ± 1.2	3.2 ± 1.2	0.57	2.9 ± 0.9	3.0 ± 1.2	2.4 ± 0.7	0.10
Distal of implant	2.3 ± 0.6	2.7 ± 1.1	2.9 ± 0.9	0.03	2.0 ± 0.8	2.5 ± 0.7	2.6 ± 0.8	0.04	3.3 ± 1.1	3.0 ± 1.2	3.2 ± 1.2	0.04
Palatal of implant	2.0 ± 0.8	2.5 ± 0.7	2.6 ± 0.8	0.10					1.9 ± 0.8	2.4 ± 0.5	2.4 ± 0.7	
<b>Papilla volume (0/1/2/3/4) (%)</b>												
<i>Mesial/distal of implant</i>												
No papilla (score 0)	0/0	0/0	0/0		0/0	0/0	0/0		0/0	0/0	0/0	
Less than half papilla (score 1)	5/5	0/5	15/20		5/5	0/5	15/20		0/0	0/0	10/10	
At least half papilla (score 2)	65/35	15/35	25/35		65/35	15/35	25/35		45/55	15/25	35/50	
Entire papilla (score 3)	30/40	85/60	60/45		30/40	85/60	60/45		55/45	85/75	55/40	
Hyperplastic papilla (score 4)	0/0	0/0	0/0		0/0	0/0	0/0		0/0	0/0	0/0	

NA, not assessed.

Resulting negative values of subtracting the baseline value (T<sub>pre</sub>) from T<sub>1</sub> and T<sub>12</sub> means recession, positive values mean tissue gain.

PES/WES not assessed at T<sub>pre</sub> and T<sub>1</sub>, because T<sub>12</sub> was most meaningful.



**TABLE 3** Patient satisfaction regarding general satisfaction, esthetics, and treatment procedure

	NG group (n = 20) T <sub>pre</sub> Median (IQR)	CTG group (n = 20)	XCM group (n = 20)	P value	NG group (n = 20) T <sub>1</sub> Median (IQR)	CTG group (n = 20)	XCM group (n = 20)	P value	NG group (n = 20) T <sub>12</sub> Median (IQR)	CTG group (n = 20)	XCM group (n = 20)	P value
<b>VAS-questions (0-10)</b>												
How satisfied are you with your current dental situation?	5.8 (3.6-6.3)	5.5 (3.9-6.4)	4.9 (2.7-6.4)	0.65	8.1 (7.4-8.9)	7.5 (7.2-8.2)	8.8 (7.9-9.7)	0.01	8.2 (7.4-8.8)	7.9 (6.8-9.0)	8.8 (7.6-9.6)	0.27
How satisfied are you with your current dental situation compared to the situation before treatment?	-	-	-		8.6 (8.0-9.7)	8.4 (7.5-9.3)	9.2 (7.8-9.9)	0.37	8.5 (7.8-9.1)	8.5 (8.2-9.7)	9.3 (8.7-9.6)	0.15
How satisfied are you with the implant and the implant crown?	-	-	-		8.9 (7.9-9.6)	8.6 (8.0-9.2)	9.7 (8.9-10.0)	0.02	8.7 (8.3-9.5)	8.4 (6.9-9.2)	9.3 (8.8-10.0)	0.04
<b>Esthetics (0-10)</b>												
Color of the crown	-	-	-		9.4 (8.6-9.9)	8.8 (7.4-9.8)	9.8 (9.4-9.9)	0.02	9.3 (7.2-9.9)	8.8 (6.8-9.9)	9.6 (8.9-10.0)	0.30
Form of the crown	-	-	-		9.5 (8.5-9.9)	8.9 (7.3-9.8)	9.8 (9.0-9.9)	0.10	9.0 (7.7-9.7)	9.3 (7.1-9.9)	9.8 (9.2-10.0)	0.15
Color of the peri-implant mucosa	-	-	-		9.0 (7.9-9.8)	7.9 (7.0-9.1)	9.2 (7.4-9.8)	0.15	8.0 (6.9-9.7)	8.6 (7.2-9.6)	9.5 (8.6-10.0)	0.11
Form of the peri-implant mucosa	-	-	-		7.6 (6.8-9.3)	6.1 (4.6-8.5)	8.9 (7.0-9.8)	0.04	7.6 (5.3-9.5)	8.3 (5.6-9.7)	9.0 (7.0-10.0)	0.23
<b>Treatment procedure (0-10)</b>												
I regret that I chose this treatment	-	-	-		0.1 (0.0-0.3)	0.3 (0.1-0.6)	0.0 (0.0-0.4)	0.06	0.1 (0.0-0.8)	0.1 (0.0-0.3)	0.0 (0.0-0.3)	0.59
I would recommend the treatment to other patients	-	-	-		9.6 (8.2-10.0)	9.4 (8.7-10.0)	9.9 (9.3-10.0)	0.14	9.8 (9.0-10.0)	9.6 (7.9-9.9)	9.9 (9.5-10.0)	0.18
<b>Total OHIP-score (0-70)</b>	24.5 (21.3-41.0)	31.0 (25.0-37.8)	25.5 (22.3-40.0)	0.39	18.0 (14.3-22.0)	19.5 (15.3-29.8)	17.5 (14.0-26.0)	0.41	15.0 (14.0-21.3)	16.0 (15.0-22.3)	15.0 (14.0-19.8)	0.34

NA, not assessed.



The majority of studies on the effect of soft-tissue grafting assess the change in mid-buccal mucosal volume (MBMV). Measurement of the change in MBMV would have been desirable, but was beyond the scope of this study. CT grafting could have resulted in an increase in the peri-implant soft-tissue volume, which possibly compensated for the bone resorption-inducing effect of flap elevation<sup>48</sup> in all the study groups. Only the last item in the PES, judging root convexity, soft-tissue texture, and color, focuses on changes in soft-tissue volume. However, this is a combined scoring item and only states whether all aspects (score 2), two aspects (score 1), or one/no aspect (score 0) are comparable to the contralateral tooth. The fact that we could not find any differences between the groups for this item can be explained by the limitations of scoring this item, because the PES is not sensitive enough to pick up small changes. The same applies to the other items and the total PES score.

Changes in marginal bone level in this study are in line with the changes in relation to the alveolar ridge preservation procedure observed in previous studies conducted by our group.<sup>44,46</sup> This is in contrast to Wiesner et al.,<sup>15</sup> who observed a higher loss of marginal bone level in the test and control groups. The limited change in bone level in this study may be explained by the reduced bone loss in a vertical direction as a result of the ridge preservation procedure after removal of the failing tooth.<sup>9,10</sup>

With respect to esthetics, no differences were found in the objective rating according to PES and WES. The rates were in line with recent literature.<sup>44</sup> Overall, patients were highly satisfied with the form and color of the peri-implant mucosa and the implant crown. The exception was the form of the peri-implant mucosa in the CTG group at T<sub>1</sub> (Table 3), possibly because the CT grafted sites appeared immature and had not merged with the surrounding peri-implant mucosa, as observed by Nevins et al.<sup>49</sup> This dissatisfaction was not observed 1 year after the final implant crown was placed. Conversely, patients were generally less satisfied with the CT grafted implant sites at T<sub>12</sub>. This might be explained by the higher patient morbidity when harvesting the CTG from the patients' palate compared to patients who had not received a graft or a XCM and, thus, did not have a second surgical site.<sup>24,30</sup> Nevertheless, this could not be seen in question outcomes asking whether patients regretted choosing the treatment they did and whether they would recommend the treatment to others.

## 5 | CONCLUSION

The application of a soft-tissue graft combined with placement of a single implant in a preserved alveolar ridge in the esthetic zone does not result in a more favorable esthetic outcome than when no soft-tissue graft was applied during

implant placement. Thus, soft-tissue grafting should not be considered a standard procedure.

## ACKNOWLEDGMENTS

The authors thank Cees Stellingsma (CS; Department of Oral and Maxillofacial Surgery, University Medical Center Groningen, University of Groningen, Groningen, The Netherlands) and Menno van der Veen (MvdV; Gronings Tandtechnisch Laboratorium, Groningen, The Netherlands) for their assistance in the fabrication of the provisional and final implant crowns. The authors report no conflicts of interest related to this study.

## AUTHOR CONTRIBUTIONS

EGZ, HJAM, AV, and GMR had substantial contributions to the conception or design of the work and the acquisition, analysis, or interpretation of data for the work. EGZ, HJAM, AV, and GMR were involved in drafting the paper and revising it critically. EGZ, HJAM, AV, and GMR gave final approval of the version to be published. EGZ, HJAM, AV, and GMR agreed to be accountable for all aspects of the work in ensuring that questions related to accuracy or integrity of any parts of the work are appropriately investigated and resolved.

## REFERENCES

- den Hartog L, Slater JJ, Vissink A, Meijer HJ, Raghoobar GM. Treatment outcome of immediate, early and conventional single-tooth implants in the aesthetic zone: a systematic review to survival, bone level, soft-tissue, aesthetics and patient satisfaction. *J Clin Periodontol* 2008;35:1073–1086.
- Jung RE, Zembic A, Pjetursson BE, Zwahlen M, Thoma DS. Systematic review of the survival rate and the incidence of biological, technical, and aesthetic complications of single crowns on implants reported in longitudinal studies with a mean follow-up of 5 years. *Clin Oral Implants Res* 2012;23(Suppl 6):2–21.
- Rokn A, Bassir SH, Rasouli Ghahroudi AA, Kharazifard MJ, Manesheof R. Long-term Stability of Soft Tissue Esthetic Outcomes Following Conventional Single Implant Treatment in the Anterior Maxilla: 10–12 Year Results. *Open Dent J* 2016;10:602–609.
- Chappuis V, Araujo MG, Buser D. Clinical relevance of dimensional bone and soft tissue alterations post-extraction in esthetic sites. *Periodontol* 2000 2017;73:73–83.
- Merheb J, Quirynen M, Teughels W. Critical buccal bone dimensions along implants. *Periodontol* 2000 2014;66:97–105.
- Januario AL, Duarte WR, Barriviera M, Mesti JC, Araujo MG, Lindhe J. Dimension of the facial bone wall in the anterior maxilla: a cone-beam computed tomography study. *Clin Oral Implants Res* 2011;22:1168–1171.
- Avila-Ortiz G, Elangovan S, Kramer KW, Blanchette D, Dawson DV. Effect of alveolar ridge preservation after tooth extraction: a systematic review and meta-analysis. *J Dent Res* 2014;93:950–958.



8. Lee AMH, Poon CY. The Clinical Effectiveness of Alveolar Ridge Preservation in the Maxillary Anterior Esthetic Zone-A Retrospective Study. *J Esthet Restor Dent* 2017;29:137–145.
9. MacBeth N, Trullenque-Eriksson A, Donos N, Mardas N. Hard and soft tissue changes following alveolar ridge preservation: a systematic review. *Clin Oral Implants Res* 2017;28:982–1004.
10. Araujo MG, da Silva JCC, de Mendonca AF, Lindhe J. Ridge alterations following grafting of fresh extraction sockets in man. A randomized clinical trial. *Clin Oral Implants Res* 2015;26:407–412.
11. Barone A, Ricci M, Tonelli P, Santini S, Covani U. Tissue changes of extraction sockets in humans: a comparison of spontaneous healing vs. ridge preservation with secondary soft tissue healing. *Clin Oral Implants Res* 2013;24:1231–1237.
12. Ten Heggeler JMAG, Slot DE, Van der Weijden GA. Effect of socket preservation therapies following tooth extraction in non-molar regions in humans: a systematic review. *Clin Oral Implants Res* 2011;22:779–788.
13. Thoma DS, Benic GI, Zwahlen M, Hämmerle CHF, Jung RE. A systematic review assessing soft tissue augmentation techniques. *Clin Oral Implants Res* 2009;20(Suppl 4):146–165.
14. Buser D, Chappuis V, Belser UC, Chen S. Implant placement post extraction in esthetic single tooth sites: when immediate, when early, when late? *Periodontol 2000* 2017;73:84–102.
15. Wiesner G, Esposito M, Worthington H, Schlee M. Connective tissue grafts for thickening peri-implant tissues at implant placement. One-year results from an explanatory split-mouth randomised controlled clinical trial. *Eur J Oral Implantol* 2010;3:27–35.
16. Stefanini M, Felice P, Mazzotti C, Marzadori M, Gherlone EF, Zucchelli G. Transmucosal Implant Placement with Submarginal Connective Tissue Graft in Area of Shallow Buccal Bone Dehiscence: a Three-Year Follow-Up Case Series. *Int J Periodontics Restorative Dent* 2016;36:621–630.
17. Hanser T, Khoury F. Alveolar Ridge Contouring with Free Connective Tissue Graft at Implant Placement: a 5-Year Consecutive Clinical Study. *Int J Periodontics Restorative Dent* 2016;36:465–473.
18. De Bruyckere T, Eghbali A, Younes F, De Bruyn H, Cosyn J. Horizontal stability of connective tissue grafts at the buccal aspect of single implants: a 1-year prospective case series. *J Clin Periodontol* 2015;42:876–882.
19. Schneider D, Grunder U, Ender A, Hämmerle CHF, Jung RE. Volume gain and stability of peri-implant tissue following bone and soft tissue augmentation: 1-year results from a prospective cohort study. *Clin Oral Implants Res* 2011;22:28–37.
20. Zuiderveld EG, Meijer HJA, den Hartog L, Vissink A, Raghoebar GM. Effect of connective tissue grafting on peri-implant tissue in single immediate implant sites: a RCT. *J Clin Periodontol* 2018;45:253–264.
21. Bienz SP, Jung RE, Sapata VM, Hämmerle CHF, Husler J, Thoma DS. Volumetric changes and peri-implant health at implant sites with or without soft tissue grafting in the esthetic zone, a retrospective case-control study with a 5-year follow-up. *Clin Oral Implants Res* 2017;28:1459–1465.
22. Thoma DS, Buranawat B, Hämmerle CHF, Held U, Jung RE. Efficacy of soft tissue augmentation around dental implants and in partially edentulous areas: a systematic review. *J Clin Periodontol* 2014;41(Suppl 1):S77–S91.
23. Thoma DS, Mühlemann S, Jung RE. Critical soft-tissue dimensions with dental implants and treatment concepts. *Periodontol 2000* 2014;66:106–118.
24. Sanz M, Lorenzo R, Aranda JJ, Martin C, Orsini M. Clinical evaluation of a new collagen matrix (Mucograft prototype) to enhance the width of keratinized tissue in patients with fixed prosthetic restorations: a randomized prospective clinical trial. *J Clin Periodontol* 2009;36:868–876.
25. Herford AS, Akin L, Cicciu M, Maiorana C, Boyne PJ. Use of a porcine collagen matrix as an alternative to autogenous tissue for grafting oral soft tissue defects. *J Oral Maxillofac Surg* 2010;68:1463–1470.
26. Thoma DS, Zeltner M, Hilbe M, Hämmerle CHF, Husler J, Jung RE. Randomized controlled clinical study evaluating effectiveness and safety of a volume-stable collagen matrix compared to autogenous connective tissue grafts for soft tissue augmentation at implant sites. *J Clin Periodontol* 2016;43:874–885.
27. Lorenzo R, Garcia V, Orsini M, Martin C, Sanz M. Clinical efficacy of a xenogeneic collagen matrix in augmenting keratinized mucosa around implants: a randomized controlled prospective clinical trial. *Clin Oral Implants Res* 2012;23:316–324.
28. Zeltner M, Jung RE, Hämmerle CHF, Hüsler J, Thoma DS. Randomized controlled clinical study comparing a volume-stable collagen matrix to autogenous connective tissue grafts for soft tissue augmentation at implant sites: linear volumetric soft tissue changes up to 3 months. *J Clin Periodontol* 2017;44:446–453.
29. Maiorana C, Pivetti L, Signorino F, Grossi GB, Herford AS, Beretta M. The efficacy of a porcine collagen matrix in keratinized tissue augmentation: a 5-year follow-up study. *Int J Implant Dent* 2018;4:1.
30. Cairo F, Barbato L, Tonelli P, Batalocco G, Pagavino G, Nieri M. Xenogeneic collagen matrix versus connective tissue graft for buccal soft tissue augmentation at implant site. A randomized, controlled clinical trial. *J Clin Periodontol* 2017;44:769–776.
31. Jepsen K, Jepsen S, Zucchelli G, et al. Treatment of gingival recession defects with a coronally advanced flap and a xenogeneic collagen matrix: a multicenter randomized clinical trial. *J Clin Periodontol* 2013;40:82–89.
32. Cardaropoli D, Tamagnone L, Roffredo A, Gaveglio L. Treatment of gingival recession defects using coronally advanced flap with a porcine collagen matrix compared to coronally advanced flap with connective tissue graft: a randomized controlled clinical trial. *J Periodontol* 2012;83:321–328.
33. Froum SJ, Khoully I, Tarnow DP, et al. The use of a xenogeneic collagen matrix at the time of implant placement to increase the volume of buccal soft tissue. *Int J Periodontics Restorative Dent* 2015;35:179–189.
34. Mombelli A, van Oosten MA, Schurch E, Jr, Lang NP. The microbiota associated with successful or failing osseointegrated titanium implants. *Oral Microbiol Immunol* 1987;2:145–151.
35. Smeets EC, de Jong KJ, Abraham-Inpijn L. Detecting the medically compromised patient in dentistry by means of the medical risk-related history. A survey of 29,424 dental patients in The Netherlands. *Prev Med (Baltim)* 1998;27:530–535.





36. Belser UC, Grutter L, Vailati F, Bornstein MM, Weber HP, Buser D. Outcome evaluation of early placed maxillary anterior single-tooth implants using objective esthetic criteria: a cross-sectional, retrospective study in 45 patients with a 2- to 4-year follow-up using pink and white esthetic scores. *J Periodontol* 2009;80:140–151.
37. Meijndert L, Meijer HJ, Raghoobar GM, Vissink A. A technique for standardized evaluation of soft and hard peri-implant tissues in partially edentulous patients. *J Periodontol* 2004;75:646–651.
38. Kan JY, Morimoto T, Rungcharassaeng K, Roe P, Smith DH. Gingival biotype assessment in the esthetic zone: visual versus direct measurement. *Int J Periodontics Restorative Dent* 2010;30:237–243.
39. Loe H. The Gingival Index, the Plaque Index and the Retention Index Systems. *J Periodontol* 1967;38(Suppl):610–616.
40. Jemt T. Regeneration of gingival papillae after single-implant treatment. *Int J Periodontics Restorative Dent* 1997;17:326–333.
41. Albrektsson T, Zarb G, Worthington P, Eriksson AR. The long-term efficacy of currently used dental implants: a review and proposed criteria of success. *Int J Oral Maxillofac Implants* 1986;1:11–25.
42. van der Meulen MJ, John MT, Naeije M, Lobbezoo F. Developing abbreviated OHIP versions for use with TMD patients. *J Oral Rehabil* 2012;39:18–27.
43. Faul F, Erdfelder E, Buchner A, Lang AG. Statistical power analyses using G\*Power 3.1: tests for correlation and regression analyses. *Behav Res Methods* 2009;41:1149–1160.
44. Slagter KW, Meijer HJA, Bakker NA, Vissink A, Raghoobar GM. Immediate Single-Tooth Implant Placement in Bony Defects in the Esthetic Zone: a 1-Year Randomized Controlled Trial. *J Periodontol* 2016;87:619–629.
45. Tonetti MS, Cortellini P, Graziani F, et al. Immediate versus delayed implant placement after anterior single tooth extraction: the timing randomized controlled clinical trial. *J Clin Periodontol* 2017;44:215–224.
46. Raghoobar GM, Slater JJH, den Hartog L, Meijer HJA, Vissink A. Comparison of procedures for immediate reconstruction of large osseous defects resulting from removal of a single tooth to prepare for insertion of an endosseous implant after healing. *Int J Oral Maxillofac Surg* 2009;38:736–743.
47. Jung RE, Philipp A, Annen BM, et al. Radiographic evaluation of different techniques for ridge preservation after tooth extraction: a randomized controlled clinical trial. *J Clin Periodontol* 2013;40:90–98.
48. Natto ZS, Parashis A, Steffensen B, Ganguly R, Finkelman MD, Jeong YN. Efficacy of collagen matrix seal and collagen sponge on ridge preservation in combination with bone allograft: a randomized controlled clinical trial. *J Clin Periodontol* 2017;44:649–659.
49. Nevins M, Nevins ML, Kim S-W, Schupbach P, Kim DM. The use of mucograft collagen matrix to augment the zone of keratinized tissue around teeth: a pilot study. *Int J Periodontics Restorative Dent* 2011;31:367–373.

## SUPPORTING INFORMATION

Additional supporting information may be found online in the Supporting Information section at the end of the article.

**How to cite this article:** Zuiderveld EG, Meijer HJA, Vissink A, Raghoobar GM. The influence of different soft-tissue grafting procedures at single implant placement on esthetics: A randomized controlled trial. *J Periodontol*. 2018;89:903–914. <https://doi.org/10.1002/JPER.18-0061>