

INFLUENCE OF TRICALCIUM SILICATE ON COURSE OF TRAUMATIC PULPITIS

¹Kovach I., ¹Buniatian K., ¹Makarevych A., ¹Verbyts'ka A., ²Gargin V.¹State Establishment "Dnipropetrovsk Medical Academy", ²Kharkiv National Medical University, Ukraine

Constantly search of new materials and improvement of technology for their application is important for patients who need endodontic care and its management. Calcium silicate-based materials are one of groups which have been widely studied and used in such purpose. Among such materials, Tricalcium Silicate (TS) as Biodentine™ (BD, Septodont, Saint Maur des Fossés, France), was specifically designed as a "dentin replacement" material for applications such as root perforations, apexification, treatment of resorptive lesions, as well as a retrograde filling material in endodontic surgery [6,16], as considered as one of the main physical characteristics of hydraulic cements [7].

BD is composed of a mixed powder and liquid system. The powder contains tricalcium silicate which is main component, calcium carbonate which is used as filling material, zirconium oxide which works as radiopacifier, with traces of dicalcium silicate, calcium oxide, and iron oxide. The liquid phase of BD consists of a water-soluble polymer solution (water-reducing agent), using calcium chloride to decrease the setting time [4,14,16].

Biodentin has been reported to have better biological properties than other tricalcium silicate cements, such as trioxide mineral aggregate (MTA). Previous research has shown that the dynamic interaction of BD with the surface of dentin and pulp tissue stimulates the recruitment and

differentiation of pulp cells, upregulates transformation factors (gene expression), and promotes dentinogenesis [3,16]. Other studies have shown that BD is not cytotoxic and not genotoxic for pulp and gingival fibroblasts [13], but with were higher up regulation of mineralization and odontoblastic differentiation-associated gene expressions as compared to MTA group [6,19].

Described property could be useful for various treatment options and management of closing defect due to named above character by direct pulp capping [18], but with unclear consequences of such measurement for pulp tissue on case of development of pulpitis. Clinical trials have reported that these materials reduce the frequency and severity of major complications. Despite these treatment options, there is still a need for other cost-effective modalities to prevent future disorders.

The aim of this study was to determine the effects of Tricalcium Silicate (BD) on course of traumatic pulpitis by detection of morpho-functional peculiarities of changes in pulp tissue.

Material and methods. We performed experimental investigation for study of the morpho-functional changes of the pulp tissues tissue with modeling of traumatic pulpitis (on rabbits, males, aging three-month) and direct pulp capping by next steps (Fig. 1).

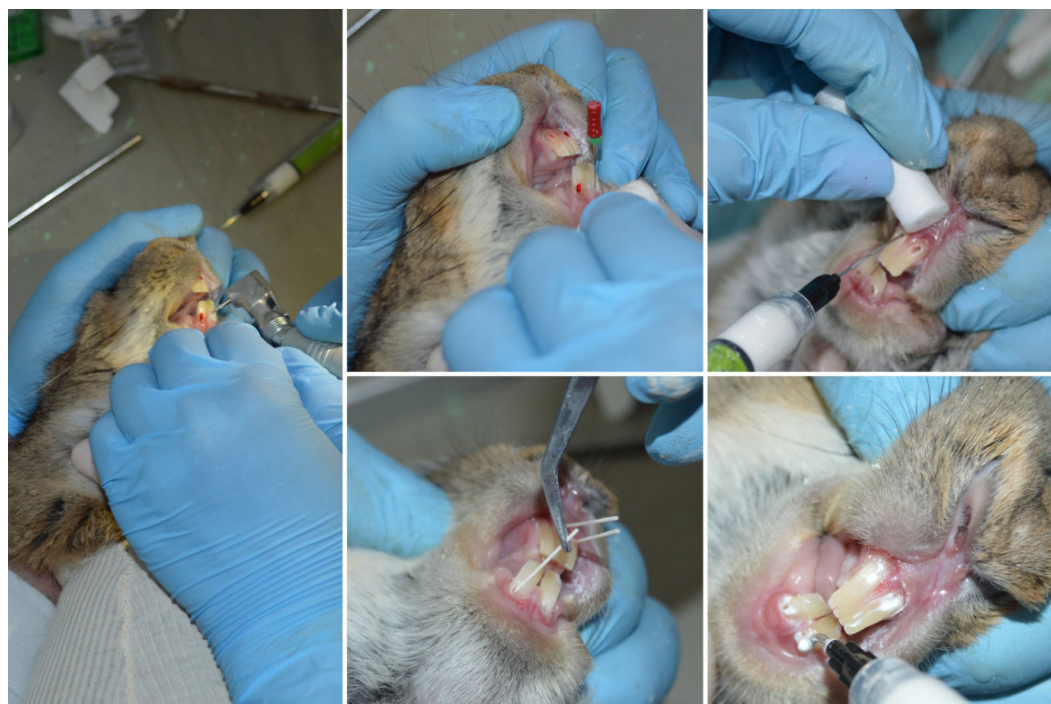

Fig. 1. Modeling of traumatic pulpitis with the preparation of hard tissues of the teeth; bleeding stopping; performing medical proceeding of the cavity and dry the cavity after that; direct pulp capping and filling the tooth with glass ionomer cement

After a general anesthesia (5% ketamine, of 0.4 ml per 1 kg of body weight, intramuscularly) we made the preparation of hard tissues of the teeth with a micromotor tip with opening of the tooth pulp horn. Bleeding was stopped with 5% aminocaproic acid. We performed medical proceeding of the cavity with a 3% solution of sodium hypochlorite and dry the cavity after that. After direct pulp capping with a tricalcium silicate (BD) preparation (8 animals, investigated group) and calcium hydroxide (Calasept, NORDISKA DENTAL) preparation (8 animals, comparison group), filling the tooth has been performed with glass ionomer cement.

After excretion of animals from the experiment on the 2nd and 6th weeks tissues of tooth were fixed in 10% formalin. Fixed in formalin tissue has been routine proceeding after decalcification in acetic acid with making histological slides which were stained with hematoxylin and eosin (H&E), according to van Gieson, Mallory, PAS-reaction was performed [1]. The slides were studied with the microscope "Olympus BX-41" and followed interpretation by "Olympus DP-soft version 3.2", which was used for morphometric study. Morphometric studies were performed by superimposing of grid with square cell (side 10⁻⁴ m) and detection of cellular density for pulpary cells and inflammatory elements. Number of vessel cross-sections per 1 mm², odontoblasts, x10³ per 1 mm², fibroblasts, x10² per 1 mm², neutrophils, x10² per 1 mm², has been detected. All values are expressed as means and standard error of the mean for statistical analysis. Statistical comparison was performed using Mann-Whitney test for statistical analysis. The accepted level of significance was p<0.05.

The procedure was done strictly in compliance with the Helsinki Declaration, European Convention for the protection of vertebrate animals (18.03.1986), European Economic Society Council Directive on the Protection of Vertebrate Animals (24.11.1986) after approval from the Regional Ethical Review Board at State Establishment "Dnipropetrovsk Medical Academy" protocol №2 (01.04.2016).

Conflict of Interest Statement. The authors declare that the research was conducted in the absence of any commercial or financial relationships that could be construed as a potential conflict of interest.

Results and their discussion. Acute damage of the pulp with the formation of traumatic pulpitis (Fig. 2) has been revealed in histological investigation of specimen

obtained after two weeks of direct pulp capping in group with calcium hydroxide. Pronounced vascular disturbance and inflammatory infiltration have been detected. Microfocal hemorrhages and necrobiotic changes have been revealed with background of hyperemia and edema. There is a pronounced PAS-reaction of the thickening vascular membranes with defibrination that is especially expressed around the walls of capillaries; PAS-positive hyaline membranes are indicated. Cellular reaction of traumatic changes is manifested with infiltration of the zone of damage by inflammatory cells (neutrophils, macrophages) surround dentinal fragments mainly. Morphometric data are presented in table 1 for that and other groups.

Necrobiosis and necrosis have been revealed in area of the trauma with cellular reducing density accompanied by the decomposition of reticulin fibers, homogenization of the basic substance and the accumulation of PAS-positive material. There are dystrophic changes of fibroblasts in the area of neutrophil appearance; nuclei of fibroblasts are pale. The cytoplasm of odontoblasts is vacuolated. There is destruction of the vascular membranes in the inflammation zone. Thus serous-purulent pulpitis with foci of necrosis or purulent fusion has been described in group with calcium hydroxide direct pulp capping after two weeks.

The histological examination of the obtained microspecimens after direct pulp capping with a tricalcium silicate preparation shows other picture of pulp tissue condition. Cellular elements of the pulp are represented by odontoblasts in the peripheral layer, and by subodontoblasts in the subodontoblastic and central layers; fibroblasts and sedentary macrophages have been revealed in the subodontoblastic and central layers also. Hyperemia is less pronounced without hemorrhages; necrobiotic changes have not been revealed. PAS-reaction is evenly positive in connective tissue fibers and vascular membrane of pulp.

The tissue is abundantly vascularized with numerous new formed microcirculatory bed and lymphatic vessels with pronounced crimp and anastomosis. Cellular composition of the pulp is represented mainly by undifferentiated cells of the fibroblastic lines, fibroblasts, odontoblasts, macrophages; neutrophils are isolate. The layered type of the structure of the pulp is preserved with exception of trauma area.

The histological examination of the obtained microspecimens after direct pulp capping with a calcium hydroxide preparation shows signs of proliferative inflammatory

Table 1. Morphometric data of pulp for investigated groups

Investigated parametr	Intact group	Group of calcium hydroxide		Group of tricalcium silicate	
		2 weeks	6 weeks	2 weeks	6 weeks
Number of vessel cross-sections per 1 mm ²	49.2±3.47	95.3±6.58*	79.24±9.41*#	69.31±4.76*	47.38±4.12#
Odontoblasts, x10 ³ per 1 mm ²	8.3±1.02	1.73±0.44*	3.41±0.92*#	3.92±1.03*	7.49±1.51#
Fibroblasts, x10 ² per 1 mm ²	17.92±4.42	5.31±2.18*	11.47±2.16#	10.71±2.36	16.04±3.11
Neutrophils, x10 ² per 1 mm ²	0.34±0.03	41.32±5.73*	6.01±1.47*#	6.39±2.61*	1.39±0.72#

* - p<0,05 compared to the intact animals; # - p<0,05 compared to 2 weeks group

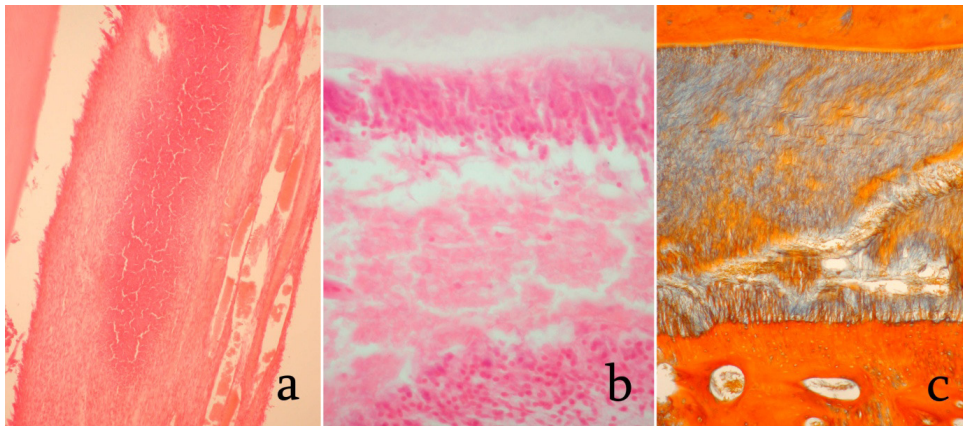


Fig. 2. Tissue changes in modeling of traumatic pulpitis and consequences of direct pulp capping with a tricalcium silicate preparation. Necrobiotic changes of pulp tissue, formation of inflammatory infiltration, uneven congestion of microcirculatory bed vessels with overfilled lumens, H&E stain, magnification x100 (a); proliferative activity of odontoblastic layer, H&E stain, magnification x400 (b); sclerotic changes pulp, staining according to Mallory, magnification x100, (c)

process after six weeks. There are no pronounced signs of osteodentin formation which has been noted around dentinal fragments. The processes of organization are accompanied by active neoplasm of fibrous structures (encapsulation, formation of osteodentin, etc.). There are false intrapulpary cysts which appeared on the spot of hematomas, after elimination of vascular disorders in the pulp; a protective reaction is developed with form of deposits of substitute dentin on the walls of the tooth cavity without pronounced migration of the odontoblast nuclei.

Cloak dentin has been detected in solid tissues of large defects with penetration into the pulp with conglomerates of cellular detritus. The zone of the crown dentin undergoes severe destruction: it is represented by a softened dentin with formation of a zone of transparent dentin. Simultaneously there are foci of neutrophil accumulation till formation of microabscess around which fibrous tissue is developed, which characterizes the proliferative type of inflammation (productive tissue reaction). There is developed sclerosis and net atrophy with the formation of macrophage granulomas and the active formation of osteoclasts in that group.

Use as the odontotropic preparation of tricalcium silicate is realized after six weeks in proliferative type of cellular reaction without sign of acute inflammatory process that is allowed by creation of a hermetic crown restoration with a high degree of adhesion to the dentin of the bottom. There are numerous fibroblasts in pulp which indicate active stimulation of the formation of a hard tissue bridge under the influence of the angio- and dentinogenesis processes, the main structural element of which are coarse collagen fibers. Cells of connective tissue are presented by mature cells predominantly. Lymphoid elements are dispersed evenly between the connective tissue fibers, without the formation of focal accumulations; signs of accumulation of inflammatory exudate have not been demonstrated.

Search of new methods and materials is extremely important for treatment of dental pathology [2, 9] especially

with understanding of pathogenetical background [11,12]. So after becoming calcium silicate material “Biodentine” that was commercially available from 2009 as a “dentine replacement” material it has been applied wide and one of suggested way as pulp capping started to be discussed in restorative dentistry [14]. However methodology is specifically useful and preferred when the coronal pulp tissue is inflamed and a direct pulp capping is not a suitable option according to some works [17].

But described interactions between pulp capping materials and the injured pulp tissue with signalling of reparative dentinogenesis of Biodentine as well as the ability to modulate TGF secretion by pulp cells which has previously shown to be released from dentine by calcium hydroxide [13] make direct pulp capping interesting for BD using in traumatic pulpitis as perforation consequences for example.

It has been established that pulp tissue possesses high reactive capabilities, while direct coating of the pulp promotes active regeneration processes with active formation of capillary net and new connective tissue elements [5,15]. Two weeks after injury, manifestations of protective adaptive mechanisms in the form of an inflammatory process with its resolution were found in it, encapsulation of dentinal fragments and foci of necrosis with their delimitation from viable pulp tissue with background of intensive angiogenesis. Vascular disturbance could be recognized as one of most important factors in inflammatory processes of oral cavity [5,8,10].

Creation of hermetic contact with high degree of adhesion to the dentin of the bottom promotes development of aseptic inflammatory process with transformation in proliferative and formation of dense connective tissue bridge. It was established that processes of rheology disturbance with disorders of lymph circulation are replaced by restoration cellular component. The main goal of endodontic treatment should be clinical success but experimental trials with long term follow up (in our research 6 weeks) with

next step in clinical pathogenetical based using for different selection of material accordingly to clinical necessity and success. Suggested direct pulp capping was investigated for traumatic pulpitis and found out similar clinical and pathologic effectiveness with positive regenerative process with formation of hard tissue bridge which consists of rode collagen fibers as carcass, so our results could be helpful for BD in comparison with calcium hydroxide.

Conclusion. Manifestations of protective adaptive mechanisms have been revealed in the form of inflammatory process two weeks after the injury in the pulp tissue with its resolution six weeks after performing of direct pulp capping with Tricalcium Silicate (Biodentine) with replacement of necrotic area by connective tissue with their delimitation from viable pulp tissue against a background of intensive neoplasm of capillaries. Morphometric study proved dynamical changes of vascular number cross-sections per 1 mm² from 69.31±4.76 (2 weeks) to 47.38±4.12 (6 weeks) with 49.2±3.47 vascular density in intact group. Cellular density of odontoblasts as changed from 3.92±1.03 x10³ per 1 mm² (2 weeks) to 7.49±1.51 x10³ per 1 mm² (2 weeks) with 8.3±1.02 x10³ per 1 mm² cellular density in intact group.

REFERENCE

1. Avwioro G. Histochemical Uses Of Haematoxylin - A Review. JPCS, (2011) 1, 24-34.
2. Bezruk V., Krivenko S., Kryvenko L. The Pareto chart of caries intensity evaluation for children with allergic diseases. In Problems of Infocommunications Science and Technology (PIC S&T); Second International ScientificPractical Conference. 2015; 110-111.
3. Bogen G, Chandler N. Pulp preservation in immature permanent teeth. Endod Topics. 2010;23(1):131-52.
4. Camilleri J, Sorrentino F, Damidot D. Investigation of the hydration and bioactivity of radiopacified tricalcium silicate cement, Biodentine and MTA Angelus. Dent Mater. 2013 May;29(5):580-93.
5. Denga O, Pyndus T, Gargin V, Schneider S. Influence of metabolic syndrome on condition of microcirculatory bed of oral cavity. Georgian Med News. 2017 Dec;(273):99-104.
6. Jafari F, Jafari S, Etesamnia P. Genotoxicity, Bioactivity and Clinical Properties of Calcium Silicate Based Sealers: A Literature Review. Iran Endod J. 2017 Fall;12(4):407-413.
7. Kayahan MB, Nekoofar MH, McCann A, Sunay H, Kaptan RF, Meraji N, Dummer PM. Effect of acid etching procedures on the compressive strength of 4 calcium silicate-basedendodontic cements. J Endod. 2013 Dec;39(12):1646-8.
8. Kovac I.V., Kravchenko L.I., Gargin V.V. Morphofunctional peculiarities of tissue of oral cavity in chronic recurrent aphthous stomatitis with therapeutical correction. Inter Collegas. (2016) 4: 201-205.
9. Kovach I, Kravchenko L, Khotimska Y, Nazaryan R, Gargin V. Influence of ozone therapy on oral tissue in modeling of chronic recurrent aphthous stomatitis. Georgian Med News. 2017 Mar;(264):115-119.
10. Krivenko LS, Nazaryan RS. Influence of maternal pathology and atopic diseases on development of oral cavity pathology in children. Inter Collegas. 2015; 3(4): 386-391.
11. Kuzenko EV, Romaniuk AN, Politun AM, Moskalenko RA. Pathogenesis of periodontal cell DNA damage during periodon-

titis. Georgian Med News. 2013; Apr;(217):57-61. [Article in Russian]

12. Kuzenko Y, Romanyuk A, Politun A, Karpenko L. S100, bcl2 and myeloperoxid protein expressions during periodontal inflammation. BMC Oral Health. 2015; Aug 7;15:93.
13. Laurent P, Camps J, About I. Biodentine (TM) induces TGF-β1 release from human pulp cells and early dental pulp mineralization. Int Endod J. 2012;45(5):439-48.
14. Malkondu O, Karapinar Kazandag M, Kazazoglu E. A review on biodentine, a contemporary dentine replacement and repair material. Biomed Res Int. 2014;2014:160951.
15. Nazaryan R, Kryvenko L, Gargin V. The role of nitric oxide synthase in the modulation of the immune response in atopic disease. The New Armenian Medical Journal. 2017; 11(2): 52-57
16. Scelza MZ, Nascimento JC, Silva LED, Gameiro VS, DE Deus G, Alves G. Biodentine™ is cytocompatible with human primary osteoblasts. Braz Oral Res. 2017 Sep 28;31:e81.
17. Shayegan A, Jurysta C, Atash R, Petein M, Abbeele AV. Biodentine used as a pulp-capping agent in primary pig teeth. Pediatr Dent. 2012 Nov-Dec;34(7):e202-8.
18. Stefaneli Marques JH, Silva-Sousa YTC, Rached-Junior FJA, Macedo LMD, Mazzi-Chaves JF, Camilleri J, Sousa-Neto MD. Push-out bond strength of different tricalcium silicate-based filling materials to root dentin. Braz Oral Res. 2018 Mar 8;32:e18.
19. Zhang S, Yang X, Fan M. BioAggregate and iRoot BP Plus optimize the proliferation and mineralization ability of human dental pulp cells. Int Endod J. 2013;46(10):923-9.

SUMMARY

INFLUENCE OF TRICALCIUM SILICATE ON COURSE OF TRAUMATIC PULPITIS

¹Kovach I., ¹Buniatian K., ¹Makarevych A., ¹Verbyts'ka A., ²Gargin V.

*¹State Establishment "Dnipropetrovsk Medical Academy",
²Kharkiv National Medical University, Ukraine*

The use of Tricalcium Silicate (TS) as an odontotropic preparation makes it possible to create a hermetic crown restoration with a high degree of adhesion. However, the use of TS silicate by direct pulp capping remains disputable. The aim of this study was to determine the effects of TS on course of traumatic pulpitis by detection of morpho-functional peculiarities of changes in pulp tissue.

We performed experimental investigation (on rabbits, males, aging three-month) for study of the morpho-functional changes of the pulp tissues with modeling of traumatic pulpitis and direct pulp capping with TS preparation (8 animals, investigated group) and calcium hydroxide (Calasept, NORDISKA DENTAL) preparation (8 animals, comparison group). After 2nd and 6th weeks tissues of tooth were fixed in 10% formalin with performing routine proceeding after decalcification and making histological slides which were investigated.

Manifestations of protective adaptive mechanisms have been revealed in the form of inflammatory process two weeks after the injury in the pulp tissue with its resolution six weeks after performing of direct pulp capping

with TS with replacement of necrotic area by connective tissue with their delimitation from viable pulp tissue against a background of intensive formation of capillaries. Morphometric study proved dynamical changes of vascular number cross-sections per 1 mm² from 69.31±4.76 (2 weeks) to 47.38±4.12 (6 weeks) with 49.2±3.47 vascular density in intact group. Cellular density of odontoblasts as changed from 3.92±1.03 x10³ per 1 mm² (2 weeks) to 7.49±1.51 x10³ per 1 mm² (6 weeks) with 8.3±1.02 x10³ per 1 mm² cellular density in intact group.

Thus it can be argued that the use of TS as a material for direct pulp capping promotes more active regeneration processes.

Keywords: pulpitis, tricalcium silicate, calcium hydroxide, histology, experiment.

РЕЗЮМЕ

ВЛИЯНИЕ ТРИКАЛЬЦИЙСИЛИКАТА НА ТЕЧЕНИЕ ТРАВМАТИЧЕСКОГО ПУЛЬПИТА

¹Ковач И.В., ¹Бунтян К.А., ¹Макаревич А.Ю.,
¹Вербицкая А.В., ²Таргин В.В.

¹Днепропетровская медицинская академия; ²Харьковский национальный медицинский университет, Украина

Целью исследования явилось определение влияния трикальцийсиликата на течение травматического пульпита.

Поставлен эксперимент на 3-месячных кроликах-самцах для изучения морфофункциональных изменений ткани пульпы с моделированием травматического пульпита и прямым покрытием пульпы трикальцийсиликатом (8 животных, исследуемая группа) и гидроксидом кальция (Calasept, NORDISKA DENTAL) (8 животных, группа сравнения). Спустя 2 и 6 недели ткани зуба фиксировали в 10% формалине и после декальцификации и рутинной проводки исследовали гистологические препараты.

Спустя 2 недели после нанесения травмы в ткани пульпы обнаружены проявления защитно-приспособительных механизмов в виде воспалительного процесса с его разрешением, при котором наблюдается замещение зоны некроза соединительной тканью на фоне интенсивного новообразования капилляров, что характеризуется изменением плотности сосудов микроциркуляторного русла. Морфометрическое исследование показало динамические изменения количества сосудистых сечений с 69,31±4,76/мм² (2 недели) до 47,38±4,12/мм² (6 недель) при 49,2±3,47/мм² в интактной группе. Плотность одонтобластов изменилась

с 3,92±1,03×10³/мм² (2 недели) до 7,49±1,51×10³/мм² (6 недель) при 8,3±1,02×10³/мм² клеточной плотности в интактной группе.

Таким образом, следует предположить, что использование трикальцийсиликата в качестве материала для прямого покрытия пульпы способствует более активным процессам регенерации.

რეზიუმე

ტრიკალციისილიკატის გავლენა ტრავმული პულპიტის მიმდინარეობაზე

¹ი. კოვაჩი, ¹კ. ბუნტიანი, ¹ა. მაკარევიჩი, ¹ა. ვერბიცაია, ²ვ. გარგინი

¹დნეპროპეტროვსკის სამედიცინო აკადემია; ²ხარკოვის ეროვნული სამედიცინო უნივერსიტეტი, უკრაინა

კვლევის მიზანს შეადგენდა ტრიკალციისილიკატის გავლენის შეფასება ტრავმული პულპიტის მიმდინარეობაზე.

პულპის ქსოვილის მორფოფუნქციური ცვლილებების ექსპერიმენტული კვლევა ჩატარებულია 3 თვის ასაკის მამრ ბოცვერებზე ტრავმული პულპიტის მოდელირებით და პულპის პირდაპირი დაფარვით ტრიკალციისილიკატით (8 ცხოველი, საკვლევი ჯგუფი) და კალციუმის ჰიდროქსიდით (Calasept, NORDISKA DENTAL) (8 ცხოველი, საცდელი ჯგუფი). 2 და 6 კვირის შემდეგ კბილის ქსოვილები ფიქსირდებოდა 10%-იან ფორმალინში, დეკალციფიკაციის შემდეგ შეისწავლებოდა ჰისტოლოგიური პრეპარატები.

ტრავმის მიყენებიდან 2 კვირის შემდეგ პულპის ქსოვილში გამოვლინდა დაცვით-შემგუებლობითი მექანიზმები ანთებითი პროცესის სახით, სახეზეა ნეკროზული ზონის ჩანაცვლება შემაერთებელი ქსოვილით კაპილარების ინტენსიური წარმოქმნის და მიკროცირკულაციური კალაპოტის სისხლძარღვების სიმჭიდროვის ცვლილების ფონზე.

მორფომეტრულმა კვლევამ გამოავლინა სისხლძარღვოვანი კვებების რაოდენობის დინამიური ცვლილებები 69,31±4,76/მმ²-დან (2 კვირა) 47,38±4,12/მმ²-მდე (6 კვირა); ეს მაჩვენებელი ინტაქტურ ჯგუფში შეადგენს 49,2±3,47/მმ²-ს. ოდონტობლასტების სიმჭიდროვე შეიცვალა 3,92±1,03×10³/მმ²-დან (2 კვირა) 7,49±1,51×10³/მმ²-მდე (6 კვირა); ეს მაჩვენებელი ინტაქტურ ჯგუფში შეადგენს 8,3±1,02×10³/მმ²-ს.

ავტორები დაასკნიან, რომ ტრიკალციისილიკატის გამოყენება მასალად პულპის პირდაპირი დაფარვისათვის ხელს უწყობს რეგენერაციის პროცესების აქტივიზებას.