

IOSR Journal of Dental and Medical Sciences (IOSR-JDMS)

e-ISSN: 2279-0853, p-ISSN: 2279-0861. Volume 17, Issue 6 Ver.7 (June. 2018), PP 06-12

www.iosrjournals.org

The Importance Of The Surface Layer Of Dental Implants For Successful Tissue Integration : A Clinical Case Report

Dr. Kiro Papakoca, Ph.D; Dr. Sonja Rogoleva

Corresponding Author: Dr. Kiro Papakoca

Abstract: An evaluation of twenty patients was made during a period of thirty six months. The treatment, the observation and the evaluation of the patients have taken place in the private office of dentistry "Dent Estet" located in Shtip, Republic of Macedonia. All of the patients of this study were treated with the same system of dental implants and the results of the treatment were much similar among different patients. One of the clinical cases analyzed in details is a 30 years old male patient with missing second premolar, first and second molar on the left side of the mandible. As a consequence of the early lost of these teeth and the delayed decision of the patient for dental treatment, the amount of alveolar bone tissue was significantly reduced. There were done clinical and other investigations such as computer tomography and x – ray imaging. After that we made a decision to apply three dental implants using the dental implant system BioHorizon, combined with artificial bone MinerOss XP and artificial membrane to fill the bone defects. After the application of the dental implants, the primary stability was measured and we made a control X – ray image to evaluate the treatment. 6 months after the period of integration, the soft tissue recovery process was evaluated and also a few more x – ray images were taken for better visualization of the osteointegration. On the implants were placed sulcus formers and 15 days after their opening a prosthetic construction of solo crew - retained crowns was placed. After 12 months, control reviews were done, twice in the first 12 months and every next 12 months, during a period of total 36 months. Thanks to the modified superficial layer of the implants and their specific design, the primary stability was excellent, the physiological bone loss was minimal almost invisible, the bone integration and the soft tissue recovery were excellent.

Key words: Dental implants , surface layer , surface modification, osteointegration, soft tissues healing .

Date of Submission: 29-05-2018

Date Of Acceptance: 14-06-2018

I. Introduction

Choosing the right design of implants system has a big influence on the early success and also on the success that is achieved with the dental implants treatment.¹ Despite the many factors that determinate the long lasting and the success of the treatment, the superficial layer and its structure of the implants plays a crucial role and has a fundamental meaning in the whole process. There are numerous different variations of the surface and the structure of implants and their influence firstly on the primary stability, secondly on the bone integration also and the impact on the soft tissue healing.^{2,3} The modification and the improvement of the superficial layer on the dental implants, according to the modernized technology and methods, significantly improves the success of the osteointegration, knowing for the different forms of biotype of the hard and soft tissue in the patients, with enlarging the contact surface and the ability for the cell extensions and the collagen micro fibrils to precisely collide on the implant surface.^{4,5} Many of the new modern implants have superficial layer that is processed abrasively using jet of metal particles or it is engraved using acid. Normally these processed surfaces offer rough structure that improves the integration. But with help of the laser ablation and creating micro canals with size of a cell, is proven that it is created much more efficient surface for osteointegration and for collision with the soft tissues.^{6,7}

Purpose: The purpose of this study was to highlight the impact and importance of the surface layer structure of dental implants for the treatment success.

II. Materials and Methods:

This survey is based on investigation that took place in PZU "Dent Estet" in Shtip, R.M. during the period of three years, starting January 2015, ending January 2018. In the survey were included twenty patients. The survey was done with treatment, observation and evaluation of the patients and all patients were treated using the same implantology system BioHorizons®.

Case Description

For clinical investigation was taken the evaluation of a healthy 30 years old patient (G.D.) with missing second premolar, first and second molar in the lower left quadrant. Extraction of these teeth has been done over 6 years ago, because of these missing teeth and the late decision for expert treatment of the patient, the alveolar ridge was significantly reduced, and the mesio – distal space reduced. The patient required the best resolution for replacement of the missing teeth. The decision was placement of three implants of the BioHorizon® system, placement of artificial bone MinerOss® XP and placement of artificial bone membrane Mem-Lok® Resorbable Collagen Membrane, and chronological placement of superstructure created in dentistry laboratory, based on titanium created for each tooth apart, on what were placed zirconium crowns that were screwed individually above every implant.

Preoperative procedure

The preoperative procedure consisted of detailed anamnesis and clinical examination with paraclinical exams such as basic blood analysis, computed tomography and roentgen panoramic imaging, with intention to determine the height of the bone, its density and also its thickness, and also to create the treatment planing. (image 1,2,3).

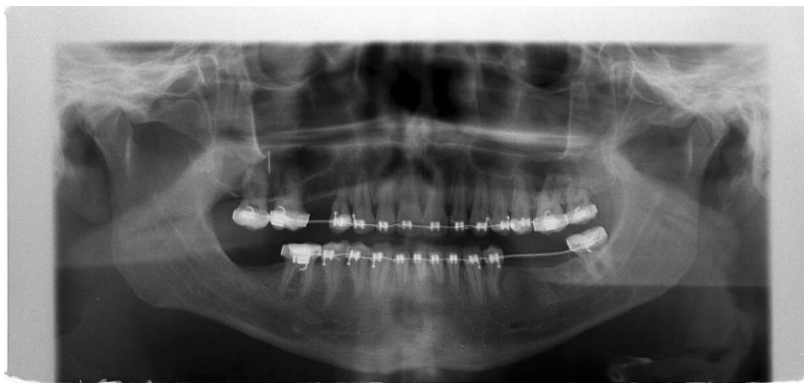

Image 1. Roentgen panoramic image before the treatment

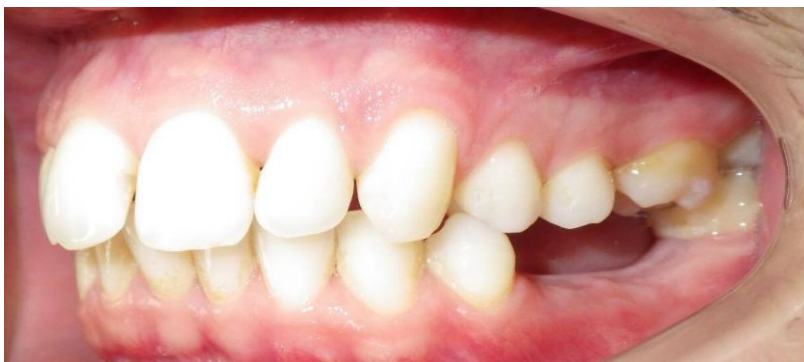

Image 2. Dentition and ridge condition before the treatment

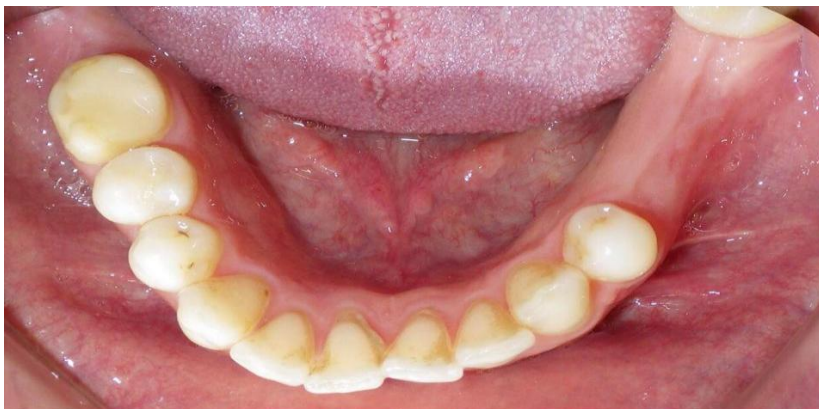

Image 3. Occlusal view of the dental ridge condition

Surgical procedure

The patient was given 1,000 mg of amoxicillin 2 hours before surgery. One minute prior to surgery, he rinsed with 0.12% chlorhexidine gluconate.

A local anesthetic was administered for pain control. The mucoperiosteal flap was made on the center of the alveolar ridge with additional vertical relaxing incisions. The bone was exposed using the surgical set of the BioHorizon® system, it was created adequate bearing, and subsequently were placed three implants, side to side each on the place for second premolar, first molar and second molar. (image 4,5)

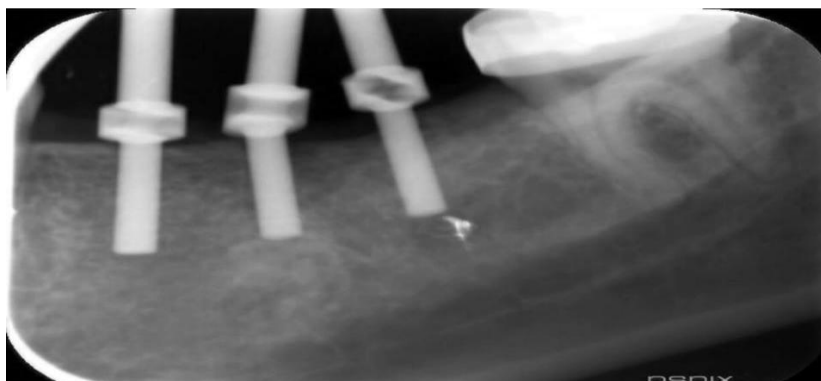


Image 4. Retroalveolar image with pins used for parallelism (during the intervention, that help determine the direction and the height before the implants placement).

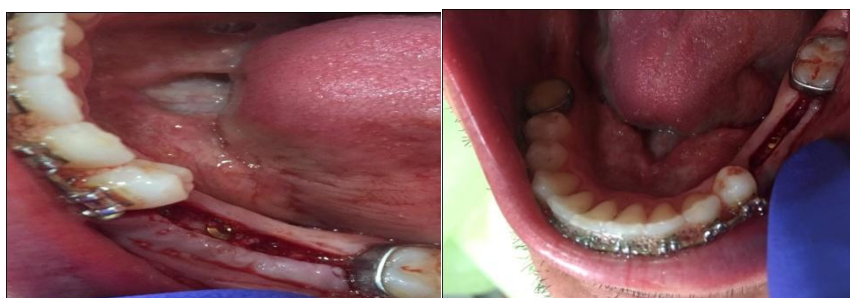

Image 5. Occlusal view of the placed implants in lower left quadrant

Placed implants BioHorizons Tapered Internal had the following dimensions: 3.8x 12mm, 3.5 Plat ; 3.8x 9mm, 3.5 Platform и 3.8x 9mm, 3.5 Platform. Due to the ridge resorption we had available height of 14 mm and width of 3.9 mm in the premolar region and height of 12 mm and width of 4.1 mm in the molar region, so it was indication for application of bone graft. Using Bone Scraper autologous bone was taken from the patient, that was placed as primary graft above the implant and on it was placed mixture of bone substituent 70% and bone graft MinerOss® XP Anorganic Bone Mineral 30% that were protected with artificial membrane Mem-Lok® Resorbable Collagen Membrane. With assistance of PenguinRFA® – OSSEOINTEGRATION MONITORING DEVICE the primary stability of the implants was determined, so the stability for the first implant placed on the second premolar position was 76 ISQ (resonance frequency analysis), second was with 68 ISQ, and the third was with 82 ISQ value. Therefore the flap was closed using single sutures and control roentgen images were made for evaluation of the procedure (image 6)

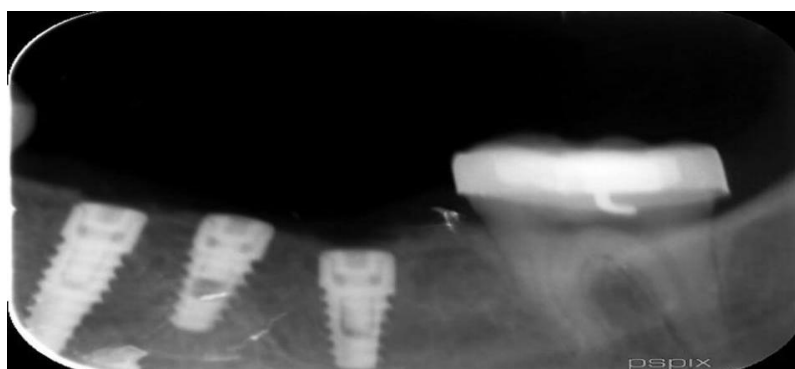

Image 6. Retroalveolar roentgen image taken right after the intervention

Antibiotics were ordinated in combination with proteolytic enzymes as a part of the tratment protocol, control of the flap healing in the following few days and a control imaging, 6 weeks after the intervention.

Uncovering

After seven months period of healing and osteointegration, the placed implants were surgically exposed and sulcus formers were placed for 15 days. They contributed for the successful adaptation and the gingival sulcus forming.

Final procedure

After the adequate forming of the gingiva and ideal soft tissue healing, finally suprastructure was placed using single zirconium fine retained crowns (image 7,8)



Image 7. Zirconium crown on second premolar, made on Ti – basis of penalties

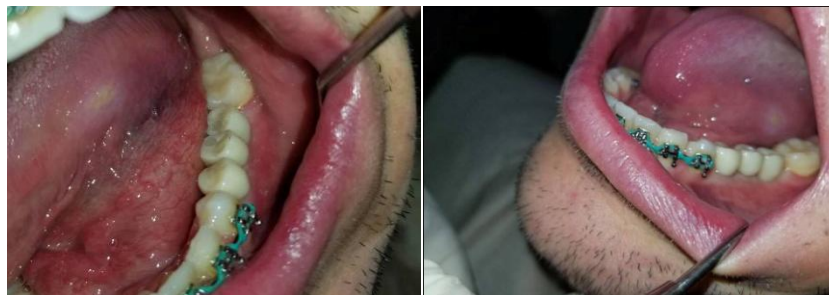

Image 8. View of placed single zirconium pin retained crowns

The patient was advised with instructions for massage using circular movements on the gums using NBF Gingival Gel®. Control examinations were done after 12 months, twice in the first 12 months, and once in every 12 months in the following 36 months (image 9,10,11)

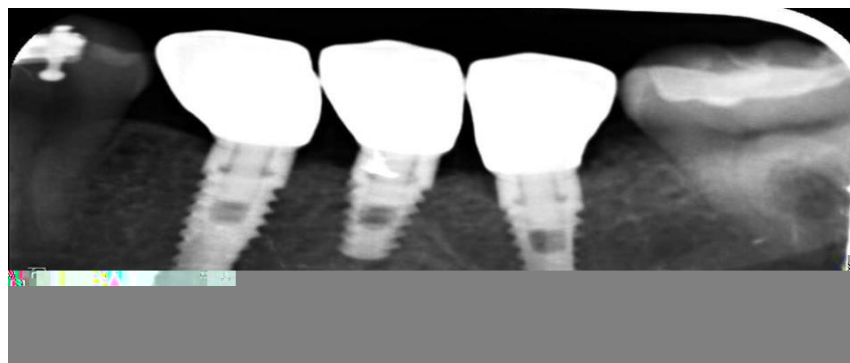


Image 9. Retroalveolar roentgen control image after 12 months

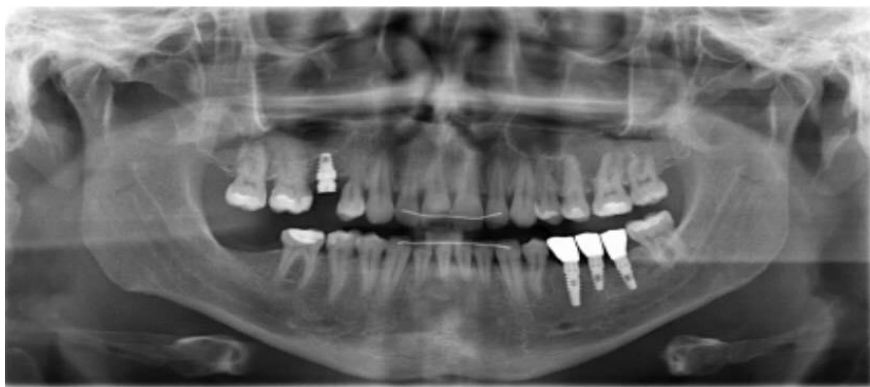

Image 10. Control panoramic roentgen image after 36 months

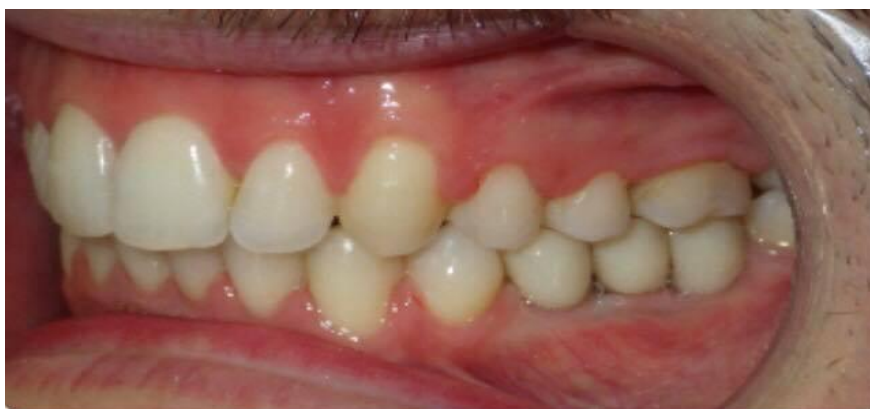

Image 11. Gingiva condition after 36 months

III. Results:

The results we got were more than similar among different patients. In the study sample for evaluation of 20 patients with good health, treated with the same implantology system, results shown that the primary stability of the implants was from 67 to 84 ISQ value. Therefore the postoperative period in all of the patients went without any pain and insignificant swell. On the control roentgen images of the patients treated with bone graft is noticed its complete integration with the bone around the graft. The radiographic images made after the treatment show unnoticeable marginal bone resorption smaller that 0.2 mm in the first year, and even smaller of 0.1 mm in the next 24 months. The soft tissue healing process and the bone integration were excellent in all of the patients thanks to the rough structure of the superficial layer and the specific design of the implants and their mechanic attachment to the connective tissue on their surface.

IV. Discussion:

Main subject of this discussion is analysis of the results brought from this research compared with results given from the literature containing researches worldwide. The success of the tissue integration including the osteointegration and the soft tissue integration does not depend only on one or two factors. The many factors including the quantity and also the quality of the bone, the shape and the implant design, its characteristic surface, the non traumatic surgery technique and also the skills and the experience of the surgeon affect the primary stability, and afterwards the whole tissue integration.^{8,9,10} Butz et al.¹¹ stated that the rough superficial layer of the implants affects the biomechanical quality and success of the osteointegration, and that the bone integrates much better and stronger with the rough surface, compared with smooth surface. Many results from literature^{12,13,14} shown that the superficial layer has influence for early and accelerated bone healing.

A survey done by Coetzee has examined 110 patients treated with potassium sulfate for bone defect reparation. It has been concluded that the potassium sulfate is incredible bone substituent that ensures bone formation and gives results that are same or better than using bone grafts. The use of autogenic bone combined with xenograft, was used to accelerate the bone regeneration and to get good soft tissue contours. According to Mitchell R. и Moskow B^{15,16} when alogen or xenograft is used, it is not vital and unreactive and it is necessary to be resorbed and on its place to be formed new bone, what delays the healing process.^{17,18}

Our opinion as other authors' In the last period, is that the augmentation that is about to be done on the very surface on the implants needs to be with autolog bone with defined thickness, and above it artificial bone protected with collagen membrane fixated above the bone graft.

Talking about the physiologic marginal bone resorbtion, based on the examinations of the plasmatic implants, Albertsson, Smith и Zarb, suggested criteria for success in the implantology, that will allow vertical bone loss less than 0.2 mm during the first year of including the implant in function. The non plasmatic implants also result with marginal bone resorbtion, with bigger bone resorbtion in the maxilla than in the mandible between 0.6 and 1.1 mm in the first year of including the implant in function.^{19,20}

On the other hand, with many clinical and scientific researches for the superficial layer on the implants that is modified using laser ablation with precisely creating micro channels with size of a cell, give better results in the osteointegration and the growth of the soft tissues.

It is highlighted that the bone loss is reduced for 70% actual 1.35 mm that after 3 years the total bone loss is up to 0.46 mm. With that is proven that this modified surface keeps and improves the peri – implant health.^{21,22,23,24}

V. Conclusion:

The results we got from the survey lead to a conclusion that every surface has a different influence on the bone integration and on the biological and physiological tissue retaining and healing process. Also many other factors contribute to the success of the treatment, such as the bone quality and quantity, the geometry shape of the implant, the superficial layer of the implant, the non traumatic technique of the surgery process and the skills and the experience of the surgeon. Our conclusion, such as many other authors' in the last period is that the augmentation that is about to be done on the surface of the dental implants, needs to be done with autolog bone, with defined thickness and above it artificial bone protected with collagen membrane fixated above the bone graft.

Also for the final success the primary stability has huge role which is connected with the superficial layer of the implant. Using an implant with smooth design is a bad choice, therefore rough surface implants give better results. The best results for long term success can be accomplished using design made with laser ablation with creating spherical channels with size of a cell, so the contact surface is enlarged and also it is allowed for the cell extensions and the collagen micro fibers to collide with the implant surface. The postoperative bone resorption is reduced, thanks to the good mechanical retaining of the connective tissue, the soft tissue healing and the biological healing are improved, compared with the use of other implant designs.

Acknowledgment

The author declares no financial interest in any of the products cited herein.

References:

- [1]. **Rabel A, Kohler SG, SchmidtWesthausen AM.** Clinical study on the primary stability of two dental implant systems with resonance frequency analysis. *Clin Oral Investig.* 2007;11:257-265.
- [2]. **Romanos GE, Damouras M, Veis A, et al.** Dental implant design and primary stability. A histomorphometric evaluation. Presented at: 42nd Annual Meeting of IADR—Continental European and Israeli Divisions, September 26-29, 2007, Thessaloniki, Greece.
- [3]. **Buser D, Schenk RK, Steinemann S, Fiorellini JP, et al.** Influence of surface characteristics on bone integration of titanium implants. A histomorphometric study on miniature pigs. *J Biomed Mater Res.* 1991;25:889-902.
- [4]. **JC Grew, JL Ricci, H Alexander.** Connective-tissue responses to defined biomaterial surfaces. II. Behavior of rat and mouse fibroblasts cultured on microgrooved substrates. *Journal of Biomedical Materials Research Part A.* 85A: 326-335, 2008.
- [5]. **Ricci, R Rose, JK Charvet, H Alexander, CS Naiman.** Cell interaction with microtextured surfaces. JL Presented at the Fifth World Biomaterials Congress. May 29-June 2, 1996. Toronto, Canada.
- [6]. **Iglhaut G, Becker K, Golubovic V, Schliephake H, Mihatic I.** The impact of dis-/reconnection of laser microgrooved and machined implant abutments on soft- and hard-tissue healing. *Clin Oral Implants Res.* 2013 Apr;24(4):391-7.
- [7]. **GE Pecora, R Ceccarelli, M Bonelli, H Alexander, JL Ricci.** Clinical Evaluation of Laser Microtexturing for Soft Tissue and Bone Attachment to Dental Implants. *Implant Dent.* 2009 Feb;18(1):57-66.
- [8]. **Romanos GE.** Surgical and prosthetic concepts for predictable immediate loading of oral implants. *J Calif Dent Assoc.* 2004;32:991-1001.
- [9]. **Romanos GE.** Bone quality and the immediate loading of implants-critical aspects based on literature, research, and clinical experience. *Implant Dent.* 2009;18:203-209
- [10]. **Tabassum A, Meijer GJ, Wolke JG, et al.** Influence of surgical technique and surface roughness on the primary stability of an implant in artificial bone with different cortical thickness: A laboratory study. *Clin Oral Implants Res.* 2010;21:213-220.
- [11]. **Butz F, Aita H, Wang CJ, et al.** Harder and stiffer bone osseointegrated to roughened titanium. *J Dent Res.* 2006;85:560-565.
- [12]. **Wennerberg A, Albrektsson T.** Structural influence from calcium phosphate coatings and its possible effect on enhanced bone integration. *Acta Odontol Scand.* In press.
- [13]. **Wennerberg A, Albrektsson T.** Effects of titanium surface topography on bone integration: A systematic review. *Clin Oral Implants Res.* 2009;20:172-184.
- [14]. **Bratu EA, Tandlich M, Shapira L.** A rough surface implant neck with microthreads reduces the amount of marginal bone loss: A prospective clinical study. *Clin Oral Implants Res.* 2009;20:827-832.
- [15]. **Mitchell R,** (1992). An evaluation of bone healing in cavities in the jaws implanted with a collagen matrix. *Br J Oral Maxillofac Surg* 30:180.

- [16]. **Moskow B, Gold S, Gottsegen R**, (1976). Effects of scleral collagen upon the healing of experimental osseous wounds. J Oral Maxillofac Surg 47:596.
- [17]. **Debalso AM, Adrian JC**, (1996). Collagen gel in osseous defects: A preliminary report. Oral Surg Oral Med Oral Pathol 42:562.
- [18]. **Burchardt H**, (1983). The biology of bone graft repair. Clin Orthop 174:28.
- [19]. **Fiorellini, J. P. & Nevins, M. L.** (2003). Calvarial ridge augmentation/preservation. A systematic review. Ann Periodontol, vol. 8, no. 1, pp. 321-7.
- [20]. **Fransson, C.; Wennstrom, J. & Berglundh, T.** (2008). Clinical characteristics at implants with a history of progressive bone loss. Clin Oral Implants Res, vol. 19, no. 2, pp.142-7.
- [21]. **GE Pecora, R Ceccarelli, M Bonelli, H Alexander, JL Ricci** .Clinical Evaluation of Laser Microtexturing for Soft Tissue and Bone Attachment to Dental Implants. Implant Dent. 2009 Feb;18(1):57-66.
- [22]. **C Shapoff, B Lahey, P Wasserlauf, D Kim**. Radiographic Analysis of Crestal Bone Levels on Laser-Lok Collar Dental Implants. Int J Periodontics Restorative Dent. 2010;30:129-137.
- [23]. **S Botos, H Yousef, B Zweig, R Flinton and S Weiner**.The effects of laser microtexturing of the dental implant collar on crestal bone levels and peri-implant health. Int J Oral Maxillofac Implants. 2011;26:492-498.
- [24]. **HEK Bae, MK Chung, IH Cha, DH Han**. Marginal Tissue Response to Different Implant Neck Design. J Korean Acad Prosthodont. 2008, Vol. 46, No. 6.

Dr. Kiro Papakoca "The Importance Of The Surface Layer Of Dental Implants For Successful Tissue Integration : A Clinical Case Report "IOSR Journal of Dental and Medical Sciences (IOSR-JDMS), vol. 17, no. 6, 2018, pp 06-12