

Marcus Clauss · Hanspeter Steinmetz ·  
Ulrike Eulenberger · Pete Ossent · Robert Zingg ·  
Jürgen Hummel · Jean-Michel Hatt

## Observations on the length of the intestinal tract of African *Loxodonta africana* (Blumenbach 1797) and Asian elephants *Elephas maximus* (Linné 1735)

Received: 12 May 2006 / Accepted: 19 July 2006 / Published online: 5 October 2006

© Springer-Verlag 2006

**Abstract** The digestive tract of elephants is surprisingly short compared to other herbivorous mammals. However, measurements relating the length of the intestine to the body mass of the respective individual are rare. In this study, we report such data for an African elephant and an Asian elephant. Our data support the hypothesis that Asian elephants have a longer intestinal tract than their African counterparts. These findings are in accord with the observation of longer retention times and higher digestion coefficients in Asian as compared to African elephants. This difference between the species could be the reflection of slightly different ecological niches, with Asian elephants adapted to a natural diet with a higher proportion of grass.

**Keywords** *Loxodonta africana* · *Elephas maximus* · Gastrointestinal tract · Body mass · Digestive anatomy · Digestive physiology · Intestine

### Introduction

In the dissection of elephants, the intestinal tract seems to have received least attention of the different internal organs most likely due to its cumbersome size. Blair (1710) (data collated in 1683–1775) already stated that, during his dissection of a specimen, after the opening of the abdominal cavity, “... the intestines jeated out in a confus’d mass [...] but I had not time to take notice of their precise length.”

Elephants differ in their digestive physiology from other ungulate species due to their very short ingesta retention times and low digestion coefficients (Clauss et al. 2003c; Loehlein et al. 2003). One correlate of these findings is the dimension of their digestive tract, which is unusually short for herbivorous mammalian species (Shoshani et al. 1982; Clauss et al. 2003a). Mitchell (1903–1906) already noted that to his astonishment, the elephant’s large intestine was hardly shorter than its small intestine. Although this general feature sets elephants apart from other herbivores, the two elephant species still differ in their respective digestive physiology. Hackenberger (1987) showed, in a thesis of enormous experimental scope ( $n=50$  elephants), that Asian elephants achieve higher digestion coefficients on comparable diets, and have longer ingesta mean retention times, than their African counterparts. Similar results had been obtained, although with a lower number of animals, by Foose (1982). This difference could be an indication of a difference in the natural diet both species select. Both extant elephant species are intermediate feeders with a preference for browse, but isotopic investigations showed that both lineages were once grazers and are in a transition back to browsing (Cerling et al. 1999), and that the Asian elephant (*Elephas maximus*) might ingest a higher proportion of grass than the African elephant (*Loxodonta africana*). This difference was con-

---

M. Clauss (✉) · H. Steinmetz · U. Eulenberger · J.-M. Hatt  
Division of Zoo Animals, Exotic Pets and Wildlife,  
Vetsuisse Faculty, University of Zurich,  
Winterthurerstr. 260,  
8057 Zurich, Switzerland  
e-mail: [mclauss@vetclinics.unizh.ch](mailto:mclauss@vetclinics.unizh.ch)  
Tel.: +41-44-6358376  
Fax: +41-44-6358901

P. Ossent  
Institute of Veterinary Pathology, Vetsuisse Faculty,  
University of Zurich,  
Winterthurerstr. 268,  
8057 Zurich, Switzerland

R. Zingg  
Zoological Garden of Zurich,  
Zürichbergsstr. 221,  
8044 Zurich, Switzerland

J. Hummel  
Zoological Garden of Cologne,  
Cologne, Germany

J. Hummel  
Institute of Animal Science, Animal Nutrition Group,  
University of Bonn,  
Bonn, Germany

firmed by microwear results (Solounias and Semprebon 2002). As grass yields fermentative energy at a slower rate than browse (Hummel et al. 2006), longer ingesta retention times have been suggested as a particular adaptation of herbivores consuming grass (Clauss et al. 2005a; Clauss et al. 2006b). The differences in molar structure between the two species (with *L. africana* having less enamel ridges than *E. maximus*) could also be interpreted as a higher degree of adaptation for grass forage in *E. maximus* (Frade 1955) because grass, a flexible material that does not break easily, is assumed to require a higher degree of enamel folding for appropriate masticatory particle size reduction (Solounias and Dawson-Saunders 1988; Archer and Sanson 2002).

It has been suggested that the difference in ingesta retention and digestive efficiency between the species should be reflected in differences in gastrointestinal morphology (Clauss et al. 2005a). However, the paucity of available anatomical data so far prevented even a preliminary check of this hypothesis. The length of the intestinal tract of elephants has only been measured sporadically, and the available data suggest a longer intestinal tract in Asian elephants (Table 1). Combined information on both the intestinal tract length and the body mass (BM) of individuals is scarce and comprises, to our knowledge, three Asian elephants and one African elephant so far (Shoshani et al. 1982). In this study, we report the BM and length of the intestinal tract of one additional individual of each species, thus facilitating a preliminary comparison.

## Materials and methods

The necropsy of 21-year-old female African elephant, which was clinically healthy but was culled because it had tested positive for tuberculosis, has been described previously in this journal (Clauss et al. 2005b). A 39-

year-old female Asian elephant from the Zoological Garden of Zurich was euthanized in March 2006. Six months before the procedure, the animal had been weighed on a scale outside of the elephant house at Zurich Zoo; unfortunately, this scale is susceptible to freezing and does not yield reliable results in the wintertime. The last weight measurement obtained from this animal was 4.2 metric tons. The animal had a history of chronic lameness and of presumed arthrosis and had had increasing difficulties moving. At necropsy, a severe degree of generalized arthrosis was confirmed. Up to its death, the animal had displayed a normal food intake. To ensure a physiological gut fill postmortem, the animal was offered grass hay ad libitum until being euthanized. Its regular diet had consisted of grass hay, straw, browse, elephant pellets, fruits, and vegetables. At necropsy, all body parts and organs (including the individually isolated parotid glands) were weighed individually up to the nearest kilogram with a portable digital scale (Berkel L316, Obrecht Technologie G, Dietikon, Switzerland). The total sum of all weight measurements was assumed to represent 90% of the live body weight of the animal, with the remaining 10% representing blood and body fluids lost during necropsy (Shoshani et al. 1982). All adhering mesenteries were removed from the gastrointestinal tract. The lengths of the individual segments were measured, and photographs were taken to facilitate the preparation of anatomical drawings.

## Results

The BM of the African elephant was 3,140 kg (Clauss et al. 2005b). A total BM of 4,228 kg was calculated for the Asian elephant by adding 10% for blood and body fluids to a total mass of weighed body parts of 3,805 kg (both parotids: 4 kg; discrete adipose tissue not including subcutaneous fat: 244 kg). Thus, the BM recorded 6 months before the death was confirmed. The animal was

**Table 1** Reported measurements of body mass (BM, kilograms) and length measurements (meters) of different sections of the gastrointestinal tract from the literature

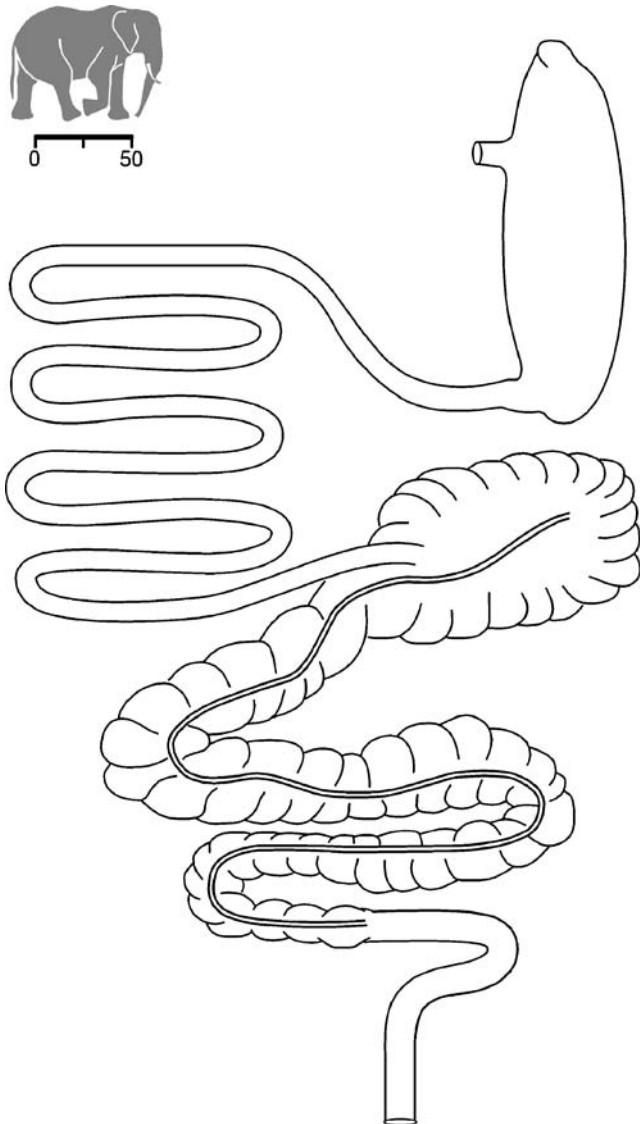
Species	BM	Stomach	Small intestine	Cecum	Large intestine	Total intestine	Source
–	–	1.2	20.0	0.5	5.8	26.3	(Mullen 1682)
–	–	1.0	9–11	0.5	5–7	14.5–18.5	(Frade 1955)
–	–	–	21	0.6–1.5	12.8	34.4–35.3	(Schmidt 1978)
<i>L. africana</i>	–	1.1	13.8	0.8	8.5	23.1	(Stevens and Hume 1995)
<i>L. africana</i>	–	1.2	11.0	1.0	6.0	18.0	(Sikes 1971)
<i>L. africana</i>	7,256	–	–	–	–	28.2	(Shoshani et al. 1982)
<i>E. maximus</i>	–	–	20.0	–	11.6	–	(Evans 1910)
<i>E. maximus</i>	–	–	21.0	–	12.2	–	(Evans 1910)
<i>E. maximus</i>	–	–	22.3	–	14.0	–	(Evans 1910)
<i>E. maximus</i>	–	–	22.6	–	13.1	–	(Evans 1910)
<i>E. max.</i>	–	–	21.5	0.8	8.0	30.3	(Gabry et al. 1965)
<i>E. maximus</i>	2,268	1.2	15.9	0.9	12.1	29.3	(Shoshani et al. 1982)
<i>E. maximus</i>	2,903	–	–	–	–	28.4	(Shoshani et al. 1982)
<i>E. maximus</i>	3,216	–	–	–	–	29.9	(Shoshani et al. 1982)

“–” means not given.

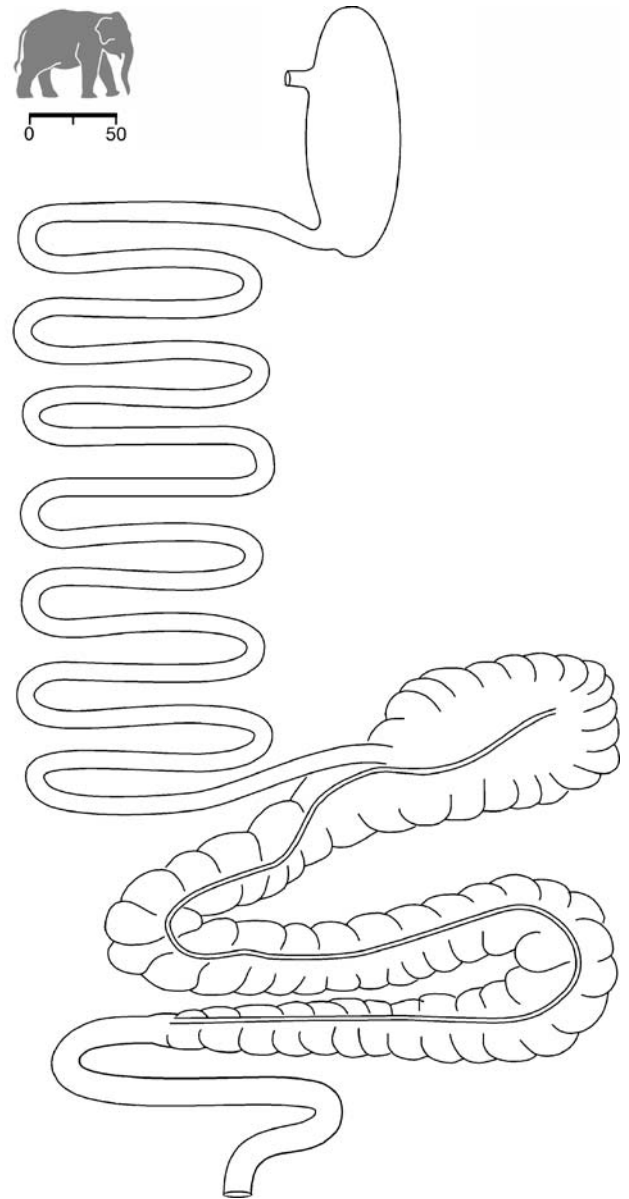
considered to be in a good body condition with moderate obesity. When comparing the intestinal tracts of both animals (Figs. 1 and 2), it appeared that, whereas the cecum was of comparable size, the large intestine, but particularly the small intestine, was longer in the Asian specimen. The measurements are given in Table 2. If all available data (own results, literature) on BM and total intestine length were combined, it appeared that there was a trend for increasing length with increasing BM, but on a lower general level, in the African than in the Asian elephant (Fig. 3).

## Discussion

Conclusions based on so few individual animals must always remain speculative, and results obtained from zoo



**Fig. 1** Gastrointestinal tract of an African elephant (*Loxodonta africana*) (necropsy described in Clauss et al. 2005b). The scale bar represents 50 cm

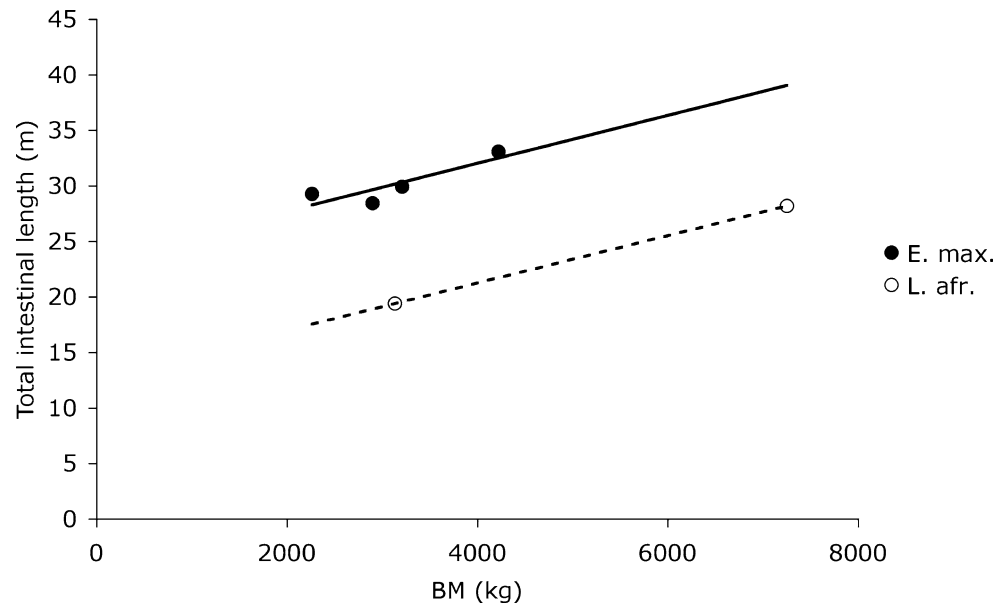


**Fig. 2** Gastrointestinal tract of an Asian elephant (*Elephas maximus*). The scale bar represents 50 cm

**Table 2** Body mass (BM, kilograms) and length measurements (meters) of an African (*Loxodonta africana*) and an Asian (*Elephas maximus*) elephant (this study)

	<i>L. africana</i>	<i>E. maximus</i>
BM (kg)	3,140	4,228
Length (m)		
Stomach	1.8	1.4
Small intestine	9.2	20.2
Cecum	1.0	1.0
Colon	9.4	11.8
Total intestine	19.6	33.0

**Fig. 3** Association of body mass (BM, kilograms) and the length of the intestinal tract (small intestine, cecum, and colon) in Asian (*Elephas maximus*) and African (*Loxodonta africana*) elephants (data from Tables 1 and 2)



animals must additionally be considered with caution. On the one hand, diseased specimens with a history of decreased food intake and, on the other hand, obese specimens may yield results not representative for the natural state of the species. The elephants of Zurich Zoo have a history of being obese but have been on a weight reduction and control program for more than a decade (Hatt and Liesegang 2001). The Asian elephant measured in this study was moderately obese, so her BM may be a bit high relative to her gastrointestinal parameters.

Nevertheless, a comparison of the intestinal tract lengths as correlated to BM (Fig. 3) supports the hypothesis that the more grazing Asian elephant has a longer total intestinal tract than its less grazing African counterpart. This difference in length is evident both in the small and the large intestines and could account for the observed differences in ingesta retention and digestive efficiency demonstrated between the species. The results therefore provide further support for the notion that the two extant elephant species might provide valuable examples of herbivores adapted to diets differing in the proportion of browse and grass. In fact, apart from the adaptations in digestive physiology and dental morphology, two further observations might support this pattern. In ruminants, it has been suggested that grazers have larger masseter insertion surfaces, which are thought to reflect the higher masticatory forces required to grind grass material (Stöckmann 1979; Axmacher and Hofmann 1988). Likewise, the diagram of the lower mandible in Frade (1955) suggests that the masseter insertion area is larger in Asian than in African elephants. Another distinctive morphological characteristic between grazing and browsing ruminants is the size of the salivary glands, which is generally smaller in grazers (Hofmann 1989). In the Asian elephant from this study, the total weight of the parotid glands was 4 kg; in contrast, in six free-ranging adult African elephants (of unknown BM), the combined weight of both parotid glands averaged 14.8 kg (Raubenheimer et al. 1988). In another

captive Asian elephant, one parotid gland measured 18×12×9.5 cm (Shoshani et al. 1982) in contrast to 29×22×19 cm in the free-ranging African elephants. While these sparse data are suggestive, more anatomical measurements are evidently needed to corroborate these findings.

The postulated differences in digestive anatomy and physiology between the elephant species would gain credibility if similar differences were demonstrated between other browsing and grazing hindgut fermenters, e.g., in rhinoceroses. Differences have been demonstrated in ingesta retention (Clauss et al. 2005a) and digestive efficiency (Clauss et al. 2006a) between the grazing and browsing rhinoceros species. The browsing black rhinoceros (*Diceros bicornis*) has both shorter small and large intestines than the grazing rhinoceroses (*Ceratotherium simum*, *Rhinoceros unicornis*) (data collated in Clauss et al. 2003a). However, due to the difference in BM range between these species, a direct comparison is impossible.

In parallel to the more capacious rumens in grazing ruminants (Clauss et al. 2003b) and a presumably longer ingesta retention at this site (Clauss et al. 2006b), a longer hindgut would be expected in the more grazing Asian elephant, as grass yields relevant amounts of fermentative energy after a longer period of time than browse (Hummel et al. 2006). However, the observation that the grazing species—ruminants (Hofmann 1989), elephants, and potentially rhinoceroses—also have a longer small intestine has not been accounted for so far. In vitro studies on the enzymatic digestion of grass and browse material are warranted to explain this difference. In elephants, bacterial fermentation even takes place in the small intestine as well (van Hoven et al. 1981). Those animals in which gut bacteria hydrogenate dietary fatty acids before lipid absorption have a lower proportion of polyunsaturated fatty acids in their body lipids (Christie 1981). Therefore, a longer retention of the ingesta in a longer small intestine with bacterial activity might account for the fact that Asian

elephants seem to have a lower proportion of polyunsaturated fatty acids in their spermatozoa (Swain and Miller 2000) and blood cells (Clauss et al. 2003d) than African elephants.

**Acknowledgments** We thank the elephant keepers of Zurich Zoo, especially Bettina Aeschbach and her team, for their support in the planning of and performing the necropsy, Felix Ehrensperger, Roland Zraggen, Dorothea Besselmann, Erik Fröhlicher, Maria Furger, Olga Martin Jurado, Katharina Müller, Angie Simai, and Eveline Zollinger for their aid during the necropsy, and Nicole Brunclik, Sandra Mosimann, Sabrina Riedle, and Sarah Scharmer for running the Exotic Pets Clinic of our division while everybody else was at the zoo. We would also like to acknowledge Jeanne Peter from the Institute of Veterinary Anatomy of the University of Zurich for producing the illustrations of the intestinal tracts.

## References

- Archer D, Sanson G (2002) Form and function of the selenodont molar in southern African ruminants in relation to their feeding habits. *J Zool (London)* 257:13–26
- Axmacher H, Hofmann RR (1988) Morphological characteristics of the masseter muscle of 22 ruminant species. *J Zool (London)* 215:463–473
- Blair P (1710) Osteographia elephantina: or, a full and exact description of all the bones of an elephant which died near Dundee, April the 27th, 1706, with their several dimensions, etc. *Philos Trans R Soc Lond [Biol]* 27:51–116
- Cerling TE, Harris JM, Leakey MG (1999) Browsing and grazing in elephants: the isotope record of modern and fossil proboscideans. *Oecologia* 120:364–374
- Christie W (1981) Lipid metabolism in ruminant animals. Pergamon, Oxford
- Clauss M, Frey R, Kiefer B, Lechner-Doll M, Loehlein W, Polster C, Rössner GE, Streich WJ (2003a) The maximum attainable body size of herbivorous mammals: morphophysiological constraints on foregut, and adaptations of hindgut fermenters. *Oecologia* 136:14–27
- Clauss M, Lechner-Doll M, Streich WJ (2003b) Ruminant diversification as an adaptation to the physicochemical characteristics of forage. A reevaluation of an old debate and a new hypothesis. *Oikos* 102:253–262
- Clauss M, Löhlein W, Kienzle E, Wiesner H (2003c) Studies on feed digestibilities in captive Asian elephants (*Elephas maximus*). *J Anim Physiol Anim Nutr* 87:160–173
- Clauss M, Wang Y, Ghebremeskel K, Lendl CE, Streich WJ (2003d) Plasma and erythrocyte fatty acids in captive Asian (*Elephas maximus*) and African (*Loxodonta africana*) elephants. *Vet Rec* 153:54–58
- Clauss M, Froeschle T, Castell J, Hummel J, Hatt JM, Ortmann S, Streich WJ (2005a) Fluid and particle retention times in the black rhinoceros (*Diceros bicornis*), a large hindgut-fermenting browser. *Acta Theriol* 50:367–376
- Clauss M, Robert N, Walzer C, Vitaud C, Hummel J (2005b) Testing predictions on body mass and gut contents: dissection of an African elephant (*Loxodonta africana*). *Eur J Wildl Res* 51:291–294
- Clauss M, Castell JC, Kienzle E, Dierenfeld ES, Flach EJ, Behlert O, Ortmann S, Streich WJ, Hummel J, Hatt JM (2006a) Digestion coefficients achieved by the black rhinoceros (*Diceros bicornis*), a large browsing hindgut fermenter. *J Anim Physiol Anim Nutr* 90:325–334
- Clauss M, Hummel J, Streich WJ (2006b) The dissociation of the fluid and particle phase in the forestomach as a physiological characteristic of large grazing ruminants: an evaluation of available, comparable ruminant passage data. *Eur J Wildl Res* 52:88–98
- Evans GH (1910) Elephants and their diseases. GPO, Rangoon
- Foose TJ (1982) Trophic strategies of ruminant versus nonruminant ungulates. Ph.D. dissertation, University of Chicago, Chicago
- Frade F (1955) Ordre des proboscidiens. In: Grassé PP (ed) *Traité de zoologie. Anatomie, systématique, biologie*. Tome XVII. Masson et Cie Editeurs, Paris, pp 715–783
- Gabry K, Gabry A, Sosnowski A (1965) Darmstich und tiefer Wassereinlauf bei der Kolik eines indischen Elefanten. *Kleintierpraxis* 10:116–120
- Hackenberger MK (1987) Diet digestibilities and ingesta transit times of captive Asian and African elephants. University of Guelph, Guelph
- Hatt JM, Liesegang A (2001) Nutrition of Asian elephants (*Elephas maximus*) in captivity—an overview and practical experiences. *Verh Ber Erkr Zootiere* 40:117–122
- Hofmann RR (1989) Evolutionary steps of ecophysiological adaptation and diversification of ruminants: a comparative view of their digestive system. *Oecologia* 78:443–457
- Hummel J, Südekum KH, Streich WJ, Clauss M (2006) Forage fermentation patterns and their implications for herbivore ingesta retention times. *Functional Ecology* (in press)
- Loehlein W, Kienzle E, Wiesner H, Clauss M (2003) Investigations on the use of chromium oxide as an inert, external marker in captive Asian elephants (*Elephas maximus*): passage and recovery rates. In: Fidgett A, Clauss M, Ganslosser U, Hatt JM, Nijboer J (eds) *Zoo animal nutrition*, vol 2. Filander, Fuerth, Germany, pp 223–232
- Mitchell PC (1903–1906) On the intestinal tract of mammals. *Trans Zool Soc Lond* 17:437–536
- Mullen A (1682) An anatomical account of the elephant accidentally burnt in Dublin on Friday, June 17, in the year 1681. Sam Smith, London
- Raubenheimer EJ, Dauth J, Dreyer MJ, De Vos V (1988) Parotid salivary gland of the African elephant (*Loxodonta africana*): structure and composition of saliva. *J S Afr Vet Assoc* 59:184–187
- Schmidt M (1978) Elephants. In: Fowler ME (ed) *Zoo and wild animal medicine*. Saunders, Philadelphia, PA, pp 709–752
- Shoshani J, and 76 co-authors (1982) On the dissection of a female Asian elephant (*Elephas maximus*) and data from other elephants. *Elephant* 2:3–93
- Sikes SK (1971) The natural history of the African elephant. Weidenfeld and Nicolson, London
- Solounias N, Dawson-Saunders B (1988) Dietary adaptations and palaeoecology of the late Miocene ruminants from Pikermi and Samos in Greece. *Palaeogeogr Palaeoclimatol Palaeoecol* 65:149–172
- Solounias N, Semperebón G (2002) Advances in the reconstruction of ungulate ecomorphology with application to early fossil equids. *Am Mus Novit* 3366:1–49
- Stevens CS, Hume ID (1995) Comparative physiology of the vertebrate digestive system. Cambridge University Press, New York
- Stöckmann W (1979) Differences in the shape of the mandibles of African bovidae in relation to food composition. *Zool Jahrb Syst* 106:344–373
- Swain JE, Miller RR (2000) A post-cryogenic comparison of membrane fatty acids of elephant spermatozoa. *Zoo Biol* 19:461–473
- van Hoven W, Prins RA, Lankhorst A (1981) Fermentative digestion in the African elephant. *S Afr J Wildl Res* 11:78–86