

MUMMIFICATION IN A BITCH A CASE REPORT

Perumal, P., Venkateswaralu, B., Mohanty,
D.N., Das, S., Barik, A.K. and Mishra, P.C.

Deptt.of ARGO, Orissa Veterinary College,
Bhubaneswar – 751 003

Lyka Pet Clinic & Surgical Centre,
Dindigul, Tamilnadu state – 624001

Species: Canine

Breed: Pug

Age: 5 years

Colour: Fawn

PRESENT HISTORY

- Dystocia since one day
- Normal vaginal discharge

PAST HISTORY

- Normal vaginal bleeding after puberty every 6 month
- No breeding/whelping

DIAGNOSIS

- History
- Clinical signs
- Physical examination
- Abdominal palpation
- X-ray investigation
- Vaginal examination

TREATMENT

CAESARIAN SECTION



PRE OPERATIVE CARE

Inj. Cefataxime 500 mg i/m

ANAESTHESIA

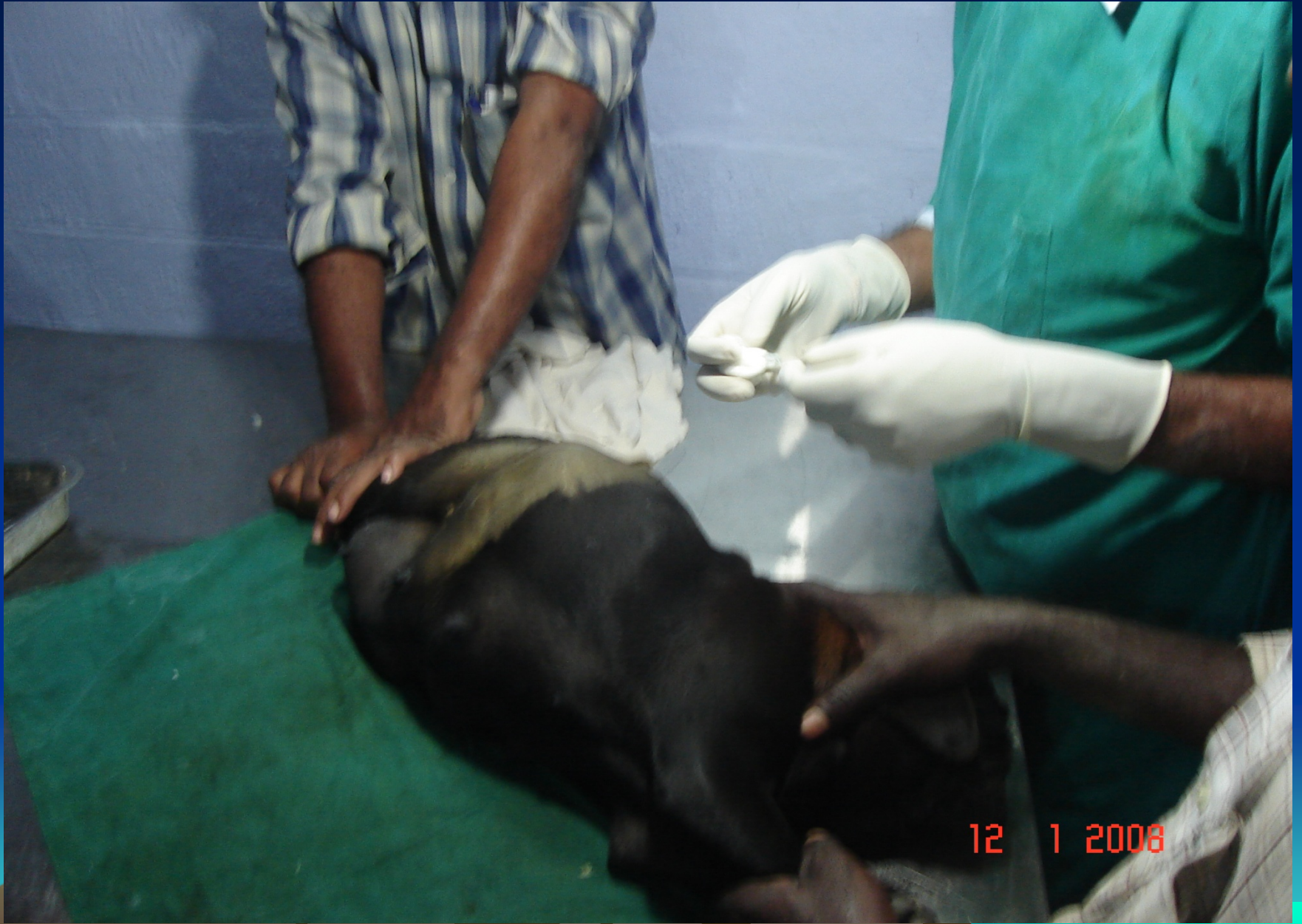- Inj. Ropine at 0.045mg/kg body wt i/m
- Inj. Xylazine at 1 mg/kg body wt i/m
- Inj. Lignocaine 2% epidural to effect
- Inj. Lignocaine 2% as local infiltration

POST OPERATIVE CARE

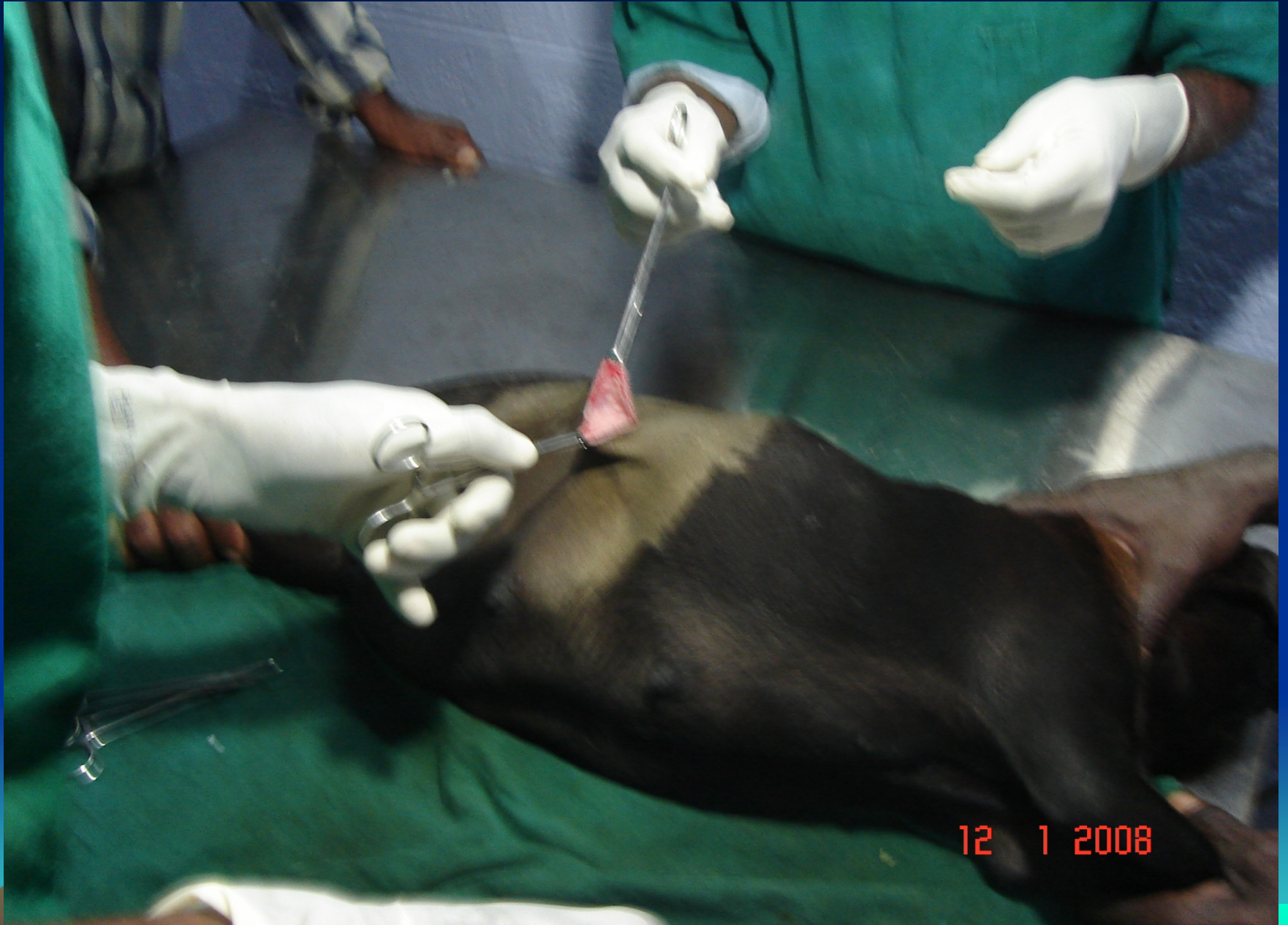- Inj. Oxytocin i/v
- Inj. Cefataxime 500 mg BID for 2 days through i/v
- Inj. Cefataxime 500 mg SID for 5 days through i/m
- Intravenous fluid therapy – DNS & RL for 2 days
- Daily dressing done with T-Bact ointment (Mupirocine)
- Sutures removed on 10th postoperative day



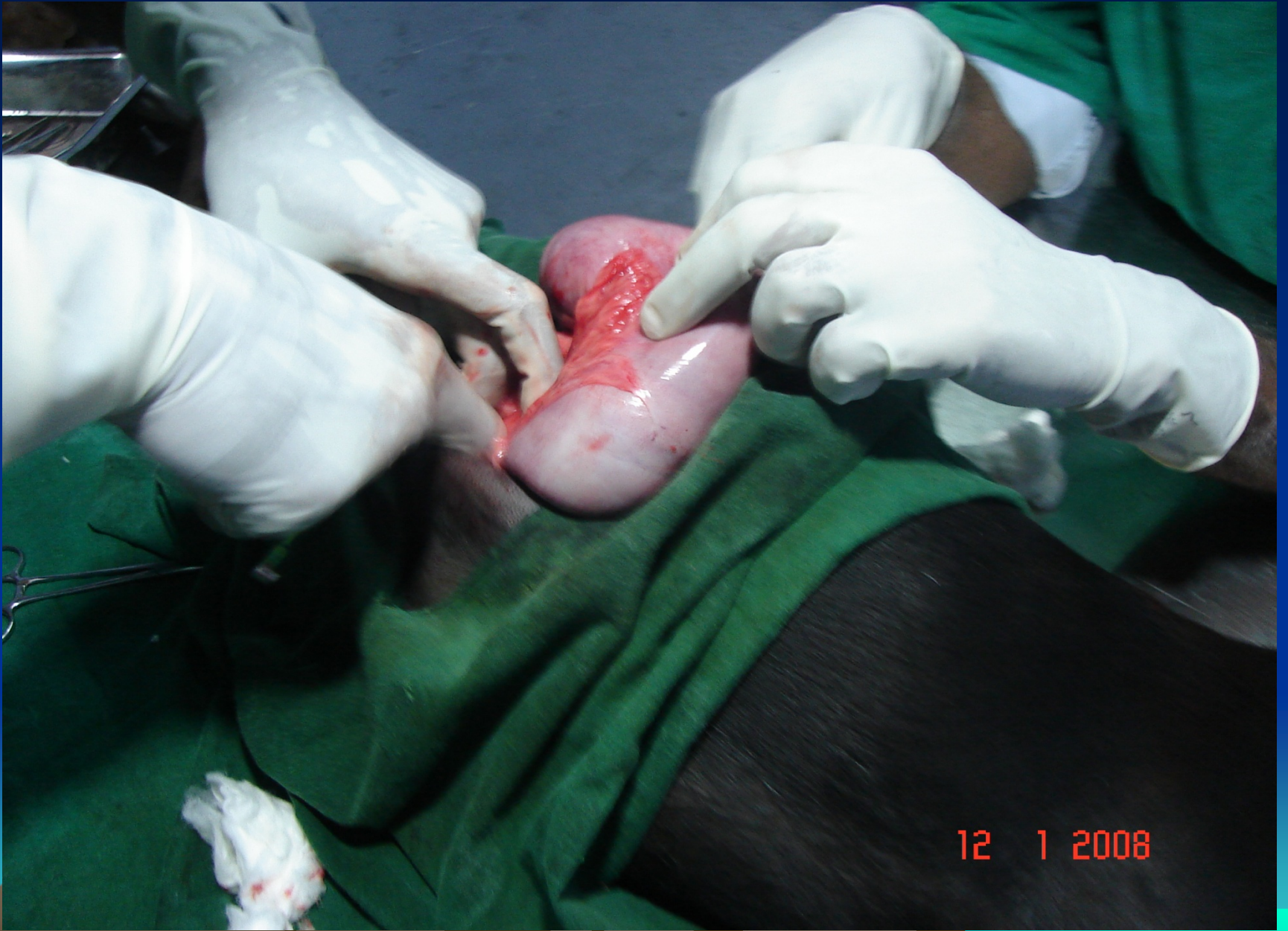12 1 2008



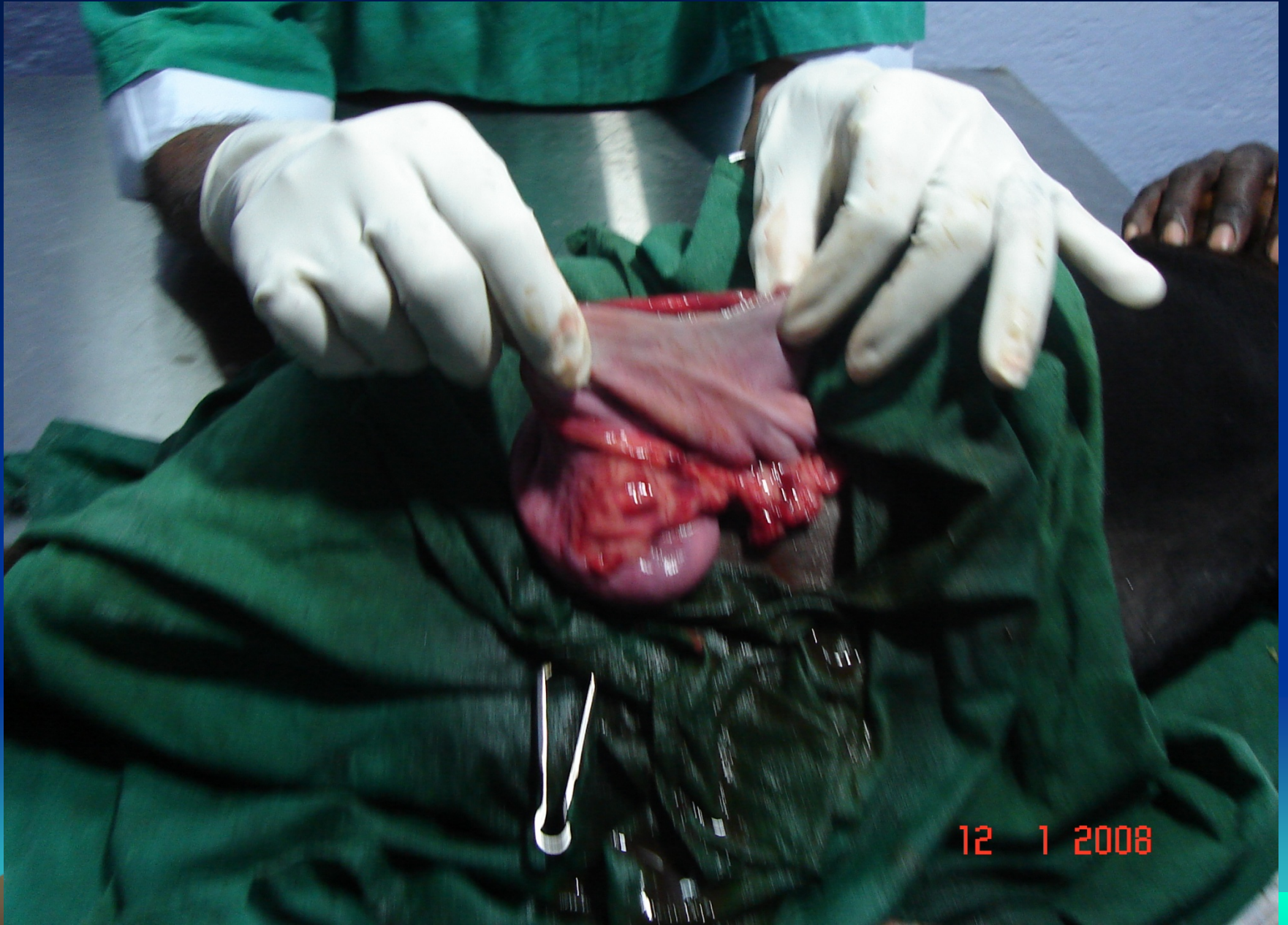
12 1 2008



12 1 2008

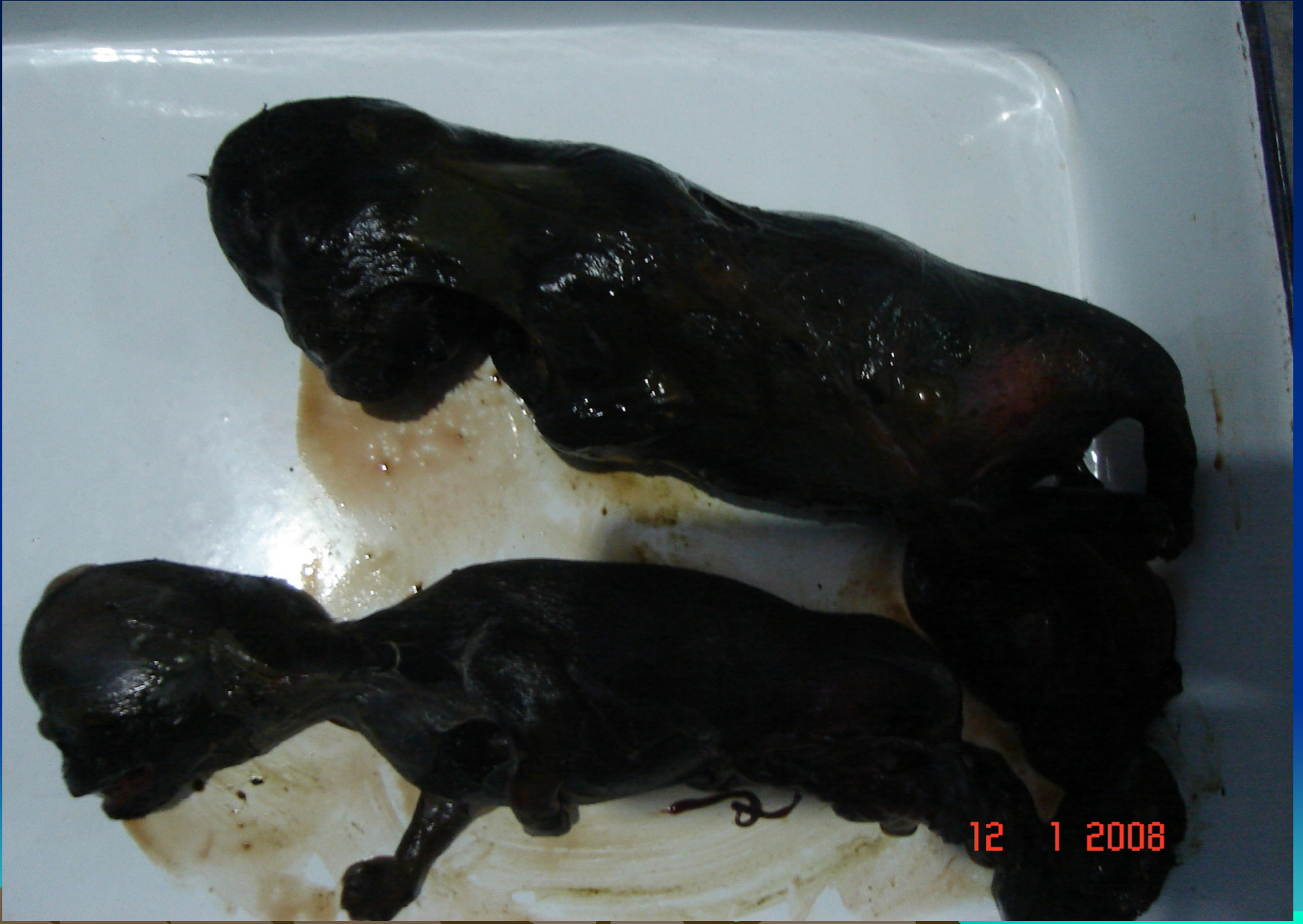

12 1 2008

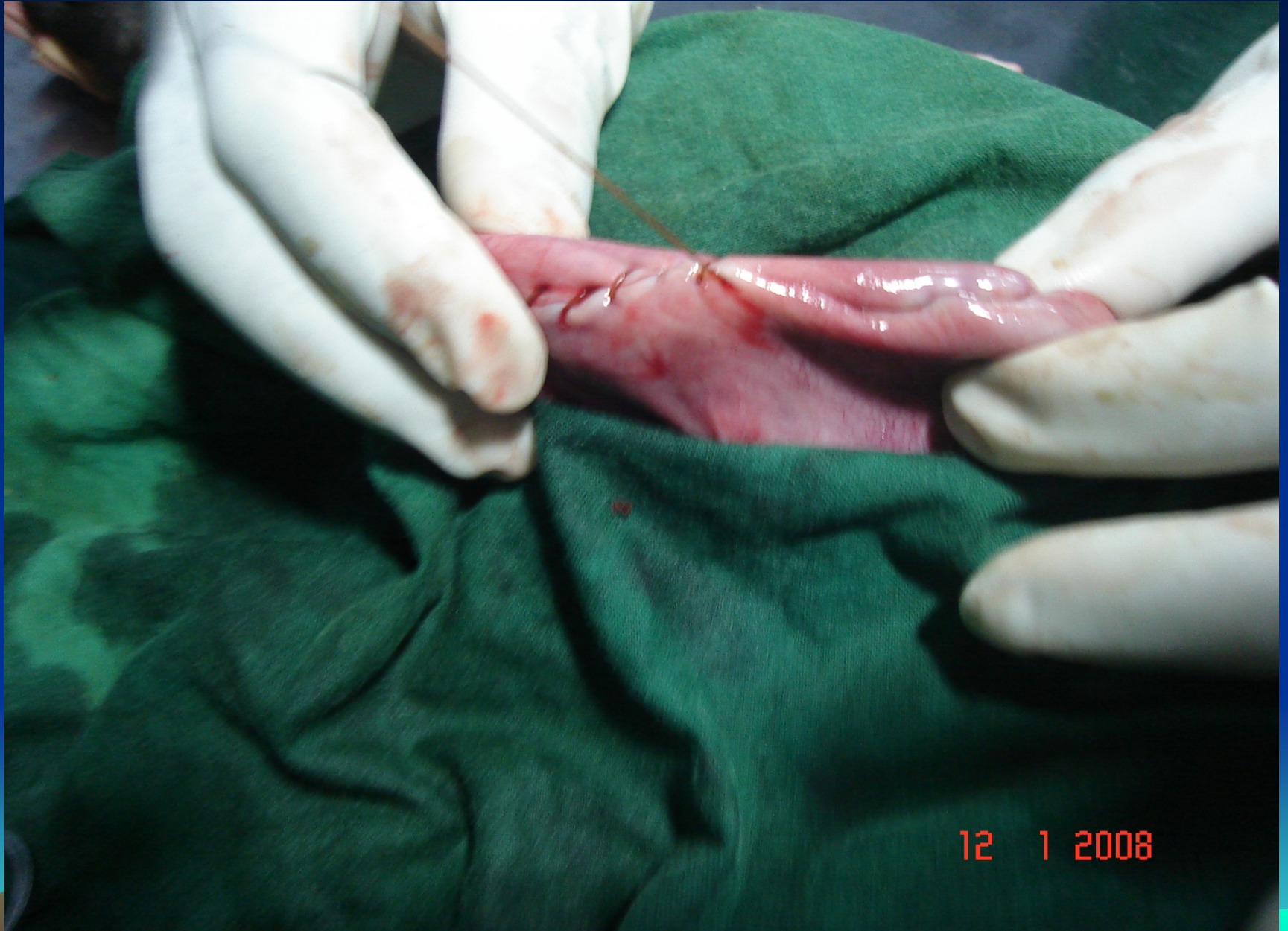



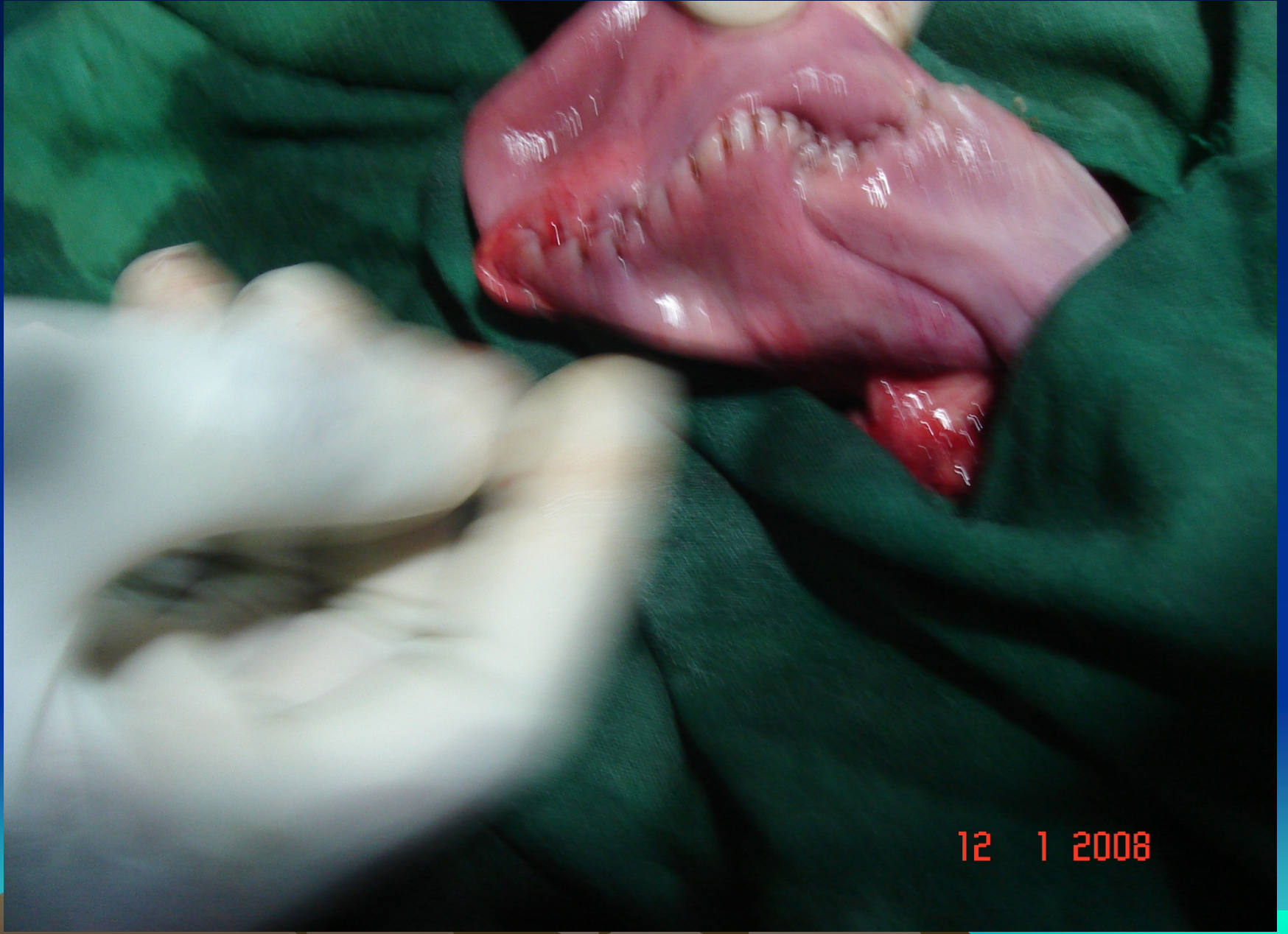12 1 2008



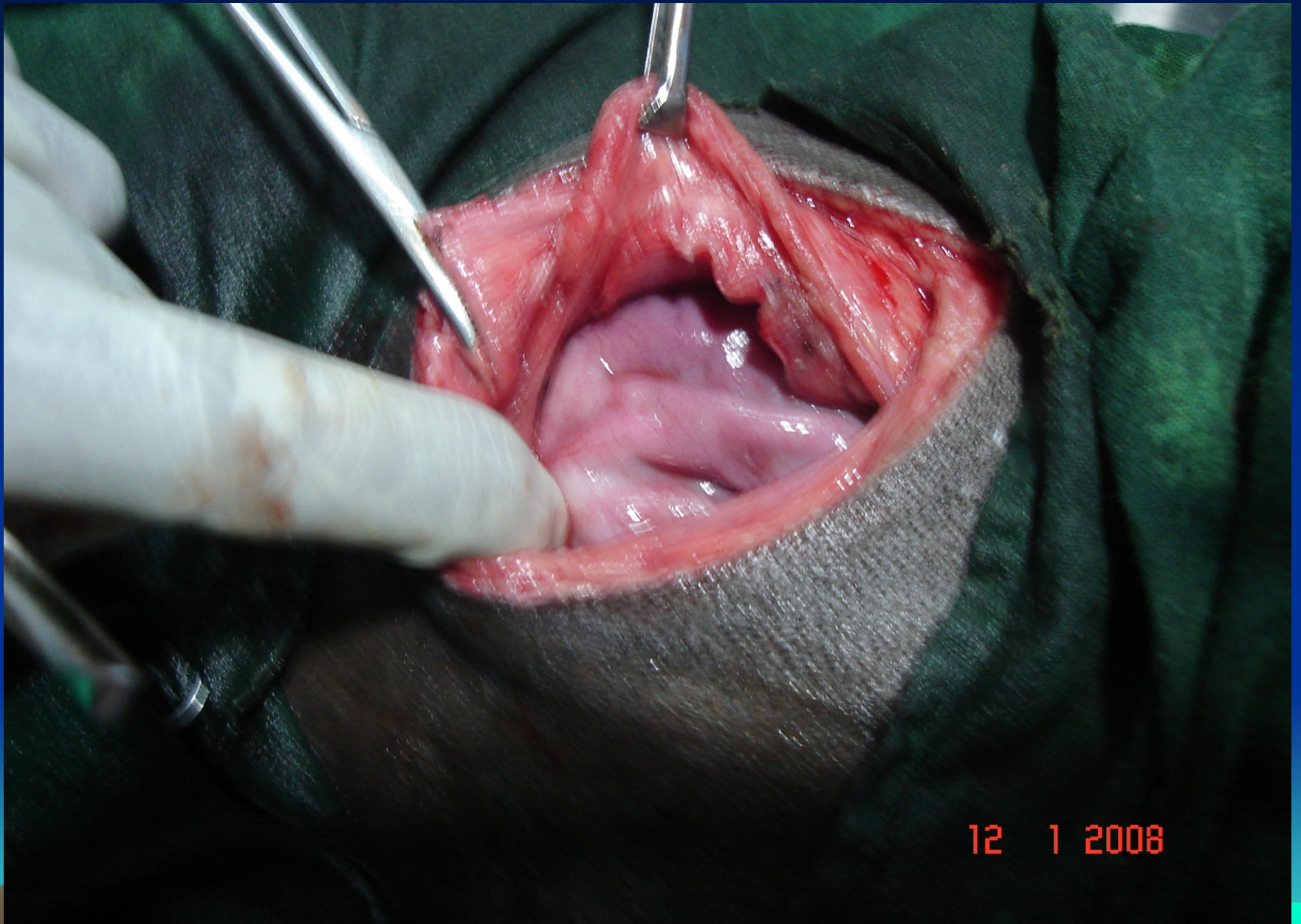
12 1 2008



12 1 2008



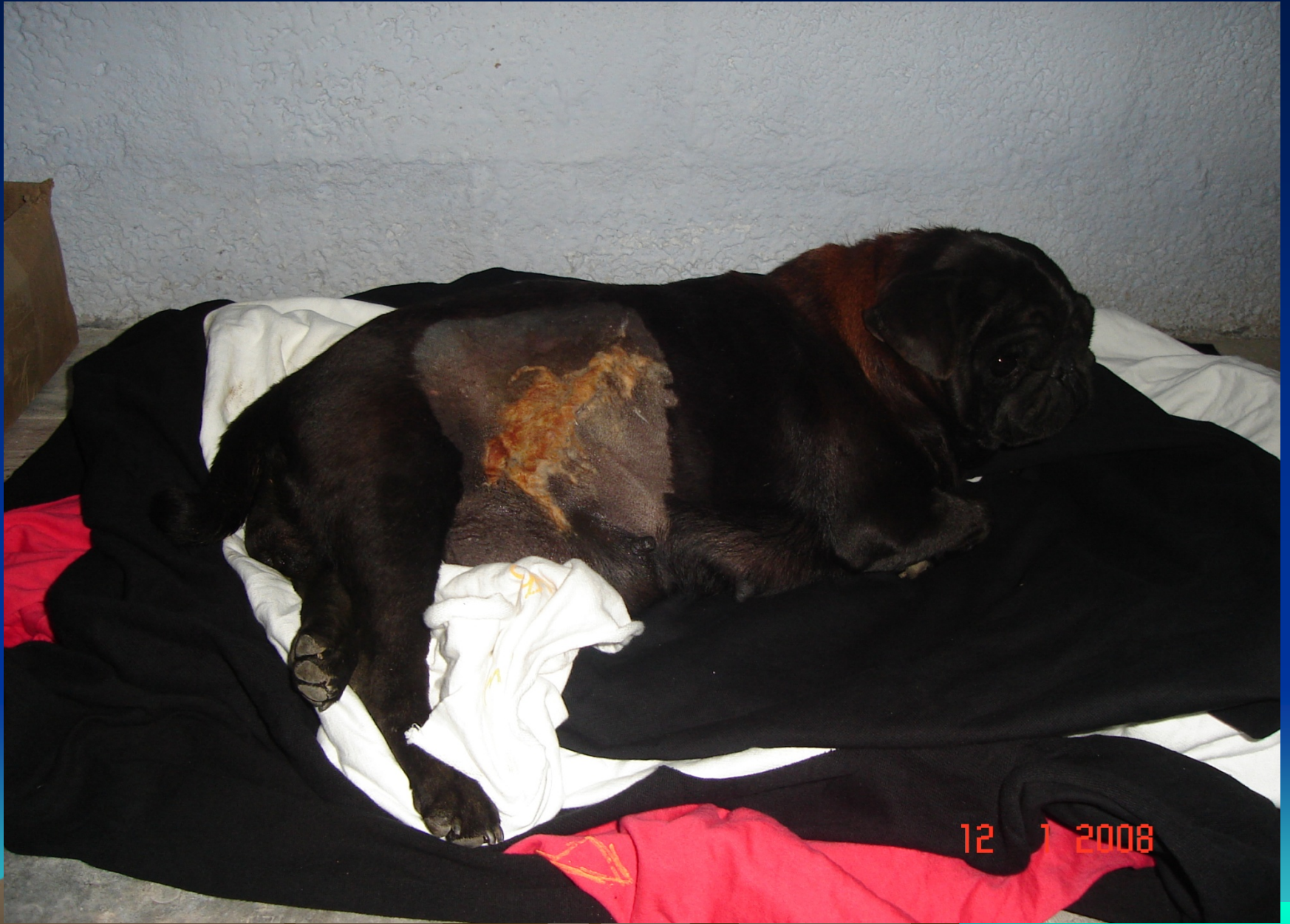12 1 2008



12 1 2008



12 1 2008



12 7 2008





18 1 2008

THANK YOU

