

# PRF to Enhance the Esthetic Outcome of Surgical Treatment of Cutaneous Chronic Fistula

ALESSANDRO ESPEDITO DI LAURO<sup>1#</sup>, HORIA CALNICEANU<sup>2#</sup>, FABIO SCOTTO<sup>1</sup>, STEFAN STRATUL<sup>2</sup>, DARIAN RUSU<sup>2\*</sup>, MARIUS BOARIU<sup>3#</sup>, LAURA CRISTINA RUSU<sup>4</sup>, VICENZO IORIO SICILIANO<sup>5</sup>

<sup>1</sup> Department of Oral Surgery, University Federico II, Naples, Italy

<sup>2</sup> Victor Babes University of Medicine and Pharmacy, Department of Periodontology, 2 Eftimie Murgu Sq., 300041, Timisoara, Romania

<sup>3</sup> Victor Babes University of Medicine and Pharmacy, Department of Endodontics, 2 Eftimie Murgu Sq., 300041, Timisoara, Romania

<sup>4</sup> Victor Babes University of Medicine and Pharmacy, Department of Oral Pathology, 2 Eftimie Murgu Sq., 300041, Timisoara, Romania

<sup>5</sup> Department of Periodontology, Magna Graecia University, Catanzaro, Italy

*Cutaneous odontogenic fistulas or sinus tracts are uncommon manifestations of chronic dental infections that typically begin at the apex and discharge the suppurative material through the skin. They usually respond to conventional endodontic treatment or to removal of the causative tooth, leaving often very unesthetic retractile scars. For esthetic reasons, surgical treatment is sometimes necessary to remove the sinus tract. Platelet-Rich Fibrin (PRF) is an autologous source of growth factors obtained from the centrifugated blood of the patient, supporting collagen synthesis, tissue repair and accelerating the wound healing. This is the first to demonstrate the surgical technique using membrane-shaped PRF after resective surgery of a cutaneous sinus tract, simultaneous with the removal of the causative tooth, in comparison with a case treated only with removal of the dental starting point of the infection. The benefic role of this technique in the esthetic post-surgical healing is suggested.*

*Keywords: Cutaneous odontogenic fistula, sinus tract, PRF*

Cutaneous sinus tracts or fistulas are uncommon manifestations of pulpal necrosis that typically begins at mandibular teeth apex, perforate the hard and soft layers in buccal direction, and discharge the suppurative material through the skin [1]. The sinus tract appears most commonly on the chin or jaw line, but they can also appear elsewhere on the face and neck [2,3]. The diagnosis of the infectious source of a sinus tract is challenging and is the most important aspect for the successful treatment [4]. The literature frequently mentions cases of cutaneous fistulas, as originating from misdiagnosed pyogenic granuloma. The use of systemic antibiotics only results in temporary cessation of the drainage, which returns immediately after the antibiotic treatment is over [5]. The correct treatment protocol is based on elimination of the focal infection (either the conservative endodontic treatment of the causative tooth, or its extraction) [6-8] followed by the esthetic excision of the sinus tract. L-PRF in form of fibrin clot was previously used to enhance the cutaneous healing process after various skin surgeries [9]. In the mentioned cases, the fibrin clot was known to release gradually growth factors or cytokines (VEGF, PDGF, TGF-beta, Thrombospondin etc.) in the surgical site [10]. This is a surgical technique using membrane-shape PRF after resective surgery of a cutaneous sinus tract simultaneous with the removal of the causative tooth, in comparison with a case treated only with removal of the dental starting point of the infection. The proposed technique is aimed to improve the healing, to reduce residual retractile scars and to enhance the esthetic outcome.

## Experimental part

### Case 1

A 63-year caucasian male, smoker patient, with no relevant medical history, referred to our clinic with a chief

complaint of a chronically draining lesion on the lower left mandible. He recalled that the fistula appeared two months ago, but, in absence of any significant pain, his chief complaint was the inesthetic appearance of the lesion. The initial extraoral examination revealed an erythematous retractile nodule, with continuous drainage, tender and soft at palpation, at the mid distance between the gonion and the chin, on the left lower anterior cheek (fig. 1A). No modifications of the regional lymph nodes were noted. Endooral examination revealed deficient oral hygiene, plaque, calculus, and a deep carious lesion of the tooth 3.5 (fig. 1B). The tooth was the only on the quadrant irresponsive to thermal or electric pulp testing, with advanced loss of support and severe mobility (grade III). These dental clinical findings excluded other possible regional causes of the infection.

Based on the clinical findings, the decision to simultaneously extract the tooth and to surgically remove the sinus tract was taken (fig. 1C, D). The patient agreed to the intervention and to the suggestion of adding supplementary healing factors for a better esthetic outcome.

The tissue dissection in planes, the isolation and the removal of the fistula were performed using Bard-Parker blades No.15 and Klemmer forceps (fig. 1D). Prior to the surgery, cca 40 cc of venous blood were collected in four 9mL glass-coated plastic tubes (Intra-Lock, Boca Raton, FL, USA) without anticoagulant to obtain the PRF (Platelet Rich Fibrin). The protocol was performed with the Intra-Spin centrifuge (Intra-Lock, Boca Raton, FL, USA) set at 2700 rpm (around 400g) for 12 min. The centrifugation results in the formation of the clot and the activation of the growth factors. After the centrifugation, the tubes were left to rest for 5 min, then the PRF clots were collected together with some red blood cells from the test-tubes,

\* email: rusu.darian@gmail.com

# Authors with equally contributions

using sterile pliers (fig. 1E). The clots were digitally compressed between two gauzes in order to obtain maneuverable membranes (fig. 1F).

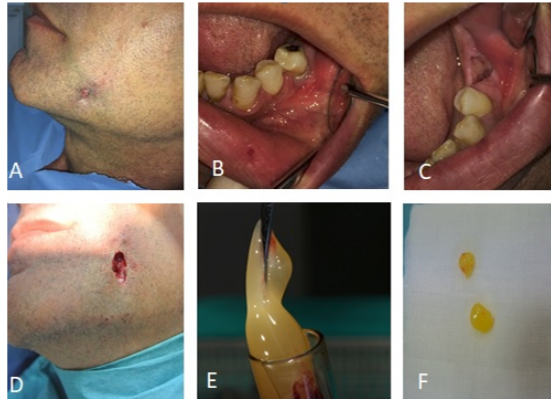

Fig. 1. A. Pre-operative extra-oral situation. Note the buttoned cutaneous fistula. B. Intra-oral view. Note the deep cavity on tooth 3.5. C. The causative tooth extracted. D. The surgically removal of the fistula. E. The PRF clot. F. The compressed clot in shape of membrane

The first PRF membrane was inserted in the wound (fig. 2A). The suture of the muscular plane was performed using resorbable vycril 4/0 sutures. The last PRF membrane was inserted between the muscular and the cutaneous plane, the latter being sutured with braided vycril 4/0 sutures (fig. 2B). Steri-strips were used to approximate the cutaneous plane (fig. 2C). The same oral medication as in the previous case was prescribed, as well. In both cases, the healing occurred uneventful, the sutures were removed after ten days. Daily massage with Contractubex gel (Merz Pharma GmbH & Co., Frankfurt/Main, Germany) was recommended for the next two months post-operatively, in order to enhance the skin mobility and to avoid developing of retractile scars. At one month, in the case treated with L-PRF, the former surgical area presented a completely scar-free aspect, of normal pigmentation and pilosity, with a slight dimple (fig. 2D). The timeline of case 1 is displayed in figure 3.

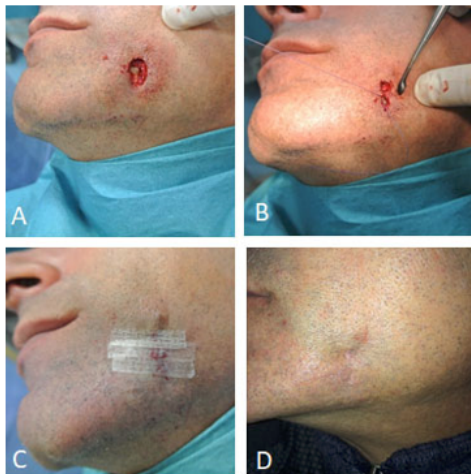

Fig. 2. A. The folded membrane pushed into the surgical wound. B. The cutaneous plane sutured. C. Steri-stripes to approximate the margins of the wound. D. The healed wound at 4 weeks after the surgery. Note the completely scar-free aspect and normal pigmentation & pilosity

### Case 2

A 42-yo caucasian male patient, non-smoker, in good clinical health, was referred to our clinic with a chronically draining lesion on the right side of the lower anterior cheek. History of the case revealed a small swelling in the anterior

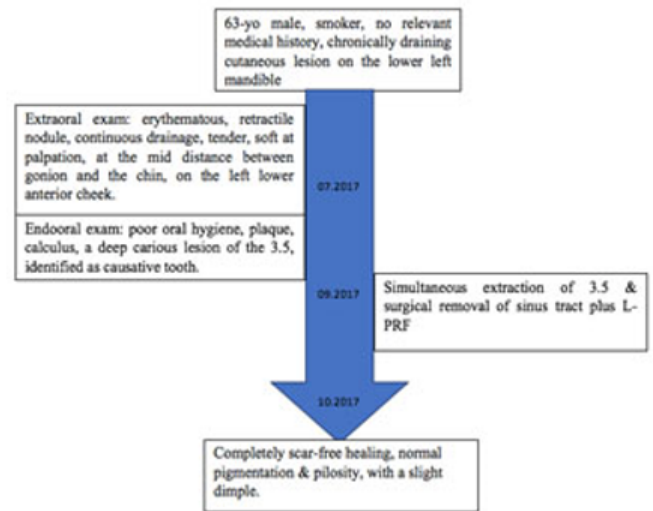


Fig. 3. Timeline of case 1: cutaneous fistula of dental origin treated by extraction of causative tooth simultaneously with the surgical removal of sinus tract plus PRF

right jaw, associated with recurrent untreated dental abscesses of lateral mandibular teeth in the last 12 months. The swelling was followed by a cutaneous draining lesion, long time neglected by the patient. The initial extraoral examination revealed a draining erythematous nodule, soft at palpation and mobile. The digital pressure of the nodule resulted in discharge of a reduced amount of sanguinolent content (fig. 4A, B). Endooral examination revealed a poor oral hygiene with multiple tooth decays, plaque and calculus accumulation, generalized gingival inflammation, loss of periodontal support, teeth with increased mobility of various degrees and residual roots (fig. 4C)

Computed tomography revealed a large, irregular radiotransparent area of 1.5 cm in diameter of the right mandible region, including the residual roots of tooth 4.6, and a large circumferential periodontal defect of tooth 4.4 (fig. 4D). The images suggested tooth 4.6 as the origin of the lesion. The patient agreed to a surgical intervention limited only at the removal of the etiological tooth.

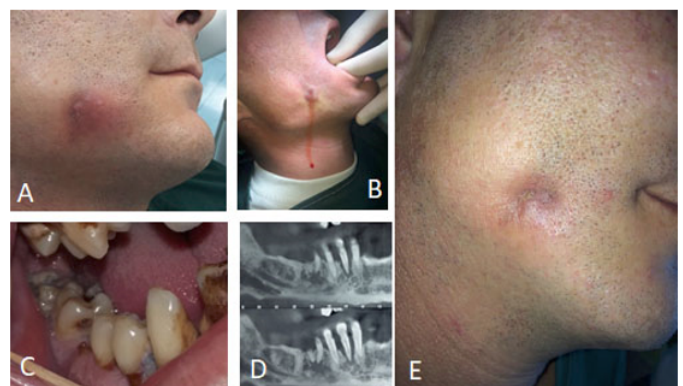

Fig. 4. A. Extra-oral aspect of the sinus tract. B. Discharge of a reduced amount of sanguinolent content. C. Poor oral hygiene, multiple carious lesions and loss of periodontal support. D. CBCT image presenting the osteitic lesion including the residual roots of tooth 4.6 and the crater-like deep osseous defect of tooth 4.4. E. Cutaneous unesthetic retractile scar, five weeks after the surgery

After a thorough professional hygiene, the patient was referred for oral surgery. The surgical extraction of the residual roots of 4.6 and the curettage of the cystic lesion was performed. A collagen sponge was inserted and the margins of the alveolar wound and several 4-0 sutures were placed. Analgetic medication (Ibuprofen, 3x400 mg/day) but no antibiotics were prescribed. The healing occurred uneventful and the sutures were removed after ten days.

Daily massage with Contractubex was also recommended. The sinus tract healed progressively after cca. 2 weeks, leaving a cutaneous residual scar. Its appearance did not improve post-operatively, displaying at one month an inesthetic, circular, purple-pigmented, relatively adherent, retractile scar, centered by a depression, with disturbed pilosity in the lower right jaw region (fig. 3E). The timeline of case 2 is displayed in figure 5.

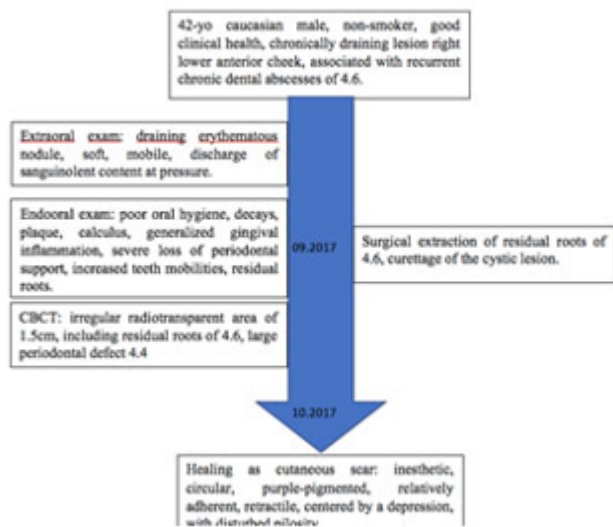


Fig. 5. Timeline of case 2: cutaneous fistula of dental origin treated by extraction of causative tooth and curettage of the cystic lesion

## Results and discussions

As far as we know, this is the first case report to describe comparatively two cases of treatment of cutaneous fistula of dental origin, with or without additional use of PRF membranes. Moreover, a surgical technique of using the PRF concentrate for this indication is proposed and described in detail.

Currently, platelet-rich plasma is being used in periodontal and oral surgical practices in a wide variety of applications. 27 of the 31 clinical studies (87%) analyzed in a recent systematic review supported the use of PRF for soft tissue regeneration and wound healing, in a variety of procedures in medicine and dentistry. The review concluded that PRF has positive effects on wound healing after regenerative therapy for the management of various soft tissue defects in medicine and dentistry [11]. The use of platelet concentrates for topical use is of particular interest for the promotion of skin wound healing. Fibrin-based surgical adjuvants have been widely used indeed in plastic surgery over many years, in order to improve scar healing and wound closure. The addition of platelets and their associated growth factors opened a new range of possibilities, particularly for the treatment of chronic skin ulcers and other applications of regenerative medicine of the covering tissues [12].

If correctly diagnosed and the cause of the dental chronic infection timely removed, cutaneous sinus tracts are expected to disappear within one or two weeks, always leaving inesthetic residual scars or retractile scars, connected to the periosteum of the former cortical perforation by a fibrous, sometimes intraorally palpable chord. If the source of infection is not removed, systemic antibiotic therapy will result in a temporary cessation of a drainage and apparent healing. The tract will recur immediately after the antibiotic therapy [13]. For esthetic reasons, the scar lesion can be surgically removed, either simultaneously with the removal of the infected tooth, or,

more frequently, at a later point [14]. Clinical examination, dental radiograph and CBCT are usually necessary for the certitude diagnosis [14]. In rare cases, clinical examination alone provides sufficient data to support the diagnosis of cutaneous sinus tract of dental origin, and indicates the tooth that originated the lesion.

As far as we know, this case report describes for the first time the simultaneous removal of the causative tooth and the fistulous lesion, by a surgical technique that employs the PRF concentrate in shape of a membrane. The described procedure is in contrast with the only existing report of an oro-antral fistula following sinus augmentation and implant placement treated by using PRF [15]. In that case report, a series of PRF clots was inserted non-pressed into the sinus cavity through a large oro-antral opening, which was surgically closed by covering with an oral flap. In our case, the membranes resulted by pressing the fibrin clot were pushed into the oro-cutaneous wound towards the empty alveolar socket via the bone plate orifice, except the last one, which was inserted between the muscular and the cutaneous plane. The membrane-shape of the PRF clot was chosen over the disk-shape, as being easier to be handled and to be pushed into the former tract of the fistula, while the last PRF-membrane seemed to be appropriate to be inserted between the layers of the surgical wound. One of the limitations of the described technique was the use of PRF clots pressed between two gauzes. In the future, to further improve the surgical technique, for the same indication (surgical removal of cutaneous fistulas) PRF clots pressed between the plates of the PRF-Box could be used, in order to obtain more compact membranes.

The benefit of adding the PRF concentrate to the known surgical technique of removing the fistula was a faster healing with a clearly improved esthetic appearance, when compared with the similar case treated without PRF. In the near future, the esthetic outcome of similar procedures could be probably enhanced by perio-lesional injections with i-PRF or A-PRF-liquid [16, 17]. However, the precise protocols of such therapeutic additions needs to be discussed.

## Conclusions

This study showed that the use of PRF seems to have a benefic role in the healing process after respective surgery of cutaneous sinus tract, improving the wound healing without leaving inesthetic, retractile scars. Beyond the observed benefit in cutaneous sinus tracts of dental origin, PRF could be a valuable addition in the surgical treatment of other various skin defects of the face. However, clinical trials including more cases and evaluating also patient-centered outcomes are needed in order to further validate the indication of PRF and to improve the surgical technique.

## List of abbreviations

- PRF – Platelet Rich Fibrin
- VEGF – Vascular Endothelial Growth Factor
- PDGF – Platelet-Derived Growth Factor
- TGF-beta – Transforming Growth Factor beta
- CBCT – Cone Beam Computer Tomography
- i-PRF – injectable PRF
- A-PRF – Advanced PRF

*Acknowledgements: This study was partially supported by an internal grant (P-IV-CI-PDCC 2015/2016, contract 7199/01.07.2015) of the Victor Babes University of Medicine and Pharmacy, Timisoara, Romania.*

## References

1. BROWN RS, JONES R, FEIMSTER T, SAM FE. Cutaneous sinus tracts (or emerging sinus tracts) of odontogenic origin: a report of 3 cases. *Clin Cosmet Investig Dent*. 2010 Jul 5;2:63-7.
2. MARASCO PV, TAYLOR RG, MARKS MW. Dentocutaneous fistula. *Ann Plast Surg*. 1992;29:205-210.
3. KARP MP, BERNAT JE, COONEY DR. Dental diseases masquerading as suppurative lesions of the neck. *J Pediatric Surg*. 1982;17:532-536
4. EDVARD JANEV, ENIS REDZEP. Managing the Cutaneous Sinus Tract of Dental Origin. *Maced JMed Sci*. 2016 Sep 15; 4(3): 489-492.
5. GIMENEZ-GARCÍA R, MARTINEZ-VERA F, FUENTES-VERA L. Cutaneous Sinus Tracts of Odontogenic Origin: Two Case Reports. *J Am Board Fam Med*. 2015 Nov-Dec;28(6):838-40.
6. LUCHIAN, A.L., MARTU, I., GORIUC, A., MARTU, C., BELDIMAN, A., MARTU, S., *Rev. Chim. (Bucharest)*, **67**, no. 4, 2016, p. 741
7. LUCHIAN, I., MARTU, I., GORIUC, A., VATA, I., HURJUI, L., MATEI, M.N., MARTU, S., *Rev. Chim. (Bucharest)*, **67**, no. 10, 2016, p. 2119
8. URSARESCU, I.G., MARTU STEFANACHE,, M.A., SOLOMON, S.M., PASARIN, L., BOATCA, R.M., CARUNTU, I.D., MARTU, S., *Rev. Chim. (Bucharest)*, **67**, no. 2, 2016, p. 386
9. CIESLIK-BIELECKA A, CHOUKROUN J, ODIN G, DOHAN EHRENFEST DM. L-PRP/L-PRF in esthetic plastic surgery, regenerative medicine of the skin and chronic wounds. *Curr Pharm Biotechnol*. 2012 Jun;13(7):1266-77
10. CHOUKROUN J, DISS A, SIMONPIERI A, GIRARD MO, SCHOEFFLER C, DOHAN SL, DOHAN AJ, MOUHYIJ, DOHAN DM. Platelet-rich fibrin (PRF): a second-generation platelet concentrate. Part IV: clinical effects on tissue healing *Oral Surg Oral Med Oral Pathol Oral Radiol Endod*. 2006 Mar;101(3):e56-60.
11. MIRON RJ, FUJIOKA-KOBAYASHI M, BISHARA M, ZHANG Y, HERNANDEZ M, Choukroun J. Platelet-Rich Fibrin and Soft Tissue Wound Healing: A Systematic Review. *Tissue Eng Part B Rev*. 2017 Feb;23(1):83-99.
12. SPEAR KL, SHERIDAN PJ, PERRY HO, Sinus tracts to the chin and jaw of dental origin. *J Am Acad Dermatol* 1983; **8**:486-92
13. JOHNSON BR, REMEKIS NA, VAN CURA NA. Diagnosis and treatment of cutaneous facial sinus tracts of dental origin. *J Am Dent Assoc*. 1999; **130**:832-836
14. PASTERNAK-JUNIOR B, TEIXERA CS, SILVA-SOUSA YT, SOUSA-NETO MD. Diagnosis and treatment of odontogenic cutaneous sinus tracts of endodontic origin: three case studies. *Int. Endod J* 2009;42(3):271-76
15. DEPOI R, JOHN V, PAEZ DE MENDOZA CY, GOSSWEILER MK. Development of an oro-antral fistula following sinus elevation surgery: a case report on management using platelet-rich plasma. *J Indiana Dent Assoc*. 2007-2008 Winter;86(4):10-6.
16. ZHAO Q, DING YJ, SI T. Platelet-rich fibrin in plastic surgery. *OA Evidence-Based Medicine* 2013 Apr 01;1(1):3.
17. SCLAFANI AP, SAMAN M. Platelet-rich fibrin matrix for facial plastic surgery. *Facial Plast Surg Clin North Am*. 2012 May;20(2):177-86

Manuscript received: 13.04.2017