

Online Submissions: [wjg.wjgnet.com](http://wjg.wjgnet.com)  
[www.wjgnet.com](http://www.wjgnet.com)  
[wjg@wjgnet.com](mailto:wjg@wjgnet.com)



World J Gastroenterol 2008 February 7; 14(5): 720-724  
 World Journal of Gastroenterology ISSN 1007-9327  
 © 2008 WJG. All rights reserved.

## RAPID COMMUNICATION

# Double balloon endoscopy associated pancreatitis: A description of six cases

Soeresh VA Jarbandhan, Stijn JB van Weyenberg, Willem M van der Veer, Dimitri GN Heine, Chris JJ Mulder, Maarten AJM Jacobs

Soeresh VA Jarbandhan, Stijn JB van Weyenberg, Willem M van der Veer, Dimitri GN Heine, Chris JJ Mulder, Maarten AJM Jacobs, Small Bowel Unit, Department of Gastroenterology, VU University Medical Center Amsterdam, The Netherlands  
 Correspondence to: Soeresh VA Jarbandhan, MD, Small Bowel Unit, Department of Gastroenterology, VU University Medical Center Amsterdam, PO Box 7057, 1007 MB, Amsterdam, The Netherlands. [v.jarbandhan@vumc.nl](mailto:v.jarbandhan@vumc.nl)  
 Telephone: +31-20-4440613 Fax: +31-20-4440554  
 Received: August 14, 2007 Revised: October 25, 2007

Adverse events; Complications; Pancreatitis; Enteroscopy

**Peer reviewer:** Ibrahim Abdulkarim Al Mofleh, Professor, Department of Medicine, College of Medicine, King Saud University, PO Box 2925, Riyadh 11461, Saudi Arabia

Jarbandhan SVA, van Weyenberg SJB, van der Veer WM, Heine DGN, Mulder CJJ, Jacobs MAJM. Double balloon endoscopy associated pancreatitis: A description of six cases. *World J Gastroenterol* 2008; 14(5): 720-724 Available from: URL: <http://www.wjgnet.com/1007-9327/14/720.asp> DOI: <http://dx.doi.org/10.3748/wjg.14.720>

## Abstract

**AIM:** To perform a single-center analysis of all double balloon endoscopy (DBE) related cases of pancreatitis identified prospectively from a recorded DBE-complication database.

**METHODS:** From November 2003 until January 2007, 603 DBE procedures were performed on 412 patients, with data on complications recorded in a database. The setting was a tertiary care center offering DBE. DBE was performed from the antegrade or retrograde route. Outcome measurements included age, gender, medication, indication, DBE-endoscope type, insertion depth, procedure duration, findings, interventions, post-procedural abdominal pain, and post-procedural hospitalization.

**RESULTS:** This is the largest single-center study reporting on post-DBE pancreatitis prospectively. Six patients (1.0%) developed post-DBE pancreatitis, all after antegrade DBE. There was no association with gender, duration of the procedure or type of endoscope. The mean age was 51.9 years (range 25-78). Four patients had severe pancreatitis. Of these, two had inflammatory signs in the body-tail region, one had pancreatitis in the tail region, and the total pancreas was involved in one.

**CONCLUSION:** The incidence of post-DBE pancreatitis in our series is higher than previously reported. We found no relation with DBE-endoscope type. The inflammatory changes occurred in the body-tail region of the pancreas, suggesting that post-DBE pancreatitis is caused by repetitive mechanical strain on the pancreas.

© 2008 WJG. All rights reserved.

**Key words:** Double balloon endoscopy; Small intestine;

## INTRODUCTION

Since its introduction in 2001 by Yamamoto<sup>[1]</sup>, double balloon endoscopy (DBE) has revolutionized both diagnostic and therapeutic small bowel endoscopy<sup>[2]</sup>. This technique allows (intervention) endoscopy of the complete small bowel (often in two sessions) with the possibility of carrying out interventions; e.g. mucosal biopsy, argon plasma coagulation, snare polypectomy, injection therapy, tattooing, foreign body extraction and balloon dilatation. DBE plays an important role in the diagnosis and treatment of obscure gastrointestinal bleeding<sup>[3-6]</sup>, Crohn's disease<sup>[7-10]</sup>, celiac disease<sup>[11,12]</sup>, polyposis syndromes<sup>[13]</sup> and small bowel tumors. In the series published to date, complications solely related to the diagnostic procedure are rare<sup>[14-18]</sup>. A recent retrospective multicenter survey indicates a complication rate of 0.8% in diagnostic procedures<sup>[16]</sup>. In that study, pancreatitis occurred in six of 2362 (0.3%) procedures and contributed to 46% of all complications after diagnostic DBE. Another recent study showed that an asymptomatic rise of serum amylase and lipase levels after antegrade DBE is frequently encountered<sup>[19]</sup>. Nevertheless, only a few patients develop the clinical picture of post-DBE pancreatitis. The reason for this remains unknown.

This article presents an analysis of all DBE-related cases of pancreatitis identified prospectively from a recorded DBE-complication database of 603 procedures in a single center.

## MATERIALS AND METHODS

From November 2003 to January 2007, 603 DBE

Table 1 Patient characteristics

	Gender	Age (yr)	Indication	Scope type	Midazolam (mg)	Fentanyl (mg)	Duration (cm)	Insertion length (cm)	Interventions	Admission (d)	CT inflammation	Peak amylase U/L	Peak lipase U/L
1	M	66	Anemia	P	15	0.100	120	400	Biopsy	7	No CT	334	734
2	M	60	Anemia	P	12.5	0.150	90	250	Biopsy	21	Corpus Tail	412	160
3	F	37	Malabsorption	T	12.5	0.075	90	250	None	2	Tail	619	2037
4	M	54	Anemia	P	10	0.050	80	300	None	11	Total	1395	3660
5	F	23	M.Crohn	P	15	0.150	120	420	None	22	Corpus Tail	1071	369
6	F	44	Small bowel stenosis	T	15	0.050	145	400	Polypectomy	4	No CT	321	120

Reference values: amylase 0-100 U/L, lipase 0-70 U/L.

procedures were performed in an outpatient setting in the Department of Gastroenterology at the VU University Medical Center in Amsterdam, The Netherlands. In our procedures, we used the Fujinon EN-450P5- and the thicker Fujinon EN-450T5 endoscopes. Of the total number of procedures, 311 were performed in men (51.6%) and 292 in women (48.4%) with a mean and median age of 59 and 60 years respectively (range 12-94). Informed consent was obtained from all patients in accordance with the institutional review board guidelines. Data recorded in the complication database included age, gender, co-morbidity, surgical history, medication, indication for DBE, depth of insertion as described by May<sup>[20]</sup>, procedure duration, findings, interventions performed, post-procedural abdominal pain, and post-procedural hospitalization. The patients received a combination of midazolam and fentanyl intended for conscious sedation.

The complication database was reviewed. All patients with post-DBE pancreatitis were identified and their charts were reviewed for additional clinical information including severity of pancreatitis, length of hospitalization, peak serum CRP, peak serum amylase, peak serum lipase, abdominal imaging performed, surgery performed and mortality.

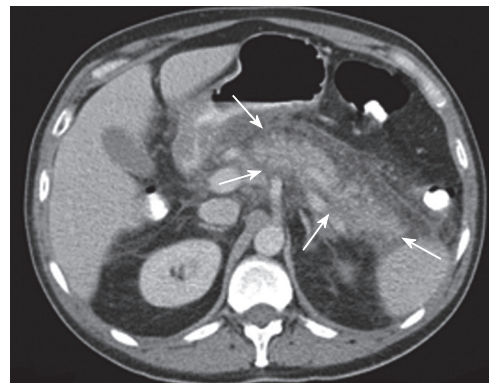
According to the literature on post-endoscopic retrograde cholangiopancreatography pancreatitis (ERCP; American Society of Gastrointestinal Endoscopy (ASGE) guidelines), post-DBE pancreatitis was defined as newly developed abdominal pain after a DBE-procedure, requiring at least 2 d of unplanned hospitalization, with a serum amylase  $\geq 3$  as the upper limit 24 h after the procedure<sup>[21]</sup>. According to these guidelines, the severity of the disease was classified as follows: mild pancreatitis requiring 2-3 d of hospitalization; moderate pancreatitis requiring 4-10 d of hospitalization; severe pancreatitis requiring 10 or more days of hospitalization, and/or the occurrence of pseudocysts and/or the need for surgery.

### Statistical analysis

The different parameters were compared with t-tests. Results were considered significant if *P* values were < 0.05.

## RESULTS

In a total of 603 DBE procedures, six patients (1%) developed post-DBE pancreatitis. Case summaries are presented in Table 1. Fifty percent of the patients (*n* = 3)



**Figure 1** A CT image of a 23-year old female, who developed post-DBE pancreatitis (case 5), showing an inflamed body-tail region, with edema and fatty infiltration (arrows).

was male. The mean age was 47.3 years (range 23-66). DBE was performed for the following indications: iron deficiency anemia (*n* = 3), Crohn's disease (*n* = 1), malabsorption (*n* = 1) and small bowel stenosis after bowel surgery (*n* = 1). The route of the procedure was oral in all 6 patients. In 67% (*n* = 4) the P-type endoscope (Fujinon EN-450P5) was used. The mean duration of the procedures was 108 min (80-148), the mean depth of insertion was 337 cm (250-420). In one patient, a polypectomy was performed.

All six patients developed clinical signs of pancreatitis within 6 h after the procedure. A scoring system to record the intensity of the pain in the patients was not maintained. The mean duration of admission was 11.2 d (2-22). The mean peak amylase and lipase levels were respectively 692 U/L (321-1395) and 1180 U/L (120-3660). Two patients developed moderately severe pancreatitis (case 1 and 6), and four had severe pancreatitis (case 2-5). In four patients, CT-scan was performed. Two of these patients showed inflammatory signs of the body-tail region of the pancreas with edema and fatty infiltration. One patient had pancreatitis in the tail of the pancreas and developed a pseudocyst during admission (case 3). In one patient, the whole pancreas was involved (Figures 1 and 2). Two patients had moderate clinical and laboratory signs of disease and could be discharged within a few days of admission. Therefore, CT imaging was not performed. One patient underwent laparotomy because postprocedural abdominal pain was suspected to be caused by perforation.

Table 2 Procedural characteristics

	Pancreatitis (n = 6)		No Pancreatitis (n = 597)		
Age (yr)	47.3	(23-66)	59.3	(12-94)	
Gender					
Male	3	(50%)	301	51.60%	
Female	3	(50%)	292	48.40%	
Route					
Oral	6	100%	435	73%	
Anal	0		162	26%	
Endoscope					
P-type	4	67%			
T-type	2	33%			
Duration (min)	108	(80-148)	105	(30-240)	
Insertion depth (cm)	337	(250-420)	270	(25-640)	P = 0.09
Midazolam (mg)	13.3	(10-15)	10	(2.5-25)	
Fentanyl (mg)	0.1	(0.05-0.15)	0.075	(0.025-0.2)	

However, during surgery, pancreatitis was diagnosed and no perforation was present. The other five patients were treated conservatively. There was no mortality in our series.

Table 2 shows clinical and procedural characteristics of the patients that developed acute pancreatitis in comparison with the patients that did not develop pancreatitis. All patients who developed post-DBE pancreatitis had undergone antegrade DBE. Depth of insertion was higher in the patients developing pancreatitis than in those who did not, although this difference did not reach statistical significance.

## DISCUSSION

In our series, post-DBE pancreatitis developed after six of 603 procedures (1%). This rate is higher than previously reported in the literature. A study by Heine *et al*, in which our center participated, identified 3 cases of post-DBE pancreatitis in a total of 275 procedures<sup>[22]</sup>. Two of those patients are also described in the present study. In a prospective multicenter study by Ell and colleagues, 100 patients were included and no pancreatitis occurred<sup>[23]</sup>. In a retrospective analysis of 378 DBE procedures by Zhong *et al* 2 patients suffered an unspecified rise of serum amylase in conjunction with abdominal pain, which resolved after conservative measures<sup>[24]</sup>. Whether these patients required hospitalization is not stated. The multicenter questionnaire survey by Mensink *et al* identified 6 cases of pancreatitis in 1728 diagnostic procedures (0.3%) and 1 case of pancreatitis after DBE-assisted ERCP in a patient with a Roux-en-Y reconstruction<sup>[16]</sup>. Several possibilities should be considered when trying to explain the difference between post-DBE pancreatitis rates in the present study and the previously published studies. First of all, the method of insertion and withdrawal might be a factor in the origin of post-DBE pancreatitis. However, we are not aware of any differences in technique between our center and other centers, while there is close contact and exchange of knowledge with many DBE-performing centers inside and outside The Netherlands. The fact that trained fellows under close supervision regularly perform DBE in our center, and that pancreatitis could be a consequence of relatively inexperienced endoscopists, is also an unlikely

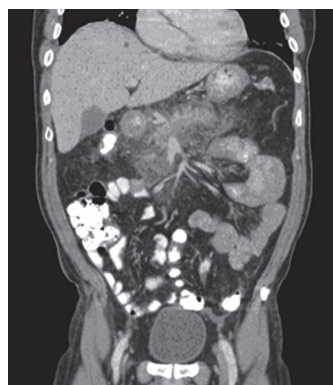

Figure 2 A transversal CT-image of a 54-year old male, who developed post-DBE pancreatitis (case 4), showing edema and fatty infiltration around the pancreas.

explanation since this would most certainly have been reflected in total procedure time, which was almost the same in patients developing pancreatitis and those who did not. Additionally, post-DBE pancreatitis did not occur more frequently after procedures performed by fellows. A third possible explanation could be an underestimation of post-DBE pancreatitis in previously published studies, as is evident in the study by Zhong, which reports two patients with abdominal pain and increased serum amylases without labeling these cases as pancreatitis<sup>[24]</sup>. Especially, retrospective questionnaire based surveys might be at risk from report or inclusion bias. Differences in definitions of post-procedural complications offer a likely explanation for the difference in reported post-DBE pancreatitis. Since we conducted a review of a recorded database prospectively, using predefined definitions of pancreatitis and its severity, the chance of report or inclusion bias seems lessened.

The pathogenesis of post-DBE pancreatitis is not known. Honda *et al* found asymptomatic hyperamylasemia in 5 of 13 patients after antegrade DBE. One of 13 patients developed pancreatitis<sup>[25]</sup>. Several mechanisms could be responsible for the development of hyperamylasemia or pancreatitis. First, the repetitive mechanical strain on the pancreas, by inserting the endoscope/overtube, by inflated balloons or by stretching movements, could induce pancreatitis, especially by traction at the ligament of Treitz. This hypothesis is supported by the finding that in most cases in which an early CT scan was performed, pancreatitis was located in the tail or body/tail region of the pancreas. As in the study by Mensink *et al*, no significant association between the use of the T-endoscope and the occurrence of pancreatitis was present. This strain-hypothesis is also suggested by our finding that insertion depth (and therefore the number of advancing and stretching movements of both endoscope and overtube) seems higher in the pancreatitis group ( $P = 0.9$ , Table 2). A second explanation could be duodenal hypertension due to air trapping between the overtube balloon and the pylorus, which in theory could interfere with pancreatic drainage. In fact, a closed duodenal loop is an established animal model for acute pancreatitis<sup>[26-29]</sup>. As far as we know, data that could prove this theory do not exist and our finding that procedure time (and therefore the time the supposed duodenal hypertension would have existed) was not different between the groups is not supportive of this theory. Impaired pancreatic drainage



due to temporary obstruction of the papilla could not have resulted in pancreatitis in our series, since we inflate the balloons after Treitz's ligament has been passed.

To our knowledge no cases of pancreatitis have been reported after retrograde DBE-procedures, therefore it is highly unlikely that medications used for sedation could have played an important role. We also noted that all the females that developed post-DBE pancreatitis were premenopausal. However, this series is too small to identify patient-related risk factors. It is therefore unknown whether patient characteristics associated with post-ERCP pancreatitis (like sphincter of Oddi dysfunction, young age or female gender) are also associated with the occurrence of post-DBE pancreatitis<sup>[30]</sup>. Larger, prospective multicenter studies are needed to investigate operator-dependent factors and to identify additional patient-related risk factors that could explain why some patients develop only transient hyperamylasemia and others severe pancreatitis. Such studies should include early pancreatic imaging. Anatomical and imaging studies on the effect of DBE on the position of the pancreas and proximal duodenum are necessary to investigate the validity of the pancreatic strain and the duodenal hypertension hypotheses.

Although post-DBE pancreatitis is relatively uncommon, it is the most important complication of antegrade, diagnostic DBE. It is of major importance to consider pancreatitis as a cause of post procedural abdominal pain, to avoid unnecessary surgical exploration as has been the case in one of our patients. Abdominal pain after DBE warrants additional investigation. Since hyperamylasemia is quite common after DBE and not discriminative for DBE pancreatitis, the diagnosis should be based on clinical findings and or radiological imaging techniques.

## COMMENTS

### Background

Double balloon endoscopy (DBE) was introduced by Yamamoto in 2001. This endoscopic technique allows (intervention) endoscopy of the small bowel. Post DBE pancreatitis is a well known complication after antegrade DBE.

### Research frontiers

This article describes the cases of post DBE pancreatitis in the largest single center series of DBE procedures to date.

### Related publications

Honda *et al* showed that an asymptomatic rise of serum amylase and lipase levels after antegrade DBE occurs frequently. Nevertheless, previous studies indicate that post DBE pancreatitis occurs seldom.

### Innovations and breakthroughs

The pathophysiology behind the occurrence of post DBE pancreatitis largely remains unknown. Only a few reports on this subject have been published. Studies to determine the pathogenesis are currently performed in our center.

### Applications

The investigation post DBE pancreatitis will help us to determine the pathogenesis of this complication, to define high risk groups, and thus to prevent post DBE pancreatitis.

### Terminology

DBE is an endoscopic technique that allows access to the complete small intestine for diagnostic and therapeutics procedures.

## Peer review

It is a good manuscript reporting six cases of DBE-associated pancreatitis.

## REFERENCES

- 1 Yamamoto H, Sekine Y, Sato Y, Higashizawa T, Miyata T, Iino S, Ido K, Sugano K. Total enteroscopy with a nonsurgical steerable double-balloon method. *Gastrointest Endosc* 2001; **53**: 216-220
- 2 Tanaka S, Mitsui K, Tatsuguchi A, Kobayashi T, Ehara A, Gudis K, Sakamoto C. Current status of double balloon endoscopy--indications, insertion route, sedation, complications, technical matters. *Gastrointest Endosc* 2007; **66**: S30-S33
- 3 Concha R, Amaro R, Barkin JS. Obscure gastrointestinal bleeding: diagnostic and therapeutic approach. *J Clin Gastroenterol* 2007; **41**: 242-251
- 4 Fujimori S, Seo T, Gudis K, Tanaka S, Mitsui K, Kobayashi T, Ehara A, Yonezawa M, Tatsuguchi A, Sakamoto C. Diagnosis and treatment of obscure gastrointestinal bleeding using combined capsule endoscopy and double balloon endoscopy: 1-year follow-up study. *Endoscopy* 2007; **39**: 1053-1058
- 5 Kaffes AJ, Siah C, Koo JH. Clinical outcomes after double-balloon enteroscopy in patients with obscure GI bleeding and a positive capsule endoscopy. *Gastrointest Endosc* 2007; **66**: 304-309
- 6 Ohmiya N, Yano T, Yamamoto H, Arakawa D, Nakamura M, Honda W, Itoh A, Hirooka Y, Niwa Y, Maeda O, Ando T, Yao T, Matsui T, Iida M, Tanaka S, Chiba T, Sakamoto C, Sugano K, Goto H. Diagnosis and treatment of obscure GI bleeding at double balloon endoscopy. *Gastrointest Endosc* 2007; **66**: S72-S77
- 7 Chang DK, Kim JJ, Choi H, Eun CS, Han DS, Byeon JS, Kim JO. Double balloon endoscopy in small intestinal Crohn's disease and other inflammatory diseases such as cryptogenic multifocal ulcerous stenosing enteritis (CMUSE). *Gastrointest Endosc* 2007; **66**: S96-S98
- 8 Fukumoto A, Tanaka S, Yamamoto H, Yao T, Matsui T, Iida M, Goto H, Sakamoto C, Chiba T, Sugano K. Diagnosis and treatment of small-bowel stricture by double balloon endoscopy. *Gastrointest Endosc* 2007; **66**: S108-S112
- 9 Gay G, Delvaux M. Double balloon enteroscopy in Crohn's disease and related disorders: our experience. *Gastrointest Endosc* 2007; **66**: S82-S90
- 10 Semrad CE. Role of double balloon enteroscopy in Crohn's disease. *Gastrointest Endosc* 2007; **66**: S94-S95
- 11 Cichoz-Lach H, Celiński K. Modern methods of endoscopic diagnosis of gastrointestinal tract. *J Physiol Pharmacol* 2007; **58** Suppl 3: 21-31
- 12 Hadithi M, Al-toma A, Oudejans J, van Bodegraven AA, Mulder CJ, Jacobs M. The value of double-balloon enteroscopy in patients with refractory celiac disease. *Am J Gastroenterol* 2007; **102**: 987-996
- 13 Monkemuller K, Fry LC, Ebert M, Bellutti M, Venerito M, Knippig C, Rickes S, Muschke P, Rocken C, Malfertheiner P. Feasibility of double-balloon enteroscopy-assisted chromoendoscopy of the small bowel in patients with familial adenomatous polyposis. *Endoscopy* 2007; **39**: 52-57
- 14 May A, Nachbar L, Pohl J, Ell C. Endoscopic interventions in the small bowel using double balloon enteroscopy: feasibility and limitations. *Am J Gastroenterol* 2007; **102**: 527-535
- 15 May A, Ell C. Push-and-pull enteroscopy using the double-balloon technique/double-balloon enteroscopy. *Dig Liver Dis* 2006; **38**: 932-938
- 16 Mensink PB, Haringsma J, Kucharzik T, Cellier C, Perez-Cuadrado E, Monkemuller K, Gasbarrini A, Kaffes AJ, Nakamura K, Yen HH, Yamamoto H. Complications of double balloon enteroscopy: a multicenter survey. *Endoscopy* 2007; **39**: 613-615
- 17 Cazzato IA, Cammarota G, Nista EC, Cesaro P, Sparano L, Bonomo V, Gasbarrini GB, Gasbarrini A. Diagnostic and therapeutic impact of double-balloon enteroscopy (DBE) in a

- series of 100 patients with suspected small bowel diseases. *Dig Liver Dis* 2007; **39**: 483-487
- 18 **Monkemuller K**, Weigt J, Treiber G, Kolfenbach S, Kahl S, Rocken C, Ebert M, Fry LC, Malfertheiner P. Diagnostic and therapeutic impact of double-balloon enteroscopy. *Endoscopy* 2006; **38**: 67-72
- 19 **Groenen MJ**, Moreels TG, Orlent H, Haringsma J, Kuipers EJ. Acute pancreatitis after double-balloon enteroscopy: an old pathogenetic theory revisited as a result of using a new endoscopic tool. *Endoscopy* 2006; **38**: 82-85
- 20 **May A**, Nachbar L, Ell C. Double-balloon enteroscopy (push-and-pull enteroscopy) of the small bowel: feasibility and diagnostic and therapeutic yield in patients with suspected small bowel disease. *Gastrointest Endosc* 2005; **62**: 62-70
- 21 **Mallery JS**, Baron TH, Dominitz JA, Goldstein JL, Hirota WK, Jacobson BC, Leighton JA, Raddawi HM, Varg JJ 2nd, Waring JP, Fanelli RD, Wheeler-Harbough J, Eisen GM, Faigel DO. Complications of ERCP. *Gastrointest Endosc* 2003; **57**: 633-638
- 22 **Heine GD**, Hadithi M, Groenen MJ, Kuipers EJ, Jacobs MA, Mulder CJ. Double-balloon enteroscopy: indications, diagnostic yield, and complications in a series of 275 patients with suspected small-bowel disease. *Endoscopy* 2006; **38**: 42-48
- 23 **Ell C**, May A, Nachbar L, Cellier C, Landi B, di Caro S, Gasbarrini A. Push-and-pull enteroscopy in the small bowel using the double-balloon technique: results of a prospective European multicenter study. *Endoscopy* 2005; **37**: 613-616
- 24 **Zhong J**, Ma T, Zhang C, Sun B, Chen S, Cao Y, Wu Y. A retrospective study of the application on double-balloon enteroscopy in 378 patients with suspected small-bowel diseases. *Endoscopy* 2007; **39**: 208-215
- 25 **Honda K**, Itaba S, Mizutani T, Sumida Y, Kanayama K, Higuchi N, Yoshinaga S, Akiho H, Kawabe K, Arita Y, Ito T, Nakamura K, Takayanagi R. An increase in the serum amylase level in patients after peroral double-balloon enteroscopy: an association with the development of pancreatitis. *Endoscopy* 2006; **38**: 1040-1043
- 26 **Nevalainen TJ**, Seppa A. Acute pancreatitis caused by closed duodenal loop in the rat. *Scand J Gastroenterol* 1975; **10**: 521-527
- 27 **Chetty U**, Gilmour HM, Taylor TV. Experimental acute pancreatitis in the rat--a new model. *Gut* 1980; **21**: 115-117
- 28 **Ferrie MM**, O'Hare R, Joffe SN. Acute and chronic pancreatitis in the rat caused by a closed duodenal loop. *Digestion* 1978; **18**: 280-285
- 29 **Rao SS**, Watt IA, Donaldson LA, Crockett A, Joffe SN. A serial histologic study of the development and progression of acute pancreatitis in the rat. *Am J Pathol* 1981; **103**: 39-46
- 30 **Freeman ML**, Guda NM. Prevention of post-ERCP pancreatitis: a comprehensive review. *Gastrointest Endosc* 2004; **59**: 845-864

S- Editor Piscaglia AC L- Editor Lutze M E- Editor Ma WH