

Effectiveness of preoperative planning in the restoration of balance and view in ankylosing spondylitis

ROY R. PIGGE, B.Sc.(MED),¹ FAMKE J. SCHEERDER, M.D.,¹ THEO H. SMIT, PH.D.,²
MARGRIET G. MULLENDER, PH.D.,¹ AND BAREND J. VAN ROYEN, M.D., PH.D.¹

Departments of ¹Orthopaedic Surgery and ²Physics and Medical Technology, VU University Medical Centre, Amsterdam, The Netherlands

Object. The object of this study was to assess the effectiveness of preoperative planning in the restoration of balance and view angle in patients treated with lumbar osteotomy in ankylosing spondylitis (AS).

Methods. The authors prospectively analyzed 8 patients with a thoracolumbar kyphotic deformity due to AS that was treated using a closing wedge osteotomy (CWO) of the lumbar spine to correct sagittal imbalance and horizontal view. Preoperative planning to predict postoperative balance, defined by the sagittal vertical axis (SVA) and the sacral endplate angle (SEA), and the view angle, defined by the chin-brow to vertical angle (CBVA), was performed using the ASKypoplan computational program.

Results. All patients were treated with a CWO at level L-4 and improved in balance and view angle. The mean correction angle was 35° (range 24–47°). The postoperative SEA improved from 21 to 36° for a mean correction of 15°. In addition, the SVA and CBVA improved significantly. Note, however, that the postoperative results did not exactly reflect the predicted values of the analyzed parameters.

Conclusions. Preoperative planning for the restoration of balance and view angle in AS improves understanding of the biomechanical and clinical effects of a correction osteotomy of the lumbar spine. The adaptation of basic clinical and biomechanical principles to restore balance is advised in such a way that the individual SEA is corrected by 15° (maximum 40°) in relation to the horizon and C-7 is balanced exactly above the posterosuperior corner of the sacrum. (DOI: 10.3171/FOC/2008/24/1/E7)

KEY WORDS • ankylosing spondylitis • lumbar spine • osteotomy • surgical planning

DESPITE adequate conservative treatment, AS can lead to severe fixed TLKD of the spine. Such fixed spinal kyphosis can cause severe impairment in the quality of life. Patients with this pathophysiology describe a constant feeling of leaning forward, which frequently results in pain and fatigue in the spine as well as the thighs and buttocks, given that the muscles are under constant strain from trying to maintain an erect posture. In addition, pulmonary function decreases because the rigidity of the thoracic cage prevents chest expansion and because diaphragmatic respiration declines due to compression of the abdominal viscera by the inferior margin of the rib cage. The chief symptom, however, is an inability to look straight ahead to the horizon, which restricts many of the patient's daily activities, for example, interpersonal com-

munication, walking on the street, or driving a car. Occasionally, psychosocial aspects play a role too; patients tend to feel socially unaccepted and are troubled by their appearance.

Corrective osteotomy of the spine can be considered in these patients. The goal of such a surgical procedure is to restore the patient's capacity to see the horizon, view angle, and sagittal balance of the ankylosed spine so that the legs remain straight during normal standing and so that little muscular effort is needed to balance the spine. Generally, a CWO of the lumbar spine is performed to correct the TLKD in patients with AS. This procedure has been used in clinical practice for ≥ 60 years, and its value in correcting the spinal deformity in AS has been well established.^{1,3,8,10}

The effect of a spinal osteotomy on balance and the view angle depends on both the correction angle and the level at which the osteotomy is performed. Adequate planning is advised to predict the effect of a lumbar osteotomy on sagittal balance and the view angle. In an effort to predict the clinical outcome of a lumbar osteotomy, several methods of preoperative planning have been described.^{4,5,6,11,14} Recently, we developed a biomechanical and mathematical

Abbreviations used in this paper: AS = ankylosing spondylitis; CBVA = chin-brow to vertical angle; CWO = closing-wedge osteotomy; PSCS = posterosuperior corner of the sacrum; SEA = sacral endplate angle; SVA = sagittal vertical axis; SVA(SEA 40) = SVA with the SEA corrected 40° to the horizon; TLKD = thoracolumbar kyphotic deformity.

procedure for planning sagittal plane corrective osteotomies in AS. Subsequently, we introduced the ASKyphoplan computational program, which was based on these biomechanical and mathematical principles and was easily applied in daily practice.¹² The ASKyphoplan computer program is free for use at www.stega.nl (subheading "Research").

The clinical utility and effectiveness of preoperative planning in patients treated with spinal osteotomy for an AS-related TLKD has never been reported, and thus we undertook a prospective cohort study to analyze the efficacy of preoperative planning in the restoration of sagittal balance and view angle following a lumbar CWO.

Parameters for Balance and the View Angle

The sagittal balance of a patient with a TLKD caused by AS is defined by the position of the spine in relation to the neutral position of the pelvis. The position of the pelvis in the gravitational field is expressed in terms of pelvic tilt, sacral slope, or SEA. In healthy individuals, the SEA is on the order of 40°. In patients with an AS-induced severe TLKD, however, this angle is acutely decreased as a result of a compensation maneuver in the lower extremities. The pelvic tilt or SEA in such patients is reduced by extension of the hips and flexion of the knees and ankles, and thus is a direct indication of an unbalanced spine. Therefore, in planning an osteotomy, it is most practical to start from a well-balanced position of the pelvis, that is, with an SEA of 40°. The position of the spine in patients with AS is expressed by the SVA, which is defined as the distance between the plumb line from the C-7 vertebral body and the PSCS (in mm). To express uncompensated balance of the spine, the SVA is measured after correcting the SEA to 40° in relation to the horizon, that is, SVA(SEA 40). To prevent overcorrection, we hypothesized that the optimal postoperative SVA in a patient with AS lies between 50 and 100 mm anterior to S-1.¹¹

The view angle is defined by the CBVA, which is the angle between the vertical reference line and a line parallel to the chin and brow of the patient while he or she stands in a relaxed position with hips and knees extended. In patients with a severe TLKD caused by AS, the CBVA is increased. Functional restoration of the CBVA to as close to normal as possible is of the utmost importance. Given that a spinal osteotomy alters both the CBVA and sagittal balance, overcorrection of the CBVA following a spinal osteotomy should be prevented.⁷ Overcorrection in patients with a TLKD caused by AS has been defined as a CBVA < -10°.⁹

Clinical Material and Methods

We prospectively analyzed a cohort of eight patients (7 men and 1 woman) with a severe TLKD due to AS and undergoing a CWO of the lumbar spine for correction of sagittal imbalance and horizontal view. The mean age at the time of the operation was 40 years (range 28–51 years). The indications for surgery were a severe ankylosed TLKD, an inability to look straight ahead, and progressive thoracolumbar pain and fatigue. All patients had problems with daily activities and social life. None of the patients had secondary arthritis or subsequent flexion contractures of

the hip joints. Patients who had undergone revision operations were excluded from this study. The entire surgical procedure, including patient positioning, anesthesia, and surgery, was performed according to a technique described previously.¹³

Preoperative surgical planning was performed with the ASKyphoplan computational program in all patients.¹² The principles, a description, and the practical implications of the program have been reported recently. By using this program, we can calculate the preferred level of osteotomy and the amount of correction that can be achieved with a CWO in relation to the SVA and CBVA correction. The radiograph was rotated until the hypothetically ideal SEA was 40° to the horizon (SVA[SEA 40]).

Preoperative clinical photographs were obtained to evaluate the CBVA. A standard full-length radiograph of the whole spine was obtained while the patient remained standing in a relaxed position. The center of the body of C-7, the PSCS, and the SEA were marked on the radiograph. In addition, the 50-mm grid of the film was measured and marked for calibration. The marked radiograph was saved in a JPEG format for each patient, making it possible to upload the radiograph into the ASKyphoplan program.

A postoperative full-length radiograph of the whole spine and radiographs of the lumbar spine were obtained to measure the correction angle achieved and to reevaluate each patient's balance as expressed by the SEA and SVA (SEA 40). The correction angle was measured in degrees by calculating the Cobb angle between the upper and lower endplate of the surgically treated vertebral body. Postoperative clinical photographs were obtained to measure and evaluate each patient's CBVA.

Results

Preoperative Data

The preoperative data for all the patients are shown in Table 1. Preoperatively, the mean SEA was 21° (range 14–36°), the mean compensated SVA was 164 mm (range 67–273 mm), the mean uncompensated SVA(SEA 40) was 300 mm (range 161–387 mm), and the mean CBVA was 35° (range 11–64°).

Preoperative Planning

A posterior-based CWO at level L-4 was planned in all patients. The ideal SEA was defined at 40°. In the first 3

TABLE 1

Summary of preoperative values in 8 patients with an AS-induced TLKD

Case No.	SEA (°)	SVA (mm)	SVA(SEA 40) in mm	CBVA (°)
1	26	136	254	11
2	17	156	325	64
3	36	130	161	22
4	14	67	267	30
5	21	244	356	47
6	24	273	364	27
7	14	190	387	63
8	15	116	287	15

Preoperative planning in ankylosing spondylitis

TABLE 2

Summary of preoperative planning data in 8 patients with AS*

Case No.	Predicted SVA (SEA 40) in mm	Correction Angle (°)	Predicted CBVA Correction (°)
1	24	30	3
2	89	35	9
3	28	20	14
4	75	29	9
5	75	49	29
6	75	50	33
7	75	43	17
8	75	36	10

* In all patients the level of the osteotomy was L-4 and the SEA was 40°.

patients surgical plans were made according to the operation angle that would lead to an optimal correction of the CBVA and SVA. Calculations were based on a desirable correction that would not induce overcorrection of the view angle (CBVA; Table 2). Plans were made in the last 5 patients according to a predicted postoperative SVA of 75 mm. Calculations in these cases were based on the hypothetically desirable postoperative SVA that would lead to an achievable correction angle but not overcorrection of the CBVA (Fig. 1).¹¹

TABLE 3

Postoperative results in 8 patients who underwent spinal osteotomy for TLKD

Case No.	Correc-tion (°)	SEA (°)	SVA (mm)	SVA(SEA 40) in mm	CBVA (°)
1	33	44	54	21	3
2	27	32	7	73	-6
3	24	55	29	-96	12
4	36	32	-25	40	19
5	47	34	58	104	26
6	43	42	119	106	6
7	40	24	0	152	27
8	34	22	10	146	-3

Postoperative Results

The results following surgery are shown in Table 3. There were no complications during surgery or follow-up treatment. In all patients we were able to achieve a correction within a range of -8-7° of the planned correction angle. The mean correction angle was 35° (range 24-47°).

In all patients, balance and the view angle improved clinically. The mean postoperative SEA improved from 21 to 36° (range 22-55°) with a mean correction of 15°. Postoperative balance, expressed by SVA(SEA 40), improved

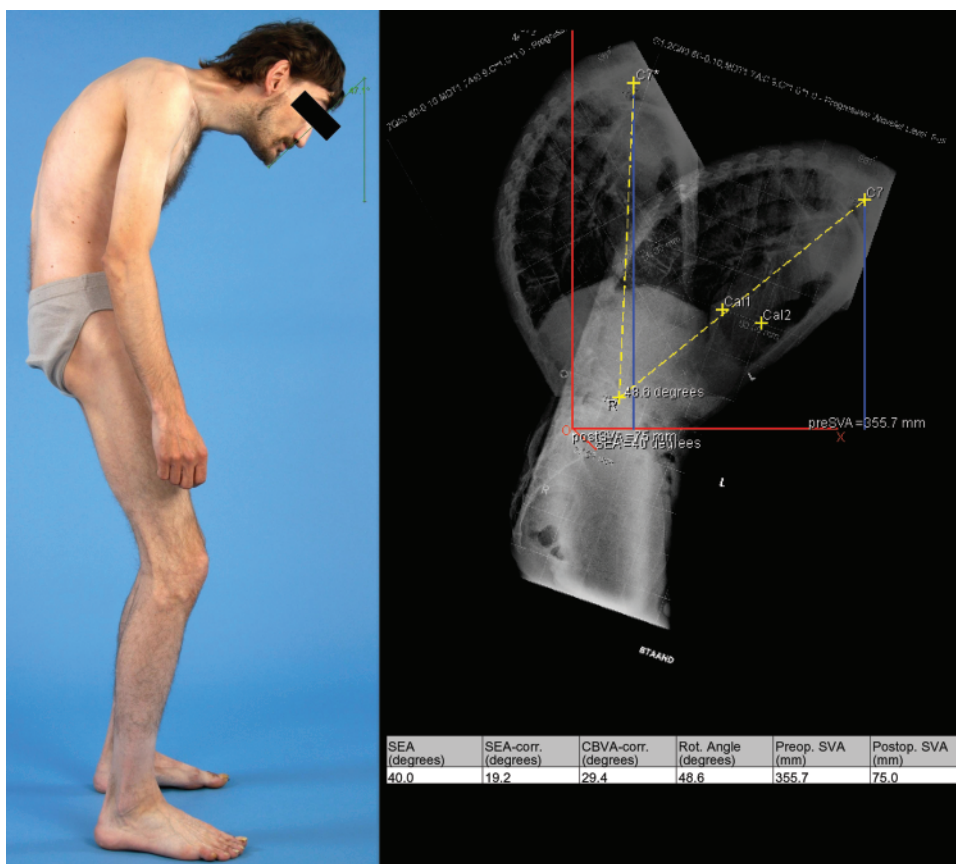


FIG. 1. Case 5. A: Preoperative photograph depicting the patient's clinical appearance. B: Preoperative ASKyplo-plan report showing preoperative parameters: CBVA of 47°, SEA of 21°, and SVA of 244 mm. Rotation of the radiograph onto the coordinate system with the SEA at 40° results in an SVA(SEA 40) of 356 mm. A 49° osteotomy at L-4 predicts the postoperative SVA(SEA 40) of 75 mm. The predicted CBVA correction is 29°.

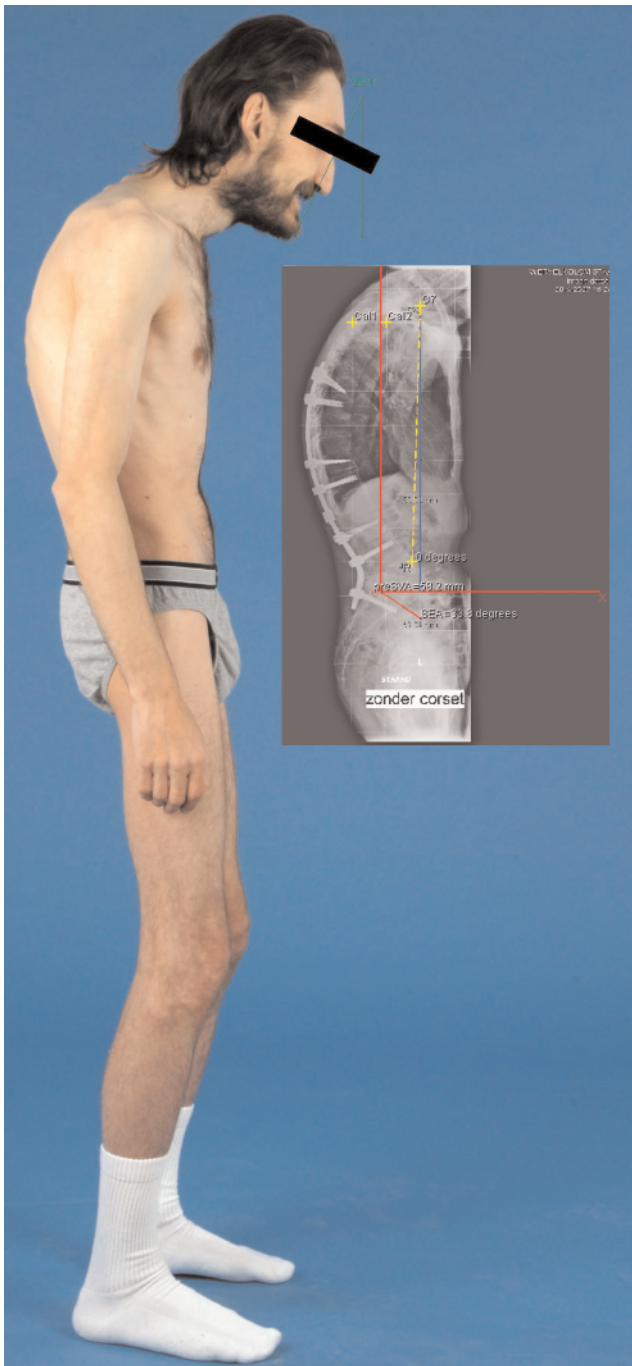


FIG. 2. Case 5. Photograph illustrating the patient's clinical appearance following the CWO. *Inset:* Final ASKyphoplan report showing postoperative parameters. Postoperative radiograph of the lumbar spine showed a correction of 47° in L-4. Postoperative full-length lateral radiograph of the whole spine showed an SEA of 34° and SVA of 58 mm. The postoperative SVA(SEA 40) with the SEA rotated at 40° was 104 mm. The clinical postoperative CBVA was 26°.

by 232 mm from 300 to 68 mm (range -96–152 mm). However, the postoperative SVA(SEA 40) differed considerably from the predicted SVA(SEA 40) in all patients in whom plans had been made according to a predicted post-

operative SVA of 75 mm. Moreover, in 1 patient (Case 3) in whom plans had been made according to the operation angle that would lead to an optimal correction of the CBVA and SVA, the postoperative SVA(SEA 40) differed considerably from the predicted value.

The mean postoperative CBVA improved by 24°, from 35 to 11° (range -6–26°). Note, however, that the CBVA achieved postoperatively did not correlate with the planned CBVA correction (Fig. 2).

Discussion

Although adequate preoperative planning for sagittal plane corrective osteotomies of the spine in AS appears essential to reliably predicting the effect of surgical correction on the restoration of balance and view, the effectiveness of this step has not been reported. We prospectively analyzed data in a cohort of patients who had undergone planning and treatment for sagittal plane corrective osteotomies according to our recently described method of visualizing the relationship between the osteotomy angle and the level of osteotomy in connection to sagittal balance and CBVA.^{11,12}

The postoperative results in this cohort showed that the use of the ASKyphoplan computational program for preoperative planning increases our understanding of the biomechanical and clinical effects of a lumbar spine correction osteotomy on the restoration of balance and view in patients with a rigid TLKD caused by AS. Balance and view angle improved in all patients. There was no overcorrection of the view angle, expressed by the CBVA, and the balance expressed by the SVA(SEA 40) improved in all cases.

Unfortunately, the postoperative results in this cohort did not exactly match the predicted values of the analyzed parameters. Can the different results be explained by the planning procedure itself? The explanation may be less obvious and is related to the difficulties encountered clinically and biomechanically. First, in the process of preoperative planning it is important to determine both how much correction is desirable and how much is achievable. The amount of correction that can be achieved in the sagittal plane by performing a posterior-based osteotomy is limited by the size of the closing wedge that can be safely created in the lumbar spine and then closed with modern pedicle fixation devices. Second, the ideal position of the pelvis in the gravitational field, expressed by the SEA as a parameter for balance in AS, may differ from that in healthy individuals. In healthy volunteers, the SEA makes an angle of ~ 40° with the horizon on a standing lateral radiographic projection.^{2,11} However, should patients with an AS-induced rigid TLKD undergo correction to this assumed normal angle? We showed that the average postoperative SEA improved from 21 to 36° (range 22–55°), for a mean correction of 15°. An increase in the SEA as a parameter of the correction of balance has also been demonstrated in 2 recent papers.^{4,6} In the study by Min et al.⁴ the mean postoperative SEA was 31.8° with a mean correction of 20°, and in the study by Ruf et al.⁶ the mean postoperative SEA was 40° with a mean correction of 17°. Third, balance expressed by the SVA(SEA 40) is measured by calculating the horizontal distance between the plumb line from C-7 and the PSCS with the SEA rotated 40° to the horizon. However, the optimum postoperative SVA(SEA 40) in

Preoperative planning in ankylosing spondylitis

patients with TLKD due to AS is not known. We hypothesized that the postoperative SVA(SEA 40) from C-7 should be between 50 and 100 mm anterior to the PSCS to prevent overcorrection of the ankylosed TLKD in AS.¹¹ For that reason, a postoperative SVA of 75 mm was planned in our cases. Realize, however, that many parameters—height of the patient, thoracic and abdominal girth, posture, and position of the head and arms—influences balance in patients with AS.

Current data suggest that some principal clinical and biomechanical assumptions must be reconsidered in patients with a rigid TLKD caused by AS. Integration of the current data with the aforementioned biomechanical principles for planning in AS leads to the conclusion that a relative increase of 15° in the SEA, up to a maximum of 40°, may be preferable in patients with a rigid TLKD caused by AS. In addition, balancing the spine by defining the SVA in C-7 exactly above the PSCS excludes differences in height, posture, thoracic and abdominal girth, and position of the head and arms. Given our small study group, the effect of this new hypothesis should be analyzed in further studies.

Conclusions

Preoperative planning increases understanding of the biomechanical and clinical effects of a lumbar spine correction osteotomy on the restoration of balance and view in patients with AS. By using preoperative clinical assumptions in the ASKyphoplan computer program, the predicted values of balance and view angle could not be achieved after surgery. Hence, the clinical and biomechanical principles in patients with a severe TLKD caused by AS cannot be extrapolated to normal sagittal spinal values. Therefore, we advise planning the level of osteotomy and the degrees of correction in such a way that the SEA is corrected by 15° (maximum 40°) to the horizon and balancing C-7 exactly above the PSCS.

References

1. Chen IH, Chien JT, Yu TC: Transpedicular wedge osteotomy for correction of thoracolumbar kyphosis in ankylosing spondylitis: experience with 78 patients. **Spine** **26**: E354–E360, 2001
2. Jackson RP, Peterson MD, McManus AC, Hales C: Compensatory spinopelvic balance over the hip axis and better reliability in measuring lordosis to the pelvic radius on standing lateral radiographs of adult volunteers and patients. **Spine** **23**: 1750–1767, 1998
3. La Chapelle EH: Osteotomy of the lumbar spine for correction of kyphosis in a case of ankylosing spondylarthritis. **J Bone Joint Surg Am** **28**:851–858, 1946
4. Min K, Hahn F, Leonardi M: Lumbar spinal osteotomy for kyphosis in ankylosing spondylitis: the significance of the whole body kyphosis angle. **J Spinal Disord Tech** **20**:149–153, 2007
5. Ondra SL, Marzouk S, Koski T, Silva F, Salehi S: Mathematical calculation of pedicle subtraction osteotomy size to allow precision correction of fixed sagittal deformity. **Spine** **31**:E973–E979, 2006
6. Ruf M, Wagner R, Merk H, Harms J: [Preoperative planning and computer assisted surgery in ankylosing spondylitis.] **Z Orthop Ihre Grenzgeb** **144**:52–57, 2006 (Ger)
7. Sengupta DK, Khazim R, Grevitt MP, Webb JK: Flexion osteotomy of the cervical spine: a new technique for correction of iatrogenic extension deformity in ankylosing spondylitis. **Spine** **26**:1068–1072, 2001
8. Smith-Petersen MN, Larson CB, Aufranc OE: Osteotomy of the spine for correction of flexion deformity in rheumatoid arthritis. **Clin Orthop Relat Res** **66**:6–9, 1969
9. Suk KS, Kim KT, Lee SH, Kim JM: Significance of chin-brow vertical angle in correction of kyphotic deformity of ankylosing spondylitis patients. **Spine** **28**:2001–2005, 2003
10. van Royen BJ, De Gast A: Lumbar osteotomy for correction of thoracolumbar kyphotic deformity in ankylosing spondylitis. A structured review of three methods of treatment. **Ann Rheum Dis** **58**:399–406, 1999
11. van Royen BJ, De Gast A, Smit TH: Deformity planning for sagittal plane corrective osteotomies of the spine in ankylosing spondylitis. **Eur Spine J** **9**:492–498, 2000
12. van Royen BJ, Scheerder FJ, Jansen E, Smit TH: ASKyphoplan: a program for deformity planning in ankylosing spondylitis. **Eur Spine J** **16**:1445–1449, 2007
13. van Royen BJ, Slot GH: Closing-wedge posterior osteotomy for ankylosing spondylitis. Partial corporectomy and transpedicular fixation in 22 cases. **J Bone Joint Surg Br** **77**:117–121, 1995
14. Yang BP, Ondra SL: A method for calculating the exact angle required during pedicle subtraction osteotomy for fixed sagittal deformity: comparison with the trigonometric method. **Neurosurgery** **59**:ONS458–ONS463, 2006

Manuscript submitted October 12, 2007

Accepted November 6, 2007.

Address correspondence to: B. J. van Royen, M.D., Ph.D., Department of Orthopaedic Surgery, VU University Medical Centre, De Boelelaan, 1117 1081 HV Amsterdam, The Netherlands. email: bj.vanroyen@vumc.nl.