

Spaceflight Associated Neuro-ocular Syndrome (SANS)

Michael B. Stenger, Ph.D.


HHC Discipline Scientist

Manager, Cardiovascular & Vision Laboratory

Biomedical Sciences and Environmental Research Division (SK3)

Deep Space Gateway Symposium

4 Dec 2017



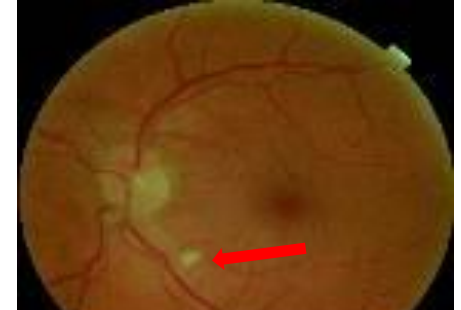History

Hyperopic Shifts

-Up to +1.75 diopters



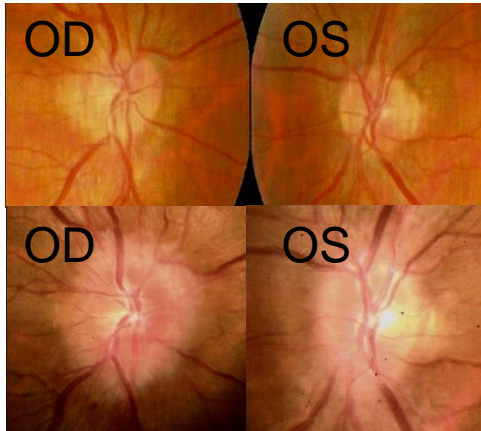
"Cotton wool" spots



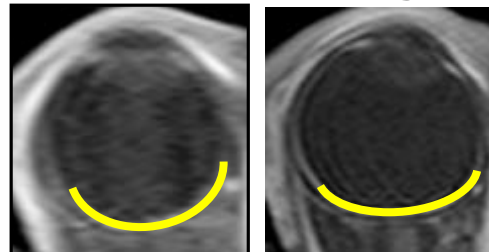
Risk: Visual Impairment/Intracranial Pressure (VIIP)



Optic Disc Edema (swelling)



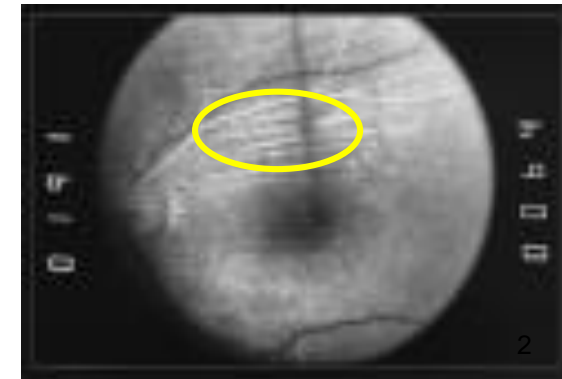Globe Flattening



Normal Globe

Flatten Globe

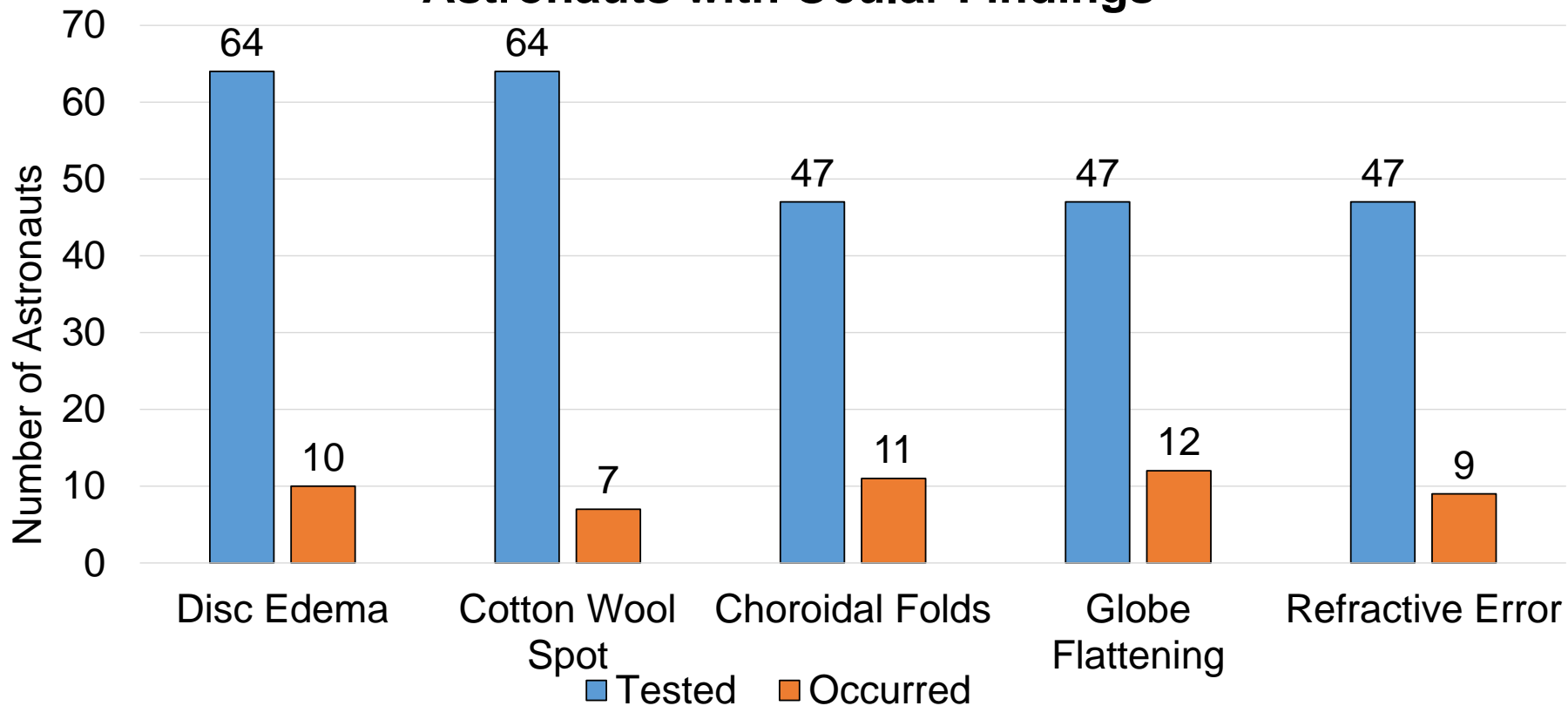
Choroidal Folds






Ocular Findings through 2016*

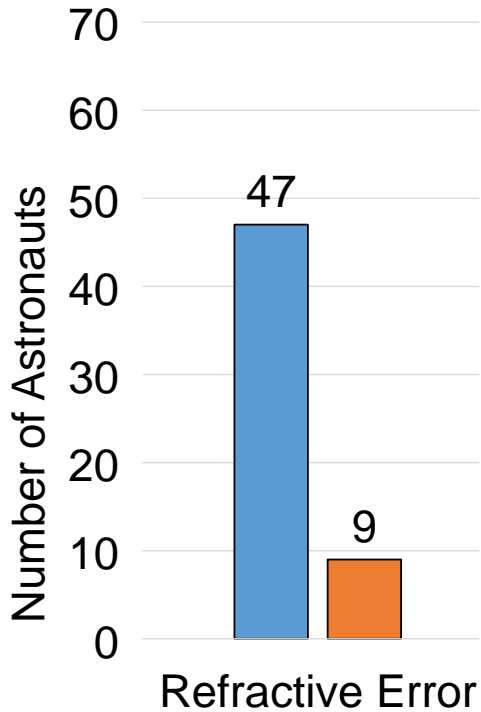
Astronauts with Ocular Findings



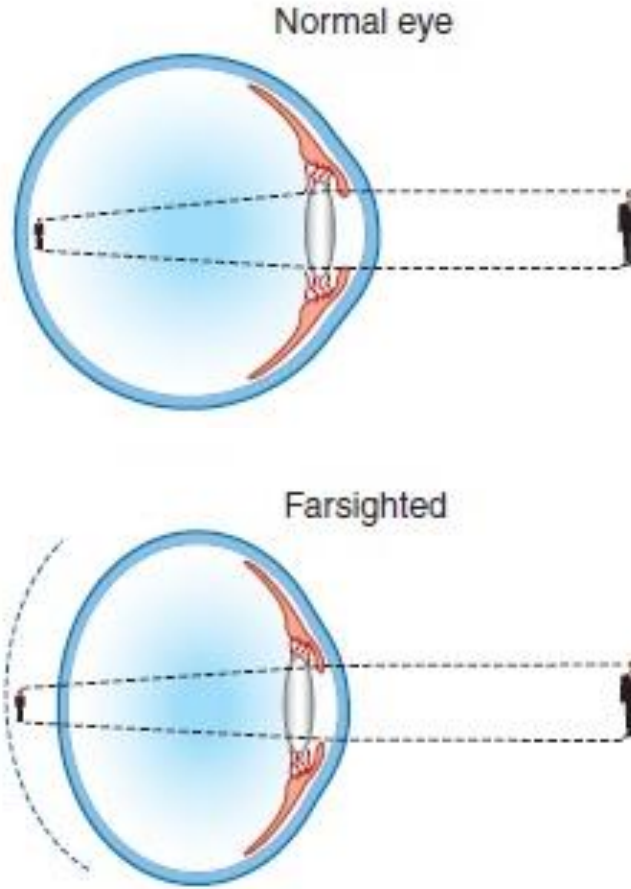
*USOS astronauts only 3



Refractive Error



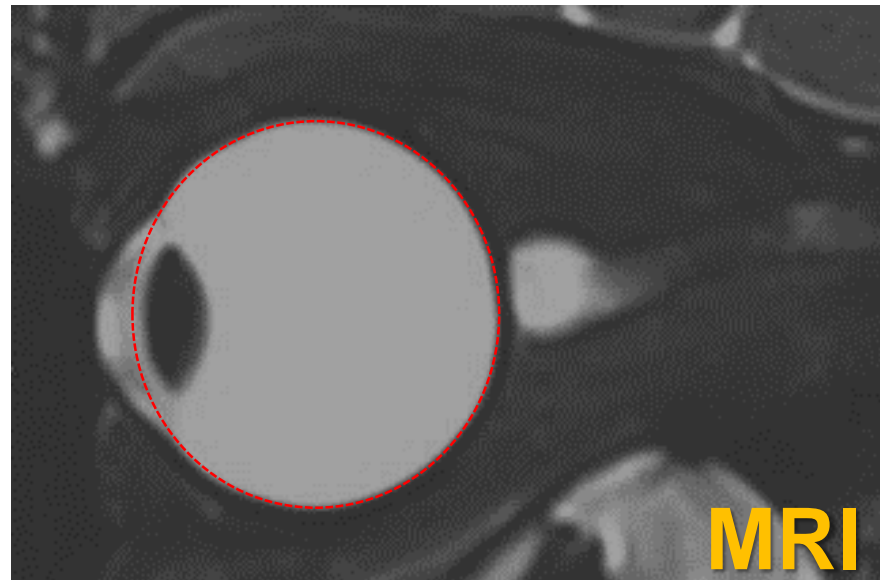
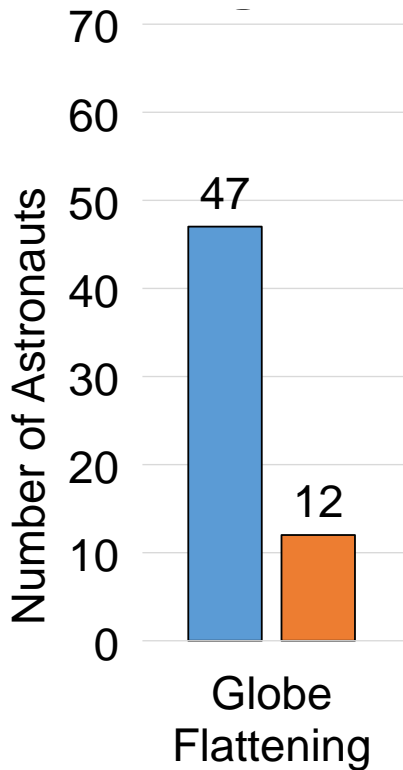
Change $\geq 0.75D$






Globe Flattening

Terrestrially: Globe flattening is associated with disc edema resulting from intracranial hypertension.



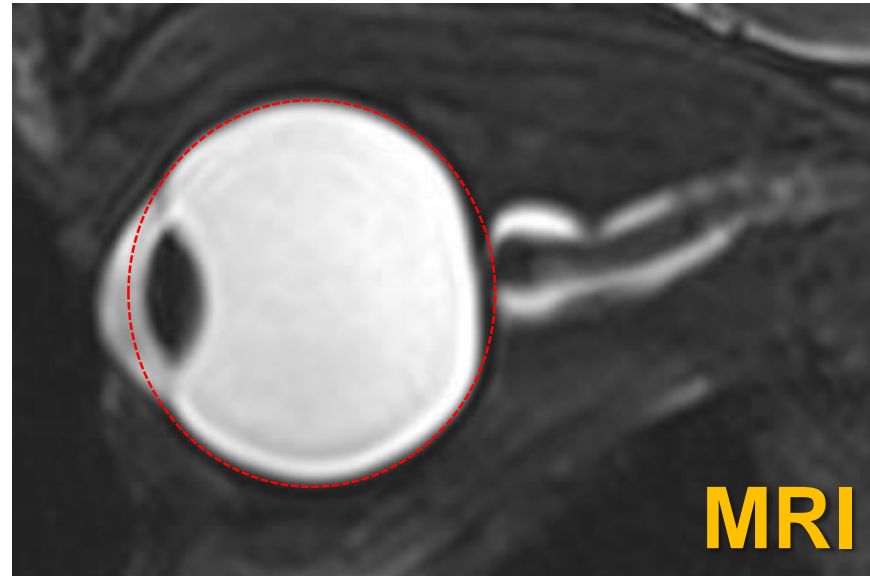
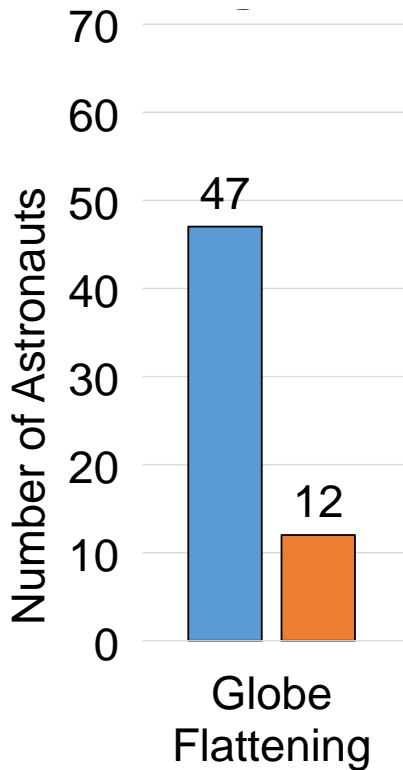
Pre-flight

Subjective call from MRI, ultrasound




Globe Flattening

Terrestrially: Globe flattening is associated with disc edema resulting from intracranial hypertension.



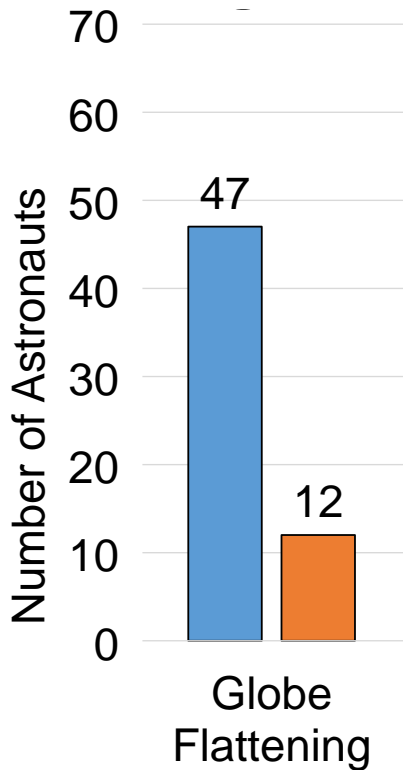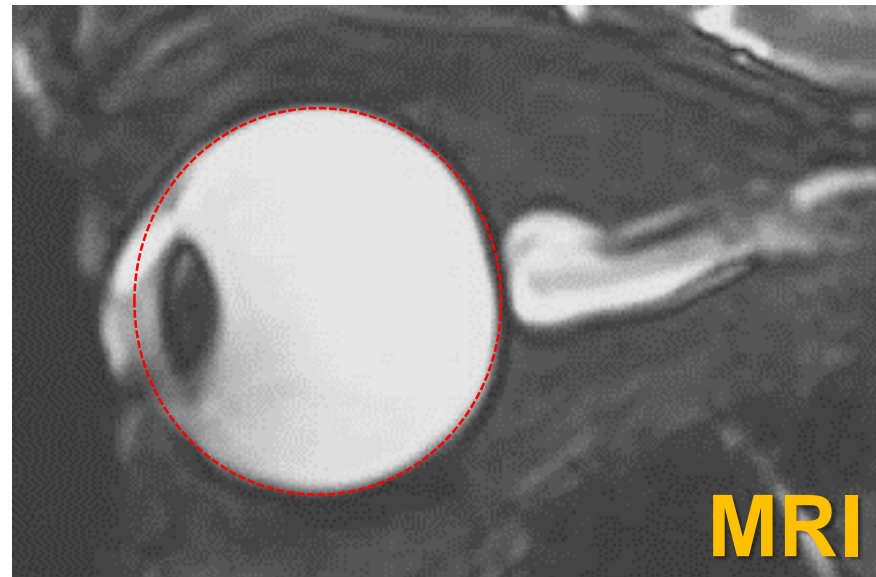
6 days post-flight

Subjective call from MRI, ultrasound




Globe Flattening

Terrestrially: Globe flattening is associated with disc edema resulting from intracranial hypertension.



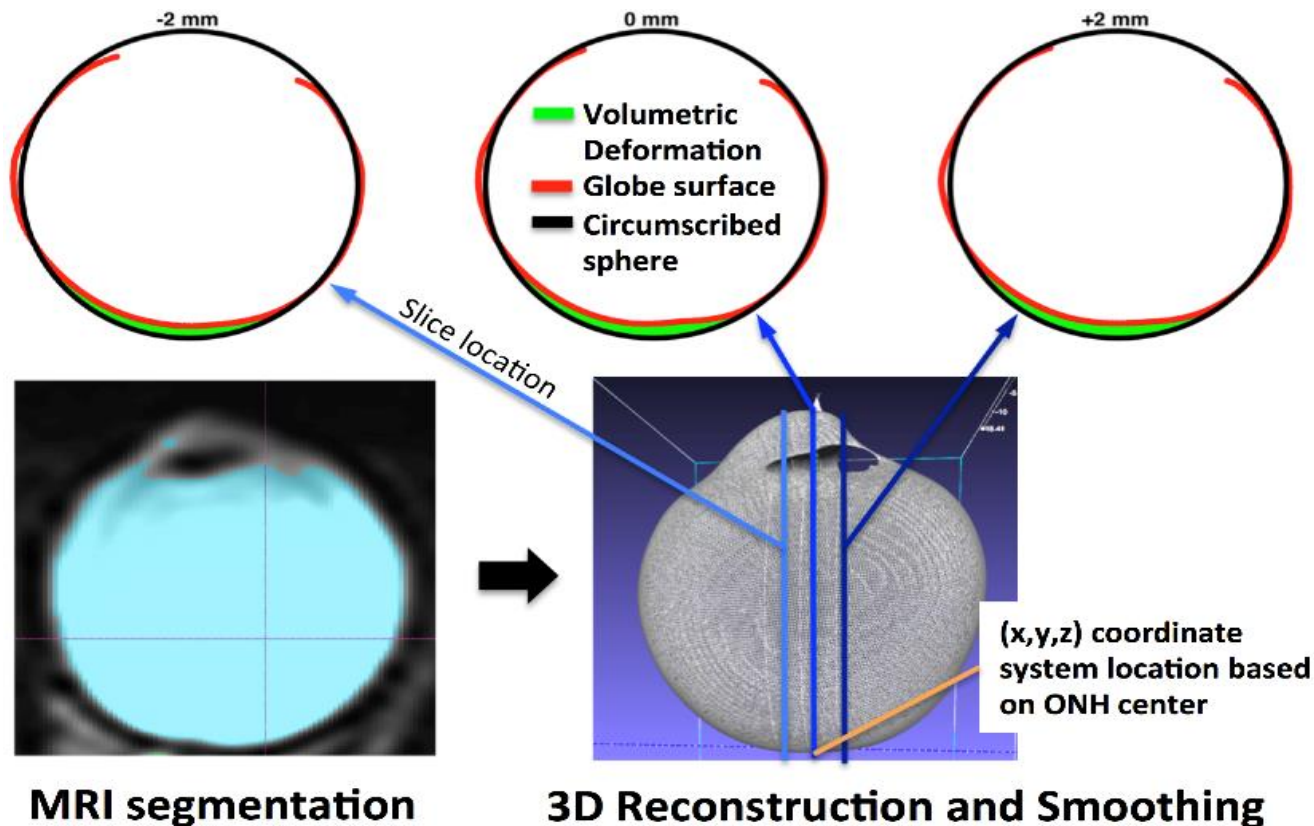
1 year post-flight


Subjective call from MRI, ultrasound



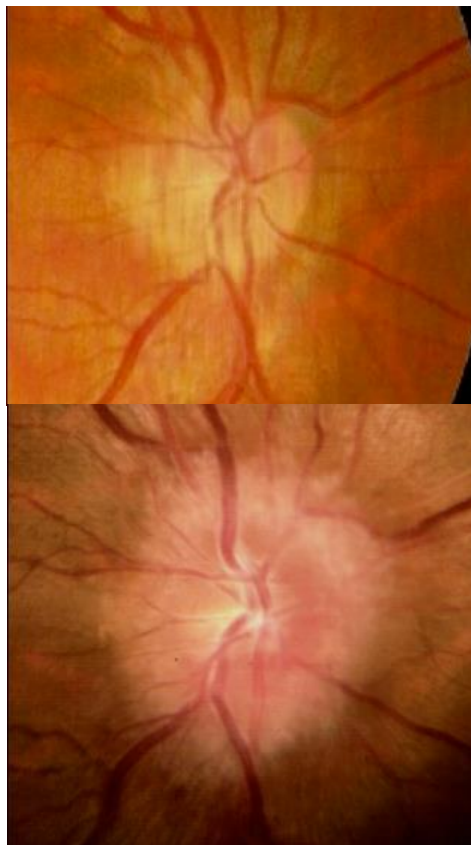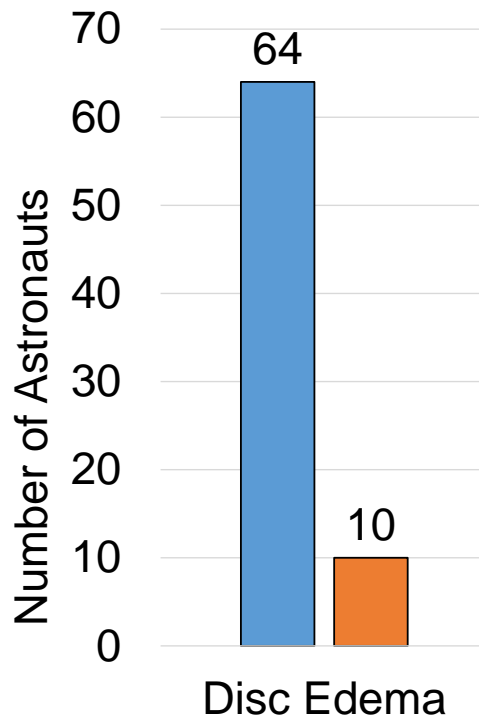
Quantify Globe Flattening

Collaboration with Dr. Bryn Martin, University of Idaho







Optic Disc Edema




- Observation of “fuzzy” optic disc on retinal fundus image.
- Score: 0-5
- 64 Pre/Post flight pairs of images
- Observed: Right > Left eye




OCT – Journey to the ISS



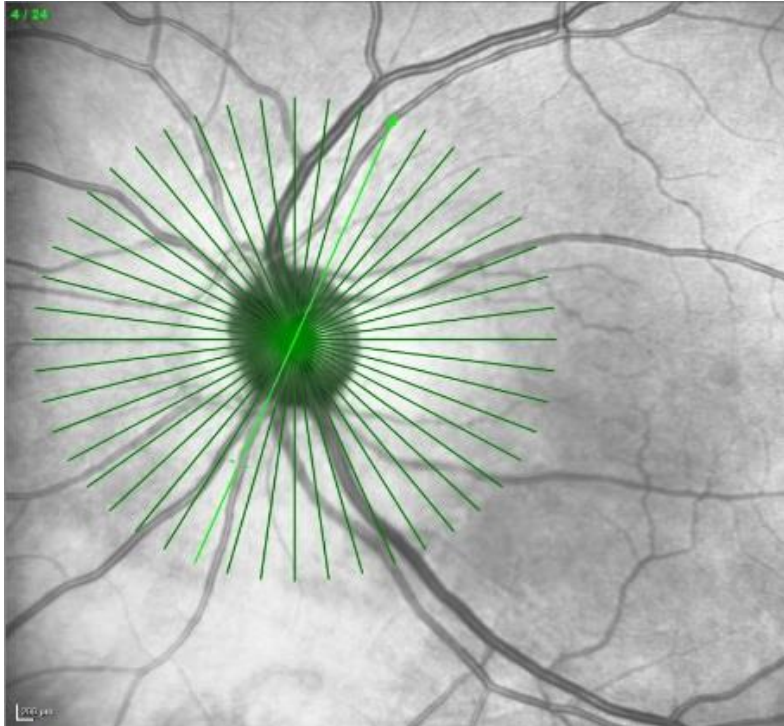

OCT on the ISS

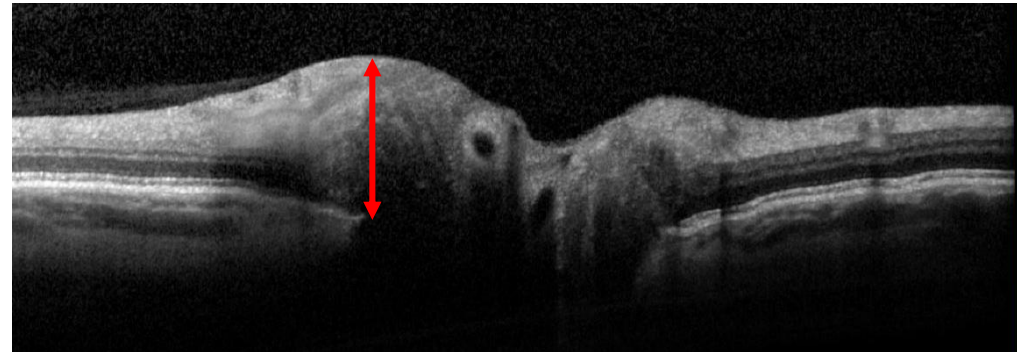
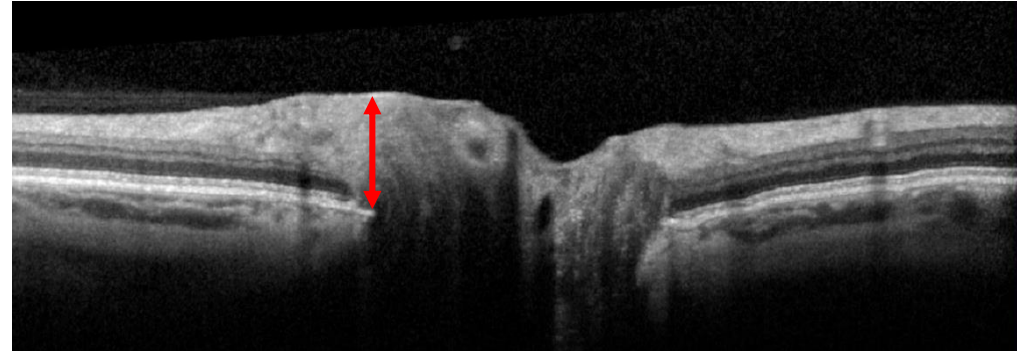




Optical Coherence Tomography



Optic nerve head. Green lines are locations of OCT scans.



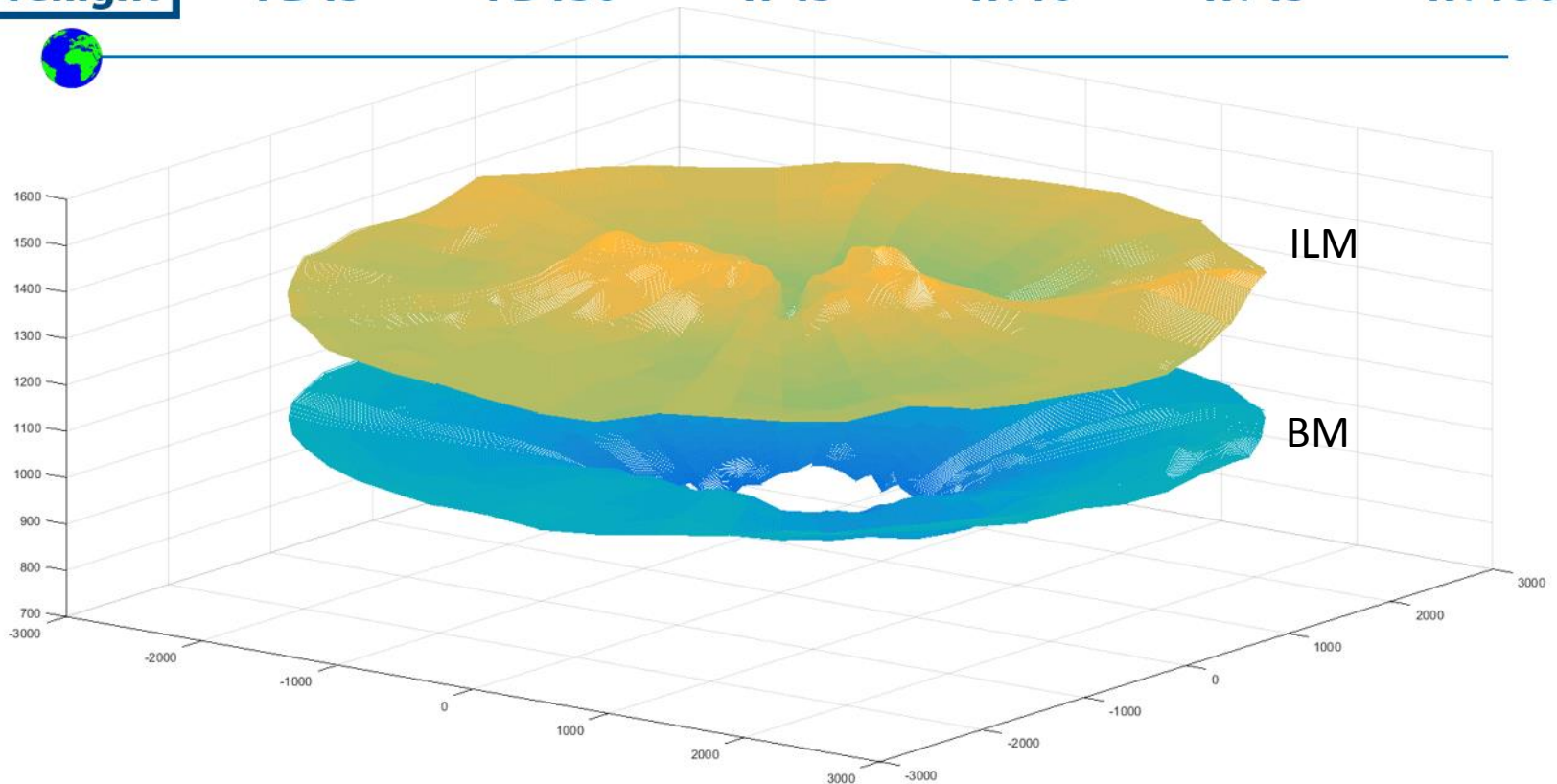
Preflight (top) and postflight (bottom) OCT scans through optic nerve head.

Reconstruct thickness map from 24 OCT images to quantify retinal thickness.



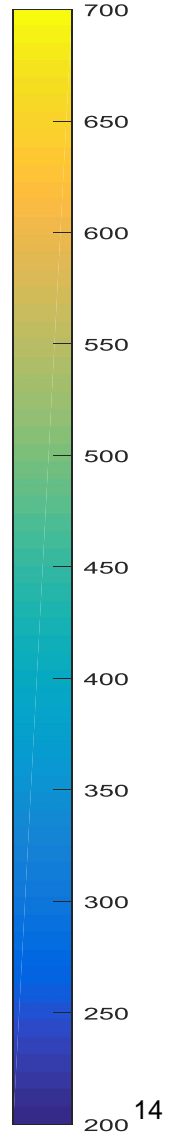
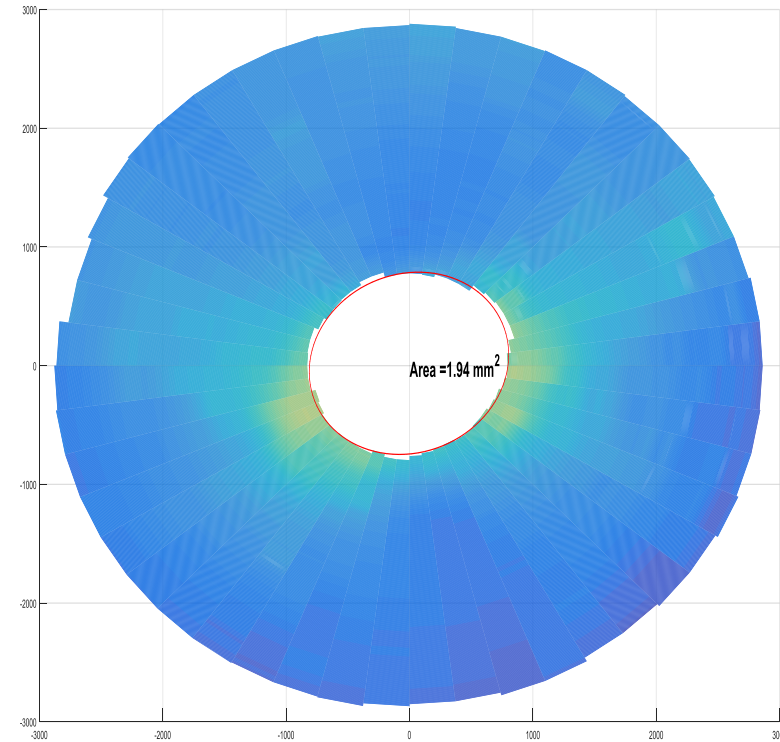
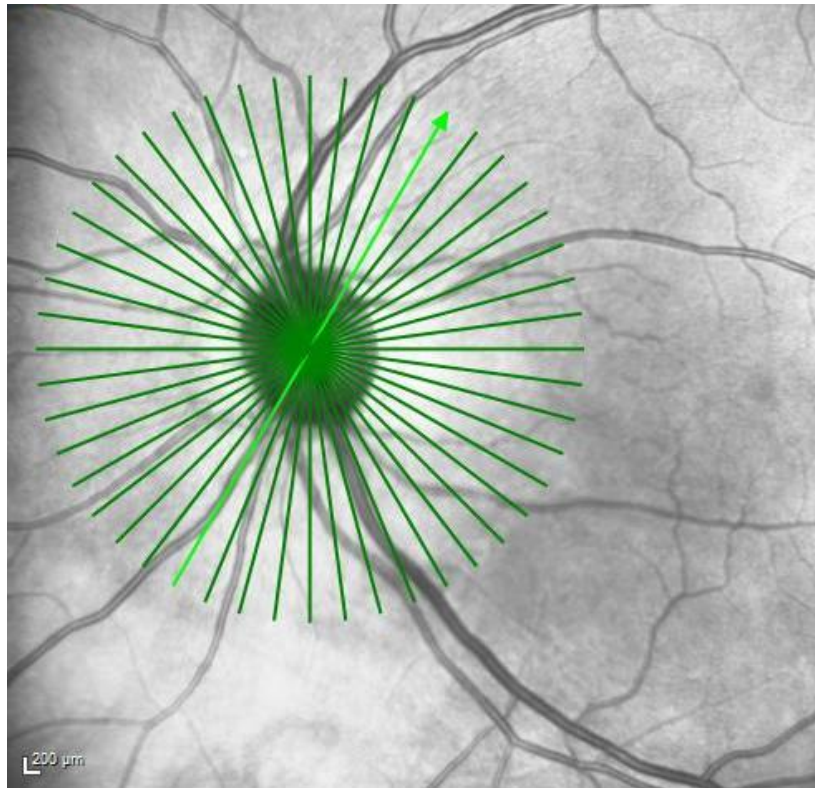
Engorgement of Optic Nerve Head


Preflight **FD45** **FD150** **R-45** **R+10** **R+45** **R+180**





ONH Thickness Map





ONH Thickness Map

Preflight

FD45

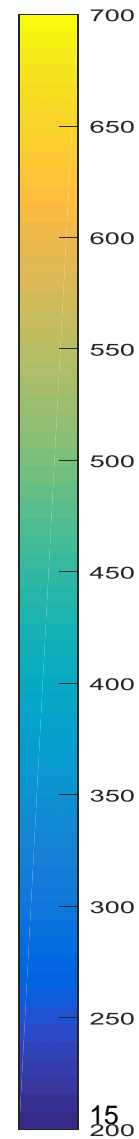
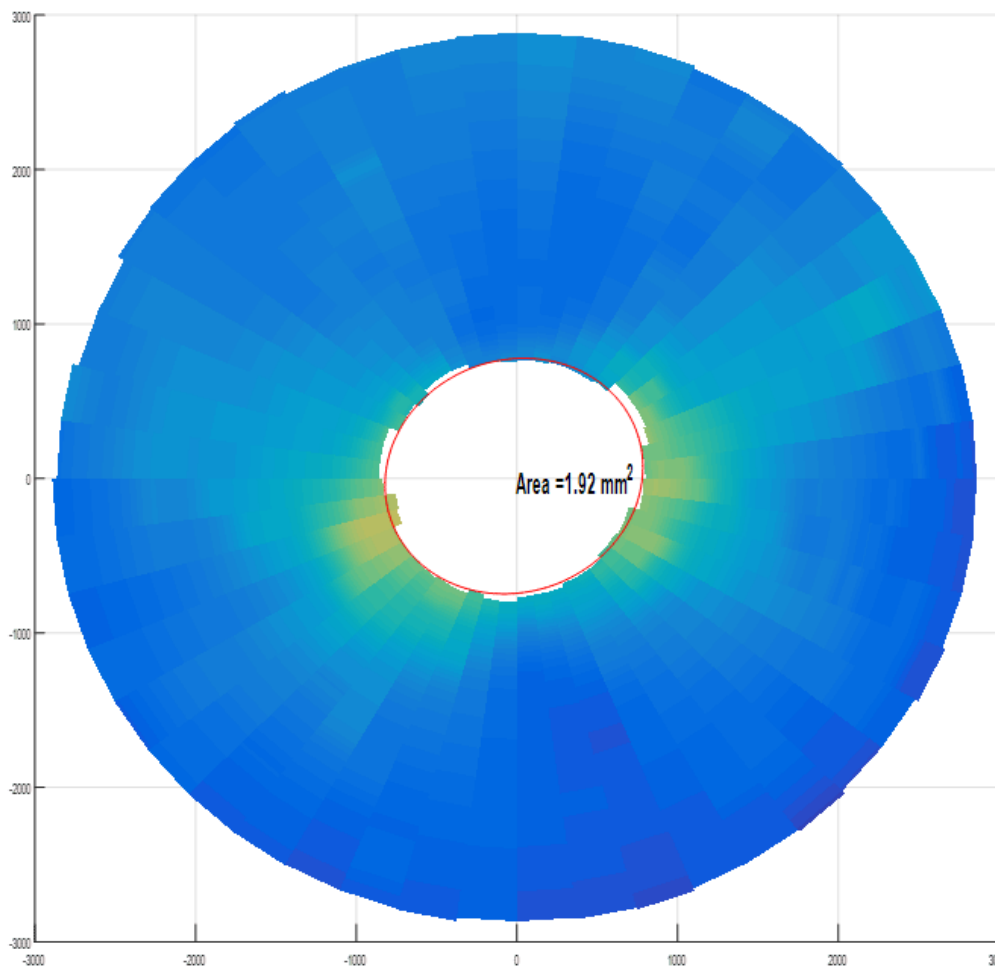
FD150


R-45

R+10

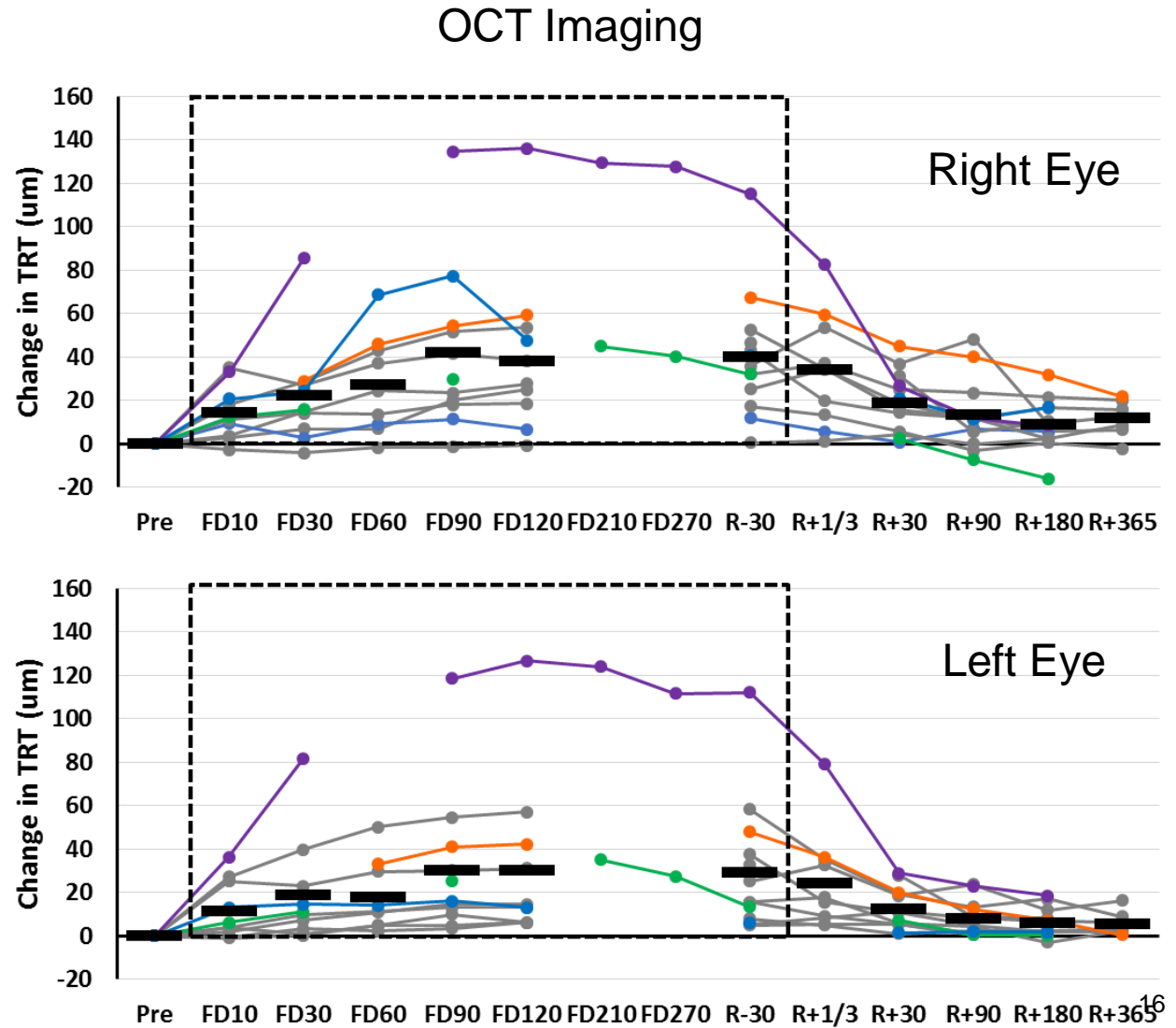
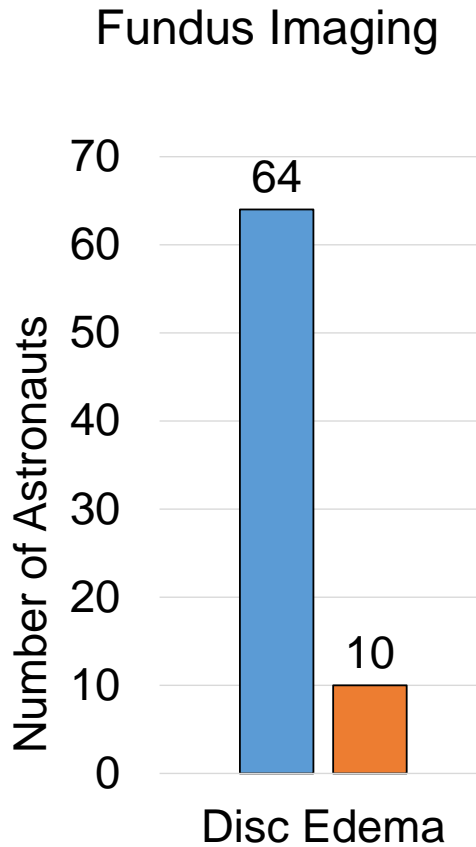
R+45


R+180





Fundus Image vs. OCT



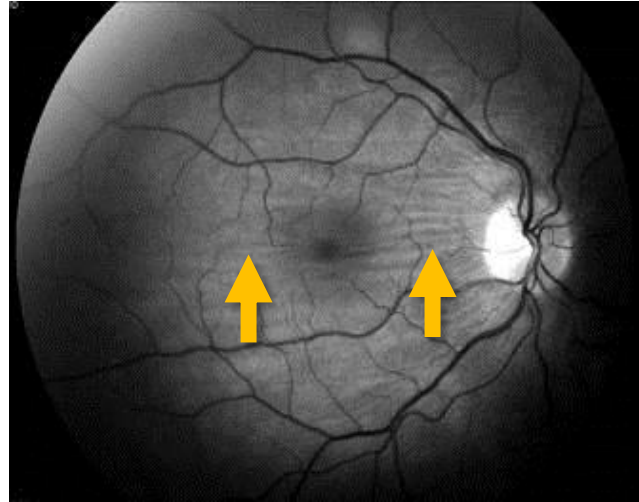
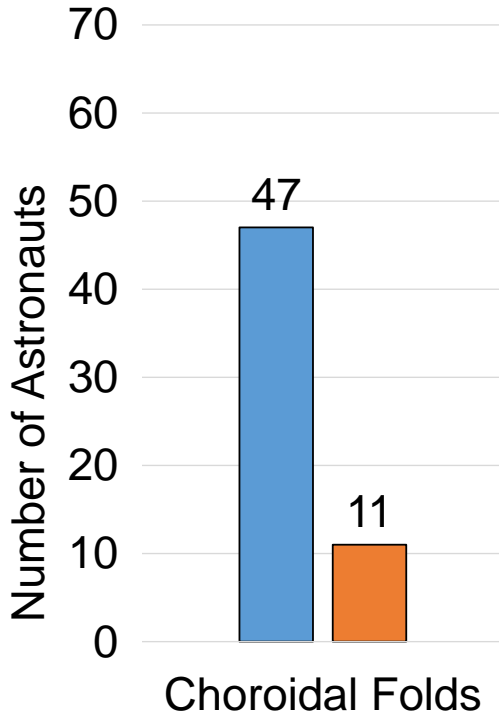


Spaceflight Duration?

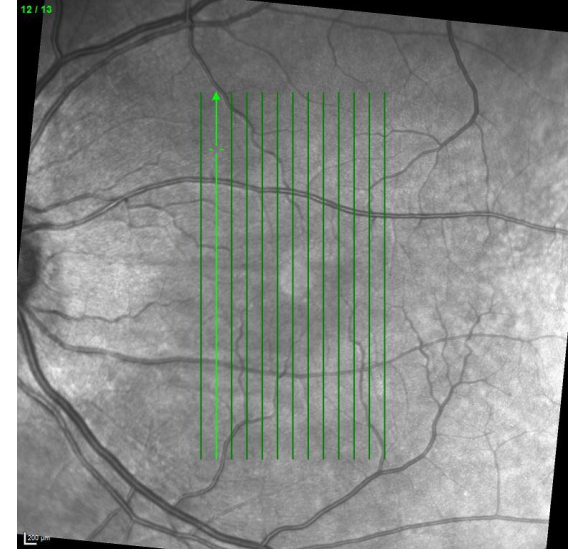Frisen Grade	Pre-flight	4-6 mo missions			1 year missions		Post-flight
Eye	L-9/6mos	FD30	FD90	FD150	FD270	R-30	R+1/3
Left	0	1	1		1	1	2
Right	0	2	2		2	2	2
Left	0	0	0	0			
Right	0	0	0	0			



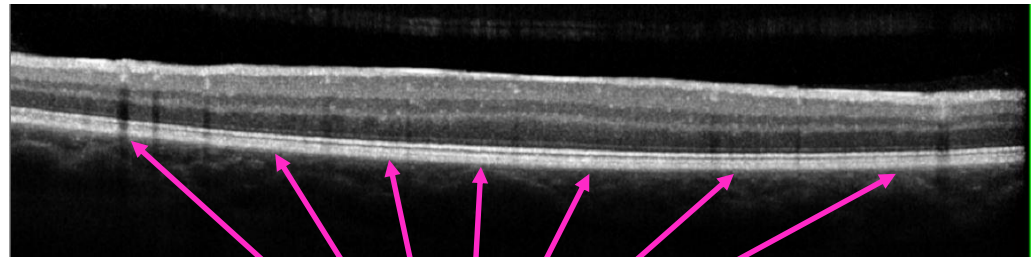
Choroidal Folds




Fundus Image



IR Image (OCT Camera)

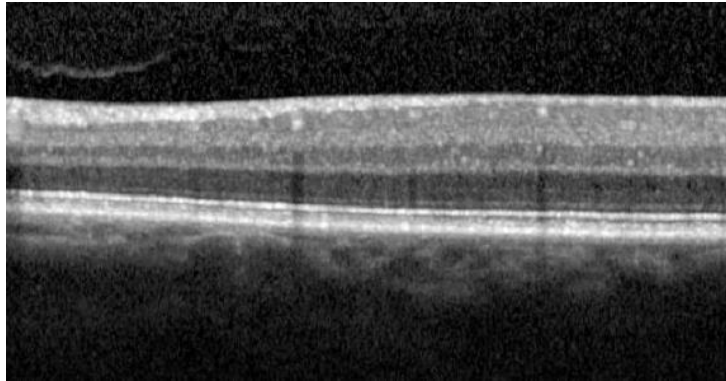


Bruch's membrane

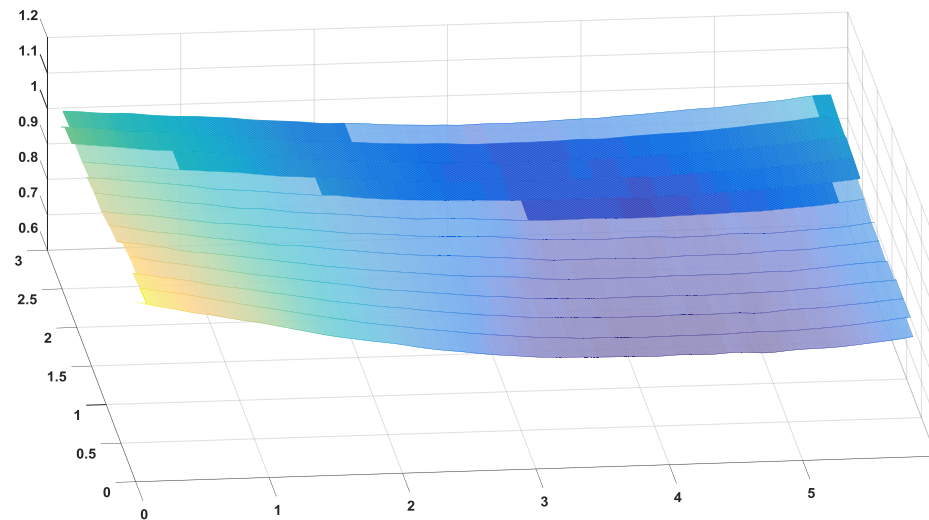
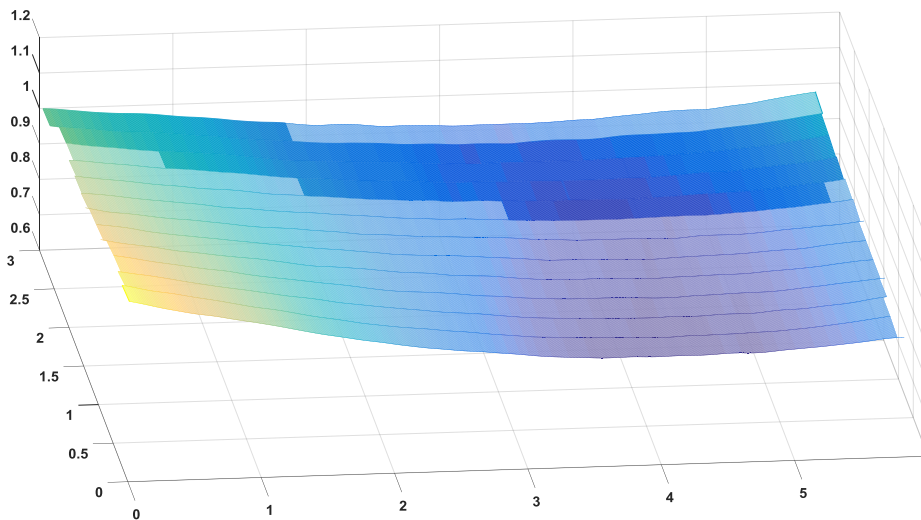
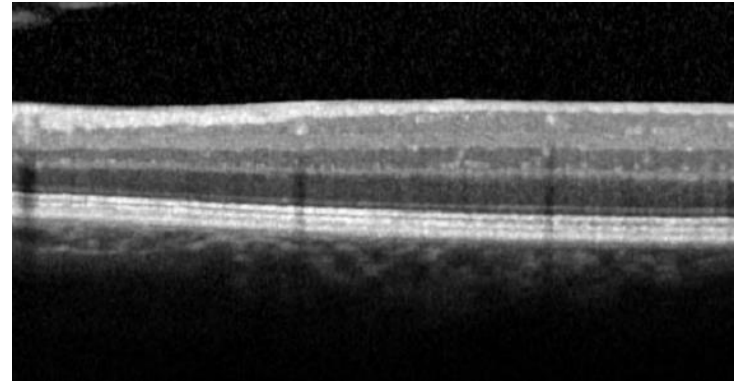



No Choroidal Folds

Pre-flight: Seated



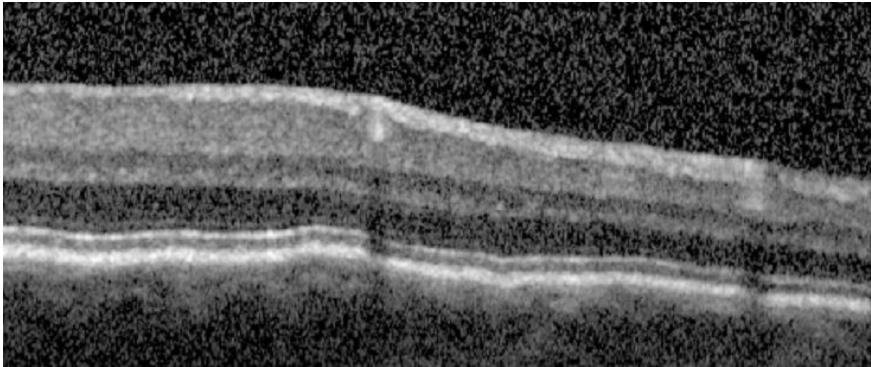
FD150



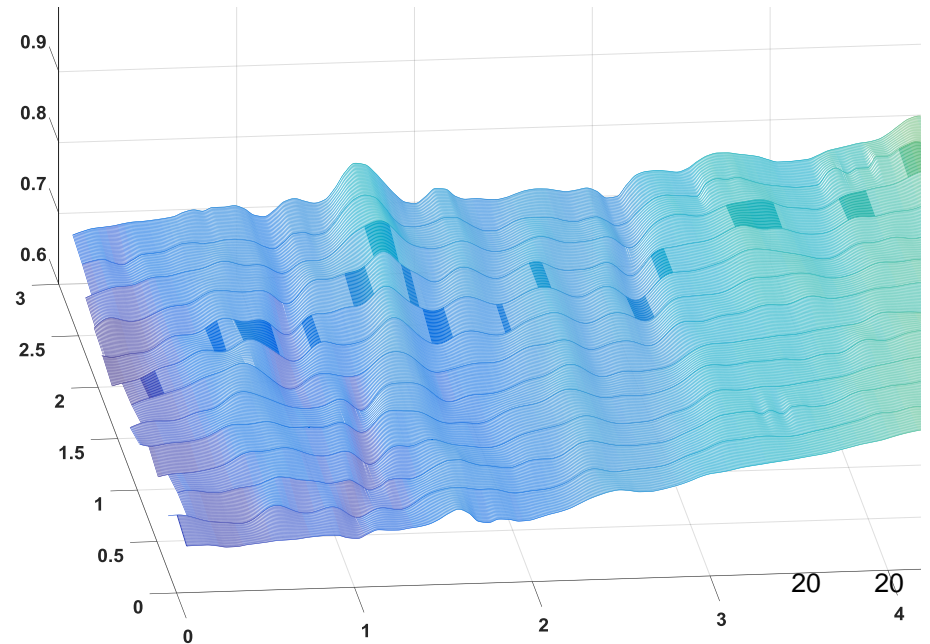
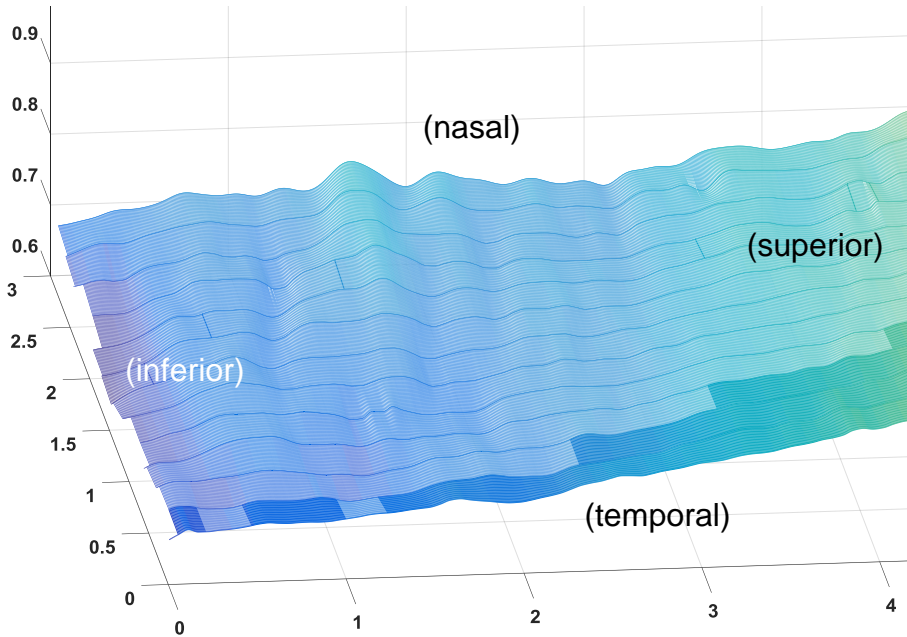
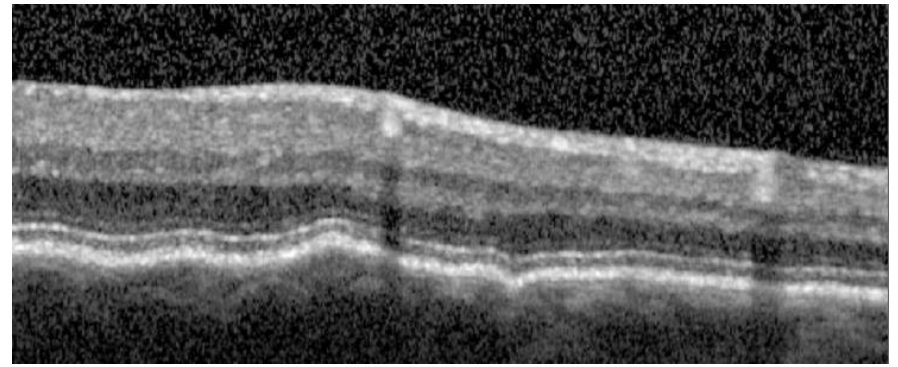


Choroidal Folds

Pre-flight: Seated

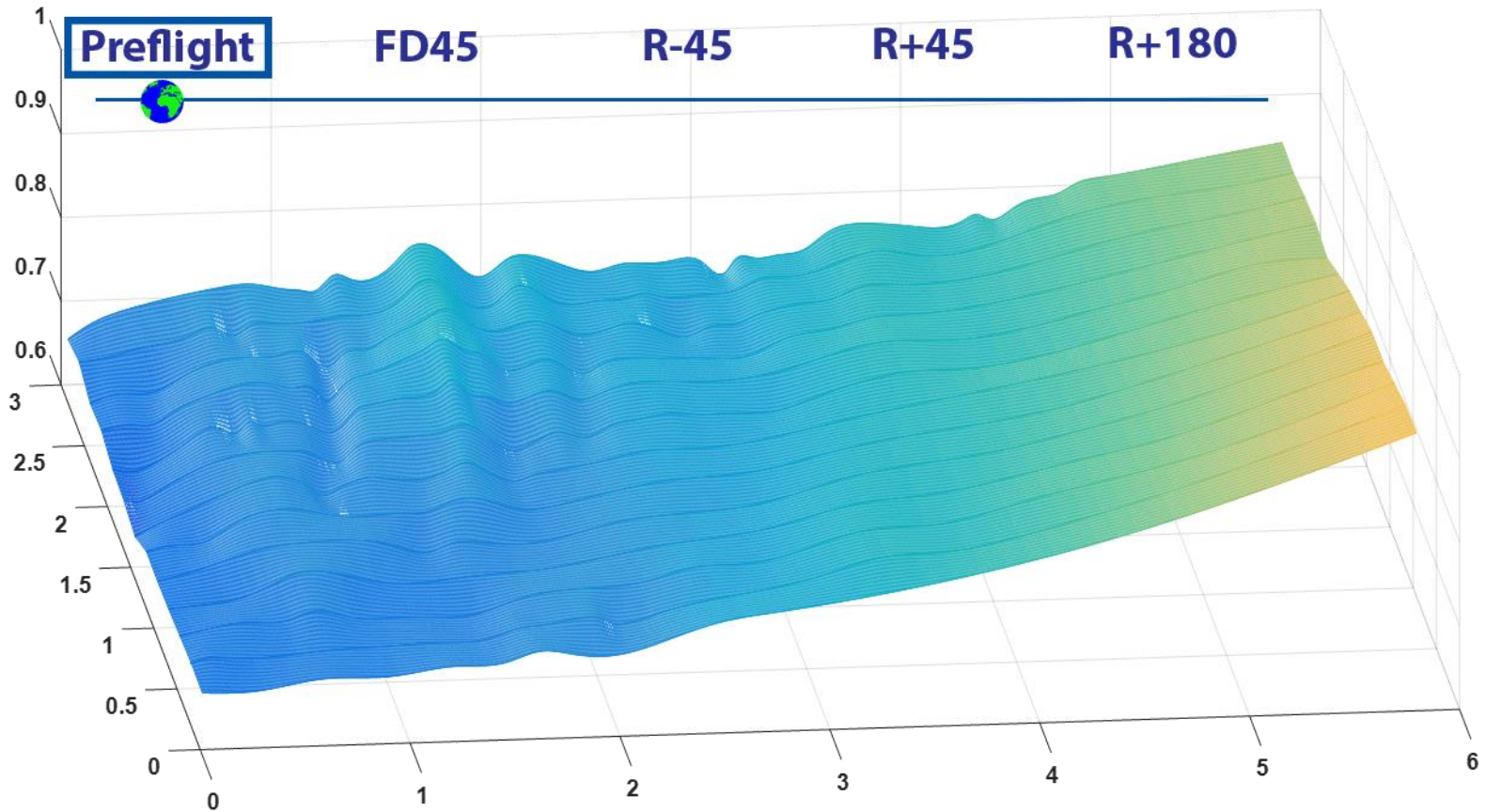


FD150



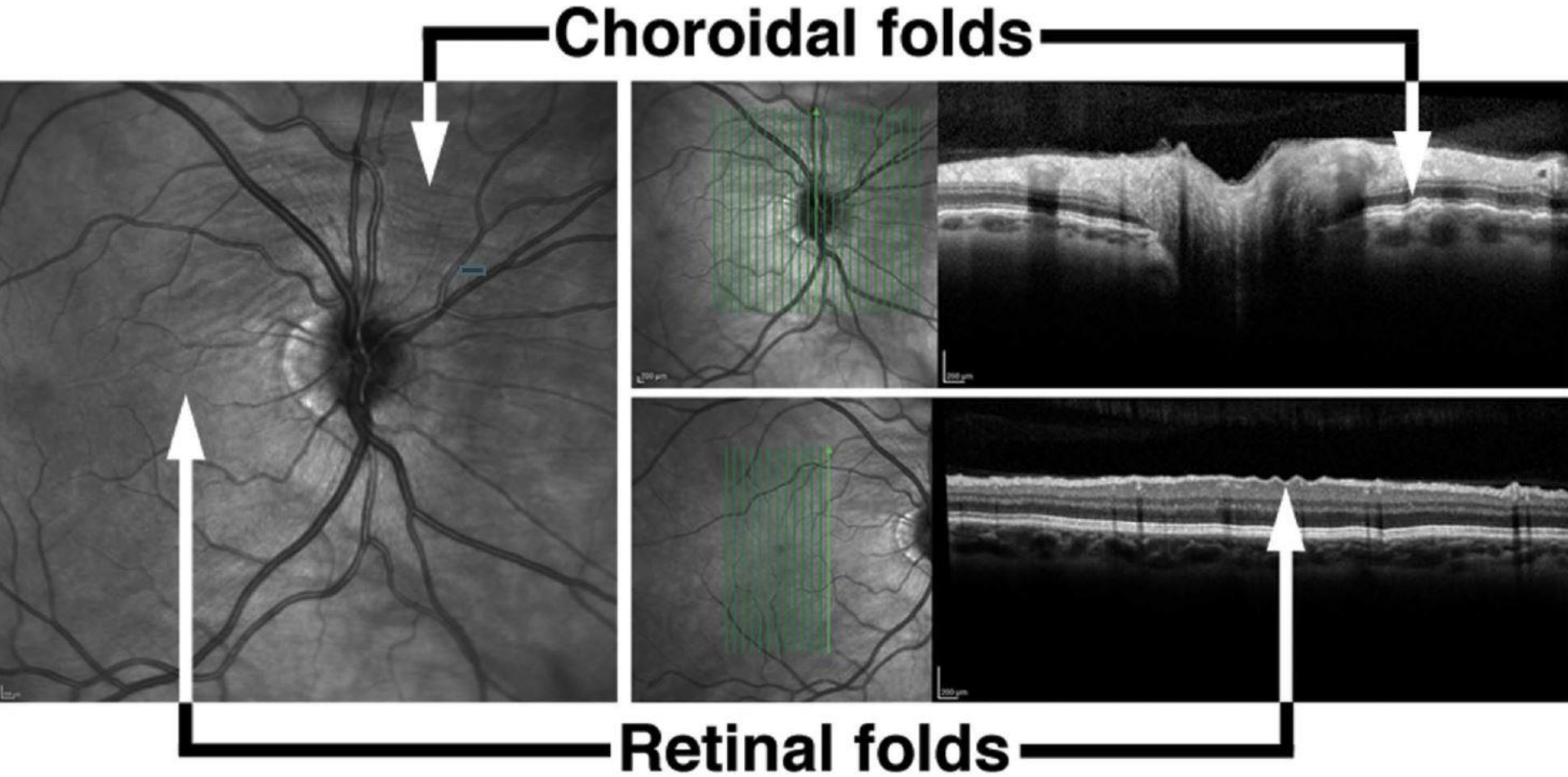



Choroidal Fold Progression



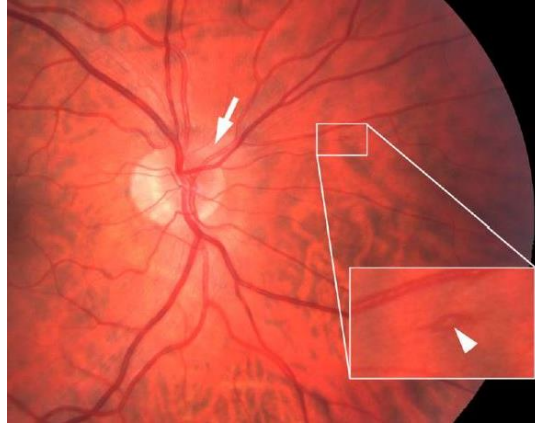
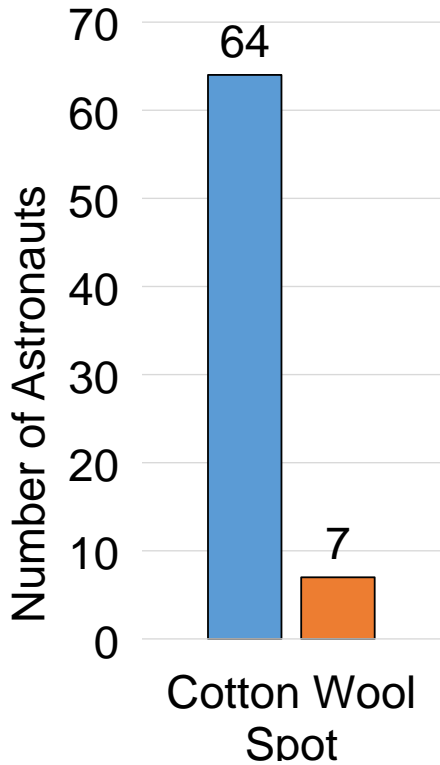


Choroidal/Retinal Folds

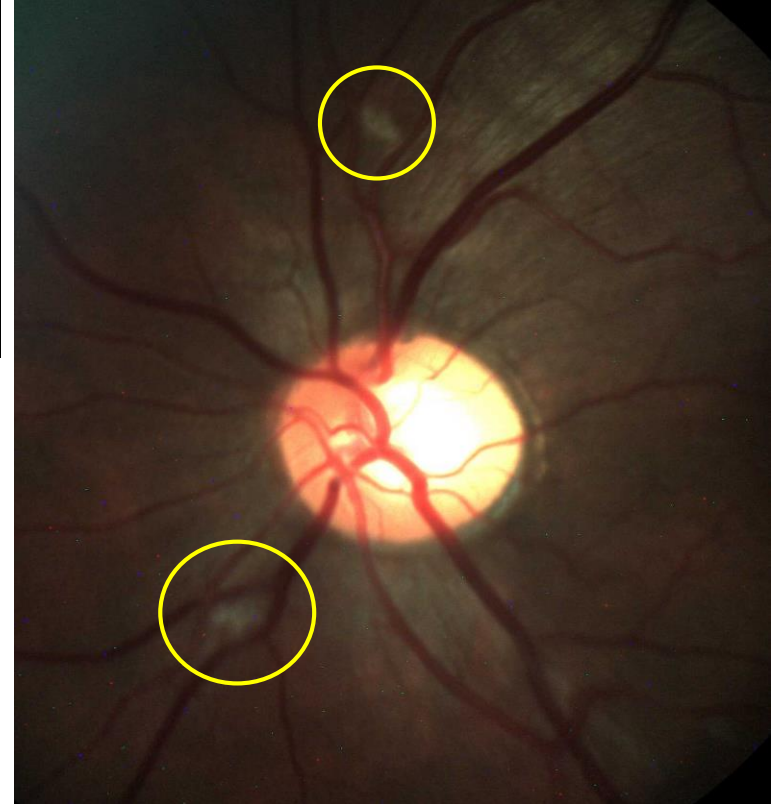





Cotton Wool Spot



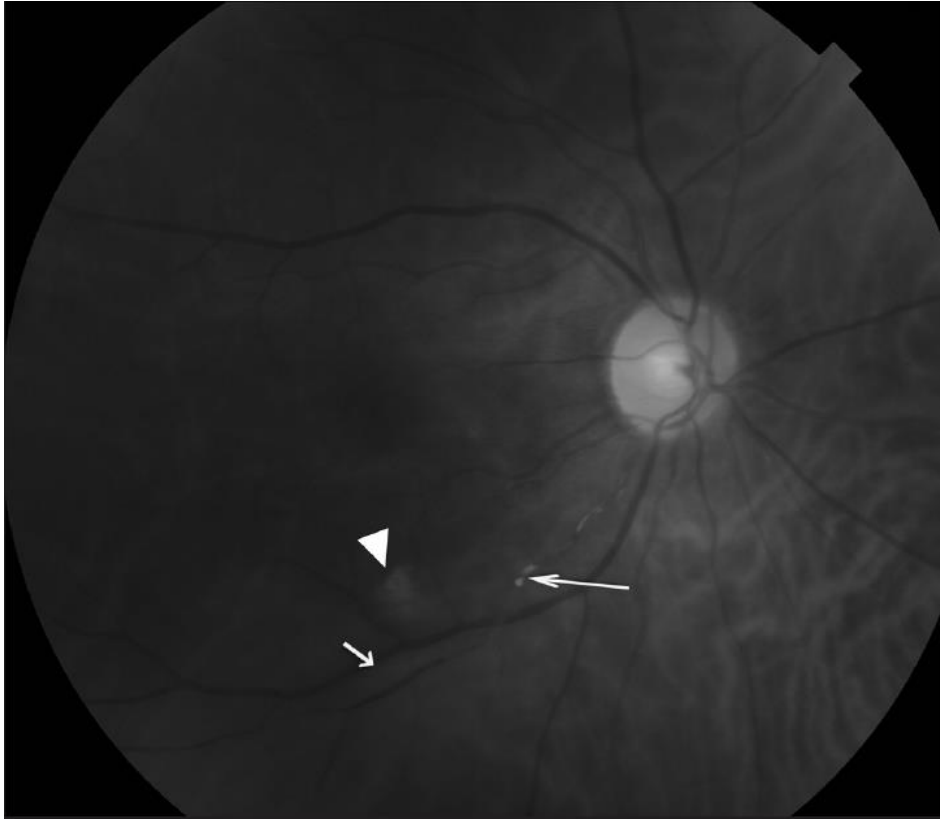
Mader et al., J Neuro-Ophthal, 2016



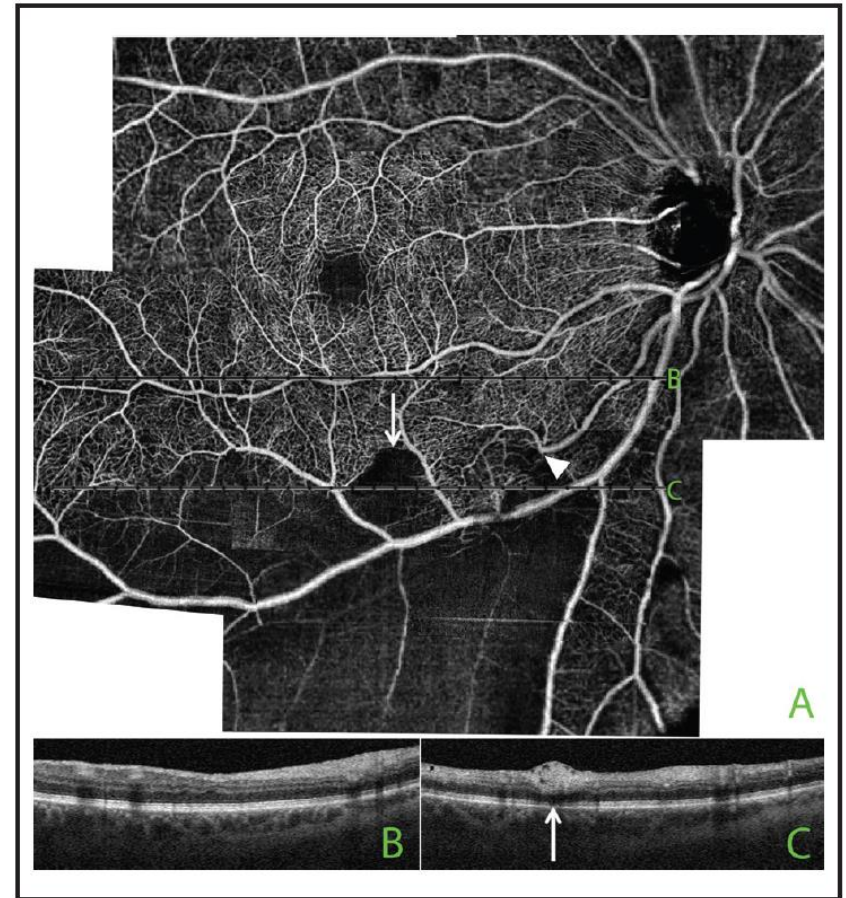



OCT Angiography

Fundus Photograph



OCT Angiography



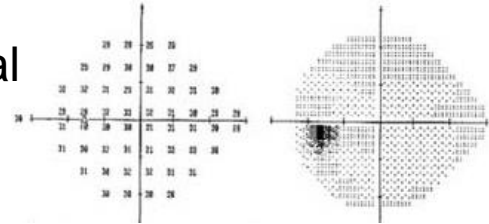


Visual Function (Threshold Visual Fields)

Humphrey Automated Perimetry

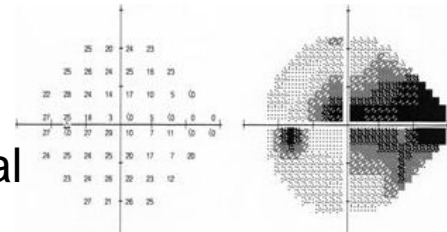


Normal

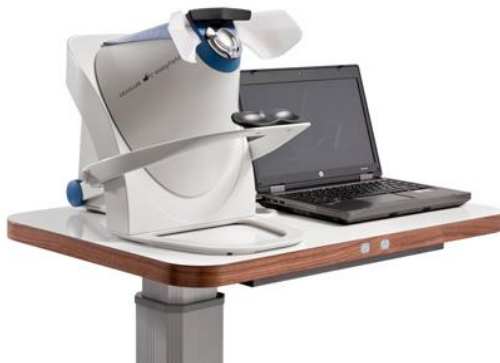

Normal Vision


Abnormal



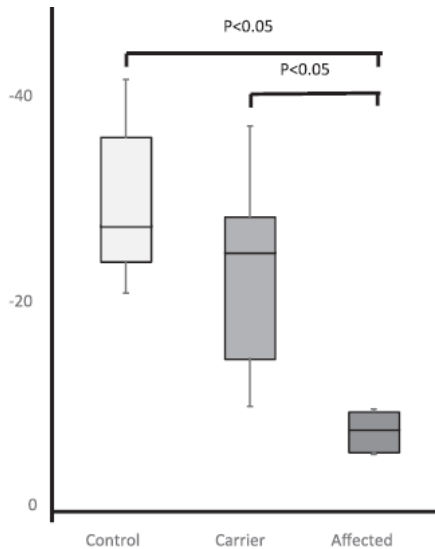
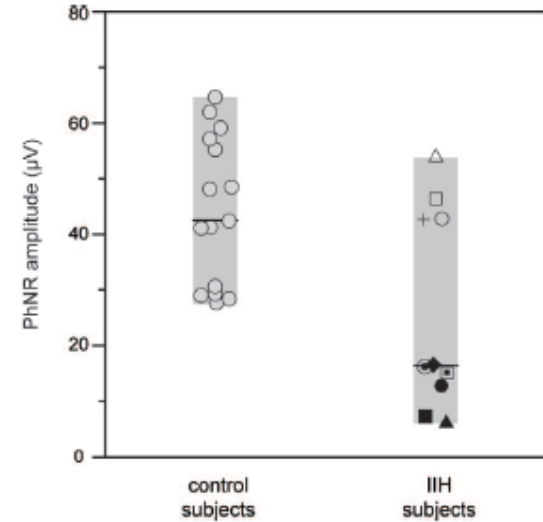
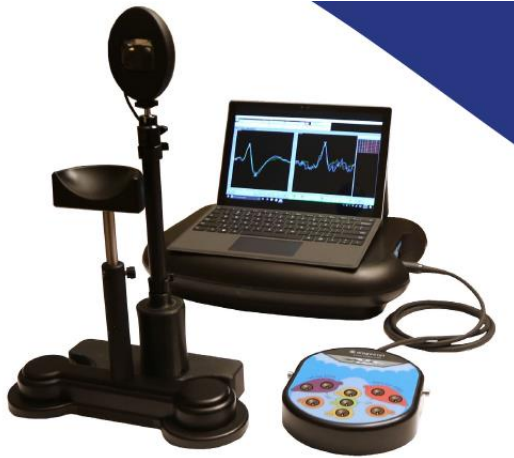Glaucoma



Potential Compact Visual Fields Device for ISS

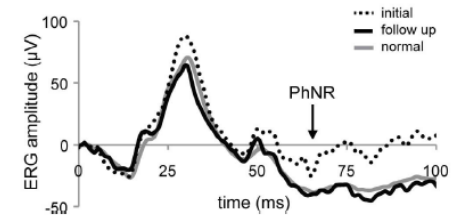
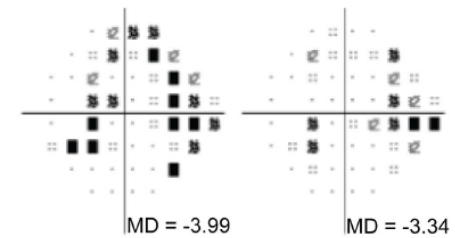


ERG – Slide here



ERG can detect significant deficits in Retinal Ganglion Cell Function in population of mitochondrial DNA mutations (some may be associated with 1C pathway)

Karanjia R et al 2017

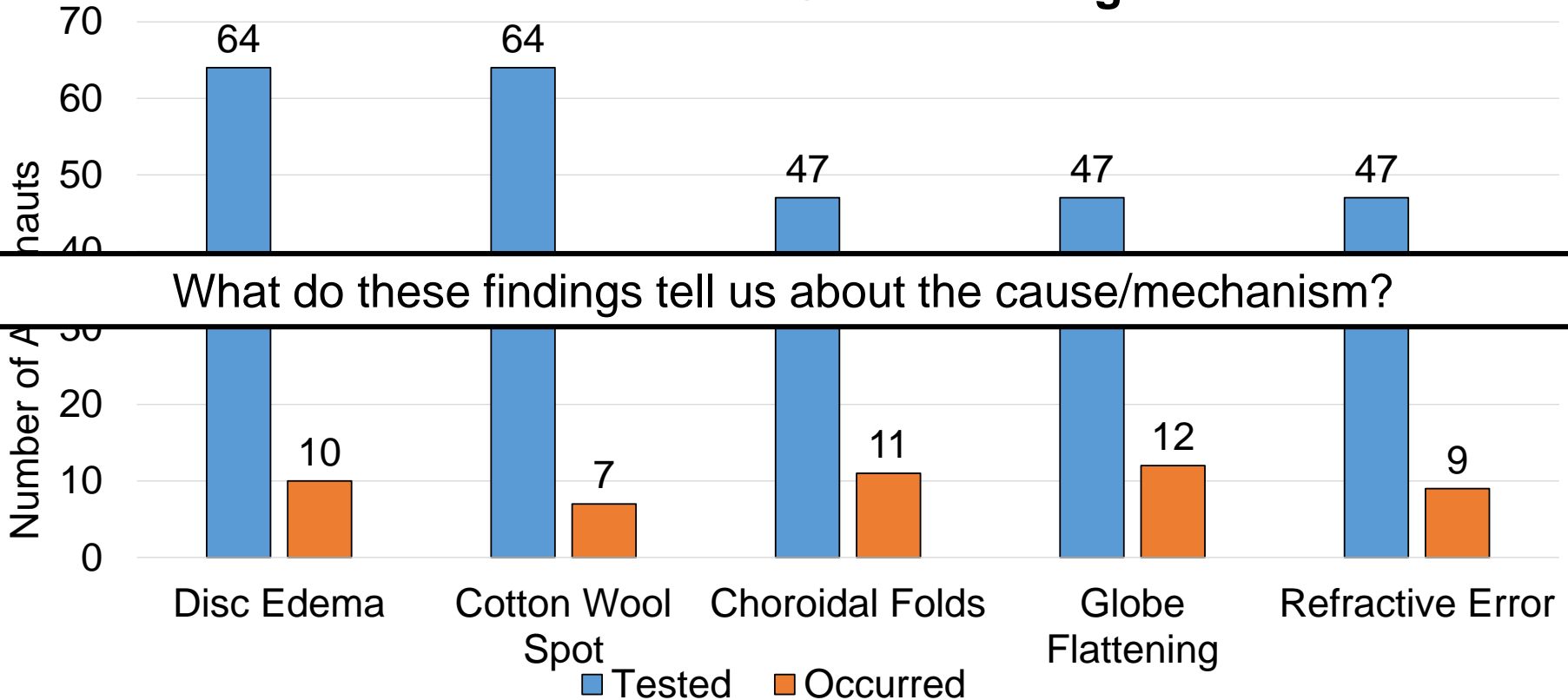


Moss H et al 2015




Ocular Findings through 2016*

Astronauts with Ocular Findings




*USOS astronauts only 27

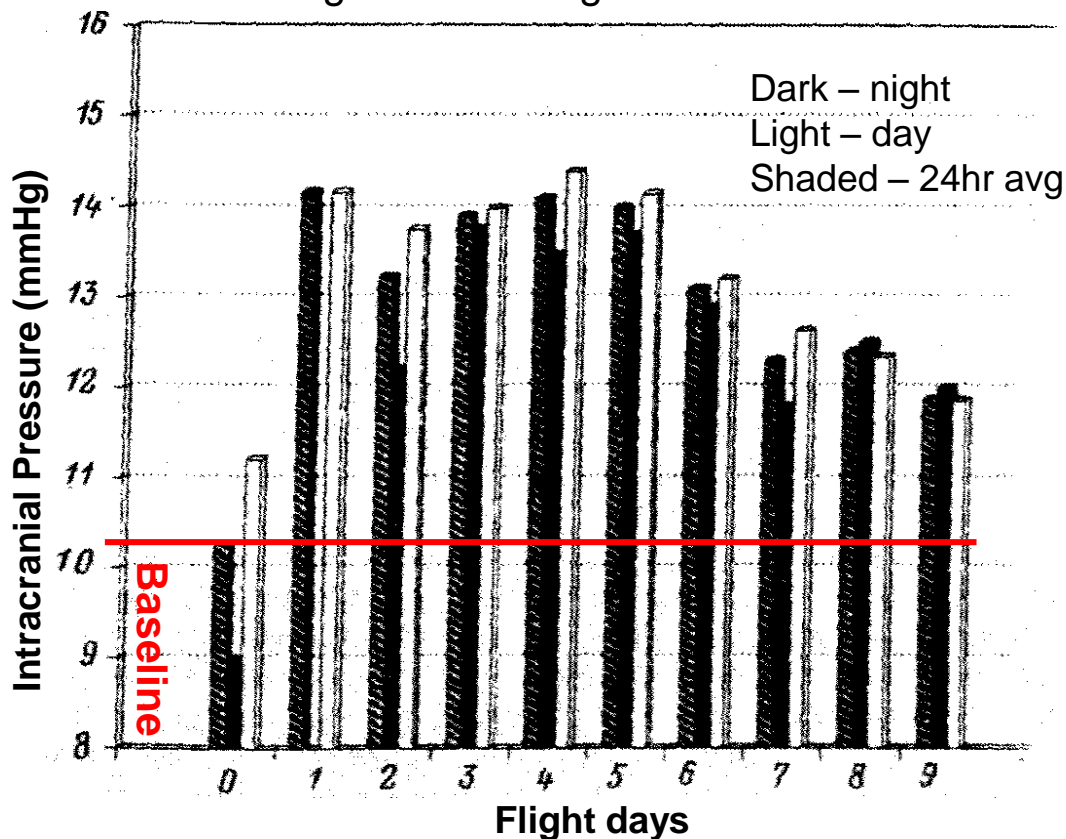



ICP during Space Flight

- ICP has never been measured in humans during spaceflight
 - Russians measured ICP invasively in a Macaque monkey in 1992, during a 10-day Bion satellite flight, with an intracranial (epidural) probe
 - ICP increased as high as 30% compared with preflight measurements
 - CO₂ did not exceed 1mmHg, ISS mission average=3.56mmHg



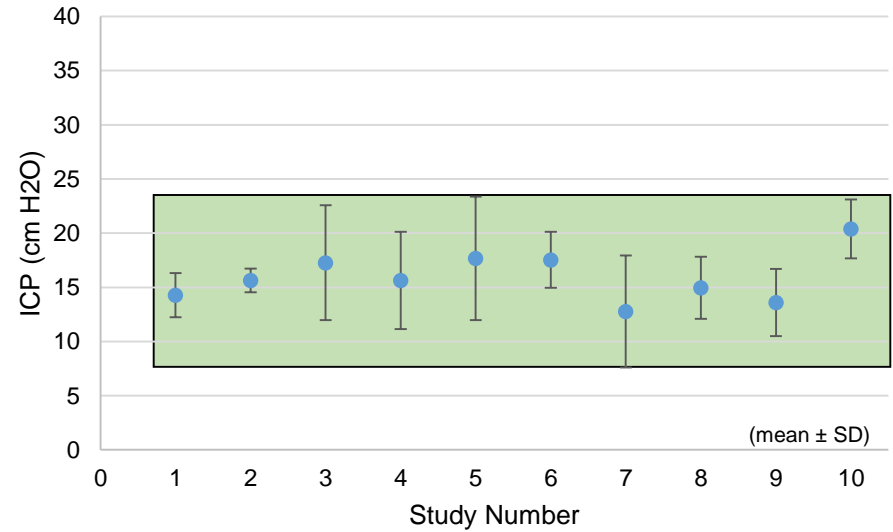
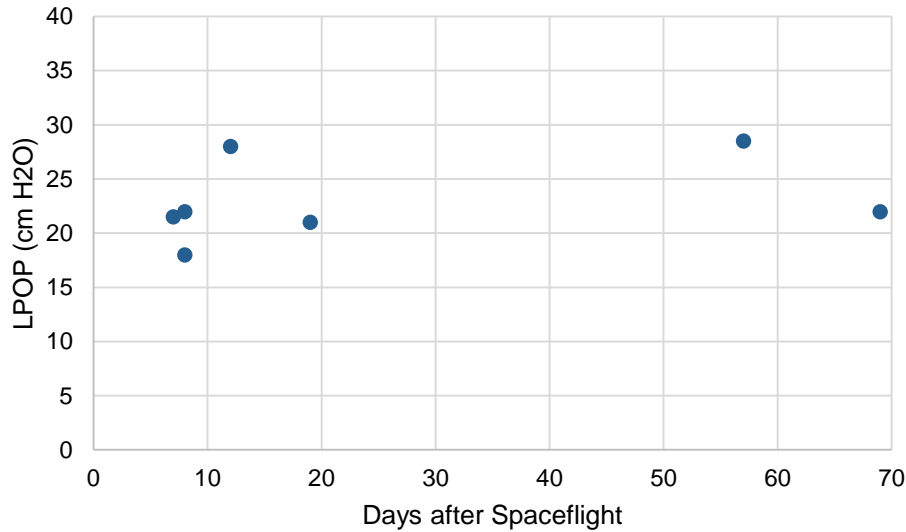
Trambovetskiĭ et al. 1995. Intracranial pressure in monkeys during the flight of Cosmos-2229. [Aviakosm Ekolog Med.](#)





Intracranial Pressure

Idiopathic Intracranial Hypertension patients: optic disc edema and globe flattening



ICP *after* spaceflight may not be pathologically elevated.

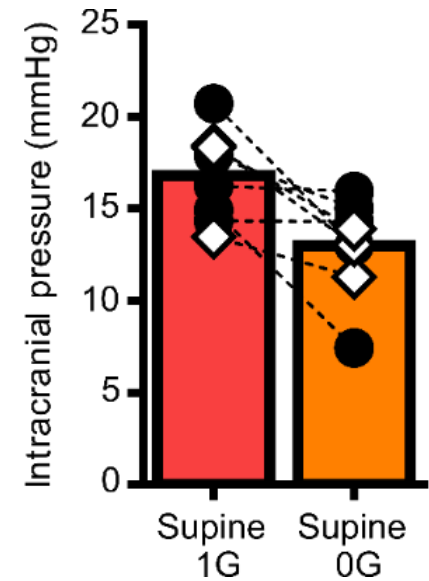
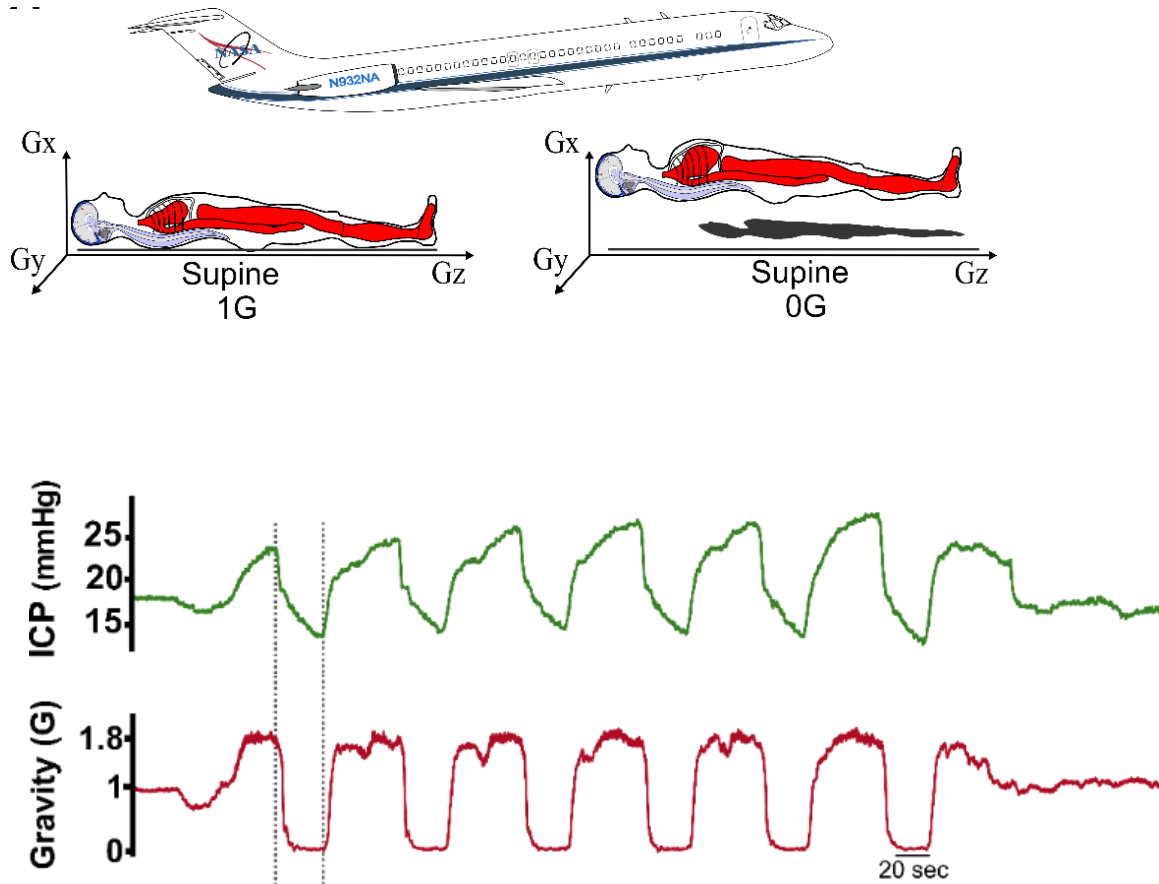
What was ICP during spaceflight?

Publication	Position	n
Eklund, Ann Neurol, (2016) 80:269-276	Supine	11
	Supine	11
Berdahl, IOVS, (2008) 49:5412-18	Supine	68
	Supine	39
Berdahl, Ophthalmology, (2008) 115:763-68	Supine	49
Ren, Ophthalmology, (2010) 117:259-66	Supine	71
Petersen, AJPR, (2015) 310:R100-4	Supine	9
Qvarlander, JAP, (2013) 115:1474-80	Supine	27
Edsbacke, AJPR, (2004) 287:R1450-5	Supine	34
Lawley, J Physiol, (2017) 15(595):2115-2127	Supine	8


*USOS crew only



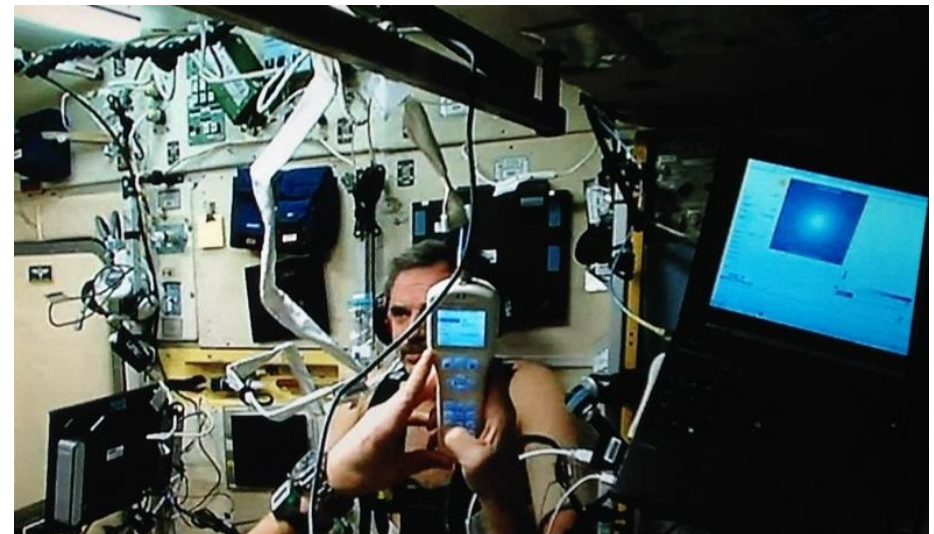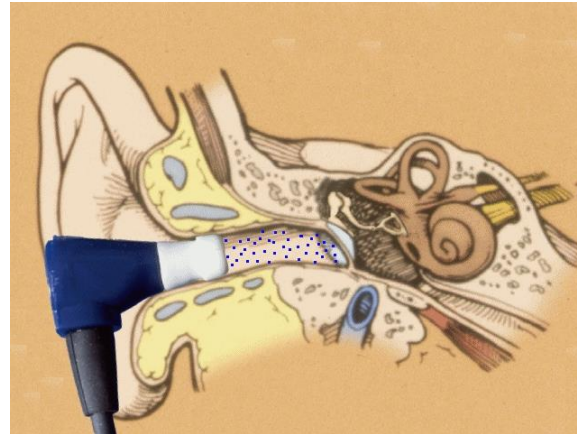
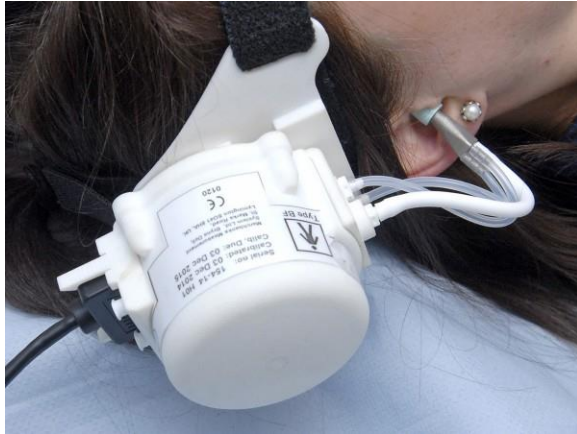Direct ICP Measures



Lawley JS et al 2017

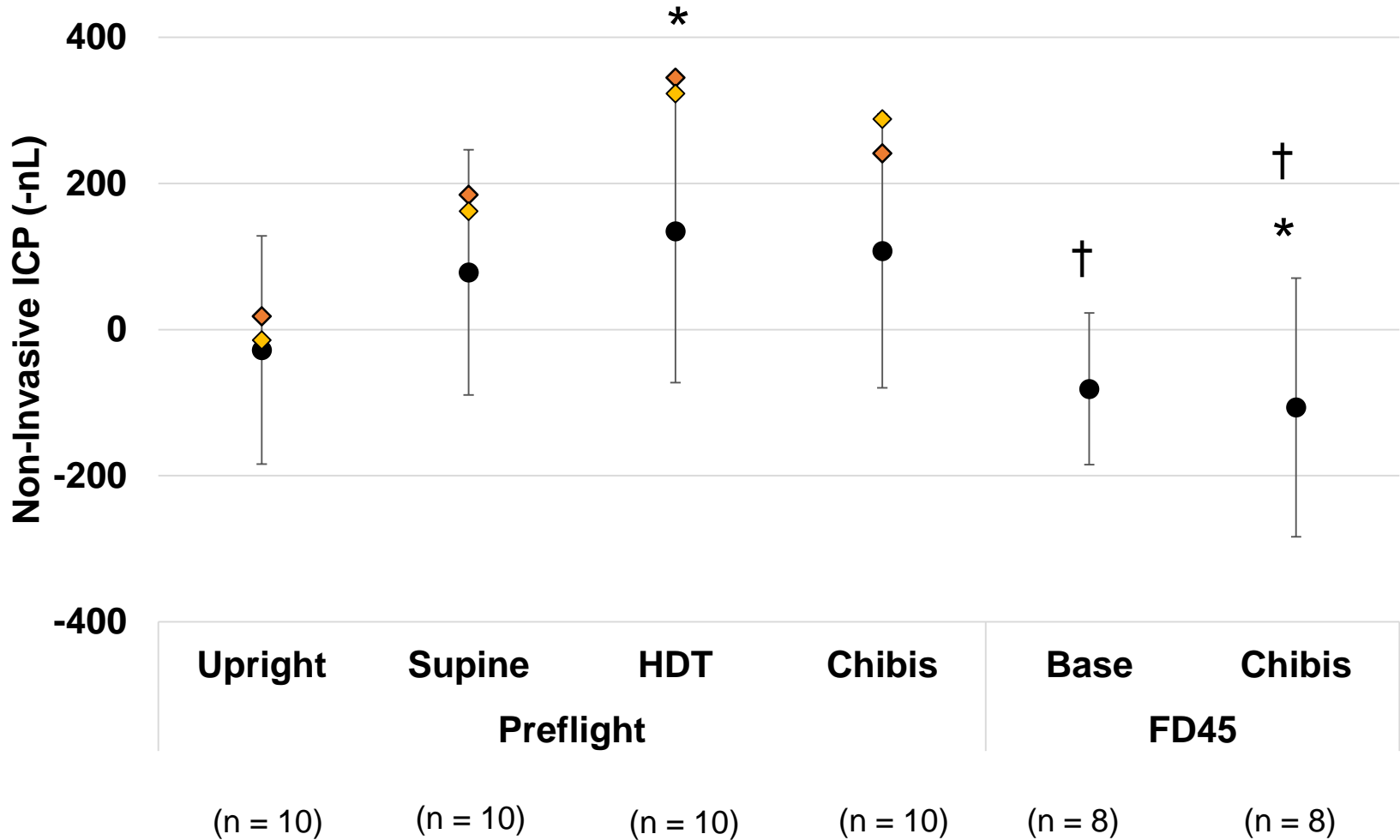


CCFP & DPOAE





Tympanic Membrane Displacement: CCFP



(mean ± standard deviation)

* p < .05 vs. Upright

† p < .05 vs. Supine




Name change: SANS

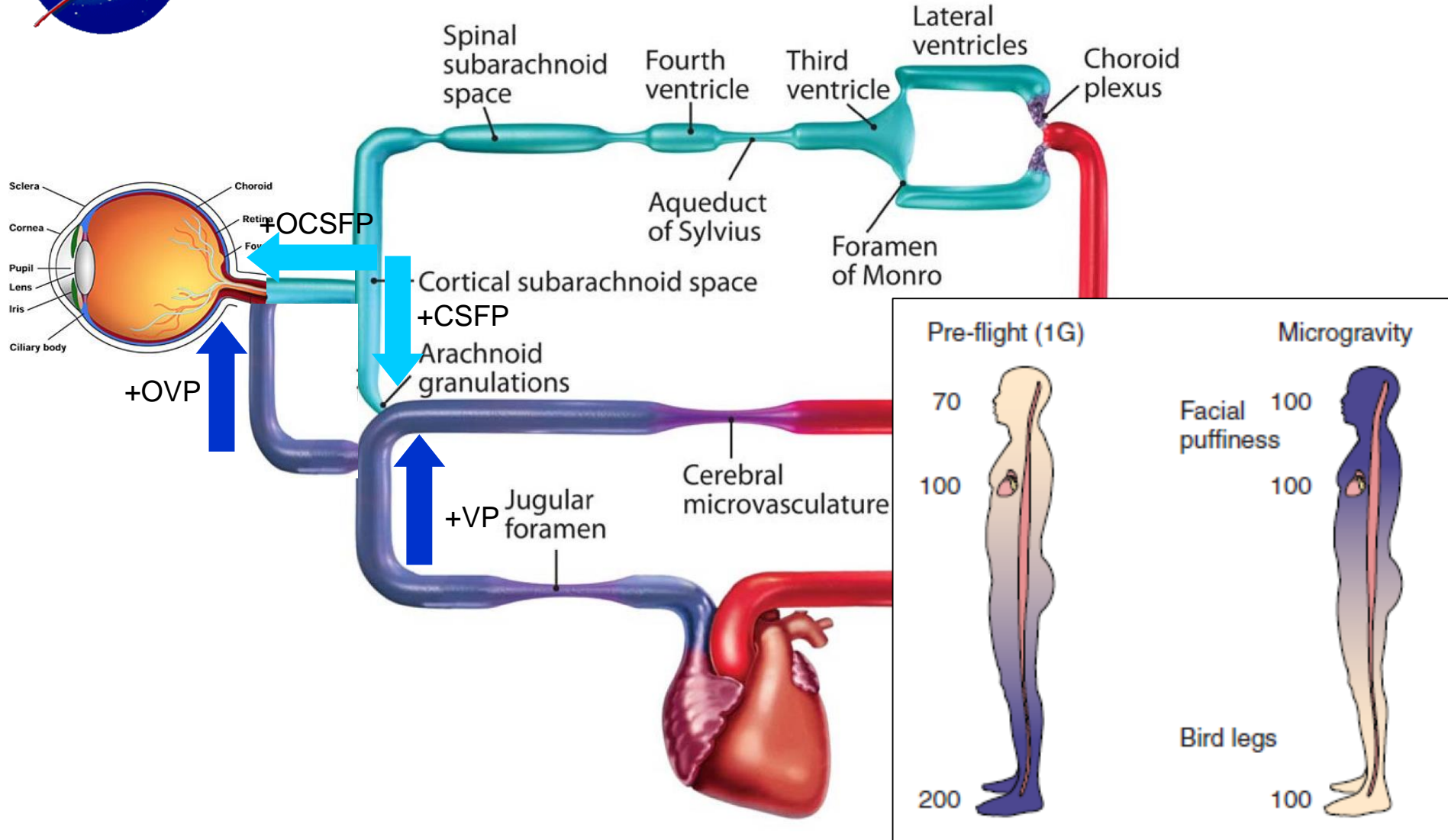
“I only have 2 concerns with the name VIIP. Crew members do not have “Vision Impairment” and it doesn’t appear that “Intracranial Pressure” is pathologically elevated.”


*- Dr. Bill Tarver, Flight Surgeon
NASA Human Systems Risk Board Presentation*

Spaceflight Associated Neuro-ocular Syndrome
(SANS)

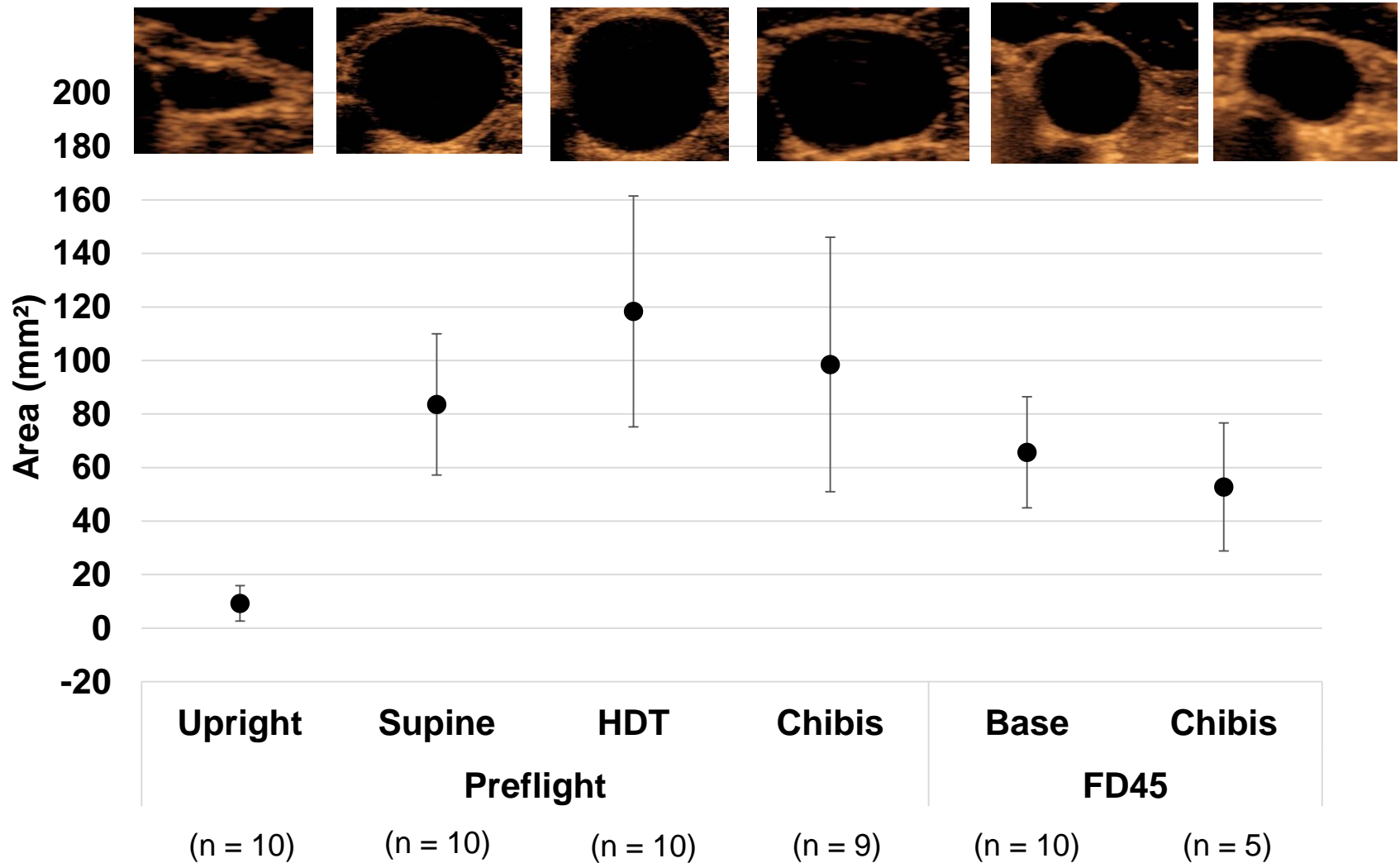


Fluid Shifts






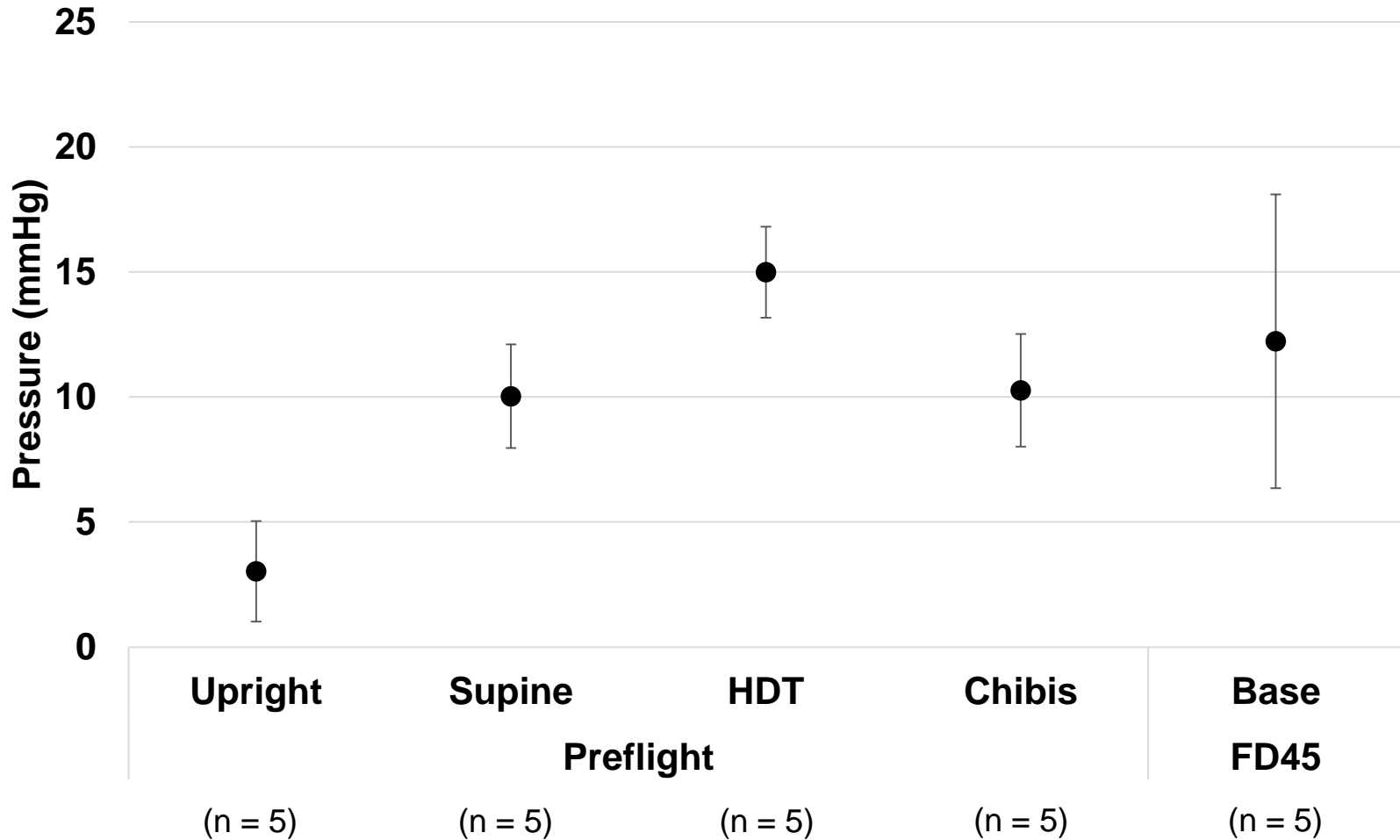
Internal Jugular Vein Area



(mean ± standard deviation)



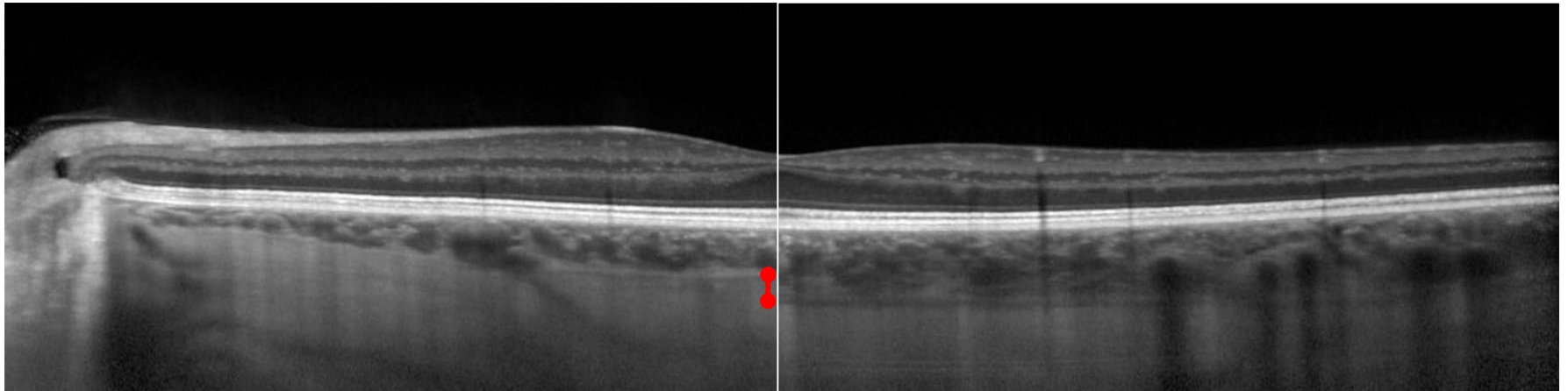
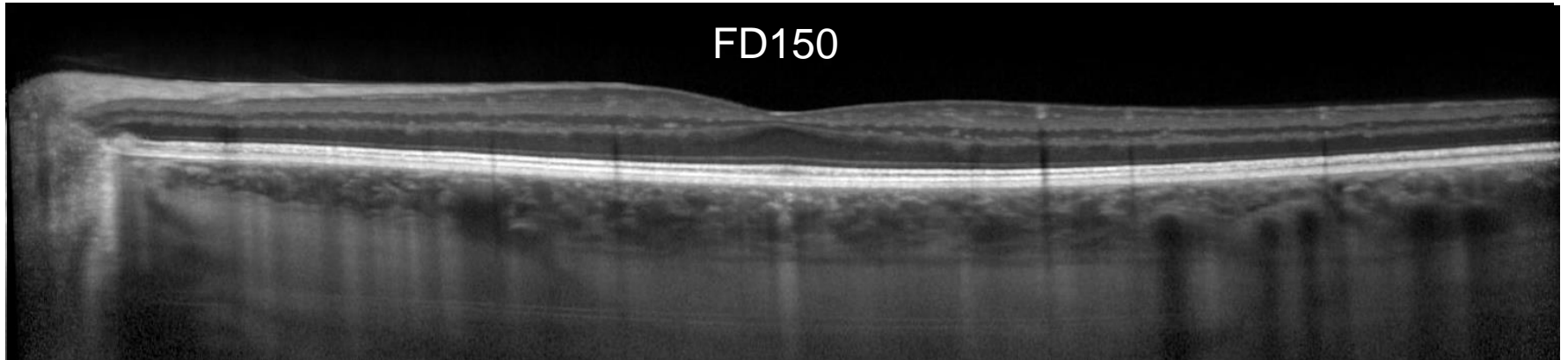
Internal Jugular Vein Pressure



(mean \pm standard deviation)



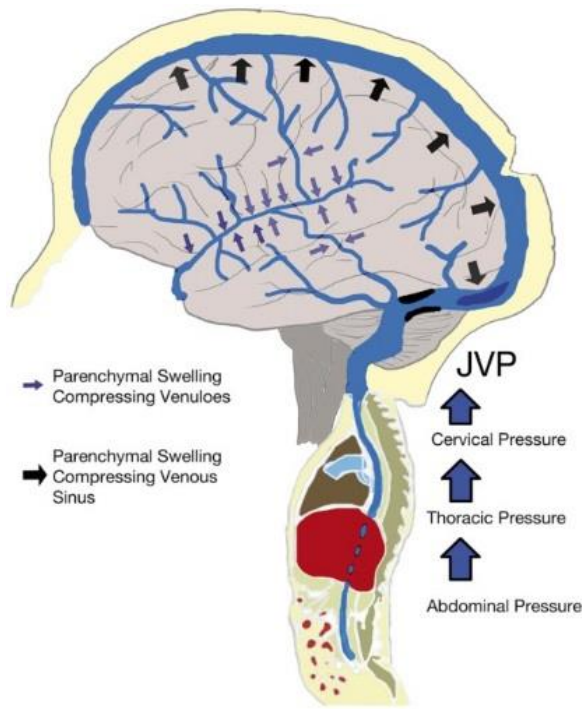
Fluid Shifts in the Eye





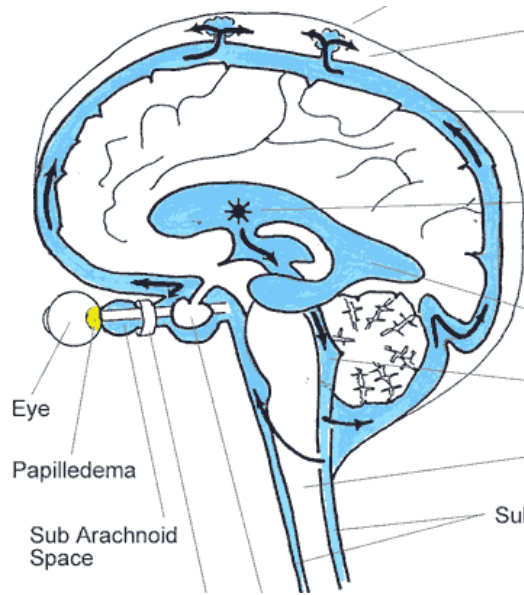
Fluid Shifts

Venous Outflow Restriction

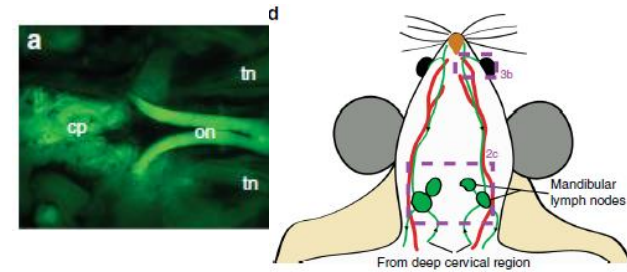


Wilson MH 2016

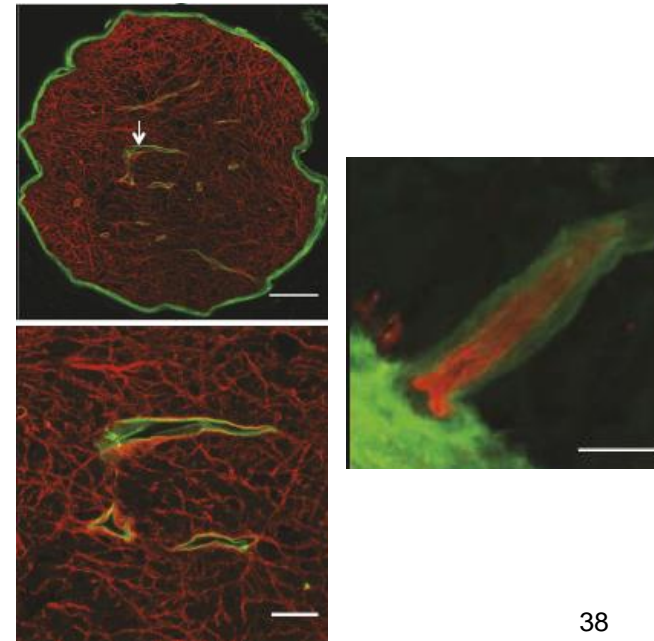
Cerebrospinal Fluid (CSF) Glymphatics & Lymphatics




Kumar KN et al 2012



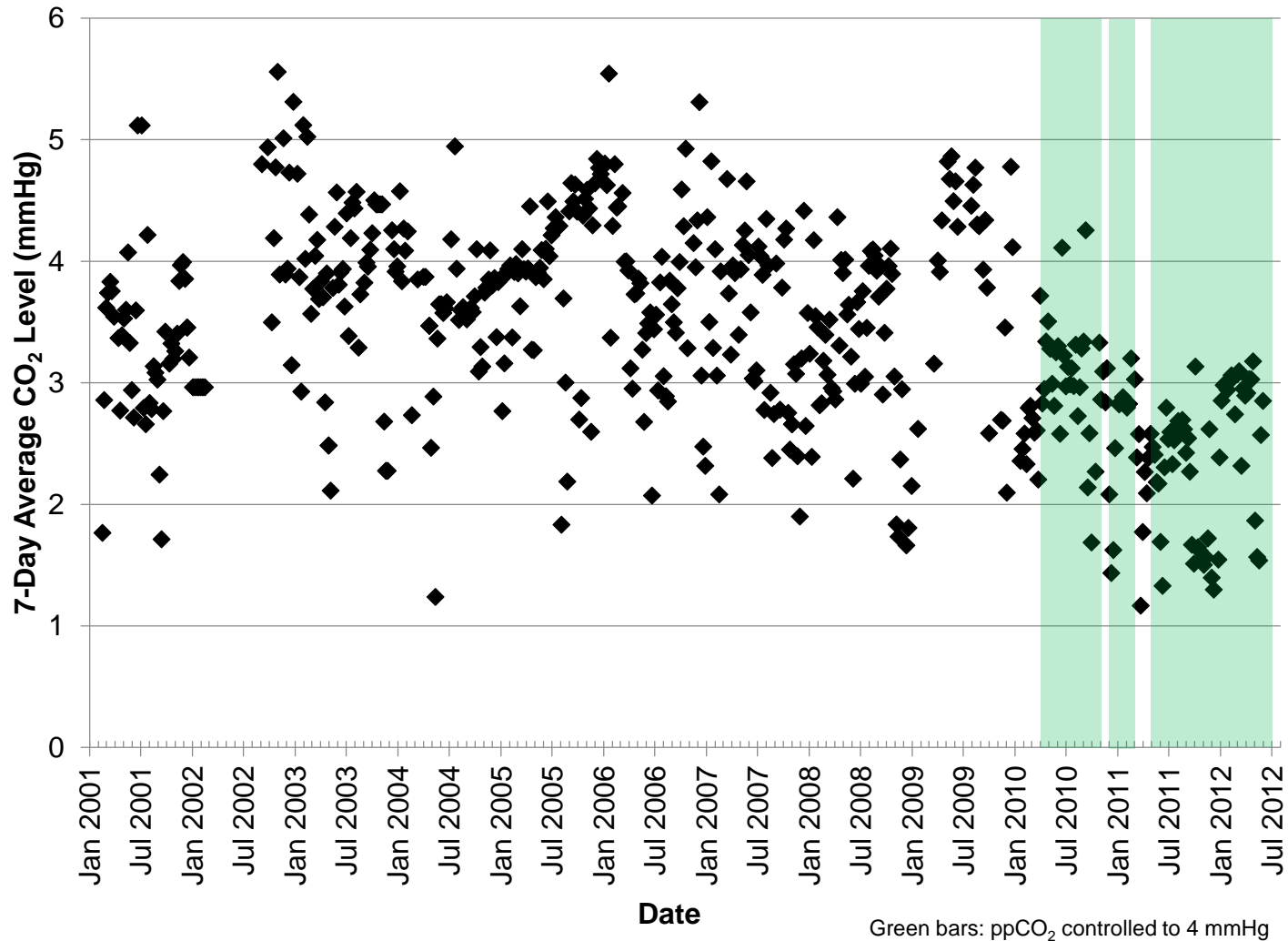
Ma Q et al 2017




Mathieu E et al 2017



Carbon Dioxide

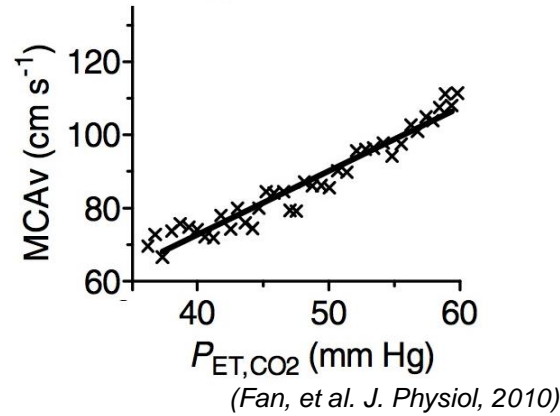




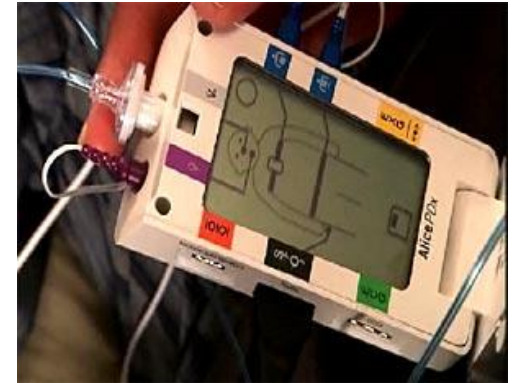
Carbon Dioxide



CO₂ Cerebrovascular Reactivity



Sleep



**Pre-Bed Rest
14 Days
(BR-14 to BR-1)**

**Bed Rest
30 Days
(BR1 to BR30)**

**Post-Bed Rest
14 Days
(BR+0 to BR+14)**

**Ambulatory +
Room Air**

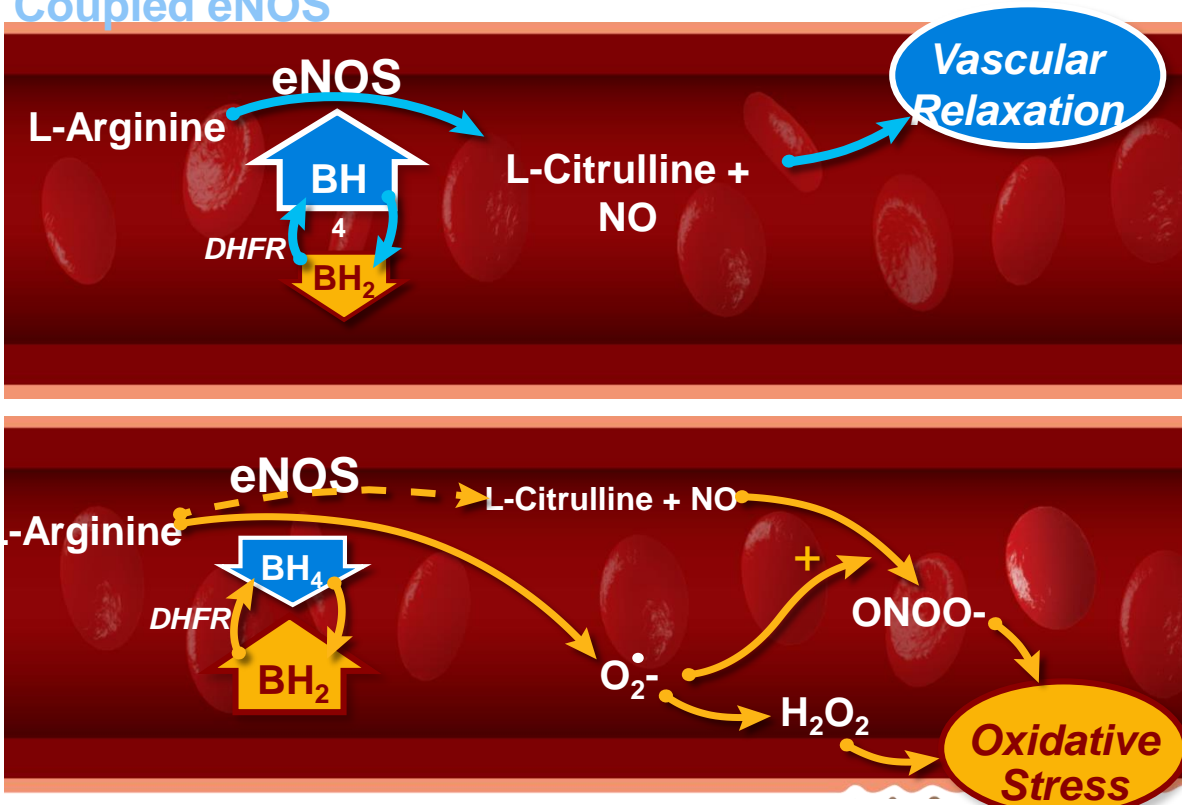
**6° HDT BR +
0.5% CO₂**

**Ambulatory +
Room Air**



Genetics

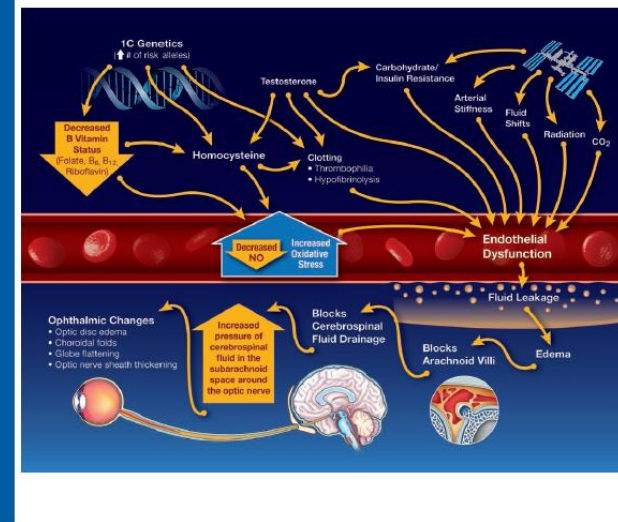
Coupled eNOS



Uncoupled eNOS


THE FASEB JOURNAL

The Journal of the Federation of American Societies for Experimental Biology • September 2017 • Volume 31 • Number 9

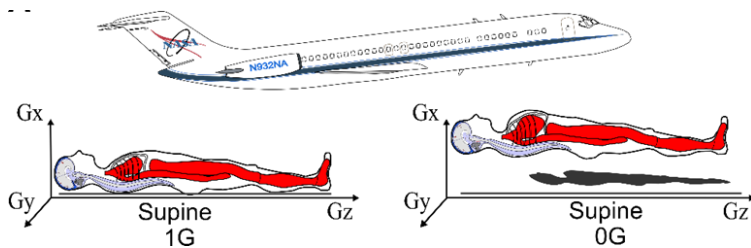
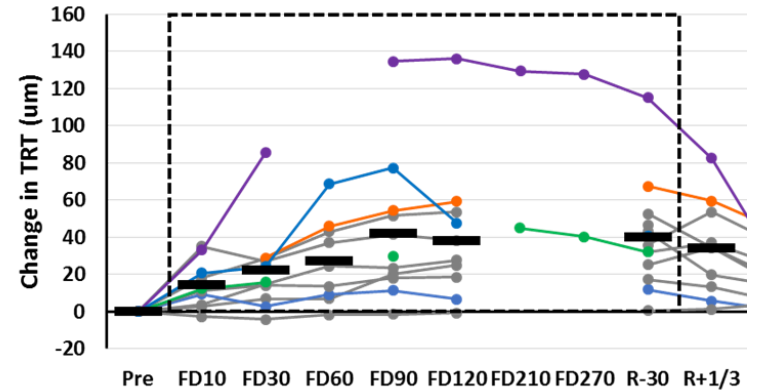
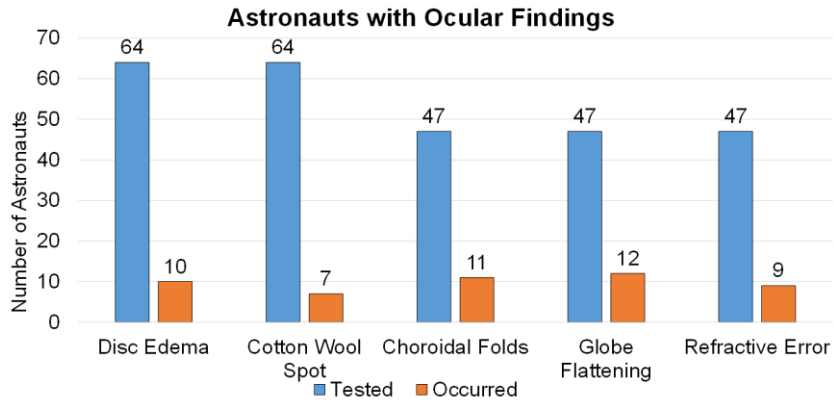


Multiple-hit hypothesis shows how genetics of the enzymes of the 1-carbon metabolic pathway are proposed to be associated with astronaut ophthalmic syndrome. See page 3746.





Summary



B vitamins

