

Dynamic Cerebral Autoregulation in Acute Lacunar and Middle Cerebral Artery Territory Ischemic Stroke

Rogier V. Immink, MD; Gert A. van Montfrans, MD, PhD; Jan Stam, MD, PhD;
John M. Karemaker, MD, PhD; Michaela Diamant, MD, PhD; Johannes J. van Lieshout, MD, PhD

Background and Purpose—We addressed whether dynamic cerebral autoregulation (dCA) is affected in middle cerebral artery (MCA) territory (MCAS) and lacunar ischemic stroke (LS).

Methods—Blood pressure (MAP) and MCA velocity (V) were measured in 10 patients with large MCAS (National Institutes of Health Stroke score, 17 ± 2 ; mean \pm SEM), in 10 with LS (score, 9 ± 1), and in 10 reference subjects. dCA was evaluated in time (delay of the MCA V_{mean} counter-regulation during changes in MAP) and frequency domains (cross-spectral MCA V_{mean} -to-MAP phase lead).

Results—In reference subjects, latencies for MAP increments (5.3 ± 0.5 seconds) and decrements (5.6 ± 0.5 seconds) were comparable, and low frequency MCA V_{mean} -to-MAP phase lead was 56 ± 5 and $59 \pm 5^\circ$ (left and right hemisphere). In MCAS, these latencies were 4.6 ± 0.7 and 5.6 ± 0.5 seconds in the nonischemic hemisphere and not detectable in the ischemic hemisphere. In the unaffected hemisphere, phase lead was $61 \pm 6^\circ$ versus $26 \pm 6^\circ$ on the ischemic side ($P < 0.05$). In LS, no latency and smaller phase lead bilaterally (32 ± 6 and $33 \pm 5^\circ$) conformed to globally impaired dCA.

Conclusions—In large MCAS infarcts, dynamic cerebral autoregulation was impaired in the affected hemisphere. In LS, dynamic cerebral autoregulation was impaired bilaterally, a finding consistent with the hypothesis of bilateral small vessel disease in patients with lacunar infarcts. (*Stroke*. 2005;36:2595-2600.)

Key Words: cerebral circulation ■ spectral analysis ■ ultrasonography

Cerebral blood flow (CBF) is maintained by both fast- and slow-acting regulatory mechanisms spanning the prevailing demands of CBF in everyday life. Static cerebral autoregulation (CA) reflects the overall efficiency, whereas dynamic CA (dCA) refers to the ability to restore CBF in the face of a sudden change in perfusion pressure, that is, the delay of CA. Acute ischemic stroke is often associated with a temporarily elevated blood pressure (BP) returning to pre-stroke values within days.¹ Adequate BP management is of importance, considering CA impairment in penumbral tissue. Thus, in this setting, CBF is likely to depend on cerebral perfusion pressure or BP. With global CBF detected by cerebral ⁸⁵Kr and ¹³³Xe clearance, static CA in patients with acute ischemic stroke was demonstrated to be impaired.²⁻⁴ In patients with large unilateral middle cerebral artery territory stroke (MCAS), a transient BP rise resulted in increased MCA velocity (V) on the affected side only, suggesting 1-sided impaired static CA.⁵ In minor MCAS, dCA was found not to be relevantly disturbed.⁶ In contrast, bilateral dCA impairment was reported but without accounting for the type of stroke.⁷⁻⁹ This study determined bilateral dCA in 2 distinct subtypes of acute ischemic stroke, that is, large MCA

territory stroke and in lacunar stroke of the basal ganglia (LS) and in reference subjects (RS).

Methods

Subjects

Ten patients with a first occurrence of MCAS and 10 patients with a first occurrence of LS were included in this study. Ischemic stroke was defined as a sudden onset of a nonconvulsive and focal neurological deficit persisting for >24 hours without signs of a cerebral hemorrhage on computed tomography (CT) scan. Patients were excluded from the study in case of a diminished consciousness (Glasgow Coma Scale <10), an inadequate acoustic window, absence or insufficient quality of one of the MCA V signals, atrial fibrillation, or significant carotid stenosis (>70%). After admission to the stroke unit, stroke severity was quantified (National Institutes of Health Stroke Scale; maximal 42-point score) and antihypertensive medication withdrawn (Table 1).

An ischemic MCAS was diagnosed by neurological examination and CT scan. Six of 10 CT scans showed early signs of MCA infarction, and none revealed leukoaraiosis or hemorrhage. We diagnosed LS when a LS (pure motor stroke [in 4 patients], pure sensory stroke [in 1 patient], sensorimotor stroke [in 1 patient], ataxic hemiparesis [in 4 patients], or dysarthria [none]) was present. A CT served to exclude a hemorrhagic cause. A unilateral lacunar lesion was present in 6 of 10 CT scans made within 3 hours after

Received March 7, 2005; final revision received August 5, 2005; accepted September 1, 2005.

From the Cardiovascular Research Institute Amsterdam (R.V.I., G.A.M., J.M.K., J.J.v.L.), Departments of Physiology (R.V.I., J.M.K.), Anesthesiology (R.V.I.), Internal Medicine (G.A.M., J.J.v.L.), and Neurology (J.S.), Academic Medical Center, University of Amsterdam, and Department of Endocrinology/Diabetes Center (M.D.), Free University Medical Center, Amsterdam, the Netherlands.

Correspondence to Johannes J. van Lieshout, Department of Internal Medicine, Medium Care Unit, Rm F7-205, Academic Medical Center, University of Amsterdam, PO Box 22700, 1100 DE Amsterdam, the Netherlands. E-mail j.j.vanlieshout@amc.uva.nl

© 2005 American Heart Association, Inc.

Stroke is available at <http://www.strokeaha.org>

DOI: 10.1161/01.STR.0000189624.06836.03

TABLE 1. Subject Characteristics

Characteristic	References, n=10	MCAS, n=10	LS, n=10
Male:Female	5:5	5:5	8:2
Age, y	57±2	59±5	63±3
Weight, kg	72±4	83±7	81±3
Length, cm	173±3	172±4	176±2
Infarct side, L:R		6:4	4:6
NIHSS		17±2*	9±1
History of:			
Hypertension		6	7
Diabetes mellitus		3	4
Hyperlipidemia		2	7
Admission:			
Heart rate, min ⁻¹		86±9	78±5
Systolic BP, mm Hg		166±9	178±16
Mean BP, mm Hg		116±4	121±11
Diastolic BP, mm Hg		86±3	93±9
Glucose, mmol/L ⁻¹		5.30±1.20	6.60±0.49
Cholesterol-total, mmol/L ⁻¹		5.18±0.38	6.52±0.40
Cholesterol-HDL, mmol/L ⁻¹		1.01±0.10	1.23±0.12
Cholesterol-LDL, mmol/L ⁻¹		3.08±0.27	3.41±0.37
Triglycerides, mmol/L ⁻¹		2.09±0.36	2.28±0.39
β blocker		2	5
ACE-inhibitor		2	1
ATIIRA		0	2
Diuretic		2	1
Cholesterol-lowering drug		1	4
Glucose-lowering drug		3	4

L:R indicates left vs right sided infarct; NIHSS, National Institutes of Health Stroke Scale; ACE, angiotensin-converting enzyme; ATIIRA, angiotensin II receptor antagonist. * $P<0.05$ vs lacunar stroke.

hospital admission. Four patients had CT evidence of leukoaraiosis, suggestive of subcortical arteriosclerotic encephalopathy. In 4 patients, no lacunar lesion was observed on the CT scan; on MRI scanning made 3 days after admission, a lacunar lesion infarct was present in 2 of them.

The RS had no history of cardiovascular disease and did not use any medication. Subjects, or a direct relative, received verbal and

written explanation of the objectives and techniques of measurements and risks associated with the study. Written informed consent was provided in accordance with the Helsinki Declaration. The study protocol was approved by the medical ethics committee of the Academic Medical Center, University of Amsterdam, the Netherlands (MEC 00/061).

Protocol and Measurements

Measurements were performed at the stroke unit between 8:00 and 11:00 PM within 72 hours after onset of stroke with the patients in supine position, in a quiet and dimly lit room to minimize arousal. RS were studied at the same time of the evening ≥ 2 hours after a light meal without caffeine-containing beverages. Recordings were obtained for ≥ 15 minutes. Brachial BP was measured before the measurements. Finger BP was measured (Portapres M2; Netherlands Organization for Applied Scientific Research, Biomedical Instrumentation, TNO-BMI) with the cuff applied to the midphalanx of the middle finger of the nonparalytic hand at heart level. To detect changes in BP correctly, a built-in expert system (Physiocal) tracked the unloaded diameter of the finger artery to establish and to adjust the arterial unloaded volume.¹⁰ The transcranial Doppler-derived blood V was measured in the proximal segments of the left and right MCA (DWL Multidop X4). Insonation with a 2.5-MHz probe located the MCA on the nonaffected side. Then, the patency of the insonated vessel was evaluated more proximally. Once the internal carotid artery bifurcation was identified, the velocity signal was optimized with forward and reversed V set at equal intensity. We checked the patency of the carotid arteries by Doppler imaging with a 4.5- MHz to 5.5-MHz transducer (Hewlett Packard SONOS 2000). Next, we located the MCA on the affected side, and waveform and systolic flow acceleration were compared with those on the nonaffected side. In case of a blunted waveform, patients were excluded from the study. The probe was secured with a headband (Mark 600, Spencer Technologies). End-tidal CO tension (Pet_{co2}) was monitored by a sampling infrared capnograph (Datex Normocap 200).

Data Analysis

Finger BP, MCA V spectrum envelope, and Pet_{co2} were A/D 100-Hz converted and stored. Mean arterial pressure (MAP) and MCA V_{mean} were the integral over 1 beat, and heart rate was taken from the pressure interval. MAP and MCA V_{mean} data were interpolated and resampled for time-domain dCA analysis. We selected manually upward and downward BP transients lasting ≥ 10 seconds at stable Pet_{co2}. All of the 10-second episodes per 15 minutes of tracing were isolated, and averaged curves of all of the 10-second upward and downward BP transients were plotted. dCA is considered adequate with MCA V_{mean} remaining stable during a change in MAP, apart from ≈ 5 -second delay, and impaired when MCA V_{mean} follows MAP passively.¹¹ Frequency domain analysis of dCA was performed as reported.¹¹ In short, for examination of dCA in the frequency domain, a 2-minute tracing of beat-to-beat data of MAP

TABLE 2. BP and MCA Blood Velocity

Variable	Type	Brachial BP, mm Hg	Finger BP, mm Hg	MCA V _{mean} , cm/s ⁻¹	
				Nonischemic	Ischemic
Reference	Systolic	127±7	115±6	92±6	92±6
	Mean	95±4	78±3	61±3	61±3
	Diastolic	79±3	59±2	39±2	40±2
MCAS	Systolic	143±9	125±7	86±9	90±10
	Mean	103±5	79±5	51±6	56±6
	Diastolic	83±3	59±5	30±3*#	39±4
LS	Systolic	156±10*	145±8*	86±5	84±6
	Mean	111±8	89±5	53±4	52±4
	Diastolic	88±8	61±5	32±3*	31±3*

* $P<0.05$ vs reference; # $P<0.05$ vs ischemic side.

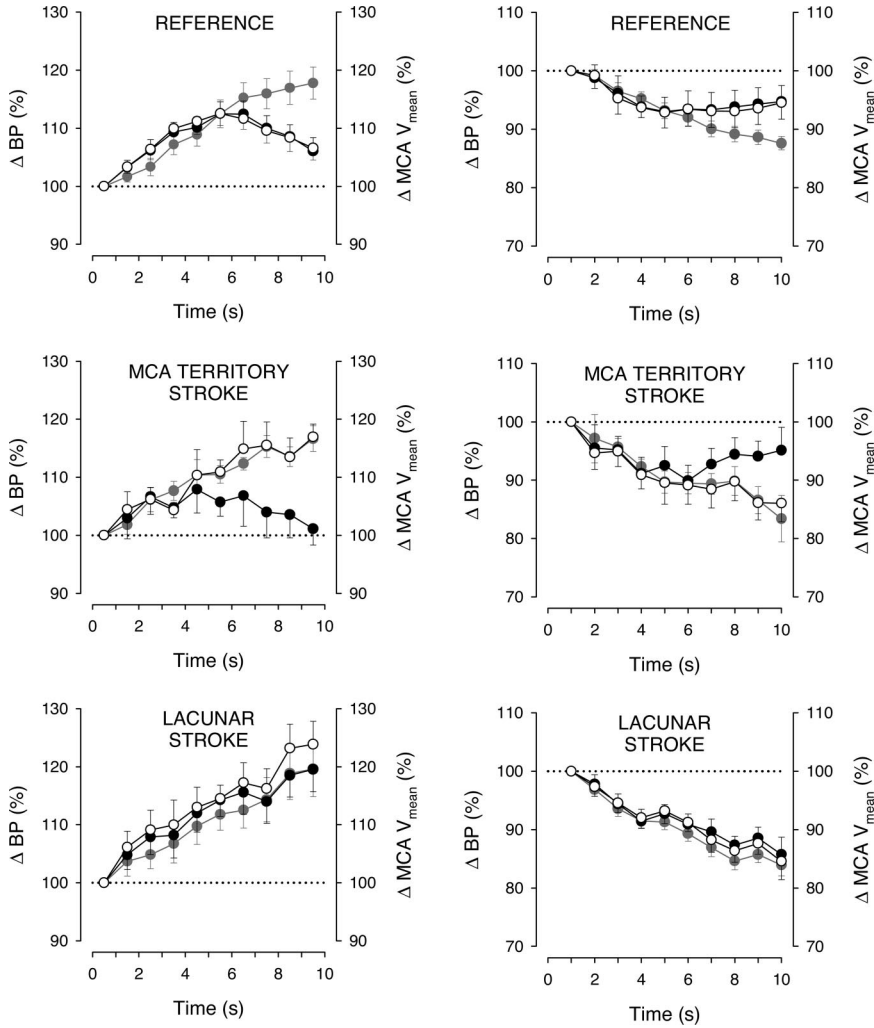


Figure 1. MCA velocity during a change in blood pressure in RS and in patients with large MCA territory and lacunar stroke; grey circles (all panels): percentage change in blood pressure (Δ BP); top: percentage changes in left (\circ) and right (\bullet) mean MCA blood velocity (Δ MCA V_{mean}); middle and bottom: ischemic (\circ) and nonischemic (\bullet) hemisphere. Data are mean \pm SEM.

and MCA V_{mean} was spline interpolated and resampled at 4 Hz. With discrete Fourier transform, the MAP and MCA V_{mean} variability was expressed as the integrated areas in the very low frequency (LF; 0.02 to 0.07 Hz), low frequency (LF; 0.07 to 0.15 Hz), and the high

frequency (HF; 0.15 to 0.3 Hz) ranges. Blood pressure fluctuations in the HF range are induced mainly by respiration, whereas those in the LF range are independent of such influence and reflect primary baroreflex activity. Furthermore, the very LF range of both flow and

TABLE 3. Variability in BP and MCA Blood Velocity

Variable	MAP Variability, mm Hg/Hz ²	MCA V_{mean} Variability ($\text{cm/s}^{-1}/\text{Hz}^2$)		Coherence	
		Nonischemic	Ischemic	Nonischemic	Ischemic
Reference, n=10					
VLF	8.5 \pm 2.4	6.0 \pm 1.3	6.1 \pm 1.4	0.55 \pm 0.04	0.55 \pm 0.04
LF	4.0 \pm 0.8	2.1 \pm 0.4	2.2 \pm 0.5	0.71 \pm 0.04	0.72 \pm 0.03
HF	0.8 \pm 0.2	1.2 \pm 0.3	1.3 \pm 0.3	0.55 \pm 0.04	0.54 \pm 0.04
MCAS, n=10					
VLF	13.8 \pm 3.9		5.5 \pm 2.0 6.5 \pm 1.6	0.54 \pm 0.07	0.63 \pm 0.06
LF	5.0 \pm 1.7		1.7 \pm 0.3 2.3 \pm 0.5	0.56 \pm 0.08	0.61 \pm 0.04
HF	3.5 \pm 0.9		2.9 \pm 0.8 2.1 \pm 0.4	0.55 \pm 0.06	0.54 \pm 0.06
LS, n=10					
VLF	31.1 \pm 13.3*		6.9 \pm 2.7 9.3 \pm 3.9	0.62 \pm 0.07	0.65 \pm 0.07
LF	4.5 \pm 1.1		1.2 \pm 0.2 1.6 \pm 0.4	0.78 \pm 0.02	0.72 \pm 0.05
HF	2.0 \pm 0.5		1.1 \pm 0.3 1.2 \pm 0.5	0.64 \pm 0.03	0.59 \pm 0.04

MAP indicates mean arterial pressure; VLF, very low frequency. * P <0.05 vs reference.

pressure variability appears to reflect multiple physiological mechanisms, which confound interpretation. Thus, the LF range was used to identify dCA. From the MAP-MCA V_{mean} cross-spectrum, transfer function gain ($[cm/s^{-1}]/mm\ Hg^{-1}$) and MCA V_{mean} -to-MAP phase lead (degrees) were calculated. The transfer function gain for MAP and MCA V_{mean} (in percentage change in cm/s^{-1} percentage change in mm Hg) was normalized to account for intersubject variability.¹¹ The cutoff value for preserved CA depends on the frequency range used. We consider a phase lead $>50^\circ$ for the LF range to represent preserved CA.¹¹ With dCA impaired, as in patients with carotid artery obstruction¹² or malignant hypertension,¹¹ phase lead decreases to as low as $\approx 30^\circ$.

Statistical Analysis

Data were mean \pm SEM or median and range. Changes in systemic and cerebral hemodynamics were examined by Kruskal-Wallis nonparametric ANOVA. Significant changes were located with the Wilcoxon signed-rank test. Differences in dCA between the ischemic versus the nonischemic hemisphere and patients versus RS were examined by nonparametric tests. $P < 0.05$ was considered to indicate statistical significance.

Results

Subjects

Age, weight, and patient height did not differ between groups. On admission, the National Institutes of Health Stroke Scale was higher in MCAS, and BP was comparable (Table 1). At the time of the study, BP was lower in both groups (Table 2). In MCAS but not in LS, MCA V tended to be higher in the ischemic hemisphere ($P = 0.08$).

Time Domain

In the 15-minute tracings, 2 to 10 episodes of spontaneous MAP increases and 2 to 9 decreases of comparable magnitude

occurred in RS ($18 \pm 3\%$ and $-12 \pm 1\%$), MCAS ($17 \pm 2\%$ and $-16 \pm 4\%$), and LS ($20 \pm 4\%$ and $-16 \pm 2\%$). In RS, CA latency was 5.3 ± 0.5 seconds for MAP increments and 5.6 ± 0.5 seconds for decrements (Figure 1). In MCAS, these latencies were 4.6 ± 0.7 and 5.6 ± 0.5 seconds in the nonischemic hemisphere and not detectable in the ischemic hemisphere. In LS, MCA V_{mean} passively followed MAP in both hemispheres.

Frequency Domain

In RS, LF MCA V_{mean} -to-MAP phase lead was $56 \pm 5^\circ$ (left hemisphere) and $59 \pm 5^\circ$ (right hemisphere). In MCAS, phase lead was lower at the ischemic ($26 \pm 6^\circ$; range, 10 to 50° ; $P < 0.05$) versus nonischemic side ($61 \pm 6^\circ$; range, 17 to 73°) with phase lead $>50^\circ$ in 6 patients and with 50° phase lead in 1 patient (Table 3). In LS, LF phase lead was reduced bilaterally (nonischemic: $32 \pm 6^\circ$; range, 5 to 49° versus ischemic hemisphere: $33 \pm 5^\circ$; range, 6 to 54° ; $P < 0.05$), and gain did not differ between the hemispheres (Figure 2).

Discussion

This study determined dynamic cerebral autoregulatory capacity in the time and frequency domain in 2 main subtypes of acute ischemic stroke: large MCAS and lacunar stroke. The main finding is that in acute MCAS, dCA is affected at the ischemic side only, whereas in acute LS, dCA is impaired bilaterally.

CA characterizes cerebral artery ability to modulate arterial wall smooth muscle tone, maintaining CBF. The latency in dCA as derived from spontaneous MAP decreases provides confirmatory information regarding impaired CA, as well as

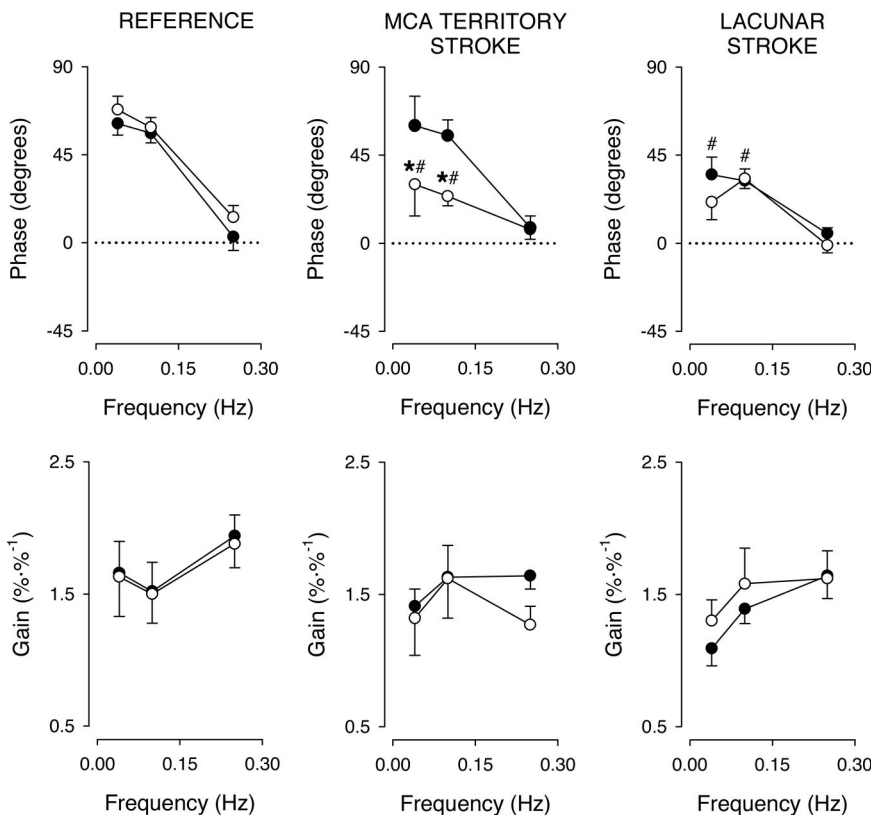


Figure 2. MAP to MCA V_{mean} cross-spectral phase difference and transfer function gain. Left: left hemisphere (○) and right hemisphere (●); middle and right: ischemic (○) and nonischemic hemisphere (●). Data are mean \pm SEM; # $P < 0.05$ versus reference; * $P < 0.05$ versus nonischemic side.

produced data akin to rapid thigh-cuff deflation as a stimulus for dCA.¹³

CA in stroke is controversial. In large MCAS, a transient rise in BP by phenylephrine raises MCA V_{mean} on the affected side only, indicating unilaterally impaired static CA.⁵ Several²⁻⁴ but not all⁷ reports suggest global static CA impairment. So far, global bihemispheric dCA impairment in acute and subacute stroke with preserved static CA has been reported without obvious differences between stroke subtypes.⁷⁻⁹ In subsequent studies, dCA appeared impaired bilaterally⁸ and remained so for at least 1 to 2 weeks,⁹ although this was not confirmed in minor MCAS.⁶ MCA territory infarcts are likely to result from embolism or large cerebral artery arterothrombosis with a considerable penumbral tissue volume. The present study extends the observations of unilaterally impaired static CA in MCAS⁵ to unilateral impairment of dCA.

In contrast to what was found in large MCAS, dCA was affected bilaterally in 1-sided LS. Intracranial small artery occlusion is the probable cause in the majority of LS.¹⁴ The penumbral volume in LS is usually small, and we consider dCA impairment in LS by the ischemic event itself unlikely.¹⁵ In syndromes with more extensive atherosclerosis of both extracranial and intracranial vessels, such as longstanding diabetes, CA is impaired.¹⁶ Cerebral small-vessel disease can produce isolated lacunar infarcts or diffuse white matter changes appearing as leukoaraiosis on a CT or MRI,^{17,18} which may explain why dCA in LS was affected on the nonischemic side as well. We examined CA capacity in acute stroke patients. In a follow-up study of patients experiencing minor MCAS, CA was still abnormal on the affected side but preserved on the normal side >2 months after stroke onset.¹⁹ We did not assess CA capacity before LS, but we speculate that a globally impaired dCA was already present.

In this study, CT scanning was the primary imaging technique used on admission. More ischemic strokes show up on diffusion-weighted imaging than on CT or conventional MRI in the first few hours. However, MRI can be difficult to use routinely in acute stroke and may not identify hyperacute intracerebral hemorrhage correctly, whereas CT scans are superior for differentiating ischemic from hemorrhagic stroke.^{18,20} In addition, lacunar syndromes are highly predictive for small deep infarcts on magnetic resonance. For that reason, brain MRI has even been considered redundant in the setting of a lacunar syndrome if supported by a CT that excludes nonischemic causes of stroke.²¹ An inherent difficulty of both CT and MRI is the ability to differentiate between acute and chronic lesions. In spite of the problem of relating lacunar syndromes to certain locations of lacunae,²² our finding that CA capacity was impaired also in the contralateral ("healthy") hemisphere in LS remains unchallenged.

Critical for the interpretation of the data are to what extent MCA V_{mean} reflects volume flow. The MCA V_{mean} is assumed to represent flow velocity in the center of the vessel, and, when flow is laminar, MCA V_{mean} follows ¹³³Xe clearance-determined CBF.²³ Thus, the constancy of vessel diameter links changes in MCA V to those in CBF. When nonlaminar blood flow in the affected cerebral arteries is considered, MCA

V_{mean} may change out of proportion to flow, and, therefore, the analysis was restricted to normally shaped Doppler signals.²⁴

CA was assessed after discontinuation of antihypertensive treatment, but a remaining biological effect cannot be excluded. However, also with β blockade, angiotensin-converting enzyme inhibition or angiotensin-receptor antagonist treatment interplay of CA has been confirmed. We did not create different steady-state BP levels, and quantification of static CA as established by Schwarz et al⁵ was not carried out. Impairment of static CA by pharmacological manipulation also affects dCA,²⁵ and we, therefore, consider that the impaired dCA found in this study suggests impairment of static CA as well.¹¹

Conclusions

In large MCAS infarcts, dCA was impaired in the affected hemisphere only. In LS, dCA was impaired bilaterally. The latter finding is consistent with the hypothesis of bilateral small vessel disease in patients with lacunar infarcts.

Acknowledgments

This study was sponsored in part by Dutch Heart Foundation grant no. 98.172.

References

1. Semplicini A, Maresca A, Boscolo G, Sartori M, Rocchi R, Giantin V, Forte PL, Pessina AC. Hypertension in acute ischemic stroke: a compensatory mechanism or an additional damaging factor? *Arch Intern Med.* 2003;163:211-216.
2. Agnoli A, Fieschi C, Bozzao L, Battistini N, Principe M. Autoregulation of cerebral blood flow. Studies during drug-induced hypertension in normal subjects and in patients with cerebral vascular diseases. *Circulation.* 1968;38:800-812.
3. McHenry LC Jr, West JW, Cooper ES, Goldberg HI, Jaffe ME. Cerebral autoregulation in man. *Stroke.* 1974;5:695-706.
4. Olsen TS, Larsen B, Herning M, Skriver EB, Lassen NA. Blood flow and vascular reactivity in collaterally perfused brain tissue. Evidence of an ischemic penumbra in patients with acute stroke. *Stroke.* 1983;14:332-341.
5. Schwarz S, Georgiadis D, Aschoff A, Schwab S. Effects of induced hypertension on intracranial pressure and flow velocities of the middle cerebral arteries in patients with large hemispheric stroke. *Stroke.* 2002;33:998-1004.
6. Reinhard M, Roth M, Guschlbauer B, Harloff A, Timmer J, Czosnyka M, Hetzel A. Dynamic cerebral autoregulation in acute ischemic stroke assessed from spontaneous blood pressure fluctuations. *Stroke.* 2005;36:1691-1696.
7. Dawson SL, Blake MJ, Panerai RB, Potter JF. Dynamic but not static cerebral autoregulation is impaired in acute ischaemic stroke. *Cerebrovasc Dis.* 2000;10:126-132.
8. Eames PJ, Blake MJ, Dawson SL, Panerai RB, Potter JF. Dynamic cerebral autoregulation and beat to beat blood pressure control are impaired in acute ischaemic stroke. *J Neurol Neurosurg Psychiatry.* 2002;72:467-472.
9. Dawson SL, Panerai RB, Potter JF. Serial changes in static and dynamic cerebral autoregulation after acute ischaemic stroke. *Cerebrovasc Dis.* 2003;16:69-75.
10. Bogert LW, Van Lieshout JJ. Non-invasive pulsatile arterial pressure and stroke volume changes from the human finger. *Exp Physiol.* 2005;90:437-446.
11. Immink RV, van den Born BJ, Van Montfrans GA, Koopmans RP, Karemaker JM, Van Lieshout JJ. Impaired cerebral autoregulation in patients with malignant hypertension. *Circulation.* 2004;110:2241-2245.
12. Diehl RR, Linden D, Lucke D, Berlit P. Phase relationship between cerebral blood flow velocity and blood pressure. A clinical test of autoregulation. *Stroke.* 1995;26:1801-1804.
13. Leftheriotis G, Preckel MP, Fizanne L, Victor J, Dupuis JM, Saumet JL. Effect of head-upright tilt on the dynamic of cerebral autoregulation. *Clin Physiol.* 1998;18:41-47.

14. Fisher CM. Lacunes: small, deep cerebral infarcts. *Neurology*. 1965;15:774–784.
15. Gan R, Sacco RL, Kargman DE, Roberts JK, Boden-Albala B, Gu Q. Testing the validity of the lacunar hypothesis: the Northern Manhattan Stroke Study experience. *Neurology*. 1997;48:1204–1211.
16. Mankovsky BN, Piolot R, Mankovsky OL, Ziegler D. Impairment of cerebral autoregulation in diabetic patients with cardiovascular autonomic neuropathy and orthostatic hypotension. *Diabet Med*. 2003;20:119–126.
17. Hassan A, Hunt BJ, O'Sullivan M, Parmar K, Bamford JM, Briley D, Brown MM, Thomas DJ, Markus HS. Markers of endothelial dysfunction in lacunar infarction and ischaemic leukoaraiosis. *Brain*. 2003;126:424–432.
18. Goetz CG, ed. *Textbook of Clinical Neurology*. 2nd ed. Orlando, FL: W.B. Saunders; 2003.
19. Novak V, Chowdhary A, Farrar B, Nagaraja H, Braun J, Kanard R, Novak P, Slivka A. Altered cerebral vasoregulation in hypertension and stroke. *Neurology*. 2003;60:1657–1663.
20. Wardlaw JM, Farrall AJ. Diagnosis of stroke on neuroimaging. *BMJ*. 2004;328:655–656.
21. Stapf C, Hofmeister C, Hartmann A, Marx P, Mast H. Predictive value of clinical lacunar syndromes for lacunar infarcts on magnetic resonance brain imaging. *Acta Neurol Scand*. 2000;101:13–18.
22. Schonewille WJ, Tuhim S, Singer MB, Atlas SW. Diffusion-weighted MRI in acute lacunar syndromes. A clinical-radiological correlation study. *Stroke*. 1999;30:2066–2069.
23. Clark JM, Skolnick BE, Gelfand R, Farber RE, Stierheim M, Stevens WC, Beck GJ, Lambertsen CJ. Relationship of ^{133}Xe cerebral blood flow to middle cerebral arterial flow velocity in men at rest. *J Cerebr Blood Flow Metab*. 1996;16:1255–1262.
24. Alexandrov AV, Demchuk AM, Wein TH, Grotta JC. Yield of transcranial Doppler in acute cerebral ischemia. *Stroke*. 1999;30:1604–1609.
25. Tiecks FP, Lam AM, Aaslid R, Newell DW. Comparison of static and dynamic cerebral autoregulation measurements. *Stroke*. 1995;26:1014–1019.