

S. K. Kamminga
C. Boer
A. A. Rijkeboer
M. A. Paul
A. Vonk Noordegraaf
R. J. Strack van Schijndel

Occult pleural cryptococcosis in an immunocompromised patient

Accepted: 16 October 2008
Published online: 1 November 2008
© The Author(s) 2008. This article is published with open access at Springerlink.com

Sir: Cryptococcosis is a rare opportunistic, invasive, fungal, life-threatening infection, which occurs in both immunocompetent and immunocompromised patients. In immunocompromised patients, the signs of cryptococcosis can easily be confused by the symptoms of the primary disease, which may delay adequate treatment [1].

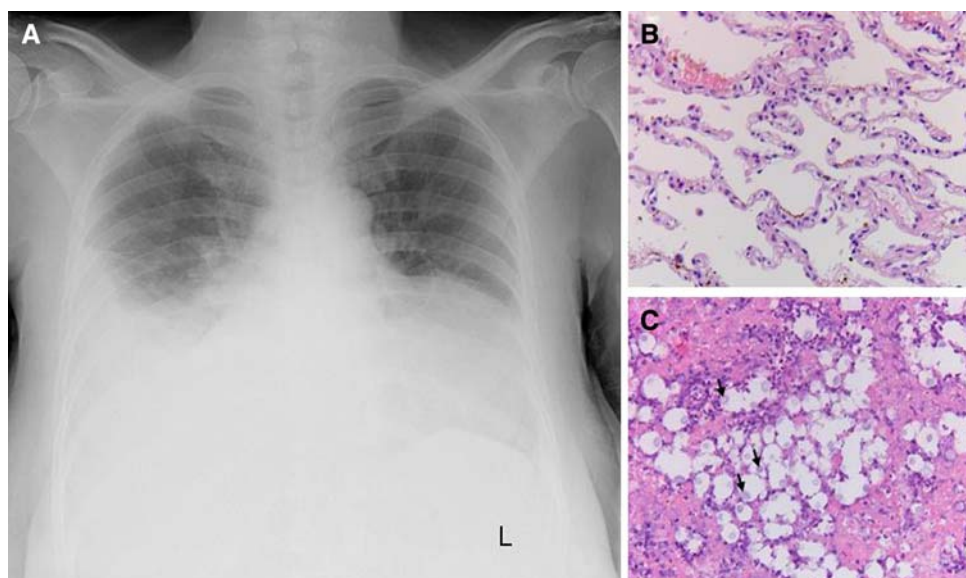
We recently treated a 47-year-old woman with a thymoma WHO type

B1 in the left hemithorax treated with three cycles of cisplatin/etoposide. Simultaneously, she developed a recurrent right-sided pleural effusion, which was drained four times and tested by an India ink and gram-stained smear, bacterial culturing, Cryptococcus serum and pleural punctuate antigen testing and a cytological stain, which were all negative for microorganisms including *Cryptococcus neoformans*. The bronchoalveolar lavage (BAL) material was also negative. The transudate contained lymphocytes and mesothelial cells. Eight days following the last cycle of chemotherapy, the patient was admitted because of fever, headache, neck pain, and cognitive changes during chemotherapy-induced pancytopenia. Three months after pleural effusion development, *C. neoformans* meningitis was diagnosed in the cerebral spinal fluid. The infection was successfully treated with amphotericin B (0.7 mg/kg/day) and flucytosine (100 mg/kg/day) for 2 weeks, followed by 8 weeks amphotericin B (0.7 mg/kg/day) with flucanazole (800 mg/kg/day). Despite the diagnosis of meningeal

cryptococcosis, pleural abnormalities remained attributed to the thymoma. Two weeks after cryptococcosis diagnosis, the patient underwent surgery for staging. Histology of the right middle lobe and pleura revealed a granulomatous necrotizing infection with *C. neoformans* (Fig. 1). One month later, a thymectomy was performed with partial pericardectomy, followed by ICU admission for 1 month.

In summary, our patient showed pulmonary cryptococcosis which, due to negative bacteriological testing, was not recognized as such. Pulmonary signs were, therefore, attributed to her thymoma. Despite repeated testing for fungi of the pleural effusion and BAL, these tests remained negative during a substantial part of the disease progression. Whether the initial pleural transudate was caused by cryptococcal infection or that secondary infection of pre-existent pleural fluid occurred, remains unclear. Microbiologic examination of specimens for cryptococci is not always conclusive: the appearance of cryptococci may vary considerably

Fig. 1 **a** Chest radiograph on the day preceding surgery showing significant pleural effusion on the right hemithorax and the thymoma in the left hemithorax. **b** Haematoxylin eosin (HE) staining of normal lung tissue of our patient (200×). **c** HE staining (200×) of lung tissue with *Cryptococcus neoformans* infiltration showing a granulomatous inflammation with dense infiltrates of lymphocytes, histocytes and plasma cells. Focal presences of cryptococcosis were seen throughout the tissue biopsy (see arrows, grey-blue colorization, variable diameters (4–20 μm), surrounded by a clear zone)



on gram-stained smears, and a positive smear should therefore always be confirmed by culture. Negative smears and cultures do not absolutely rule out cryptococcosis whilst antigen testing is false-negative in 40% of all extraneural cryptococcosis cases. Our findings underline that an accurate diagnosis of cryptococcosis remains problematic in patients in whom signs and symptoms are non-specific and often develop late in the course of infection [2–4]. The increased prevalence of fungal infections warrants a high clinical suspicion and urge for sensitive detection tools, thereby decreasing the incidence of a missed cryptococcosis diagnosis [4, 5].

In conclusion, pleural effusions should raise the possibility of a cryptococcal infection. Negative cultures and smears of the pleural fluid do not rule out this diagnosis. If central nervous system infection with cryptococcosis is present, one should be aware of the fact that the lung is the primary site of infection and concomitant intrapulmonary and pleural abnormalities should be evaluated with a high suspicion of cryptococcal infection.

Acknowledgments The authors thank Dr. Rob H. de Vries for his assistance (Department of Pathology, VU University Medical Center, Amsterdam, The Netherlands).

Open Access This article is distributed under the terms of the Creative Commons Attribution Noncommercial License which permits any noncommercial use, distribution, and reproduction in any medium, provided the original author(s) and source are credited.

References

1. Pukkila-Worley R, Mylonakis E (2008) Epidemiology and management of cryptococcal meningitis: developments and challenges. *Expert Opin Pharmacother* 9:551–560
2. Kontoyiannis DP, Peitsch WK, Reddy BT, Whimbey EE, Han XY, Bodey GP, Rolston KV (2001) Cryptococcosis in patients with cancer. *Clin Infect Dis* 32:145–150
3. Kawabata T, Matsuyama W, Higashimoto I, Koreeda Y, Eiraku N, Kawabata M, Osame M (2004) Pleural cryptococcosis with idiopathic CD4 positive T-lymphocytopenia. *Intern Med* 43:977–981
4. Nei T, Enomoto T, Sakamoto T, Shingu A, Abe S, Usuki J, Azuma A, Kudoh S, Kawamoto M (2007) A case of secondary pulmonary cryptococcosis with pleural effusion involving type 1

allergy. *Nihon Kokyuki Gakkai Zasshi* 45:551–555

5. Barnes RA (2008) Early diagnosis of fungal infection in immunocompromised patients. *J Antimicrob Chemother* 61:3–6

S. K. Kamminga (✉) · C. Boer
Department of Anesthesiology,
VU University Medical Center,
De Boelelaan 1117,
1081 HV Amsterdam, The Netherlands
e-mail: s.kamminga@vumc.nl
Tel.: +31-20-4444386

A. A. Rijkeboer · R. J. Strack van Schijndel
Department of Intensive Care Medicine,
VU University Medical Center,
De Boelelaan 1117,
1081 HV Amsterdam, The Netherlands

M. A. Paul
Department of Thoracic Surgery,
VU University Medical Center,
De Boelelaan 1117, 1081 HV Amsterdam,
The Netherlands

A. Vonk Noordegraaf
Department of Pulmonology,
VU University Medical Center,
De Boelelaan 1117, 1081 HV Amsterdam,
The Netherlands