

University of Groningen

## Studies on management of squamous cell carcinoma of the lower lip

Gooris, P. J. J.

**IMPORTANT NOTE:** You are advised to consult the publisher's version (publisher's PDF) if you wish to cite from it. Please check the document version below.

*Document Version*

Publisher's PDF, also known as Version of record

*Publication date:*

2002

[Link to publication in University of Groningen/UMCG research database](#)

*Citation for published version (APA):*

Gooris, P. J. J. (2002). Studies on management of squamous cell carcinoma of the lower lip [S.l.]: [S.n.]

**Copyright**

Other than for strictly personal use, it is not permitted to download or to forward/distribute the text or part of it without the consent of the author(s) and/or copyright holder(s), unless the work is under an open content license (like Creative Commons).

**Take-down policy**

If you believe that this document breaches copyright please contact us providing details, and we will remove access to the work immediately and investigate your claim.

Downloaded from the University of Groningen/UMCG research database (Pure): <http://www.rug.nl/research/portal>. For technical reasons the number of authors shown on this cover page is limited to 10 maximum.



# Studies on Management of Squamous Cell Carcinoma of the Lower Lip

P.J.J. Gooris

**Studies on Management  
of Squamous Cell Carcinoma  
of the Lower Lip**

The research described in this thesis was performed at:  
Department of Oral and Maxillofacial Surgery, Groningen University Hospital  
Department of Surgery/Head and Neck Surgery, Groningen University Hospital  
Department of Oral and Maxillofacial Surgery, Amphia Hospital, Breda  
Dr. Bernard Verbeeten Radiotherapeutic Institute, Tilburg

Publication of this thesis was financially supported by:  
Straumann, Nieuwegein  
Specialistisch Laboratorium MFP Laverman, Arnhem  
Martin Nederland, Nieuwegein  
Voorlichtingsbureau voor artsen, Bilthoven  
Amphia Ziekenhuis Breda  
Styker Leibinger, Eindhoven  
Barneveld Schevers, Nieuwegein  
OZ zorgverzekeringen

Internet      <http://www.ub.rug.nl/eldoc/dis/medicine/p.j.j.gooris/>  
Cover        Cole Morgan: Minus One (oil on panel), 1999  
Printing     PlantijnCasparie, Eindhoven  
NUGI        742

# Stellingen

behorend bij het proefschrift


## **Studies on Management of Squamous Cell Carcinoma of the Lower Lip**

Groningen, 30 september 2002

P.J.J. Gooris



1. Indien lipkanker volgens een multidisciplinair opgestelde richtlijn wordt gestadiëerd en behandeld, is postoperatieve radiotherapie slechts in een zeer beperkt aantal gevallen noodzakelijk. (Dit proefschrift.)
2. De veronderstelling dat bij de beschikbaarheid van een richtlijn deze ook daadwerkelijk wordt gevolgd, is een misvatting; het opstellen is slechts het halve werk. (Dit proefschrift.)
3. Bij excisie van een plaveiselcelcarcinoom van de onderlip kan met behulp van peroperatief vriescoupeonderzoek van de sneevlakken de indicatie voor een latere reëxcisie of postoperatieve radiotherapie aanmerkelijk worden gereduceerd. (Dit proefschrift.)
4. Vrije sneevlakken bij histologisch onderzoek sluiten het optreden van een lokaal recidief niet uit. (Dit proefschrift.)
5. Voor chirurgische behandeling van aangetoonde halskliermetastasering in regio I van de hals, afkomstig van een plaveiselcelcarcinoom van de onderlip, volstaat een selectieve halsklierdissectie. (Dit proefschrift.)
6. In head and neck oncology, the recommended therapy still depends to a large extent on which door the patient enters. (Modified after Rodney R. Million, 1994.)
7. Het verzoek aan de kaakchirurg een apexresectie te verrichten aan een niet endodontisch voorbehandeld non-vitaal element moet als een verwerpelijk voorstel worden beschouwd.
8. Gedoogbeleid getuigt van politieke lafheid.
9. De ware manager komt en gaat zonder papieren.
10. De moeilijkheidsgraad van een onderwerp wordt bepaald door de kwaliteit van de uitleg.
11. Als het over mensen gaat, moet je je over niets verbazen.
12. Veelal komt strafrechtspraak tegemoet aan de rechten van de verdachte en niet aan de wensen van het slachtoffer.





RIJKSUNIVERSITEIT GRONINGEN

# **Studies on Management of Squamous Cell Carcinoma of the Lower Lip**

## **Proefschrift**

ter verkrijging van het doctoraat in de  
Medische Wetenschappen  
aan de Rijksuniversiteit Groningen  
op gezag van de  
Rector Magnificus, dr. F. Zwarts,  
in het openbaar te verdedigen op  
maandag 30 september 2002  
om 16.00 uur

door

**Petrus Johannes Jacobus Gooris**

geboren op 8 maart 1954  
te Oss

Promotores Prof.dr. J.L.N. Roodenburg  
Prof.dr. A. Vermeij, FACS

Referenten Dr. R. Otter  
Dr. J.G.A.M. de Visscher

Beoordelingscommissie Prof.dr. F.W.J. Albers  
Prof.dr. H.J. Hoekstra  
Prof.dr. R. Koole

Paranimfen

I.M.M. van Nuland

J.M.A. de Laet

Copyright © by P.J.J. Gooris, Breda, The Netherlands.

No part of this thesis may be reproduced, stored in a retrieval system, or transmitted in any form or by any means, without prior written permission of the author, or, when appropriate, of the publishers of the publications.

*Aan Christel  
Voor Pim, Anne-Sophie, Haye*



# Contents

# Contents

<b>Chapter 1</b>	Introduction and aim of the study	1
1.1	Epidemiology	
1.1.1	Incidence	
1.1.2	Etiology	
1.2	Clinical aspects	
1.2.1	Primary tumor	
1.2.2	Regional metastases	
1.3	Evaluation and staging	
1.4	Treatment	
1.4.1	Treatment of the primary tumor	
1.4.2	Treatment of the neck	
1.5	Follow-up	
1.6	Prognosis	
1.7	Aim of the study	
<b>Chapter 2</b>	Regional guideline for diagnosis and treatment of squamous cell carcinoma of the lip: what is the level of compliance?	23
<b>Chapter 3</b>	Radiotherapy for cancer of the lip	39



Chapter 4	Carbon dioxide laser evaporation of leukoplakia of the lower lip	53
Chapter 5	Frozen section examination of the margins for resection of squamous cell carcinoma of the lower lip	67
Chapter 6	Surgical margins for resection of squamous cell carcinoma of the lower lip	79
Chapter 7	Supraomohyoid neck dissection in the management of cervical lymph node metastases of squamous cell carcinoma of the lower lip	89
Chapter 8	General discussion	103
Chapter 9	Summary	111
	Samenvatting (Summary)	119
	Dankwoord (Acknowledgements)	127
	Curriculum vitae	131



# **Chapter 1**

## **Introduction and Aim of the Study**



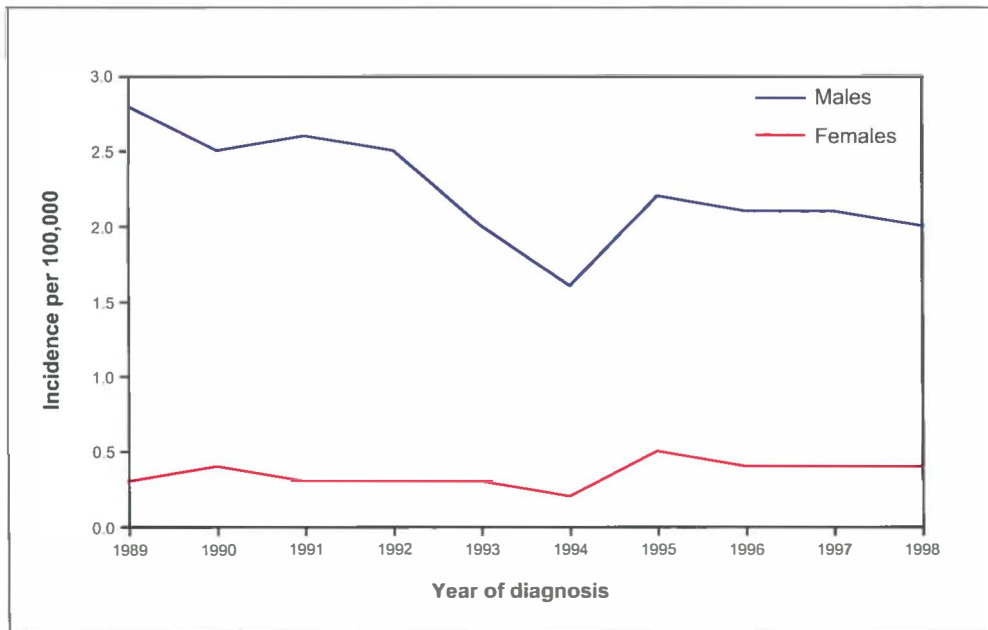
## 1.1 Epidemiology

### 1.1.1 Incidence

Cancers of the lip almost exclusively are squamous cell carcinomas. The vast majority originates on the exposed vermilion border of the lower lip, the transitional zone between oral labial mucosa and adjacent skin.<sup>1-5</sup>

During the period 1989-1998, the incidence of cancer of the lip in The Netherlands per 100,000 person years (ESR) ranged from 1.6-2.8 for males and from 0.2-0.5 for females (Fig. 1). Malignant tumors of the lip accounted for 0.4% for males and for 0.1% for females of all newly diagnosed tumors.<sup>6</sup>

During that same period, the incidence of cancer of the subsite lower lip was 1.9 for males and 0.24 for females per 100,000 individuals. Tables 1a and 1b present an overview of the incidence of lip cancer, differentiated by subsite and age for both males and females. The clinical TNM classification of squamous cell carcinoma of the lower lip (SCCLL) is shown in Table 2. The male to female ratio was 4.5:1.<sup>6</sup>



**Figure 1** *Incidence (per 100,000 person years, ESR) of patients with a squamous cell carcinoma of the lip per year in the Netherlands during the period 1989-1998.*  
*ESR: European Standardized Rate*

**Table 1a** *Distribution of incidence in male patients with squamous cell carcinoma of the lip, by subsite and age during the period 1989-1998 in the Netherlands.*

Subsite	n Sum	Rate per 100,000 persons per 10 years					ESR	WSR
		Age						
		15-29	30-44	45-59	60-74	75+		
Upper lip	98	-	0.02	0.19	0.50	0.90	0.14	0.09
Lower lip	1339	0.02	0.23	1.84	7.43	14.43	<b>1.90</b>	1.27
Overlapping	16	-	0.01	0.03	0.05	0.24	0.02	0.01
Commissure	15	-	-	0.02	0.10	0.14	0.02	0.01
Other/nos	28	-	0.01	0.03	0.10	0.48	0.04	0.02
<b>Total</b>	1496	0.02	0.27	2.11	8.18	16.19	2.12	1.40

ESR: European Standardized Rate

WSR: World Standardized Rate

nos: not otherwise specified

**Table 1b** *Distribution of incidence in female patients with squamous cell carcinoma of the lip, by subsite and age during the period 1989-1998 in the Netherlands.*

Subsite	n Sum	Rate per 100,000 persons per 10 years					ESR	WSR
		Age						
		15-29	30-44	45-59	60-74	75+		
Upper lip	76	-	0.02	0.08	0.29	0.59	0.08	0.05
Lower lip	235	-	0.03	0.27	0.78	2.07	<b>0.24</b>	0.16
Overlapping	2	-	-	-	0.01	0.02	0.00	0.00
Commissure	4	-	0.01	0.02	-	0.02	0.00	0.00
Other/nos	8	-	-	-	0.01	0.12	0.01	0.00
<b>Total</b>	325	-	0.06	0.37	1.09	2.82	0.33	0.21

**Table 2** *The clinical TNM classification of squamous cell carcinoma of the lower lip during the period 1989-1998 in the Netherlands.*

cTNM	T1	T2	T3	T4	Unknown	Total
Male	1012	126	6	3	192	1339
Female	181	19	0	1	34	235
<b>Total</b>	1193 (76%)	145 (9%)	6 (0.4%)	4 (0.2%)	226 (14.4%)	1574 (100%)

The age of onset for patients with cancer of the lip is predominantly between 50 and 85 years.<sup>1, 3-5, 7</sup> In the period 1989-1998, the mean age of patients in the Netherlands diagnosed with a SCCLL was for males 68 years (S.D. 13.07, median 69, range 18-97 years) and for females 71 years (S.D. 12.71, median 74, range 32-99 years).<sup>6</sup>

### 1.1.2 Etiology

A risk factor most commonly associated with the development of lip cancer is cumulative, life-time exposure to sunlight, particularly UVB.<sup>3, 8</sup> The everted aspect of the lower lip receives more sunlight than the caudally projected upper lip; therefore the lower lip is more frequently involved. Typically, many patients have had outdoor occupations. Especially the elderly white, fair-skinned male with outdoor employment is at risk for developing a carcinoma of the lower lip.<sup>1, 3-5, 8</sup>

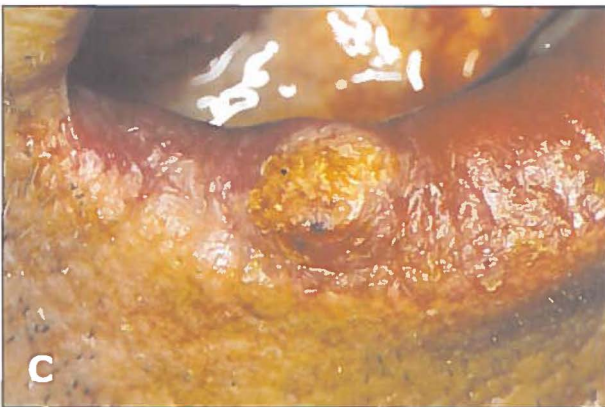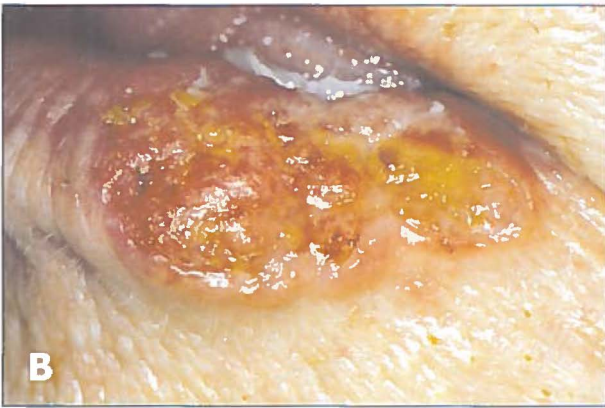
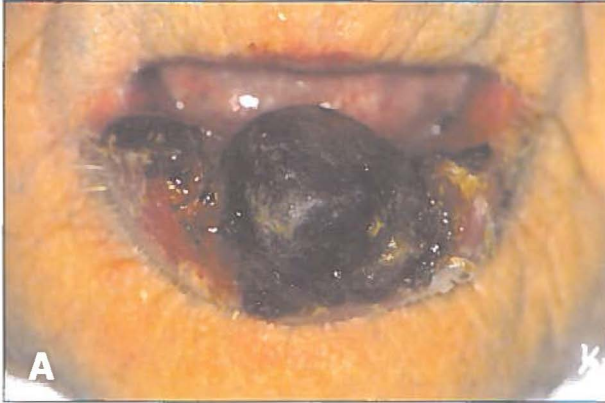Other reported risk factors, possibly of less importance, are the use of tobacco and endogenous factors such as race, familial and genetic predisposition.<sup>3, 5, 9</sup> Patients undergoing immunosuppressive therapy and patients with an immunodeficiency state may also have an increased susceptibility to the development of this neoplasm.<sup>10, 11</sup> Viruses, especially herpes simplex virus type 1 (HSV type 1) are thought to be causally related to cancer of the lip.<sup>12-14</sup>

## 1.2 Clinical aspects

### 1.2.1 Primary tumor

The clinical presentation of SCCLL may vary from an annoying nonhealing discrete, crusty lesion to an ulcer, often surrounded by an indurated area. Macroscopically, three types of lesions can be distinguished: exophytic, endophytic (ulcerative) and verrucous squamous cell carcinoma (Figure 2).<sup>5</sup> Advanced tumors may invade surrounding structures like skin, muscles, neural tissue or bone.<sup>15-18</sup> Complaints and clinical findings are then related to the invaded structures and consist of progressive irritation, recurrent bleeding, impairment of lip function, paresthesia or anesthesia of the lower lip and adjacent chin region or pathologic fractures.

Generally, cancer of the lower lip grows slowly; most tumors are readily visible, and therefore, the majority of the lower lip tumors are detected at an early stage.



**Figure 2**

- A Exophytic squamous cell carcinoma of the lower lip.*
- B Ulcerative squamous cell carcinoma of the lower lip.*
- C Verrucous squamous cell carcinoma of the lower lip.*



### 1.2.2 Regional metastases

SCCLL may spread to the regional lymph nodes. Factors that seem to correlate with an increased risk of cervical metastasis are the actual site of the tumor, the size of the primary tumor and the histologic grade of the tumor involved. For T1-T2 tumors the rate of regional metastases may vary between 5-15%.<sup>2, 5, 19, 23</sup>

Usually there is a predictable pattern of lymphatic spread to the cervical lymph nodes, which is related to the site of the primary tumor.<sup>24</sup> Although skip metastases may occur, it has been recognized that regional metastases associated with lower lip cancer are mainly located in the submental and submandibular lymph nodes. When the lateral aspect of the lower lip is involved, metastases are likely to develop in the ipsilateral submandibular lymph nodes whereas a midline malignancy may metastasize to the submental and/or to the submandibular lymph nodes on either side.<sup>24,25</sup>

## 1.3 Evaluation and staging

Adequate physical examination of the primary lip tumor and the neck is necessary for a correct staging of the extent of the malignancy. The International Classification of Diseases for Oncology (ICD-O) provides a system for coding neoplasms by topography and morphology and for indicating behavior. Code numbers are used to define sites and subsites for primary tumors of the lip (Table 3).<sup>26-28</sup>

Classification and staging follows the rules laid down by the Union Internationale Contre le Cancer in its TNM classification of malignant tumors (UICC 1987, 1992, 1997), that since 1987 corresponds with the system used by the American Joint Committee on Cancer (AJCC 1987, 1992, 1997) (Table 4).<sup>29-32</sup>

Clinical evaluation of local tumor spread and determination of the exact tumor dimension in cm is achieved by bimanual palpation. Sensory disturbance of the area innervated by the mental nerve is recorded. The neck is evaluated to rule out or detect the possible presence of regional metastases. Complete physical examination of the entire head and neck area is performed to exclude a synchronous second primary tumor.<sup>33-36</sup>

**Table 3** *Anatomical subsites of the lip.*

ICD-O	ICD-10	Subsites
140	C00	lip (excludes skin of lip)
140.0	C00.0	vermilion border of the upper lip
140.1	C00.1	vermilion border of the lower lip
140.6	C00.6	commissure of the lip
140.8	C00.8	overlapping lesion of the lip
140.9	C00.9	lip, not otherwise specified

The ICD-O is based on the ICD-9 (1976), the C00 codes are based on the ICD-10 (1990, 2000), used by the International Classification of Diseases for Oncology.<sup>26,28</sup>

**Table 4** *TNM classification for lip cancer according to the UICC/AJCC 1997.<sup>11</sup>*

TNM Classification	Description
<b>Primary tumor (T)</b>	
TX	Primary tumor cannot be assessed
T0	No evidence of primary tumor
Tis	Carcinoma in situ
T1	Tumor 2 cm or less in greatest dimension
T2	Tumor more than 2 cm but not more than 4 cm in greatest dimension
T3	Tumor more than 4 cm in greatest dimension
T4	Tumor invades adjacent structures, e.g., through cortical bone, inferior alveolar nerve, floor of mouth, skin of face
<b>Regional nodal involvement (N)</b>	
NX	Regional lymph nodes cannot be assessed
N0	No regional lymph node metastasis
N1	Metastasis in a single ipsilateral lymph node, 3 cm or less in greatest dimension
N2	Metastasis in single ipsilateral lymph node, more than 3 cm but not more than 6 cm in greatest dimension; or in multiple ipsilateral lymph nodes, none more than 6 cm in greatest dimension; or in bilateral or contralateral lymph nodes, none more than 6 cm in greatest dimension
N2a	Metastasis in a single ipsilateral lymph node, more than 3 cm but not more than 6 cm in greatest dimension
N2b	Metastasis in multiple ipsilateral lymph nodes, none more than 6 cm in greatest dimension
N2c	Metastasis in bilateral or contralateral lymph nodes, none more than 6 cm in greatest dimension
N3	Metastasis in a lymph node more than 6 cm in greatest dimension
<b>Distant metastasis (M)</b>	
MX	Distant metastasis cannot be assessed
M0	No distant metastasis
M1	Distant metastasis

It is then essential to obtain a histopathologic confirmed diagnosis of the primary tumor. Generally, an incisional biopsy including the transitional zone between suspect and normal tissue is performed. In case of a lip tumor smaller than 0.5 cm, an excisional biopsy seems justified which should include a margin of approximately 5 mm of healthy appearing tissue surrounding the tumor.<sup>36</sup> Control of these margins by frozen section examination is recommended.<sup>37-39</sup> This will reduce the potential need for a separate second surgical procedure or postoperative radiotherapy.

Imaging is performed to further evaluate the extent of the primary tumor, regional and distant metastases. The panoramic X-ray can be used to detect bone resorption adjacent to the course of the inferior alveolar nerve due to perineural spread. Because the tumor is easily accessible for inspection and palpation, CT or MRI do not evidently contribute to the T-classification, apart from the detection of possible perineural tumor spread. Evaluation and staging of the neck may require imaging techniques like CT, MRI, ultrasound and ultrasound guided fine needle aspiration cytology (USgFNAC) or positron emission tomography (PET).<sup>40-43</sup> Sentinel lymph node biopsy to determine occult cervical metastases has shown to be feasible in patients with a SCCLL who present with a larger tumor (T2) and none palpable regional lymph nodes.<sup>44,45</sup> To confirm distant lung metastases or detect a potential second primary lung tumor, a chest X-ray is obtained.

Distant, haematogenous metastasis associated with SCCLL without regional lymph node involvement is extremely rare.<sup>5, 20-22</sup>

## **1.4 Treatment**

### **1.4.1 Treatment of the primary tumor**

For the treatment of lip cancer either radiotherapy or surgery is most commonly recommended.<sup>1, 3, 7, 46-50</sup> Surgery offers the advantage of a rapid treatment and the availability of a specimen for histopathologic evaluation and margin examination. So, using surgery, the radicality of the tumor removal can be evaluated. The excision should include intraoperative frozen section examination of the margins until clear resection surfaces are confirmed.

Radiotherapy, as compared to surgery, has the advantage of being less invasive but may cause atrophy and tissue fibrosis. However, especially in larger tumors radiotherapy will result in a better functional and cosmetic post-treatment appearance of the lip as compared to surgery. Disadvantages however are the ab-

sence of a specimen for histologic examination and a prolonged treatment time. After radiation, the lip may become dry and more sensitive to environmental influences especially actinic radiation.<sup>5,36,51</sup> Because there seems to be an association between chronic exposure to ultraviolet light and the development of a skin or lip malignancy, there may be an increased risk for the development of a second primary lip tumor after radiotherapy of the lip. Younger patients will receive more cumulative life-time sunlight exposure. For this reason the guideline, formulated by the Comprehensive Cancer Centre Northern Netherlands, recommends that patients younger than 60 years of age may preferably be treated surgically.<sup>36,51</sup>

The actual choice of the type of treatment to be used depends on the TNM-classification of the disease, functional and cosmetic demands, and the age and condition of the patient involved: therefore the treatment should be individualized. Generally, in case of a T1 lip carcinoma, either surgical excision or radiotherapy provide comparable oncological results.<sup>3,5,46,52,53</sup> A T2 or T3 lip cancer may preferably be treated by radiotherapy in order to minimize functional and cosmetic deficits. An overview of the tumor-dose related radiotherapy is given in Table 5. In the presence of a T4 lip tumor, a combined treatment is indicated. The postoperative radiotherapy, minimal 60 Gy, 2 Gy per day, 5 fractions per week should start within 6 weeks after the surgical procedure.

**Table 5** Radiation therapy for squamous cell carcinoma of the lip, depending on the T-classification according to the guideline, formulated by the Comprehensive Cancer Centre Northern Netherlands 1998.

T-classification	Radiation therapy
T1	external beam radiation (orthovolt): minimal 125 kV minimal margin 0.5 cm small T1 (<1 cm): 12 x 400 cGy large T1 (>1 cm): 17 x 300 cGy or electrons 6 MeV with 0.5 cm onlay material; minimal margins 0.5 cm; 22 x 250 cGy interstitial radiation (brachytherapy <sup>192</sup> Ir): minimal 5500 cGy
T2, T3	external beam radiation (orthovolt): minimal 125 kV; 0.5-1 cm margins 17 x 300 cGy or electrons 6 MeV with 0.5 cm onlay material margins 0.5-1 cm; 22 x 250 cGy interstitial radiation (brachytherapy <sup>192</sup> Ir): minimal 5500 cGy
T4	external beam radiation (orthovolt): minimal 6000 cGy in 6 weeks

Precancerous lesions such as actinic cheilitis and leukoplakia, confirmed by biopsy, can generally be treated by vermilionectomy, CO<sub>2</sub> laser evaporation or cryo-surgery.<sup>54-56</sup>

Superficially expanding lesions such as carcinoma in situ and micro-invasive SCCLL, can be adequately treated by a lip-shave (vermilionectomy).<sup>57, 58</sup>. An alternative method for more superficially located lesions is Mohs' micrographic surgery.<sup>59-61</sup> This technique allows for histological examination of all resection margins during tumor removal; however, there is considerable increase of operating time. Other treatment methods consist of CO<sub>2</sub> laser excision, cryosurgery or photodynamic therapy.<sup>56, 62</sup>

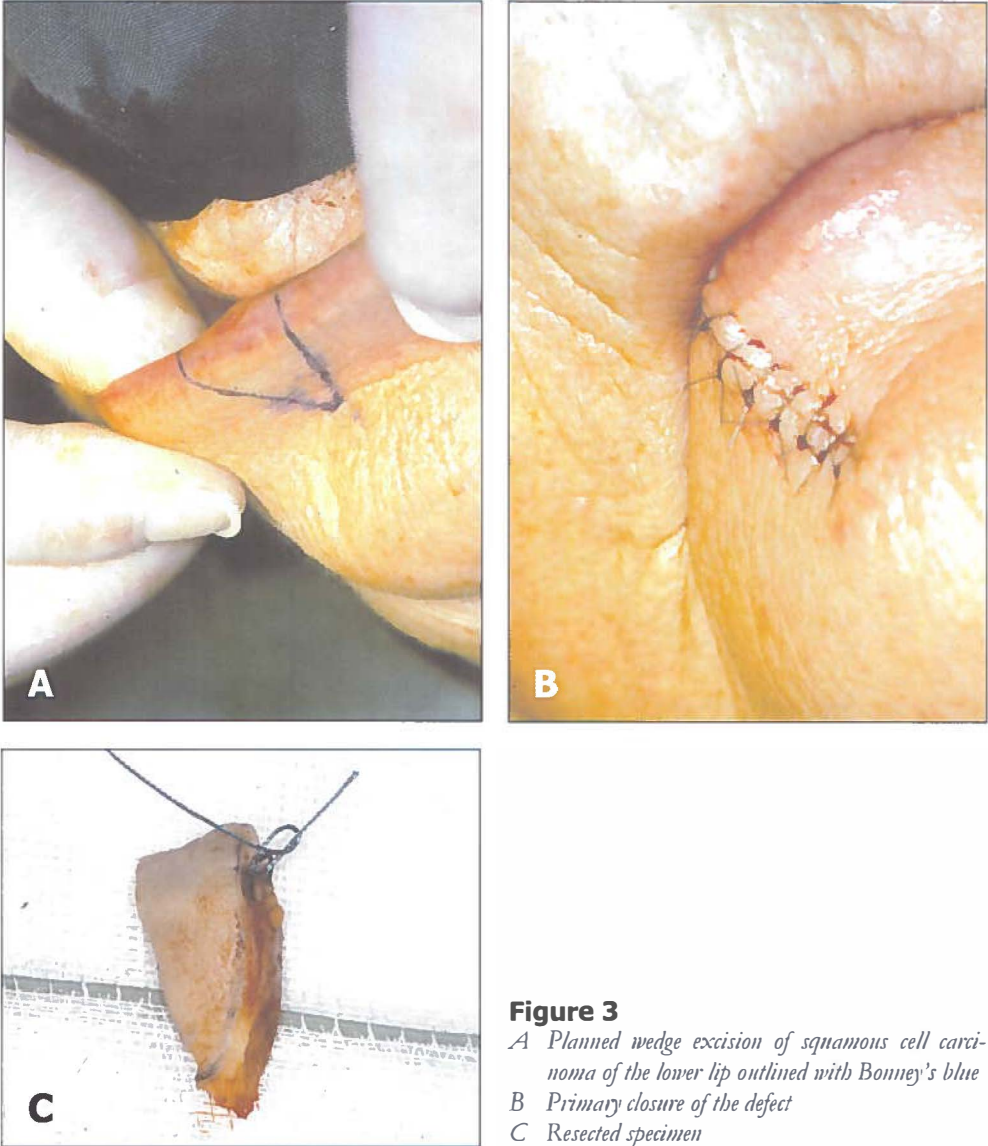
For a T1 lower lip tumor a full thickness wedge-excision is the most commonly used surgical procedure (Fig. 3). Eradication includes a margin of at least 3-10 mm of clinically uninvolved tissue, which is examined by frozen section. Generally, primary closure can be achieved if the defect covers one third or less of the lower lip width.<sup>5, 36, 46</sup>

In T2 or T3 tumors, more extensive resection and reconstruction of the defect with local flaps will mostly be necessary. Despite reconstructive surgery, this will result in impairment of the integrity of the oral sphincter muscle, thereby interfering with function and cosmetics. The preservation of the continuity of the perioral sphincter is important especially with regard to feeding, speech and facial expression.<sup>63-65</sup>

For T4 lower lip tumors, a planned combined treatment, consisting of surgery and postoperative radiotherapy, is indicated. Tumor invasion in surrounding structures necessitates a wide surgical excision in combination with 'en bloc' removal of cervical lymph nodes. Frozen section examination of the mental nerve and/or inferior alveolar nerve will inform the surgeon about potential perineural tumor involvement. The type of reconstruction largely depends on the size and the site of the defect; local, regional or free flaps may be used for reconstruction.

#### 1.4.2 Treatment of the neck

The classic radical neck dissection evolved from the surgical procedure described by Crile in 1906.<sup>66</sup> He recognized that radical surgery of cervical metastatic disease from primary malignant tumors of the head and neck is essential. Less radical surgical procedures were reported by Bartlett and Callander in 1926.<sup>67</sup> In 1941 and in 1951 the technique of the radical neck dissection was further established by Hayes Martin.<sup>68, 69</sup> For the treatment of cervical metastatic cancer, he reported different approaches including neck dissection and irradiation. In his article in 1941, Hayes



**Figure 3**

- A Planned wedge excision of squamous cell carcinoma of the lower lip outlined with Bonney's blue*
- B Primary closure of the defect*
- C Resected specimen*

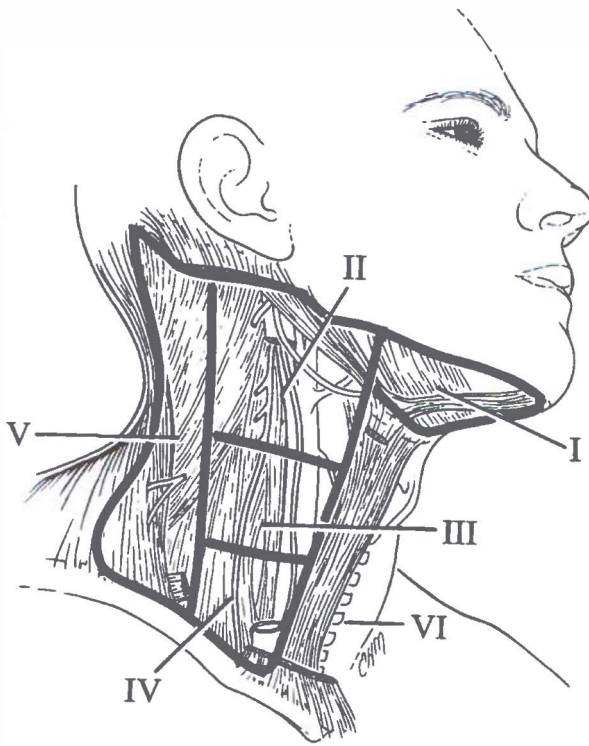
Martin already mentioned that a combination of the two treatment modalities would in some cases be better than either used alone.<sup>68</sup> Behrs, Gossel and Hollinshead in 1955 published a detailed surgical review of the technique and surgical anatomy of the radical neck dissection: a complete excision of all metastatic lesions present in the neck 'en bloc' with the lymph node bearing tissues, associated

lymph nodes and adjacent non-lymphatic structures, including the sternocleidomastoid muscle, the internal jugular vein and the accessory nerve.<sup>70</sup> In 1963, Suarez reported a revision of some traditional surgical concepts in radical neck dissection by describing 'en bloc' removal of compartments containing lymphatic structures including their surrounding aponeurotic and fascial membranes, stripping them from and in this way preserving non-lymphatic muscular and vascular structures.<sup>71-73</sup> Bocca in 1966 and Bocca and Pignataro in 1967 described respectively a 'functional' neck dissection and a conservation technique in radical neck surgery suggesting the preservation of the above-mentioned otherwise routinely excised 'functional' non-lymphatic structures as an acceptable alternative to the classic surgical procedure, provided that adequate tumor resection is not compromised.<sup>72,74</sup> Lingemann et al. and Jesse and Ballantyne in the early 1970s proposed the principle of the modified radical neck dissection as a therapeutic surgical treatment option, maintaining optimal oncological control in the neck.<sup>75, 76</sup> Better understanding of the biologic behavior of cervical metastatic disease and increasing knowledge of the pattern and predictability of its cervical spread allowed for a more selective surgical approach of the neck.<sup>24,25</sup> Evaluation and treatment of the neck and the concept of the tissue-saving selective neck dissection was further developed during the 1980s.<sup>77-80</sup>

In 1989 Medina reported a rational classification of neck dissections primarily based on the grouping of the lymph nodes in the neck.<sup>81</sup> In 1991, the Committee for Head and Neck Surgery and Oncology of the American Academy for Otolaryngology – Head and Neck Surgery published an official report to standardize neck dissection terminology including a classification of the different types of neck dissection. This classification conveniently referred to groups of cervical lymph nodes using the nowadays internationally accepted level system as originally described by the Sloan-Kettering Memorial Group (Memorial Sloan-Kettering Cancer Center, New York) (Fig. 4).<sup>82</sup>

The extent of metastatic disease in the neck is an important prognostic factor in terms of regional recurrence and distant metastases. Management of the neck in these patients can either include surgery alone, radiotherapy alone, or a planned combination of both of these treatment modalities.<sup>5, 20, 22, 68, 77, 79, 83</sup>

The estimated incidence of occult nodal disease, i.e. subclinical disease, determines the justification of elective neck treatment; this treatment of the clinically negative neck either by surgery or radiotherapy (a choice between surgery or radiotherapy being determined by the modality used for the treatment of the primary tumor) is indicated when there is a risk exceeding 15-20% for developing



**Figure 4**

*The level system for describing the location of lymph nodes in the neck. Level I indicates submental and submandibular group; level II upper jugular group; level III middle jugular group; level IV lower jugular group; level V posterior triangle group; level VI anterior compartment group.*

cervical metastases.<sup>84, 85, 87-92</sup> As the rate of metastatic disease in the neck from T1 and T2 SCCLL varies from 2-15%, elective treatment of the neck seems indicated in the rarely encountered patient with an advanced, T3- T4 tumor.<sup>3, 5</sup>

When manifest cervical lymph node metastases are present, a therapeutic neck dissection is indicated. Surgical intervention is mandatory both for treatment and staging of the disease. The type of neck dissection depends primarily on the N-stage: the location and the number of lymph nodes involved dictate a selective or more comprehensive, (modified) radical neck dissection in patients with a N+ neck, on indication followed by adjuvant radiotherapy.<sup>36, 91</sup> This planned combination treatment has resulted in a reduction of regional recurrent disease.<sup>79, 91</sup>

On the strict indication that there is just one (pN1) lymph node metastasis from SCCLL, smaller than 3 cm, limited to level I without extracapsular spread, a (selective) supraomohyoid neck dissection only seems sufficient treatment.<sup>92-94</sup>



## 1.5 Follow-up

According to the guidelines formulated and published by the Comprehensive Cancer Centre Northern Netherlands, patients are seen for follow-up during a period of at least 5 years with decreasing intervals.<sup>36, 95</sup> Besides complete physical evaluation of the head and neck area during the follow-up visits, an annual chest X-ray is recommended; recent literature, however, debates the usefulness of this radiological examination.<sup>96</sup>

Most local recurrences and regional metastases develop within 3 years after the initial treatment; however, late metastases may occur.<sup>5, 94</sup> More variable in time is the occurrence of a second primary tumor within respiratory and upper digestive tract.<sup>5, 20, 33, 35, 97, 98</sup>

## 1.6 Prognosis

The size of the primary tumor and the presence and the extension of regional metastatic disease are considered the most important prognostic determinants for survival.<sup>2, 22, 25, 99-102</sup> Clinical factors of the primary tumor that correlate with a high risk for local recurrence and metastases include tumor size, tumor thickness, histologic differentiation, subsite, perineural invasion, immunosuppression, host response and of less importance an ulcerative morphology.<sup>5, 19, 100</sup>

The five-year determinant survival rate of T1-T2 lip tumors ranges from 85%-99%.<sup>1, 5, 19</sup> When a larger lip tumor, T3-T4 is present and when there is lymph node involvement, the 5-year survival rate may decrease to 35%-70%.<sup>1, 18</sup>

## 1.7 Aim of the study

This thesis was undertaken to study essential aspects in the management of patients with SCCLL.

A multidisciplinary approach and the development and use of a guideline should maximize the quality of care for these patients and thus the best possible outcome. As a result of an increased understanding of both the biological behavior and the knowledge of the pattern of cervical lymphatic metastatic spread of SCCLL, more tissue-saving treatment strategies may be used. Studies were designed to analyze the value of less extensive, more selective surgical procedures.

The objectives of the study were:

1. The analysis of the compliance with a regional guideline for the diagnosis and treatment of SCCLL (**Chapter 2**).
2. To evaluate a series of patients presenting with a squamous cell carcinoma of the lip treated by radiation therapy, both as a single treatment modality and after irradiation surgery, and the role of multidisciplinary communication and management (**Chapter 3**).
3. To evaluate the results of carbon dioxide laser evaporation in the treatment of premalignant disease of the lower lip (**Chapter 4**).
4. To evaluate the significance of frozen section examination of the margins during the surgical management of SCCLL (**Chapter 5**) and, in particular, the efficacy of frozen section margin examination in combination with the use of a smaller margin in the treatment of SCCLL (**Chapter 6**).
5. To study the efficacy of a therapeutic supraomohyoid neck dissection for the treatment of cervical metastatic disease from SCCLL (**Chapter 7**).

**Chapter 8** presents a general discussion.

The thesis is concluded by a summary in **Chapter 9**.

## References

1. Baker SR, Krause CJ. Carcinoma of the lip. *Laryngoscope* 1980; 90: 19-27.
2. Zitsch RP, Park CW, Renner GJ, Rea JL. Outcome analysis for lip carcinoma. *Clinical epidemiology/outcomes research. Otolaryngol Head Neck Surg* 1995, 113: 589-96.
3. Baker SR. Current management of cancer of the lip. *Oncol* 1990; 4: 107-20.
4. De Visscher JGAM, Schaapveld M, Otter R, Visser O, van der Waal I. Epidemiology of cancer of the lip in the Netherlands. *Oral Oncol* 1998; 34: 421-6.
5. Renner GJ, Zitsch RP. Cancer of the lip. In: Myers EN, Suen JY. *Cancer of the Head and Neck*. Philadelphia: W.B. Saunders; 1996: 294-320.
6. Electronic Database; Data derived from the period 1989-1998. Utrecht: Association of Comprehensive Cancer Centres the Netherlands, 2001.
7. Hjortdal O, Naess A, Berner A. Squamous cell carcinomas of the lower lip. *J Cranio Maxillofac Surg* 1995; 23: 34-7.
8. Lindqvist C, Teppo I. Epidemiological evaluation of sunlight as a risk factor of lip cancer. *Br J Cancer* 1978; 37: 983-9.
9. Blomqvist G, Hirsch JM, Alberius P. Association between development of lower lip cancer and tobacco habits. *J Oral Maxillofac Surg* 1991; 49: 1044-7.
10. Mullen DL, Silverberg SG, Penn I, Hammond WS. Squamous cell carcinoma of the skin and lip in renal homograft recipients. *Cancer* 1976; 37: 729-34.
11. Penn I. Tumors after renal and cardiac transplantation. *Haematol/Oncol Clin N Am* 1993; 7: 431-45.
12. Cox MF, Scully C, Maitland N. Viruses in the aetiology of oral carcinoma? Examination of the evidence. *Br J Oral Maxillofac Surg* 1991; 29:381-7.
13. Scully C. Oncogenes, tumour suppressors, and viruses in oral squamous cell carcinoma. *J Oral Pathol Med* 1993; 22: 337-47.
14. de Visscher JGAM, van der Waal I. Etiology of cancer of the lip. A review. *Int J Oral Maxillofac Surg* 1998; 27: 199-203.
15. Müller H, Slootweg PJ. Mandibular invasion by oral squamous cell carcinoma. Clinical aspects. *J Craniomaxillofac Surg* 1990; 18: 80-4.
16. Hell B, Freitag V. Lower lip carcinoma. Infiltration of the mandible along the mental nerve. *J Craniomaxillofac Surg* 1988; 16: 76-9.
17. Bagatin M, Orihovac Z, Mohammed AM. Perineural invasion by carcinoma of the lower lip. *J Craniomaxillofac Surg* 1995; 23: 155-9.
18. Califano L, Maremonti P, De Rosa G. Spread of squamous cell carcinoma of the lower lip along the inferior alveolar nerve: a case report. *J Oral Maxillofac Surg* 1995; 5: 1108-10.
19. De Visscher JGAM, van den Elsaker K, Grond AJK, van der Wal JE, van der Waal I. Surgical treatment of squamous cell carcinoma of the lower lip: evaluation of long-term results and prognostic factors. A retrospective analysis of 184 patients. *J Oral Maxillofac Surg* 1998; 56: 814-20.
20. Zitsch RP, Lee BW, Smith RB. Cervical lymph node metastases and squamous cell carcinoma of the lip. *Head Neck* 1999; 21: 447-453.

21. Califano L, Zupi A, Massari PS, Giardino C. Lymph-node metastases in squamous cell carcinoma of the lip. *Int J Oral Maxillofac Surg* 1994; 23: 351-5.
22. McGregor GI, Davis NL, Hay JH. Impact of cervical lymph node metastases from squamous cell cancer of the lip. *Am J Surg* 1992; 163: 469-71.
23. Cruse CW, Radocha RF. Squamous cell carcinoma of the lip. *Plastic Reconstr Surg* 1987; 80: 787-91.
24. Lindberg R. Distribution of cervical lymph node metastases from squamous cell carcinoma of the upper respiratory and digestive tracts. *Cancer* 1972; 29: 1446-9.
25. Shah JP. Patterns of cervical lymph node metastasis from squamous cell carcinomas of the upper aerodigestive tract. *Am J Surg* 1990; 160: 405-9.
26. World Health Organization. International classification of diseases for oncology (ICD-O). Geneva: WHO, 1976.
27. Percy C, Van Holten V, Muir C, eds. World Health Organization. International classification of diseases for oncology (ICD-O), 2nd ed. Geneva: WHO, 1990.
28. Fritz A, Percy C, Jack A, Shanmugaratnam K, Sobin L, Parkin DM, Whelan S. World Health Organization. International classification of diseases for oncology, 3rd ed. Geneva: WHO, 2000.
29. Hermanek P, Sobin LH, eds. International Union Against Cancer (UICC). TNM classification of malignant tumours, 4th ed. Berlin: Springer, 1987.
30. Hermanek P, Sobin LH, eds. International Union Against Cancer (UICC). TNM classification of malignant tumours 4th ed. 2nd revision. Berlin: Springer, 1992.
31. Sobin LH, Wittekind Ch, eds. International Union Against Cancer (UICC). TNM classification of malignant tumours, 5th ed. Berlin: Springer, 1997.
32. Fleming ID, Cooper JS, Henson DE, Hutter RVP, Kennedy BJ, Murphy GP, O'Sullivan B, Yarbro JW, eds. American Joint Committee on Cancer. *AJCC Cancer staging manual*, 5th ed. Philadelphia: Lippincott, 1997.
33. Jovanovic A, Van der Tol IGH, Kostense PJ, Schulten EAJM, De Vries N, Snow GB, Van der Waal I. Second respiratory and upper digestive tract cancer following oral squamous cell carcinoma. *Oral Oncol, Eur J Cancer* 1994; 30B: 225-9.
34. Deleyiannis FWB, Thomas DB. Risk of lung cancer among patients with head and neck cancer. *Otolaryngol Head Neck Surg* 1997; 116: 630-6.
35. Van der Tol IGH, de Visscher JGAM, Jovanovic A, van der Waal I. Risk of second primary cancer following treatment of squamous cell carcinoma of the lower lip. *Oral Oncol* 1999; 35: 571-4.
36. Otter R. Guidelines for diagnosis and treatment of premalignant and malignant diseases in the Comprehensive Cancer Centre Northern Netherlands region (in Dutch). Groningen: Dijkhuizen van Zanten bv, 1998: 469-546.
37. Cook JA, Jones AS, Phillips DE, Soler Lluch E. Implications of tumour in resection margins following surgical treatment of squamous cell carcinoma of the head and neck. *Clin Otolaryngol* 1993; 18: 37-41.
38. Challis D. Frozen section and intra-operative diagnosis. *Pathology* 1997; 29: 165-74.
39. Loree TR, Strong EW. Significance of positive margins in oral cavity squamous cell carcinoma. *Am J Surg* 1990; 160: 410-4.

40. Van den Brekel MWM, Castelijns JA, Stel HV, Golding RP, Meyer CJLM, Snow GB. Computed tomography, magnetic resonance, ultrasound and ultrasound guided aspiration cytology for the assessment of the neck: a comparative study. *Eur Arch Otolaryngol* 1993; 250: 11-7.
41. Braams JW, Pruim J, Freling NJM, et al. Detection of lymph node metastases of squamous cell cancer of the head and neck with FDG-PET and MRI. *J Nucl Med* 1994; 36: 211-6.
42. Stern WB, Silver CE, Zeifer BA, Persky MS, Heller KS. Computed tomography of the clinically negative neck. *Head Neck* 1990; 12: 109-13.
43. Baatenburg de Jong RJ, Rongen RJ, Laméris JS, Harthoorn M, Verwoerd CDA, Kneeg P. Metastatic neck disease palpation vs ultrasound examination. *Head Neck Surg* 1989; 115: 689-90.
44. Shoab T, Soutar DS, MacDonald DG et al. The accuracy of head and neck carcinoma sentinel lymph node biopsy in the clinically N0 neck. *Cancer* 2001; 91: 79-84.
45. Altinyollar H, Berberoglu U, Celen O. Lymphatic mapping and sentinel lymph node biopsy in squamous cell carcinoma of the lower lip. *Eur J Surg Oncol* 2002; 28: 72-4.
46. De Visscher JGAM, Botke G, Schakenraad ACM, van der Waal I. A comparison of results after radiotherapy and surgery for stage I squamous cell carcinoma of the lower lip. *Head Neck* 1999; 21: 526-30.
47. Stranc MF, Fogel M, Dische S. Comparison of lip function: surgery versus radiotherapy. *Br J Plastic Surg* 1987; 40: 598-604.
48. Ashley FL, McConnel DV, Machida R, Sterling HE, Galloway D, Grazer F. Cancer of the lip. A comparison of five year results after irradiation and surgical therapy. *Am J Surg* 1965; 110: 549-51.
49. Debois JM. Brachytherapy of carcinoma of the lower lip. Experience with 130 patients. *Tumordiagn Ther* 1993; 14: 143-6.
50. Wang SJ, Wang MB, Calcaterra TC. Radiotherapy followed by neck dissection for small head and neck cancers with advanced cervical metastases. *Ann Otol Rhinol Laryngol* 1999; 108: 128-31.
51. Picascia DD, Robinson JK. Actinic Cheilitis: a review of the etiology, differential diagnosis, and treatment. *J Am Acad Dermatol* 1987; 17: 255-64.
52. Baker SR. Risk factors in multiple carcinomas of the lip. *Otolaryngol Head Neck Surg* 1980; 88: 248-51.
53. Campbell JP. Surgical management of lip carcinoma. *J Oral Maxillofac Surg* 1998; 56: 955-61.
54. Gooris PJJ, Roodenburg JIN, Vermey A, Nauta J.M. Carbon dioxide laser evaporation of leukoplakia of the lower lip: a retrospective evaluation. *Oral Oncol* 1999; 35: 490-5.
55. Alamillos-Granados FJ, Naval-Gias L, Dean-Ferrer A, Alonso del Hoyo JR. Carbon dioxide laser vermilionectomy for actinic cheilitis. *J Oral Maxillofac Surg* 1993; 51: 118-21.
56. Brufau C, Canteras M, Armijo M. Our experience in the treatment of cancer and precancerous lesions of the lower lip. *J Dermatol Surg Oncol* 1985; 11: 908-12.
57. Spira M, Hardy SB. Vermilionectomy: review of cases with variations in technique. *Plast Reconstr Surg* 1964; 33: 39-46.

58. Sanchez-Conejo-Mir J, Perez Bernal AM, Moreno-Gimenez JC, Camacho-Martinez F. Follow-up of vermilionectomies: evaluation of the technique. *J Dermatol Surg Oncol* 1986; 12: 180-4.
59. Mohs FE, Snow SN. Microscopically controlled surgical treatment for squamous cell carcinoma of the lower lip. *Surg Gynecol Obstet* 1985; 160: 37-41.
60. Mehregan DA, Roenigk RK. Management of superficial squamous cell carcinoma of the lip with Mohs micrographic surgery. *Cancer* 1990; 66: 463-8.
61. Holmkvist KA, Roenigk RK. Squamous cell carcinoma of the lip treated with Mohs micrographic surgery: outcome at 5 years. *J Am Acad Dermatol* 1998; 38: 960-6.
62. Kübler AC, De Carpentier J, Hopper C, Leonard AG, Putnam G. Treatment of squamous cell carcinoma of the lip using foscan-mediated photodynamic therapy. *Int J Oral Maxillofac Surg* 2001; 30: 504-9.
63. Sicher H, Lloyd DuBrul E. Oral anatomy, 4th ed. St Louis: Mosby, 1970: 156-68.
64. Rubin LR. Anatomy of facial expression. In: Rubin LR. Reanimation of the paralyzed face. New approaches. St Louis: Mosby, 1977: 2-27.
65. Nairn RI. The circumoral musculature: structure and function. *Br Dent J* 1975; 138: 49-56.
66. Crile G. Excision of cancer of the head and neck with special reference to the plan of dissection based on one hundred and thirty two operations. *J Am Med Assoc* 1906; 47: 1780-6.
67. Bartlett EI, Callander CL. Neck dissections *Surg Clin N Am* 1926; 6: 481-505
68. Martin H. The treatment of cervical metastatic cancer. *Ann Surg* 1941; 114: 972-85.
69. Martin H, Del Valle B, Ehrlich H, Cahan WG. Neck dissection. *Cancer* 1951; 4: 441-99.
70. Beahrs OH, Gossel JD, Hollinshead WH. Technic and surgical anatomy of radical neck dissection. *Am J Surg* 1955; 90: 490-516.
71. Suarez O. El problema de las metastasis linfaticas y alejadas del cancer de laringe e hipofaring. *Rev Otorrinolaring* 1963; 23: 83-9.
72. Bocca E, Pignataro O. A conservation technique in radical neck dissection. *Ann Otol Rhinol Laryngol* 1967; 76: 975-87.
73. Bocca E. Conservative neck dissection. *Laryngoscope* 1975; 85: 1511-5.
74. Bocca E. Supraglottic laryngectomy and functional neck dissection. *J Laryngol* 1966; 80: 831-8.
75. Lingemann RE, Helmus C, Stephens R, Ulm J. Neck dissection: radical or conservative. *Ann Otol Rhinol Laryngol* 1977; 86: 737-44.
76. Jesse RH, Ballantyne AJ, Larson D. Radical or modified radical neck dissection: A therapeutic dilemma. *Am J Surg* 1978; 136: 516-9.
77. Shah JP, Strong E, Spiro RH, Vikram B. Neck dissection: current status and future possibilities. *Clin Bulletin* 1981; 11: 25-33.
78. Byers RM. Modified neck dissection – A study of 967 cases from 1970 to 1980. *Am J Surg* 1985; 150: 414-21.
79. Larson DL, Ballantyne AJ, Guillaumondegui OM. Cancer in the Neck. Evaluation and Treatment. New York: Macmillan Publishing Company, 1986.

80. Pellitteri PK, Robbins KT, Neuman T. Expanded application of selective neck dissection with regard to nodal status. *Head Neck* 1997; 19: 260-5.
81. Medina JE. A rational classification of neck dissections. *Otolaryngol Head Neck Surg* 1989; 100: 169-76.
82. Robbins KT, Medina JE, Wolfe GT, Levine PA, Sessions RB, Pruet CW. Standardizing Neck Dissection Terminology. Official report of the Academy's Committee for Head and Neck Surgery and Oncology. *Arch Otolaryngol Head Neck* 1991; 117: 601-5.
83. Byers RM, Wolf PF, Ballantyne AJ. Rationale for elective modified neck dissection. *Head Neck Surg* 1988; 10: 160-7.
84. Van den Brekel MVM, van der Waal I, Meijer CJLM, Freeman JL, Castelijns JA, Snow GB. The incidence of micrometastases in neck dissection specimens obtained from elective neck dissections. *Laryngoscope* 1996; 106: 987-91.
85. Manni JJ, van den Hoogen FJA. Supraomohyoidal neck dissection with frozen section biopsy as a staging procedure in the clinically node-negative neck in carcinoma of the oral cavity. *Am J Surg* 1991; 162: 373-6.
86. Skolnik EM, Katz AH, Mantravadi R, Becker SP, Stal S. Evolution of the clinically negative neck. *Annal Otol* 1980; 89: 551-5.
87. Pillsbury HC, Clark M. A rationale for therapy of the N0 neck. *Laryngoscope* 1997; 107: 1294-1315.
88. Laramore GE. Treatment of nodes in the clinically N0 neck. In Laramore GE (Ed). *Radiation therapy of head and neck cancer*. Berlin: Springer-Verlag, 1989: 37-40.
89. Fletcher GH. Elective irradiation of subclinical disease in cancers of the head and neck. *Cancer* 1972; 29: 1450-4.
90. Fletcher GH. The role of irradiation in the management of squamous cell carcinomas of the mouth and throat. *Head Neck Surg* 1979; 1: 441-57.
91. Leemans CR, Tiwari RM, van der Waal I, Karim ABMF, Nauta JJP, Snow GB. The efficacy of comprehensive neck dissection with or without postoperative radiotherapy in nodal metastases of squamous cell carcinoma of the upper respiratory and digestive tracts. *Laryngoscope* 1990; 100: 1194-8.
92. Medina JE, Byers RM. Supraomohyoid neck dissection: rationale, indications, and surgical technique. *Head Neck* 1989; 11: 111-22.
93. Kowalski LP, Magrin J, Waksman G, Santo GFE, Lopez MEF, de Paula RP, Pereira RN, Tortino H. Supraomohyoid neck dissection in the treatment of head and neck tumors. *Arch Otolaryngol Head Neck Surg* 1993; 119: 958-63.
94. Gooris PJJ, Vermey A, de Visscher JGAM, Burlage FR, Roodenburg JLN. Supraomohyoid neck dissection in the management of cervical lymph node metastases of squamous cell carcinoma of the lower lip. *Head Neck* 2002; 24: 678-83.
95. Gellrich NC, Schramm A, Böckmann R, Kugler J. Follow-up in patients with oral cancer. *J Oral Maxillofac Surg* 2002; 60: 380-6.
96. Buwalda J, Zuur CL, Lubsen H, Tijsen JGP, Koole R, Hordijk GJ. Annual chest radiography in patients treated for laryngeal or oral cancer: limited number of detected second primary cancers in the lung. *Ned Tijds Geneesk* 1999; 143: 1517-22.
97. Sack JG. Metastatic squamous cell carcinoma of the lip. *Arch Otolaryngol* 1978; 104: 282-5.

98. Tepperman BS, Fitzpatrick PJ. Second respiratory and upper digestive tract cancers after oral cancer. *Lancet* 1981; II: 547-9.
99. Cachin Y, Sancho-Garnier H, Micheau C, Marandas P. Nodal metastasis from carcinomas of the oropharynx. *Otolaryngol Clin N Am* 1979; 12: 145-54.
100. Snow GB, Annyas AA, van Slooten EA, Bartelink H, Hart AAM. Prognostic factors of neck node metastasis. *Clin Otolaryngol* 1982; 7: 185-92.
101. Rowe DE, Carroll RJ, Day CL. Prognostic factors for local recurrence, metastasis, and survival rates in squamous cell carcinoma of the skin, ear, and lip. Implications for treatment modality selection. *Clinical Review. J Am Acad Dermatol* 1992; 26: 976-90.
102. Frierson HF, Cooper PH. Prognostic factors in squamous cell carcinoma of the lower lip. *Human Pathol* 1986; 17: 346-54.

## **Acknowledgement**

Permission to reproduce the illustration in Fig. 4 was kindly granted by Mosby, Inc., Harcourt Health Sciences Company, Orlando, FL., USA.



### *Assessment of a Guideline*

# **Regional Guideline for Diagnosis and Treatment of Squamous Cell Carcinoma of the Lip: What is the Level of Compliance?**

P.J.J. Gooris<sup>1</sup>, M. Schaapveld<sup>2</sup>, A. Vermeij<sup>3</sup>  
R. Otter<sup>2</sup>, A. Rispens<sup>2</sup>, J.L.N. Roodenburg<sup>4</sup>

---

<sup>1</sup>Department of Oral and Maxillofacial Surgery  
Amphia Hospital, Breda, The Netherlands

<sup>2</sup>Comprehensive Cancer Centre Northern Netherlands  
Groningen, The Netherlands

<sup>3</sup>Department of Surgery/Head and Neck Surgery  
Groningen University Hospital, The Netherlands

<sup>4</sup>Department of Oral and Maxillofacial Surgery/Oncology  
Groningen University Hospital, The Netherlands

International Journal for Quality in Health Care 2001; 13: 143-150



## Abstract

### Objective

To investigate to what extent physicians comply with a regional guideline for the diagnosis, staging, treatment and follow-up of patients with squamous cell carcinoma of the lower lip.

### Design

Retrospective analysis of data from the medical records of 248 patients diagnosed with squamous cell carcinoma of the lower lip during the period 1989-1997.

### Setting

Comprehensive Cancer Centre of the Northern region of the Netherlands.

### Study participants

The data were collected by this Centre for the regional population-based cancer registry.

### Results

Overall compliance with the separate guidelines varied between 4% and 80%. For diagnosis and staging, the guideline was followed in 4-70% of the patients. The type of treatment in relation to age conformed to the guideline in 34% of the cases.

Of the 208 surgically-treated patients, treatment was performed in accordance with the guideline in 92 (44%) patients, compared with seven out of 18 (39%) patients who received radiotherapy.

Follow-up in accordance with the guideline was 11% in the first year, 9% in the second year and 21% in the third year.

### Conclusion

Only a minority of patients with squamous cell carcinoma of the lower lip, a rare tumor, were managed according to the available regional guideline. Regular review of both the guideline and its implementation is necessary in order to optimize its use.

## Introduction

There is an increasing interest in the role of explicit clinical guidelines that aim to reduce inappropriate practice and improve the efficiency of healthcare.<sup>1,2</sup>

The American Institute of Medicine (AIM) has defined guidelines as systematically developed and recorded statements that can help physicians and patients in the decision-making process about appropriate healthcare under specific circumstances<sup>3</sup>. In the Netherlands a guideline is seen as a collection of generally accepted instructions for medical actions in a specific area of healthcare<sup>4</sup>. In contrast to a protocol or standard, which constitutes a rigid regimen, guidelines are allowed to have more flexibility to fit individual needs, depending on patient and loco-regional factors. This can lead to the development of scientifically based guidelines that are more strictly defined, or to guidelines which have less impact on the treatment outcome and can be considered optional. Guidelines should however, be consistent with the available scientific evidence to be a valid in patient management.<sup>5,6</sup>

To achieve an optimal clinical result in the most efficient manner both diagnosis and treatment should be carried out in accordance with the guidelines,<sup>1,7</sup> to avoid discordance in inappropriate diagnosis and treatment<sup>7,8</sup> and allowing cost-benefits whilst promoting uniformity and best clinical results. Medical treatment then becomes quantifiable which, in turn, makes quality control possible.<sup>3</sup> Maximum acceptance and implementation can be achieved by involving the user group in the development of guidelines.<sup>2,5,9</sup>

Because drafting and regular update of clinical guidelines is both costly and labour-intensive,<sup>1,7</sup> reports showing limited compliance of treatment with available recommendations are disturbing, especially when dealing with rare disease.<sup>1-3</sup> It was therefore decided to determine the extent of compliance with the guideline.

Since the mid-1970s in the Netherlands, it has been common practice to develop guidelines in oncology for diagnosis and treatment aimed at providing optimal care for patients with cancer. In order to analyze the impact of a guideline on the daily practice, it is necessary to investigate its level of compliance.

This article presents an evaluation of the use of a regional guideline for the diagnosis and treatment of a rare malignancy, squamous cell carcinoma (SCC) of the lower lip, generated by a Comprehensive Cancer Centre (CCC).

## Material and Methods

The population-based cancer registry of the Comprehensive Cancer Centre Northern Netherlands (CCCN) covers the northern area of the Netherlands with approximately 2.1 million inhabitants. An important role of the CCCN is to make policy. Multidisciplinary tumor workgroups are instituted, which have been active since 1978 for the development, design and dissemination of guidelines for diagnosis, staging and treatment of the most prevalent forms of malignant neoplasms. These workgroups comprise representatives from all 19 hospitals affiliated with the CCCN. All possible users of the guidelines (i.e. physicians treating cancer) are involved in the oncology committee meetings of each hospital. Also present during those meetings is a team of external academic consultants, highly specialized in the different fields of oncology. During such sessions the potential users are directly involved in the generation and implementation of guidelines: an inventory is prepared annually by the representative of the oncology workgroup. The 19 representatives then discuss the outcome of the different hospitals and thereafter more specifically formulate the guideline, in agreement with selected information from scientific research and clinical experience in combination with available directives i.e. recommendations from the Dutch Institute for Quality in Healthcare Improvement CBO (Centraal Begeleidings Orgaan; in English: Central Advisory Body). These guidelines are then structured and outlined according to the type and site of the malignancy, making the guidelines easily accessible for the user. Care is taken to provide an explicit text that is not open to alternative interpretation. All suggested guidelines are practically suitable for all 19 hospital settings, except for the radiotherapy guidelines which depend on the presence of a radiotherapeutic institute (only available in four of the affiliated hospitals). The guidelines are then published and subsequently supplied to all 19 representatives of the CCC. The group of users within the affiliated hospitals can order the “Guidelines for diagnosis and treatment of premalignant and malignant diseases in the CCCN region” free of charge; this book must be ordered because it is not automatically supplied to all the users. The book is updated every 2 years.

There is no written enforcement of the guideline; rather, compliance with the guideline is the individual physician’s responsibility. However, when patient management is not in keeping with the guideline, the physician is obliged to make a clear report of this in the medical record. Monitoring and feed back then take place during the oncology committee meetings, which are attended by the external consultancy team.

For the present study the medical records of 310 patients with SCC of the lower lip diagnosed in the period January 1989 to December 1997 and managed in one of the 19 affiliated hospitals were examined to establish whether diagnosis, staging, treatment and follow-up had been performed in accordance with the current guideline. With regard to guideline adherence, in the absence of specific information in the medical record, the item was designated as “not performed” and was thus, for the purpose of this study, not in accordance with the guideline. In 62 of the original 310 patients (20%), despite diagnosis of SCC confirmed by histopathology, there was incomplete or missing data in their record concerning diagnosis and treatment. When these patients were excluded, the data from 248 patients was analyzed further.

In the CCCN region, the 1989 guideline<sup>10</sup> and its 1994 revision<sup>11</sup> were applicable for the diagnosis and treatment of lip carcinoma. The 1994 revision included only a more precise description of dosage and fractionation of radiation treatment based on tumor size.

In the present analysis, for data from the guideline, a distinction was made between diagnosis, staging, treatment and follow-up.

## Diagnosis and staging

For diagnosis and staging the items marked with a footnote in Table 1 were selected for evaluation. For assessment of the staging the diagnostic guideline items

**Table 1** *Guideline items for diagnosis and staging of malignancy of the lower lip.*

---

Medical history
Physical diagnostic examination
<ul style="list-style-type: none"> <li>• Inspection and palpation<sup>1</sup></li> <li>• Description of tumor (dimensions)<sup>1</sup></li> <li>• Evaluation of lip sensibility<sup>1</sup></li> <li>• Inspection of head/neck; lymphogenic metastasis/ 2nd primary tumor<sup>1</sup></li> <li>• General physical examination</li> </ul>
Imaging studies
<ul style="list-style-type: none"> <li>• Orthopantomogram (panorex view)/ occlusal view</li> <li>• Chest X-ray<sup>1</sup></li> </ul>
Additional examination
<ul style="list-style-type: none"> <li>• CT or MRI in case of T3/T4 classification</li> <li>• Dissemination investigation in case of N+ classification</li> <li>• Biopsy<sup>1</sup></li> </ul>

---

<sup>1</sup> Items evaluated in the present study.

inspection and palpation and description of the primary lip tumor and inspection of the neck were evaluated. Using the guideline, tumors were staged according to the UICC-TNM classification of 1997, which for lip carcinoma is the same as that dating from 1987.<sup>12</sup> The item lip sensibility was evaluated because of its diagnostic relevance (perineural invasion) for treatment planning. We analyzed whether or not a pretreatment chest X-ray was made because the guideline advises this type of X-ray to detect the presence of a second primary lung tumor. With regard to the evaluation of the recorded information on the biopsy, the guideline requires that there should be a relationship between the type of biopsy and the tumor size. In the case of small tumors (<0.5 cm) an excisional biopsy can be carried out for which intraoperative frozen section examination of the surgical margins should be performed. For larger tumors (>0.5 cm) an incisional biopsy should be performed.

## Treatment

According to the guideline the treatment should be related to the tumor stage (Tables 2 and 3). In the choice of treatment of T1, T2 and T3 tumors the guideline states that either surgery or radiotherapy can be applied because both modalities can achieve a similar result; patient factors and the expected cosmetic and functional results will determine the eventual choice between surgery and radiotherapy. For T4 tumors, a combined treatment of surgery and radiation therapy is always indicated.<sup>13-15</sup> Surgery offers the advantage of possible histologic evaluation of the entire specimen, which could indicate the need for additional treatment. With radiotherapy there is less tissue loss, giving a good cosmetic and functional result. However, a dry lip can develop which may be more sensitive for actinic changes; theoretically, this increases the risk of the development of a second primary lip tumor. Consequently, the guideline advises that patients aged 60 years and younger should preferably be treated surgically while those aged over 60 years should be given radiation therapy. This means that in the situations of local recurrence after surgery or a second primary tumor, radiotherapy may still be applied. In our evaluation, therefore, the age criterion in the choice of surgery versus radiotherapy was taken into consideration.

In case of surgical treatment, intraoperative examination of the frozen section of the surgical margins needs to be performed, in conjunction with definitive histopathologic examination of the surgical margin. For primary radiotherapy all relevant data (quality, dosage, fractions, total dose) need to be recorded (Table 3).

**Table 2** Overview of the T-classification in 248 patients with squamous cell carcinoma of the lip.

Primary tumor		Total
Tx	Size of primary tumor cannot (no more) be assessed	0
T0	No clinical evidence of primary tumor	0
T <sub>is</sub>	Carcinoma in situ	12
T1	Tumor 2 cm or smaller in diameter	213
T2	Tumor more than 2 cm, no greater than 4 cm in diameter	21
T3	Tumor more than 4 cm in diameter	0
T4	Tumor invading adjacent structures (e.g. cortical bone, soft tissues mouth or neck)	2

**Table 3** Treatment guideline items for malignancy of the lower lip related to the TNM classification.

	January 1989	January 1994 <sup>1</sup>
T <sub>is</sub>	lip shave cryotherapy laser	lip shave cryotherapy laser
T1	excision with frozen section of margins radiotherapy over 3-4 weeks	excision with frozen section orthovoltage (>125kV) 12x4Gy /17x3Gy electrons (6 MeV) 22x2.5Gy iridium ( <sup>192</sup> Ir) minimal 55Gy
T2	excision with frozen section of margins radiotherapy	excision with frozen section Orthovoltage (>125 kV) 17x3Gy electrons (6 MeV) 22x2.5Gy iridium ( <sup>192</sup> Ir) minimal 55Gy
T3	excision with frozen section of margins radiotherapy	excision with frozen section Orthovoltage (>125 kV) 17x3Gy electrons (6 MeV) 22x2.5Gy iridium ( <sup>192</sup> Ir) minimal 55Gy
T4	excision with frozen section plus within 6 weeks radiotherapy with minimal 60 Gy for 6 weeks	
N0 <sup>2</sup>	no treatment, consider by T4	
N+ <sup>3</sup>	modified radical neck dissection; followed within 6 weeks by radiotherapy of the entire neck including the supraclavicular area left and right, unless there is 1 positive node in the first echelon (submental, submandibular) <3 cm and without extracapsular growth nodes >6 cm or fixed nodes: preoperative radiotherapy followed by radical neck dissection	

<sup>1</sup>From January 1994 a revision of treatment items for radiotherapy including quality, dosage and fractions was incorporated in the guideline.

T<sub>is</sub>, T1, T2, T3, T4 see Table 2.

<sup>2</sup>N0= No clinical regional lymph node metastases

<sup>3</sup>N+= Regional lymph node metastases.



## Follow-up

The guideline describes the follow-up method after discharge. In the first year monitoring takes place once every 2 months, in the second year once every 3 months, in the third year once every 4 months, and in the fourth and fifth year once every 6 months, when no recurrence or second primary was detected.

From the information in the medical record, we could not establish whether the patient missed an arranged appointment, or whether the appointment was not adequately organized by the physician.

## Results

### Diagnosis and staging

Tumor size is shown in Table 2. Most of the cases, i.e. 213/248 (86%) involved a T1 tumor. There was an absence of T3 lip tumors in the investigated population (Table 2). The male/female ratio was 6:1 with a mean age of 69.4 (range 34-98) years which corresponds with reported data for this disease.<sup>16, 17</sup>

Information on inspection and palpation of the tumor that could lead to a staging was documented in 102/248 (41%) of the cases. The exact dimensions of the tumor (in cm) were insufficiently recorded: generally only the T-classification was used to describe tumor size. In 9/248 (4%) of the patients mention was made of evaluation of lip sensibility. Data on neck examination were noted in 173/248 (70%) cases. Table 4 shows the relationship between the information with regard to diagnosis and staging in the medical record and the T-classification of the tumor.

Table 5 shows the type of biopsy in relation to the T-classification. In 50/213 (23%) of the T1 tumors and in 2/21 (10%) of the T2 tumors an excisional biopsy was performed. In 58/248 (23%) patients there was insufficient information on the way the biopsy was performed in which case it was classified as "unspecified".

**Table 4** Relationship between information on diagnosis and staging in the medical record versus tumor size (TNM- classification<sup>12</sup>) in patients with lower lip malignancy (CCCN 1989-1997).

cT stage	Tis	T1	T2	T4	Total
Number of patients	12	213	21	2	248
Inspection/palpation	4/12 (33%)	86/213 (40%)	10/21 (48%)	2/2 (100%)	102/248 (41%)
Lip sensibility	0/12	7/213 (3%)	1/21 (5%)	1/2 (50%)	9/248 (4%)
Neck examination	6/12 (50%)	149/213 (70%)	16/21 (76%)	2/2 (100%)	173/248 (70%)

**Table 5** *Relationship between the type of biopsy and the tumor size (TNM) of patients with a lower lip malignancy.*

Type of biopsy	Tumor size (TNM classification)				Total
	Tis	T1	T2	T4	
Incisional biopsy	4	116	11	1	132
Excisional biopsy	6	50	2		58
Biopsy unspecified	2	47	8	1	58
<b>Total</b>	12	213	21	2	248

Evaluation of the imaging studies showed that, in accordance with the guideline, a pretreatment chest X-ray was made in 26% of the cases.

### Treatment

According to the guideline the age of the patient should play a role in the choice of treatment. In 51/55 (93%) of the patients aged <60 years, surgical treatment was applied in compliance with the guideline, whereas in 3/55 (5%) irradiation was selected, and in 1/55 (2%) no treatment was given. In the patient group aged >60 years 157/193 (81%) underwent surgery, 33/193 (17%) radiotherapy and 3/193 (2%) no treatment. When summarizing the type of treatment related to age, in total 84/248 (34%) patients were managed according to the guideline.

Surgical treatment of lip tumor was used for 208/248 (84%) patients whereas 36/248 (15%) patients received radiotherapy. In four cases no treatment took place because the patient withdrew cooperation due to age or other illness.

Of the 208 surgically treated patients we investigated whether frozen section examination of the surgical margins had taken place as prescribed in the guidelines. In 92 (44%) of these patients this examination was performed; in 108 (52%) patients, however, the surgical margins were studied only at time of definitive histopathologic examination. In 8 (4%) patients information on both topics was lacking (Table 6).

A group of 36 patients underwent radiotherapy. The updated guideline addressing quality, dosage and fractionation of radiation was available from 1 January 1994. Of the 18 patients who were treated after that date, seven (39%) were treated according to the specific guideline (Table 6). When radiotherapy was given, in all cases the diagnosis was confirmed by histology beforehand.

**Table 6** Relationship between type of treatment modality according to the guideline versus tumor size (TNM classification) of the lower lip malignancy.

Type of treatment	Tumor size (TNM classification)				Total
	Tis	T1	T2	T4	
Surgery	8	187	11	2	(208)
excision: SM+ FS+		87 41%	3 14%	2 100%	92
excision: SM+ FS-	6 50%	94 44%	8 38%		108
excision: SM- FS-	2 17%	6 3%			8
Radiotherapy	3	23	10		(36)
conform guideline		3 2%	4 19%		7
not conform guideline	3 25%	20 9%	6 29%		29
No treatment	1 8%	3 1%			(4)
<b>Total</b>	12 100%	213 100%	21 100%	2 100%	248

SM = examination of surgical margins

FS = examination of frozen section.

+ indicates that the procedure was performed

- indicates that the procedure was not performed.

## Follow-up

Our evaluation of the follow-up in the first three years following treatment showed that in the first year, 26/248 (10%) of the patients were monitored according to the guideline, whereas 151/248 (61%) patients showed for follow-up with a frequency ranging from three-five times per year. In the second year 20/248 (8%) patients underwent follow-up in accordance with the guideline, whereas 116/248 (47%) patients underwent monitoring two to three times per year. In the third year 39/248 (16%) patients were followed-up according to the guideline and in 100/248 (40%) patients the control took place once or twice a year.

Table 7 presents the summarized compliance with each separate guideline in the studied population.

## Discussion

The aim of this study was to establish to what extent a group of 248 patients with SCC of the lower lip were investigated and treated in accordance with a mutually agreed, multidisciplinary determined regional guideline. To this end, data on the most important items of the guideline were collected and analyzed. It should be noted that the absence of specifically required data in the medical record does not necessarily mean that that particular investigation or action had not taken place.

**Table 7.** *Compliance with the guidelines in the studied population.*

Guideline	Compliance
Total number of patients	310
Documentation	
1. Complete documentation of diagnosis and treatment	248/310 (80%)
Diagnosis	
2. Inspection and palpation documented	102/248 (41%)
3. Lip sensibility	9/248 (4%)
4. Type of biopsy (incisional/excisional)	unspecified*
Staging	
5. Size of tumor	unspecified**
6. Neck data	173/248 (70%)
7. Chest X-ray	65/248 (26%)
Treatment	
8. Age guideline 33/193 >60 years + 51/55 <60 years =	84/248 (34%)
9. Frozen section used in surgery	92/208 (44%)
10. Radiotherapy guideline available and followed	7/18 (39%)
Follow up	
11. First year	26/248 (10%)
12. Second year	20/248 (8%)
13. Third year	39/248 (16%)

\* type of biopsy based on size of tumor in cm

\*\* size of tumor in cm

The amount of data on inspection and palpation of the primary tumor and investigation of the neck increased with increasing size of the tumor (Table 4). Assessment of lip sensibility was only sporadically performed. This information is important for assessment of possible perineural spread that, independent of tumor size, can occur and may influence the course of additional diagnosis and treatment. As the majority of the lip malignancies comprised T1 type tumors (86%), and a small tumor is considered a less serious threat, this might explain why compliance with the guideline was low.

Additional imaging study was limited to the pretreatment chest X-ray. This X-ray is made in patients with SCC of the upper respiratory and digestive tract because survival rate can be unfavorably influenced by the occurrence of a second primary, for example in the lung.<sup>18-20</sup> Literature, however, suggests that annual screening is of little benefit, in view of the limited number of patients with second primary lung cancer and the small percentage of patients eligible for curative surgical treatment.<sup>21, 22</sup> A T1N0M0 SCC of the lower lip, where T1 is a malignant tumor measuring 2 cm or less (see Table 3), N0 indicates no regional lymph node

involvement and M0 indicates no distant metastasis, 12 rarely results in haematogenic metastasis to the lung before lymphatic spread has occurred. The question arises whether this routinely performed X-ray is superfluous in the diagnostic workup of patients presenting with a T1N0M0 lip cancer and should, therefore, be deleted from the guideline in the future.<sup>15, 19, 23</sup>

The cornerstone of the diagnosis remains the biopsy. Despite the fact that the guideline stipulates that, 'depending on the recorded tumor size in centimeters an incisional or excisional biopsy should be conducted', it appeared from the medical records that generally only the T-stadium was recorded and not the actual size in cm. This was our rationale, to classify the type of biopsy according to the T-classification rather than according to the actual size of the tumor. Although a T1 may measure <0.5 cm, it can also be as large as 2cm in diameter which means that no valid analysis could be made of the type of biopsy performed in relation to tumor size. However, when dealing with T2 tumors, no excisional biopsy should have been performed. Thus, in our opinion, it should be recommended that the exact dimensions of the primary tumor be more precisely recorded and that the excisional biopsy be reserved for tumors <0.5 cm, as prescribed in the guideline.

The recommendation that patients aged <60 years should preferably be surgically treated and older patients preferably undergo radiotherapy was partly followed. Patients >60 years were mainly (81%) surgically treated. As 15 hospitals have to refer their patients for radiotherapeutic treatment, together with the time-consuming nature of radiotherapy versus one-time surgical intervention, this may have led to a preference of surgery over radiotherapy in the older patients as well.

Frozen section examination of the surgical margins is important to evaluate if a radical procedure was carried out, e.g. whether an additional resection was performed during the same session. In the absence of this investigation, as was the case in 116 (56%) patients in our study, the presence of non-free surgical margins can lead to a later re-resection as well as to postoperative radiotherapy that could otherwise have been avoided.

Follow-up was seldom conducted in accordance with the guideline. The expectation that patient cooperation decreases over time<sup>18</sup> was not confirmed in the present study. In view of the fact that a local recurrence and/or neck metastasis generally occurs in the first 2-3 years after treatment of lip malignancy<sup>23</sup> it is essential that follow-up takes place at least during the first 3 years. It is important to keep records of both the patient's compliance and the role of the medical organi-

zation with regard to the adherence to the follow-up guideline such that adequate corrections can be made quickly if required.

The adherence to the guideline is monitored during the oncology meetings together with the external consultancy team. It is difficult therefore to justify “inappropriate practice”. In contrast, in case of deviation from a standard, strict criteria are violated and enforcement is more likely to follow.<sup>5</sup>

The overall adherence to the guideline varied between 4-80% (Table 7). This is a disappointing result that requires critical examination. The treating physician either consciously deviates from the guideline without reporting the rationale for this, is not sufficiently informed about the guideline, or does not consult it. Whatever the case, it appears that control i.e. monitoring to ensure application of the guideline is necessary. Grimshaw and Russell described the criteria on which valid clinical guidelines should be based; they also reported that a scheduled review of the guideline, such as in the present study, is necessary.<sup>6</sup>

SCC of the lip is a relatively rare tumor. In the present study its incidence was 3.1/1 male inhabitants and 0.4/1 female inhabitants, but incidence can vary per region. Despite the relatively small number of lip malignancies various specialities e.g. general surgery, oral and maxillofacial surgery, ENT surgery, plastic surgery, radiotherapy, dermatology are involved in the examination and treatment. Both the rarity of a lip tumor and the number of disciplines involved may explain the low level of compliance and emphasize the need to achieve maximum uniformity in diagnosis, staging and treatment.

Although it is reported that there is better compliance for higher incidence tumors (e.g. breast cancer) the risk still remains that compliance does not occur in accordance with this guideline.<sup>24</sup> It is therefore recommended that, especially for rare tumors, the management be centralized in specialized institutions to maximize control over guideline implementation and to minimize the number of specialties involved.

The CCCN has a regional function. It is well known that nationally developed standards and consensus statements generally have more limited acceptance and influence than regional or local guidelines.<sup>1, 6</sup> In the present study, evaluating the use of a regional guideline in which representatives from all hospitals were involved in its design, a good level of implementation may be expected. The results, however, indicate that this assumption is not always justified. To improve the motivation of the treating physicians it is important that they recognize the basic rationale behind and the consequences of patient management according to the guideline. Moreover, the recommendation to incorporate ‘specific reminders’

during the ongoing interdisciplinary discussions should be considered in order to increase the level of implementation.<sup>25, 26</sup> This may especially be important when dealing with infrequent malignancies.

In all of these arguments it is essential that guidelines be easily translatable to the daily clinical practice,<sup>3, 27</sup> be easily accessible for the user and should be available in a quick and efficient manner. The incorporation of the guideline within an electronic patient record may help to achieve this, particularly with the increasing use of desktop electronic systems for the storage of medical records.

## References

1. Grimshaw JM, Russell IT. Effect of clinical guidelines on medical practice: a systematic review of rigorous evaluations. *Lancet* 1993; 342: 1317-22.
2. Lomas JL, Anderson GM, Domnick-Pierre K, Vayda E, Enkin MW, Hannah WJ. Do practice guidelines guide practice? The effect of a consensus statement on the practice of physicians. *New Engl J Med* 1989; 321: 1306-11.
3. Field MJ, Lohr KN, editors. Committee on Clinical Practice Guidelines, Division of Health Care Services Institute of Medicine; Guidelines for clinical practice: from development to use. Washington, D.C.: National Academy Press, 1992.
4. Lombarts MJMH, Everdingen JJE van, Theuvenet PJ, Casparie AF. Report consensus concerning medical-specialist guidelines. (in: Dutch: Rapport consensus over medisch-specialistische richtlijnen.) Utrecht: CBO, 1996.
5. Eddy DM. Designing a practice policy standards, guidelines and options. *JAMA* 1990; 263: 3077-84.
6. Grimshaw J, Russell I. Achieving health gain through clinical guidelines. I: Developing scientifically valid guidelines. *Qual Health Care* 1993; 2: 243-8.
7. Brook RH. Practice guidelines and practicing medicine: are they compatible? *JAMA* 1989; 262: 3027-30.
8. Tijsen JGP, Simoons ML, Van Everdingen JJE. National guidelines for clinical activity, a methodological essay. (Landelijke richtlijnen voor het klinisch handelen, een methodologische beschouwing.) *Ned T Geneesk* 1998; 142: 2078-82.
9. Eddy DM. Guidelines for policy statements: the explicit approach. *JAMA* 1990; 263: 2239-43.
10. Otter R. Guidelines for diagnosis and treatment of premalignant and malignant diseases in the Comprehensive Cancer Centre Northern Netherlands region. (in Dutch: Richtlijnen voor diagnostiek en behandeling van premaligne en maligne aandoeningen in de IKN regio) Groningen, Dijkhuizen Van Zanten bv, 1992: 341-9.
11. Otter R. Guidelines for diagnosis and treatment of premalignant and malignant diseases in the Comprehensive Cancer Centre Northern Netherlands region. (in Dutch: Richtlijnen voor diagnostiek en behandeling van premaligne en maligne aandoeningen in de IKN regio) Groningen, Dijkhuizen Van Zanten bv, 1994: 371-81.

12. Sobin LH, Wittekind CH, eds. International Union Against Cancer (UICC). TNM classification of malignant tumours, 5th ed., Springer: Berlin, 1997.
13. Cummings CW, Fredrickson JM, Harker LA, Krause CJ, Schuller DE, Richardson MA, ed. Malignant neoplasms of the oral cavity. In: Otolaryngology Head and Neck Surgery. St. Louis: Mosby 1998: 1443-62.
14. Gooris PJJ, Maat B, Vermey A, Roukema JA, Roodenburg JLN. Radiotherapy for cancer of the lip. *Oral Surg, Oral Med, Oral Pathol* 1998; 86: 325-30.
15. Renner GJ, Zitsch RP. Cancer of the lip. In: Myers EN, Suen JY, ed. *Cancer of the Head and Neck*. Philadelphia: W.B. Saunders Company, 1996: 294-320.
16. De Visscher JGAM, Schaapveld M, Otter R, Visser O, van der Waal I. Epidemiology of cancer of the lip in the Netherlands. *Oral Oncol* 1998; 34: 421-6.
17. Jovanovic A, Schulten EAJM, Kostense PJ, Snow GB, van der Waal I. Squamous cell carcinoma of the lip and the oral cavity in the Netherlands: an epidemiological study of 740 patients. *J Cranio-Maxillofac Surg* 1993; 21: 149-52.
18. Paniello RC, Virgo KS, Johnson MH, Clemente MF, Johnson FE. Practice patterns and Clinical Guidelines for Posttreatment Follow-up of Head and Neck Cancers. *Arch Otolaryngol Head Neck Surg* 1999; 125: 309-13.
19. Deleyiannis FWB, Thomas DB. Risk of lung cancer among patients with head and neck cancer. *Otolaryngol Head Neck Surg* 1997; 116: 630-6.
20. Tepperman BS, Fitzpatrick PJ. Second respiratory and upper digestive tract cancers after oral cancer. *Lancet* 1981; II: 547-9.
21. Buwalda J, Zuur CL, Lubsen H, Tijssen JGP, Koole R, Hordijk GJ. Annual chest radiography in patients treated for laryngeal or oral cancer: limited number of detected second primary cancers in the lung. (in Dutch: Jaarlijkse thoraxfoto bij patienten na behandeling wegens een larynx- of een mondholtcarcinoom: slechts beperkt rendement ten aanzien van tweede primaire tumoren in de long.) *Ned Tijdschr Geneesk* 1999; 143: 1517-22.
22. Parkin DM, Pisani P. Chest X-ray screening does not improve outcome in lung cancer [letter]. *Chest* 1996; 110: 304.
23. Rowe DE, Carroll RJ, Day CL. Prognostic factors for local recurrence, metastases, and survival rates in squamous cell carcinoma of the skin, ear and lip. Indications for treatment modality selection. *J Am Acad Dermatol* 1992; 26: 976-90.
24. Ford LG, Hunter CP, Diehr P, Frelick RW, Yates J. Effects of patient management guidelines on physician practice patterns: The community hospital oncology program experience. *J Clin Oncol* 1987; 5: 504-11.
25. Haines A, Feder G. Guidance on guidelines. Writing them is easier than making them work. *Br Med J* 1992; 305: 785-6.
26. McPhee SJ, Adair Bird J, Jenkins CNH, Fordham D. Promoting cancer screening. A randomized, controlled trial of three interventions. *Arch Intern Med* 1989; 149: 1866-72.
27. Lilford RJ, Kelly M, Baines A et al. Effect of using protocols on medical care: randomized trial of three methods of taking an antenatal history. *Br Med J* 1992; 305: 1181-4.



## Chapter 3

### Radiotherapy for Cancer of the Lip

#### *A Long Term Evaluation of 85 Treated Cases*

P.J.J. Gooris<sup>1</sup>, B. Maat<sup>2</sup>, A. Vermey<sup>3</sup>, J.A. Roukema<sup>4</sup>, J.L.N. Roodenburg<sup>5</sup>

---

<sup>1</sup>Department of Oral and Maxillofacial Surgery  
Amphia Hospital Breda, The Netherlands

<sup>2</sup>Dr. Bernard Verbeeten Radiotherapeutic Institute, Tilburg

<sup>3</sup>Department of Surgery/ Head and Neck Surgery  
Groningen University Hospital, The Netherlands

<sup>4</sup>Department of Surgery, Elisabeth Hospital, Tilburg

<sup>5</sup>Department of Oral and Maxillofacial Surgery/ Oncology  
Groningen University Hospital, The Netherlands

Oral Surgery, Oral Medicine, Oral Pathology, Oral Radiology and Endodontics 1998; 86: 325-330



## Abstract

The results of radiation therapy, both as a single treatment modality and after microscopically irradical surgery for squamous cell carcinoma of the vermilion surface/border of the lip, are retrospectively analyzed in 85 patients.

All recurrences (7%) occurred in T2 and T3 tumors treated with external beam radiotherapy only. The long-term aesthetic result and functional morbidity are evaluated. Referral patterns are discussed, and the need for a multidisciplinary treatment protocol is emphasized.

## Introduction

In the Netherlands the incidence of cancer of the vermilion zone of the lips is 2.2 per 100,000 for males and 0.3 per 100,000 for females per year.<sup>1</sup> Most of these cancers are squamous cell carcinomas, and the lower lip is involved in 90% of cases.<sup>2, 3</sup> In people who are white, prolonged exposure to sunlight has been described as a major etiologic factor, and many patients with lip cancer have or have had outdoor occupations. Another factor is the abuse of tobacco, often in combination with alcohol consumption.<sup>4, 5</sup>

The treatment modalities for cancer of the lip are surgery, radiotherapy and the combination of the two.<sup>6-8</sup> T1, T2 and T3 carcinomas can be successfully treated by surgery or radiotherapy alone.<sup>9, 10</sup> Advanced primary cancer (T4) requires a planned combination of surgery and radiotherapy.<sup>9, 11</sup> In a T4N0 tumor, elective treatment of the neck is indicated, consisting of radiotherapy or selective neck dissection (or both). A therapeutic neck dissection (N+) is always followed by irradiation, except for cases with a single positive node, less than 3 cm in the first echelon, without extracapsular spread i.e., planned combination treatment.

Postoperative radiotherapy is sometimes used if the definitive pathology report indicates that the tumor has not been radically removed. The microscopic extent of the tumor then requires a mutilating re-resection. In this situation the surgeon and patient wish to avoid further excisional and reconstructive surgery. This choice of "less mutilating" radiotherapy represents a combined treatment on indication.

In this study, data from a group of 85 patients treated for squamous cell carcinoma of the vermilion zone of the lip are retrospectively analyzed. Pattern of care, local control, and cosmetic, functional and oncologic results are evaluated and discussed.

## Patients and Methods

During the period from January 1, 1974 to January 1, 1994, 85 patients were referred to the Dr. Bernard Verbeeten Radiotherapeutic Institute, Tilburg, The Netherlands, for treatment of squamous cell carcinoma of the lip. These 85 patients were selected individually during a pretreatment consultation. The total group consisted of 79 men (93%) and 6 women (7%), with a mean age of 66 years (range, 30-92 years; median, 67 years). All patients were white and fair-skinned.

Most tumors (93%) were located in the lower lip. The other 7 % were equally divided between the upper lip (3.5%) and the oral commissure (3.5%). All tumors were redefined accurately according to the 1992 Union Internationale Contre le Cancer tumor node metastases classification.<sup>12</sup> Our study involved 55 T1N0M0 cases, 26 T2N0M0 cases and 4 T3N0M0 cases.

Various medical disciplines were involved in the referral for radiation treatment; most of the patients were referred by dermatologists (51) and general surgeons (26), whereas plastic surgeons (5), oral and maxillofacial surgeons (2) and ophthalmologists (1) were involved to a much lesser degree.

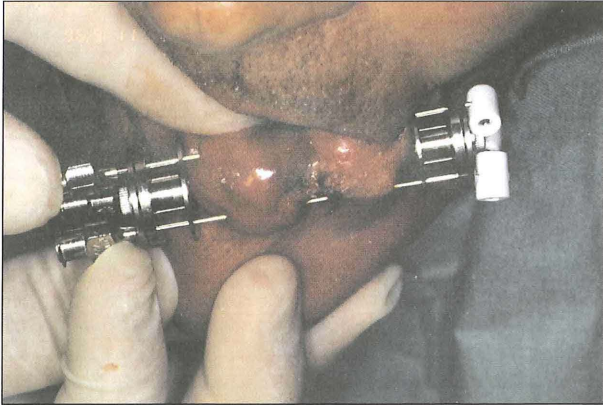The average time span between the incisional or excisional biopsy and the first consultation at the Radiotherapeutic Institute was 2.5 weeks (range, 1-4 weeks). There was no significant delay between the date of consultation and the start of radiation treatment (1-10 days).

According to the different treatment methods, the total set of 85 patients was divided in 2 groups, each of which was further divided in 2 subgroups each (Table 1).

Group 1 (66 patients) received radiation therapy only, either by external beam radiation (EBRT; subgroup 1A; 54 patients) or by brachytherapy (BT; subgroup 1B; 12 patients) (Fig. 1).

**Table 1** *Division of 85 patients according to different treatment methods*

Subgroup	Treatment	n
1A	EBRT	54
1B	BT	12
2A	surgery/EBRT	15
2B	surgery/BT	4
<b>Total</b>		<b>85</b>



**Figure 1**

*The arrangement of Iridium needles (afterloading interstitial brachytherapy) for treatment of squamous cell carcinoma of the lower lip.*

Group 2 (19 patients) received combined treatment, which consisted of surgery followed by EBRT (subgroup 2A; 15 patients) and surgery followed by BT (subgroup 2B; 4 patients). In all surgical cases a histologically proven incomplete removal of the tumor was the indication for the postoperative radiotherapy.

Different qualities of external radiotherapy were applied. This therapy consisted of orthovoltage (200-300 kV), and megavoltage electrons of relatively low energy (2-10 MeV).

With regard to the differences in relative biologic effectiveness (RBE) among the several beam qualities, it can be said that a total dose of 5100 cGy administered in 17 daily fractions of 300 cGy each, delivered with orthovoltage, or 5400 cGy in 18 daily fractions of 300 cGy each, delivered with megavoltage, both 5 times per week, and over a total time of 4 weeks, can be considered radiobiologically equivalent to a total dose of 6000 cGy administered in 30 daily fractions (at the megavoltage) of 200 cGy each, 5 times per week and over a total time of 6 weeks, as well as to a total dose of 6000 cGy delivered by an implant (BT) with a low dose rate (40-80 cGy/hr).

Subgroup 1A (EBRT; 54 patients), consisted of 37 patients with T1 lesions, 15 patients with T2 lesions, and 2 patients with T3 lesions. Subgroup 2A (surgery followed by EBRT; 15 patients) consisted of 8 patients with T1 lesions, 6 with T2 lesions and 1 patient with a T3 lesion. In each case, the total dose applied varied between 5100 and 5400 cGy, which was administered in a total number of 17 or 18 fractions at 300 cGy per fraction per day, 5 days per week. A 1-1,5 cm area around the tumor was included to establish a sufficient field size.

The 12 patients in subgroup 1B (BT), each of whom had carcinoma of the lower lip, received interstitial therapy only. In this subgroup, T1 lesions were recorded in 7 patients, T2 lesions in 4 patients, and a T3 lesion in 1 patient.

Subgroup 2B (surgery followed by BT) was composed of 4 patients; of these, 3 appeared for treatment with T1 lesions and 1 with a T2 lesion.

For BT, Iridium-192 wires were used. In each case 3 wires were positioned in a triangular fashion. A pre-treatment calculated dose rate was applied. The mean calculated dose rate was 63.54 cGy per hour. The total dose used for BT varied between 6000-7000 cGy (mean 6162 cGy; median, 6450 cGy). There was an overall short treatment time of 3 to 7 days.

The follow-up period was measured in months from the start of radiotherapy to the last follow-up visit; the mean value was 56 months (range 3-220 months; median, 46 months) for the entire set of 85 patients.

A local aesthetic and functional result survey was carried out, including evaluation for early and late cosmetic results and functional morbidity. The early results reflected the post-radiation effects appearing 0-4 weeks following radiation; the late results reflected the long-term cosmetic and functional effects, evaluated at least 1 year after radiation therapy.

The early reactions related to the irradiation were evaluated according to a scale describing the severity of the reaction (no reaction; mild, moderate or severe reaction). A *mild* or *moderate* reaction referred to mucositis; a *severe* reaction consisted of ulceration resulting from radiation therapy.

Late cosmetic result and morbidity were investigated in 25 recalled patients by means of a questionnaire. An evaluation of the subjective and objective findings of the lip after the different forms of treatment was performed. Of the 50 surviving patients, a relatively small number (25) were able to complete the recall; 12 patients could not be contacted, and 13 patients refused further follow-up (because of advanced age, illness, etc.). Each of 2 patients had developed a second primary tumor and was treated a second time; thus there were 27 evaluation forms altogether.

The patients were asked to comment on esthetic appearance, dryness, and any abnormal sensation in and around the lip. They were also asked to comment on the function of the lip. The objective evaluation of the esthetic result, sensibility and/or motor disturbance of the lip was carried out by a surgeon and a radiotherapist separately.

Local tumor control, defined as tumor control at the primary tumor site was evaluated. Local recurrences, regional metastases, and second primary tumors were registered. Death resulting from lip cancer was recorded when it had been demonstrated by autopsy.

## Results

### Etiologic factors

Causal factors were recorded in 53 cases (62%). Of the patients in these cases, 12 were known to be non-smokers, 26 admitted they smoked cigarettes, and 15 were pipe smokers. With regard to alcohol consumption, 4 patients denied alcohol intake, and 32 patients admitted using alcohol on a regular basis; alcohol consumption was not recorded for the remaining 17 cases.

The degree of outdoor activity i.e. sun exposure was not adequately recorded. However, the post treatment evaluation of the 25 patients showed that 20 of these patients (80%) reported extensive outdoor activities during their employment.

### Pattern of care

All 52 patients referred by a nonsurgical discipline were treated by irradiation only. In 42% of the 33 patients referred by a surgical discipline, irradiation was applied as the only treatment method; in the other 19 cases (58%) incomplete surgical removal was the indication for radiotherapy.

In 71 patients (84%) multidisciplinary pre-treatment planning was not carried out adequately.

### EBRT (subgroup 1A)

In this subgroup of 54 patients, 4 recurrences (7%) were observed. Local control was achieved in all 37 T1 lesions, but the local control rate decreased for the T2 lesions (12/15; 80%) and even more so for T3 lesions (1/2; 50%).

Table 2 presents an overview of the T classification of the original primary tumors that recurred. Each of the 4 patients with recurrent tumor was treated by

**Table 2** *Recurrences/metastasis after external beam radiotherapy only*

T stage	Recurrences/ metastasis	Total dose (cGy) to primary tumor/fractions	Date of recurrence/ metastasis (months)	Death
2	rec	5400/18	10.5	I
2	rec	5400/18	4	N
2	rec	5100/17	12	I
3	rec	5400/18	7.5	
1	meta	5400/18	46	

N = neoplasma, I = intercurrent

repeated radiotherapy (1), a surgical procedure (2) or a combination of both treatment methods (1).

Three of the 4 subgroup 1A patients with local recurrences died; of these, 2 died because of intercurrent disease. One patient died from a condition that was secondary to the lip tumor, this patient had initially appeared for treatment with a T2 tumor; which was originally treated with 5400 cGy in 18 daily fractions, 5 fractions per week.

There was 1 patient in subgroup 1A who developed a regional lymph node metastasis without a local recurrence. This patient initially received 5400 cGy in 18 fractions for a T1N0M0 tumor. The regional metastasis, located in the submental nodes, appeared 46 months after primary radiation therapy. A neck dissection followed by radiation treatment was carried out. The patient is still free of disease, 69 months after treatment.

### **BT (subgroups 1B and 2B)**

Of the 12 patients in the BT subgroup (1B) and the 4 patients in the surgery/BT subgroup (2B), 7 patients received 6000 cGy, 8 patients received 6500 cGy, and 1 patient received 7000 cGy. In all of these patients, tumor control was achieved.

### **Surgical treatment followed by EBRT (subgroup 2A)**

In all 15 patients of this subgroup, local tumor control was obtained at the primary tumor site. In each of two patients a second primary tumor developed. One patient developed another carcinoma on the contralateral side of the lip 6 years after treatment of the initial tumor. The other patient developed a second primary tumor at the contralateral commissure 11 years after treatment.

### **Early and late morbidity**

Within the entire set of 85 patients, evaluation of early cosmetic and functional morbidity showed that 17 patients (20%) showed a mild tissue reaction, 64 patients (75%) exhibited a moderate reaction, and 4 patients (5%) developed a severe reaction.

In the group with the mild to moderate reactions (mucositis), a total dose of 5400 cGy (EBRT) was applied. Of the 4 patients who developed severe reactions, 2 patients received 5400 cGy (EBRT) and 2 patients received 6500 cGy (BT).

The results of late morbidity, which were evaluated in a recalled group, are shown in Table 3 and 4. No patients of subgroup 2B were involved in the late



**Table 3** *Patients experience of functional and esthetic results.*

Late cosmetic and functional morbidity evaluation 27/85	Subgroup					
	EBRT n=19/54		BT n=3/16		surg/EBRT n=5/15	
	n	%	n	%	n	%
Satisfied with esthetic appearance	17	89	3	100	5	100
Sensation						
Numbness	6	32	0		0	
Pain/burning	1	5	0		0	
Discomfort (n.o.s.)	1	5	1	33	2	40
Dryness	10	53	2	67	2	40
Function						
Mouth opening limited	0		0		1	20
Spilling of fluid	3	16	0		0	

n.o.s. = not otherwise specified

**Table 4** *Doctors evaluation of functional and esthetic results.*

Late cosmetic and functional morbidity evaluation 27/85	Subgroup					
	(1A) EBRT n=19/54		(1B) BT n=3/16		Surg/EBRT n=5/15	
	n	%	n	%	n	%
Esthetics						
Teleangiectasia	1	5	0		0	
Atrophy	4	21	0		0	
Scarring/Fibrosis	2	11	0		4	80
Sensibility						
Hyperesthesia	1	5	0		1	20
Hypoesthesia	6	32	0		2	40
Anesthesia	1	5	0		0	
Motor response						
Abnormal function	4	21	0		1	20

morbidity survey. In one patient of subgroup 2A, the treatment resulted in limited mouth opening, most likely because of the surgical intervention.

Table 4 shows the results of the objective evaluation by a surgeon and a radiotherapist. Although in many cases an abnormal esthetic appearance was

objectively assessed, only very minor abnormalities actually existed. The overall esthetic appearance was good regardless of the treatment method.

Abnormal function was noted in 4 patients (21%) of the EBRT subgroup (1A) and in 1 patient (20%) of the combined treatment subgroup (2A).

There was no sensory or motor dysfunction in the BT subgroup (1B).

### Survival

Of the total set of 85 patients, 36 died during the follow-up period. Only 1 of these patients died because of the lip carcinoma.

For the 5 year follow up evaluation, 36 patients were available; this included the patient who later died because of a condition that was secondary to lip carcinoma. The actual 5-year survival rate was thus 97%. Locoregional control, measured as freedom from recurrences and/or metastasis, was achieved in 80 (94%) of 85 patients; when correction was made for the 12 patients which could not be contacted, a locoregional control figure of 68 (93%) of 73 patients resulted.

Of the 36 patients who died, each of 13 developed another primary malignancy. In 6 of these patients the other malignancy consisted of a basal cell carcinoma of the facial skin probably related to previous sun exposure; in addition, 2 of these patients developed more than one other malignancy. In each of 2 patients an intra-oral squamous cell carcinoma developed, and in each of 2 patients a malignancy of the lower digestive tract was recorded. In another 2 patients prostate malignancies occurred, and in 1 patient a bronchial cancer was diagnosed.

### Discussion

This group of 85 patients showed a male:female ratio of 13:1, which is higher than the usually reported ratio of 7:1.<sup>1</sup> The lower lip was involved in 93 % of the cases, and the upper lip and the oral commissure each contributed 3.5 % to the total. These findings are comparable with those of other studies.<sup>8, 13, 14</sup>

Chronic exposure to the ultraviolet radiation in sunlight is considered an important causative factor of actinic cheilitis. This premalignant condition may progress to a squamous cell carcinoma of the lip.<sup>15, 16, 17</sup>

During the post treatment evaluation of 25 patients, 20 (80%) described extensive outdoor activities during their employment. For these 20 patients the degree of sun exposure was greater than average because of their farming related

activities over a long period of time (10-38 years). This finding supports the importance of exposure to sunlight as potential etiologic factor in lip carcinoma.

The referral pattern of patients with lip carcinoma to the Radiotherapeutic Institute was quite variable. This may explain the differences in treatment planning; a patient referred by a surgical discipline is much more likely to undergo an excisional surgical procedure. Because 52 (61%) of the referrals were made by a non-surgical discipline, a relatively large number of the patients were treated with radiation therapy only. Clearly there was a lack of sufficient multidisciplinary pre-treatment planning, which resulted in inadequately structured decision-making between the different treatment modalities.

For smaller lip carcinomas (T1, T2, T3), surgery or radiotherapy alone gives good cure rates. The treatment of choice should ideally be determined by the location and the extent of the tumor, the expected morbidity, the age of the patient, and the potential risk for a second primary tumor.

Advantages of surgical treatment include the opportunity for performance of a pathologic evaluation and an overall shorter treatment period. There is no potential oncogenic effect with surgery in comparison with radiotherapy. In case of a recurrence or a second primary tumor in the same area, radiotherapy is still available. A surgical procedure with the need for wide margins may cause a functional and/or cosmetic deficit. However approximately 25-30% of the width of the lip can be removed without necessitating reconstructive surgery.

Radiotherapy may have a better cosmetic and functional outcome for the treatment of T2 and T3 lesions; however, one has to accept the transient but annoying side effect of mucositis.<sup>14, 18-20</sup> EBRT requires approximately 18 treatments at regular intervals over 24 days. BT requires a minor surgical procedure, usually performed with the patient under local anesthesia, to introduce the tubes into the lip; after tube insertion the patient spends 3-5 days in a radiation-protected room.<sup>21-26</sup>

BT was applied when a primary tumor with a relatively small volume (1-2.5 cm) was being dealt with at a distance from the oral commissure. The decision as to whether EBRT or BT was applied was mainly determined by the preference of the radiation-oncologist and the patient.

An interesting finding was that in 19 surgical cases incomplete removal of the tumor was the indication for radiation therapy. Although most (11) of these 19 lesions were T1 tumors, 7 were T2 tumors and 1 was T3 tumor. In all 19 cases, postsurgical radiation therapy could have been avoided if radical resection had been done. Frozen sections of margins during surgery are therefore mandatory for the sake

of ruling out residual disease. Similar findings and recommendations have been reported by Cruse.<sup>18</sup>

All 4 local recurrences occurred in the EBRT subgroup (1A), and all developed within one year after treatment of T2 and T3 primary tumors. These data suggest that T2 and T3 tumors may require a higher dose, a different radiation treatment schedule, or even surgical treatment. The literature supports the concept of a tumor-volume-dependent dose schedule.<sup>4, 6, 27, 28</sup> In our view this illustrates the need for a multidisciplinary approach to treatment planning.

The 2 patients who developed second primary tumors belonged to the combined treatment (surgery/EBRT) subgroup (2A); in one of these patients the second primary developed after 7 years, and in the other the second primary tumor developed after 11 years. An iatrogenic cause for the development of the second primary tumors (i.e., the radiation) cannot be ruled out. Radiation-induced carcinomas however, tend to occur more than 10 years after treatment.<sup>29</sup> In addition, continued exposure to sunlight of the dry irradiated lip, especially in young patients, may be a factor in the development of a second primary tumor.

Long-term evaluation of the lip after the different forms of therapy revealed that patients in the BT subgroups (1B and 2B) reported an acceptable esthetic appearance. The patients in the EBRT subgroup (1A) reported a relatively low acceptance of their esthetic appearance in 11% of cases. Long-term objective evaluation showed less esthetic results in the combined therapy group (2A and 2B), mainly because of scarring from the surgical intervention.

In the surgical group, only 1 patient reported limited mouth opening. Surprisingly, few of the patients who received EBRT mentioned leakage of saliva. This might have been related to a combination of the hypoesthesia and radiation fibrosis with consequent functional limitation of the lip.

Overall however, it should be emphasized that only a small number of patients (25) responded to the recall evaluation; therefore, no conclusions should be drawn from these data.

It was interesting that 13 (37%) of the 36 patients who died were diagnosed with second malignancies not related to their lip tumors. Of these 13 patients, each of 8 developed a second primary tumor with etiologic factors similar to those involved in lip carcinoma (eg, smoking and exposure to sunlight). However, whether the same carcinogenic factors were involved in both tumors in a given individual is unclear.

## Conclusions

1. Management of a patient with a lip carcinoma should be performed by a multidisciplinary team for the sake of achieving an overall consensus and optima protocol-based treatment of this localized disease.
2. Radiotherapy alone is an important treatment modality for squamous cell carcinoma of the lip; however, adequate dosing and treatment schedules are mandatory.
3. When a lip tumor is treated surgically, adequate resection should always be proved by intraoperative frozen sections of marginal tissue. This reduces the need for postoperative radiotherapy in most T1-3N0M0 cases.

## References

1. Otter R, Schouten L, eds. Head and neck tumours in the Netherlands 1989-1992. Netherlands Cancer Registry. Utrecht: Nederlandse Vereniging van Integrale Kanker Centra; 1995.
2. Hordijk GJ, Ravasz LA. Het hoofd-hals carcinoom. Houten: Bohn Stafleu van Loghum; 1989: 1-82.
3. Jovanovic A. Squamous cell carcinoma of the lip and the oral cavity: an epidemiological study. [thesis] Amsterdam: Free University Amsterdam; 1993.
4. Baker SR. Risk factors in multiple carcinomas of the lip. *Otolaryngol Head Neck Surg* 1980; 88: 243-8.
5. Blomquist G, Hirsch JM, Alberins P. Association between development of lower lip cancer and tobacco habits. *J Oral Maxillofac Surg* 1991; 49: 1044-7.
6. Kian Ang K., Kaanders J.H.A.M., Peters L.J. Radiotherapy for head and neck cancers: indications and techniques. Lea & Febiger 1994; 33-50.
7. Teichgraber JF, Larson DL. Some oncologic considerations in the treatment of lip cancer. *Otolaryngol Head Neck Surg*. 1988; 98: 589-92.
8. Visscher de JGAM, Grond AJK, Botke G, Waal van der I. Results of radiotherapy for squamous cell carcinoma of the vermilion border of the lower lip. A retrospective analysis of 108 patients. *Radiother Oncol* 1996; 39: 9-14.
9. Baker SR. Cancer of the lip. In Myers EN, Suen JY, editors. *Cancer of the head and neck*. 2nd ed. New York: Churchill Livingstone; 1989: 383-415.
10. Baker SR. Current management of cancer of the lip. *Oncology* 1990; 4: 107-20.
11. Kolin EJ, Castro D, Lutkin RB, Jobour BA, Hanafee WN. Perineural extension of squamous cell carcinoma. Imaging case study of the month. *Ann Otol Rhinol Laryngol* 1991; 100: 1032-4.
12. Hermanek D, Sobin LH, editors. *UICC TNM classification of malignant tumors*. 4th ed. 2nd rev. Berlin: Springer Verlag; 1992.

13. Shpitzer R, Steen Y, Segal U, Levy R. Carcinoma of the lip; observations on its frequency in females. *J Laryngol Otol* 1991; 105: 640-2.
14. Cerezo L, Liu FF, Tsang R, Payne D. Squamous cell carcinoma of the lip: analysis of the Princess Margaret Hospital Experience. *Radiother Oncol* 1993; 28: 142-7.
15. Linqvist C, Teppo L. Epidemiological evaluation of sunlight as a risk factor of lip cancer. *Br J Cancer* 1978; 37: 983-9.
16. Zelickson BD, Rocnigk RK. Actinic cheilitis treatment with the carbon dioxide laser. *Cancer* 1990; 65: 1307-11.
17. Chen J, Katz RV, Krutchkoff DJ, Eisenberg E. Lip Cancer Incidence trends in Connecticut, 1935-1985. *Cancer* 1992; 70: 2025-30.
18. Cruse CW, Radocka RF. Squamous cell carcinoma of the lip. *Plastic Reconstr Surg* 1987; 80: 787-91.
19. Jansma J. Oral sequela resulting from head and neck radiotherapy. Course, prevention and management of radiation caries and other oral complications. [thesis] Groningen: University Groningen; 1991.
20. Spijkervet FKL. Irradiation mucocitis and oral flora. Reduction of mucocitis by selective elimination of oral flora. [thesis] Groningen, University Groningen, 1989.
21. Friedrich RE, Krull A, Hellner D, Schwarz R, Heyer D, Plambeck K, Schmelzie R. Interstitial high-dose rate brachytherapy with iridium-192 in patients with oral squamous cell carcinoma. *J CranioMaxillofac Surg* 1995; 23: 238-42.
22. Henk IM. Treatment of oral cancer by interstitial irradiation using iridium-192. *Brit J Oral Maxillofac Surg* 1992; 30: 355-9.
23. Mould RF, Battermann JJ, Martinez AA, Speiser BL. Brachytherapy: from radium to optimization. Veenendaal: Nucletron International; 1994.
24. Orecchia R, Rampino M, Gribando S, Wegri GL. Interstitial brachytherapy for carcinomas of the lower lip: results of treatment. *Tumori* 1991; 77: 336-8.
25. Paine CH. Modern afterloading methods for interstitial brachytherapy. *Clin Radiol* 1972; 23: 263-72.
26. Pierquin B, Dutreix A, Paine CM, Chassaque D, Marinelle G, Ash D. The Paris system in interstitial radiation therapy. *Acta Radiol (Oncol)* 1978; 17: 33-48.
27. Moss WT, Brand WN, Battifora H. Radiation oncology: rationale, technique, results. St. Louis: C.V. Mosby; 1973: 93-100.
28. Wang CC. Radiation therapy for head and neck neoplasms. 3rd ed. New York: Wisley-Liss; 1997: 111-24.
29. De Vita VT Jr, Hellman S, Rosenberg SA. Cancer: principles & practice of oncology, 4th ed. Philadelphia: JB Lippincott Company; 1993: 2408-10.

### **Acknowledgement**

The authors would like to thank Mrs. E. van Peer, L.J. van Rijn DMD, W. van Saanen and L.D. Trimble MD, DMD for their contribution.

## Chapter 4

### **Carbon Dioxide Laser Evaporation of Leukoplakia of the Lower Lip**

*A retrospective evaluation*

P.J.J. Gooris<sup>1</sup>, J.L.N. Roodenburg<sup>2</sup>, J.M. Nauta<sup>2</sup>, A. Vermey<sup>3</sup>

---

<sup>1</sup>Department of Oral and Maxillofacial Surgery  
Amphia Hospital Breda, The Netherlands

<sup>2</sup>Department of Oral and Maxillofacial Surgery/ Oncology  
Groningen University Hospital, The Netherlands

<sup>3</sup>Department of Surgery/ Head and Neck Surgery  
Groningen University Hospital, The Netherlands

Oral Oncology 1999; 35: 490-495





## Abstract

### Purpose

Retrospective evaluation of the treatment results of CO<sub>2</sub> laser evaporation for 27 cases of leukoplakia of the lip.

### Patients and Methods

The data were derived from 23 patients who presented with leukoplakia of the lower lip during the period 1978-1996. Four patients developed a second primary leukoplakia of the lip resulting in 27 cases of leukoplakia.

All lesions were treated with a CO<sub>2</sub> laser equipped operation microscope and micromanipulator.

### Results

Short-term evaluation showed complete epithelialisation four weeks after CO<sub>2</sub> laser evaporation; there was minimal scar formation and no subsequent interference with normal lip function. During long-term evaluation, four recurrences (14.8%) were diagnosed which developed between 5 and 31 months after treatment; these were retreated with CO<sub>2</sub> laser evaporation.

There was no development of squamous cell carcinoma in the CO<sub>2</sub> laser treated area.

### Conclusions

Selective removal of affected epithelium with minimal damage to surrounding structures is possible using CO<sub>2</sub> laser evaporation, followed by excellent wound healing and good functional result. Treatment can be performed under local anesthesia on an outpatient basis. The recurrence rate is low compared with the recurrence rate after surgical excision.

Therefore, CO<sub>2</sub> laser evaporation is considered a reliable and effective treatment modality for leukoplakia of the lip.

## Introduction

Oral leukoplakia is a *clinical* diagnosis and is considered to be a premalignant lesion because there is morphologically altered tissue in which a malignancy is more likely to occur than in its apparently normal counterpart.<sup>1</sup> In 1978 the World Health Organisation defined oral leukoplakia as “a white patch or plaque of the oral mucosa that can not be characterized clinically or pathologically as any other disease”;<sup>2</sup> since then several amendments to this definition have been proposed.<sup>3, 4</sup> Recently, leukoplakia was redefined as “a predominantly white lesion of the oral mucosa that cannot be characterized as any other definable lesion; some oral leukoplakias will transform into cancer”.<sup>5, 6</sup>

The overall risk of malignant transformation (~5%) is related to the clinical and histological classification, and the localization of the lesion. Factors associated with an increased risk (>5%) of malignant transformation of a leukoplakia are gender (female); duration (years); idiopathy of the lesion; location (sites at risk: borders of the tongue, floor of the mouth and lower lip); clinical aspect (non-homogeneous); and presence of *Candida Albicans* and epithelial dysplasia on histological examination. Although dysplasia (with a five-fold increased risk compared with non-dysplastic lesions) is the most important predictor of malignant transformation, this does not necessarily mean that cancer will develop only in a dysplastic lesion. Even leukoplakia without dysplasia may transform into squamous cell carcinoma.<sup>6-15</sup>

Because leukoplakias of the lower lip have an increased tendency to malignant transformation, these lesions should be treated at an early stage. For this treatment a method should be used that is well tolerated by the patient and gives the best results possible as far as eradication of the lesion, wound healing and functional repair is concerned. Theoretically, use of the CO<sub>2</sub> laser appears to be such a method.<sup>16-19</sup>

The intrinsic property of the CO<sub>2</sub>-laser light is determined by its wavelength of 10.6 μm, being strongly absorbed in water. Tissue cells contain a large amount of water and the laser subsequently causes evaporation and cell membrane rupture.<sup>16-18</sup> There is a relatively bloodless field secondary to the coagulation of smaller blood vessels which enhances depth observation. Due to this property, superficial epithelial lesions can be selectively removed with minimal damage to surrounding tissues. The treatment can be performed under local anesthesia on an outpatient basis. Because the inflammatory response is relatively small, there is only mild postoperative pain and minimal edema. Wound healing occurs by sec-

ondary epithelialisation with minimal scarring, which is essential for optimal lip function after treatment.<sup>16, 17, 19, 20</sup> The elastic properties of the lip are better preserved after CO<sub>2</sub> laser surgery than after surgical excision.<sup>21, 22</sup> When using a CO<sub>2</sub> laser for oncological indications, there is no increased tendency to airborne and lymphatic or haematological spread of malignant cells, and no risk of inducing malignant tissue changes.<sup>17, 19</sup>

Therefore, in the Department of Oral and Maxillofacial Surgery at the Groningen University Hospital, evaporation with the CO<sub>2</sub> laser has been used for the treatment of oral leukoplakia since 1976. We report here our experiences with the laser in the treatment of leukoplakias of the lower lip.

## Patients and Methods


During the period 1978-96, 23 patients were treated for leukoplakia of the lower lip using CO<sub>2</sub> laser evaporation. The group comprised 20 men (mean age 64.8 years, range 51-83 years) and three woman (mean age 78.3 years, range 70-86 years).

Patients were referred from various disciplines; this referral pattern was analyzed. Of the 23 patients, 16 were surgically treated for a lip carcinoma prior to laser treatment of the leukoplakia. In these latter patients, the malignancy was considered an additional indication to treat the leukoplakia.

Complaints attributed to the leukoplakia, and etiological factors such as outdoor occupation, friction, and the use of tobacco and alcohol were recorded.

In all cases an incisional biopsy was taken before the CO<sub>2</sub> laser treatment. The leukoplakia was staged with regard to site, dimension, clinical aspect and histological classification, i.e. the degree of dysplasia. The number of histopathological features of epithelial dysplasia were scored according to 4 categories: no dysplasia, mild dysplasia, moderate dysplasia and severe dysplasia including carcinoma in situ.<sup>5, 6</sup>

Three laser systems have been used, all equipped with an operation microscope (Zeiss Opmi I) and a matching micromanipulator (Figure 1). Initially we used a Sharplan 791, then a Cavitron 33A, followed by our current system the Sharplan 1025 CO<sub>2</sub> laser. A defocused laser beam with a spot size of about 1 mm and output power of 8-10 watt was used.



**Figure 1**

*Photograph of the CO<sub>2</sub> laser unit, equipped with the operation microscope and the micromanipulator.*

All cases were treated with CO<sub>2</sub> laser evaporation. The treatment was carried out under local anesthesia and was performed by one surgeon on an outpatient basis. Postoperatively, the amount of analgesics used for pain management was recorded.

A follow-up examination was carried out 4 weeks postoperatively, 3 months after treatment and on a long-term basis (every 3 months until January 1998, or until death of the patient).

During follow-up the clinical aspect of the lip, and the amount of scarring and impairment of lip function were analyzed. The incidence of recurrence of leukoplakia and the elapsed time until the recurrent lesion was diagnosed were recorded, as was the development of a second leukoplakia of the lip. A second primary leukoplakia is considered to be a lesion, histologically corresponding with the first lesion (although with a variable degree of dysplasia), which develops in a different area of the same structure. In contrast to a recurrent lesion, a second lesion has to be separated from the first lesion by an area of normal healthy tissue.

## **Results**

### **Patients and leukoplakia**

Of the 23 patients, four developed a second primary leukoplakia resulting in a total of 27 cases of leukoplakia. Most of the patients (74%) were referred by medical specialists (general surgery seven; plastic surgery two; oral and maxillofacial sur-

gery six; dermatology two) while in three cases (13%) patients were referred by a dentist and another three (13%) were referred by general practitioners.

In the present study there was an 87% male predominance for the development of a leukoplakia of the lip.

An outdoor occupation was registered for 11 patients; for the remaining 12 this information was not available. Sixteen patients were smokers with a mean consumption of 17 (range 5-25) cigarettes per day for at least one year; there were three non-smokers and no information was available for four patients. Alcohol consumption was generally mild: a social alcohol consumption (1-2 units per day) was recorded for 19 patients; one patient refused alcohol intake and three patients reported a daily alcohol intake of three or more units. No frictional cause of leukoplakia was demonstrated. One case was diagnosed as idiopathic leukoplakia.

Of the 27 cases, only three reported complaints attributed to the leukoplakia consisting mainly of mild pain (i.e. irritation). Because of the minor discomfort, in 12 cases the duration of the lesion was reported as unknown, in three cases less than three months, in six cases less than six months, in four cases 6-12 months, and in two cases the duration of the lesion was more than 12 months.

Sixteen lesions measured less than 2 cm, 10 lesions 2-4 cm, and 1 lesion 4-6 cm. All but three lesions were clinically classified as homogeneous; the other three leukoplakias showed a non-homogeneous verrucous aspect.

The histology of the leukoplakia was classified. Acanthosis was present in 14/27 cases, hyperorthokeratosis in 12/27 cases and hyperparakeratosis was observed in 9/27 cases.

Of the 27 cases, 14 had no dysplasia, eight had mild dysplasia and three had moderate dysplasia; in two cases a carcinoma in situ was diagnosed (Table 1).

During follow-up of the 16 patients surgically treated for lip carcinoma, in seven the location of the leukoplakia corresponded with the location of the earlier malignancy; leukoplakia developed 3 to 238 months (mean 50.9 months) after

**Table 1** *Relation between clinical aspect of the leukoplakia and the corresponding degree of dysplasia<sup>1</sup>.*

Clinical aspect	Degree of dysplasia				Total
	None	Mild	Moderate	Severe	
Homogeneous	12	8	2	2	24
Verrucous	2	0	1	0	3
<b>Total</b>	14	8	3	2	27

<sup>1</sup>Values are numbers of cases.

treatment of the carcinoma. In 14/16 patients there was a homogeneous leukoplakia and in two patients a non-homogeneous verrucous type lesion was diagnosed. Histology of these 16 patients showed no dysplasia in seven, mild dysplasia in seven and moderate dysplasia in two patients.

The use of non-opiate analgesics was generally sufficient to manage postoperative pain.

During the early follow-up period (0-3 months) complete epithelialisation was observed within four weeks after treatment in 25/27 cases; in two cases delayed healing (six and nine weeks) was noted. At three months, clinically no abnormality or dysfunction of the lip was observed. No scarring was seen in 23/27 cases while in four cases only minimal scarring was noted without interference with lip function. Overall, the patients were satisfied with both the functional and aesthetic results.

During the follow-up period, 6/23 patients died, free of leukoplakia, due to intercurrent disease; their follow-up period ranged from 3 to 56 months (mean 18.5 months). Because of other diseases, two patients were unable to attend a recall visit; their follow-up period was limited to 6 and 14 months, respectively. The mean follow-up period of the remaining group of 15 patients was 75.6 months (range 12-192 months).

Long-term (> three months) evaluation showed that four patients had a second primary leukoplakia, which developed three to seven months (mean 5.3 months) after treatment of the primary leukoplakia.

In 4/27 cases (15%) a local recurrence of the leukoplakia was diagnosed; these recurrences developed 5, 19, 29 and 31 months (mean 21 months) after laser treatment of the primary leukoplakia.

All four recurrences were diagnosed in the patient group treated for squamous cell carcinoma of the lip prior to the leukoplakia.

In this recurrence group, all four primary leukoplakias presented as a homogeneous lesion; in three cases the lesion measured 0-2 cm and in one case 2-4 cm. Three of these cases had mild dysplasia and one case had a moderate degree of dysplasia.

Compared with the primary lesion, one case showed a corresponding degree of dysplasia in the recurrent lesion, while in two lesions there was a decrease and in the other an increase in dysplasia. There was no difference in size between the primary and recurrent leukoplakia (Table 2).

**Table 2** *Relation between the primary leukoplakia and recurrent leukoplakia with regard to the size and clinical aspect of the lesion, and the degree of dysplasia.*

	Primary leukoplakia (size, cm)				Recurrence of leukoplakia (size, cm)			
	0-2	2-4	0-2	0-2	0-2	2-4	0-2	0-2
Clinical aspect	hom	hom	hom	hom	hom	hom	verr	hom
Dysplasia	mod	mild	mild	mild	mild	mild	mod	none

hom = homogenous, mod = moderate, verr = verrucous

All recurrences were retreated by CO<sub>2</sub> laser evaporation; during the follow-up period (mean 56.8 months; range 13-147 months) no recurrent leukoplakia was observed.

There was no development of squamous cell carcinoma in the laser treated area during the entire follow-up period.

## Discussion

Proper evaluation of a white lesion of the vermilion border of the lip requires careful etiological, clinical and histological diagnosis. If a leukoplakia associated with risk factors is diagnosed, treatment is indicated. First of all etiological factors should be eliminated.

Treatment with retinoids, vitamin A, bèta carotene and topical application of bleomycine are not yet routine treatment modalities; these treatments generally have temporary effect and should only be given within a clinical trial setting with a careful follow-up and due attention for potential side-effects.<sup>23</sup>

Surgical excision (scalpel), cryosurgery and CO<sub>2</sub> laser evaporation can be used for treatment of leukoplakia with good cure rates. The advantage of an excision is that it allows histological examination of the whole specimen. In the presence of a larger lesion (>1 cm), however, the drawbacks include the need of reconstruction, cicatrization, loss of function and a poor aesthetic result. The recurrence rate after surgical excision ranges from 10 to 35%.<sup>24, 25</sup>

For cryosurgery less tissue damage is claimed. However, depending on the probe temperature and application time, the occurrence of cryonecrosis is difficult to monitor resulting in the risk of over- or undertreatment. Postoperative morbidity includes severe postoperative pain and prolonged wound healing. The recurrence rate after cryosurgery ranges from 13 to 25%.<sup>25, 26</sup>

In contrast to surgery and cryosurgery, CO<sub>2</sub> laser surgery can be used for both excision of the lesion and for selective evaporation of the affected epithelium (Figures 2 and 3). In 1983 we reported the results of CO<sub>2</sub> laser evaporation of superficial lesions of the oral mucosa in 54 patients.<sup>16</sup> Since then, CO<sub>2</sub> laser evaporation has proven to be an effective therapy for the treatment of oral premalignant lesions.<sup>16, 17, 19, 25, 27-31</sup> The local recurrence rate of CO<sub>2</sub> laser surgery is reported to range from 6 to 22%;<sup>6, 16, 25, 27, 28</sup> the recurrence rate in the present study was 4/27 (15%). When comparing our recurrence rate with that reported after surgery and cryosurgery, this is an acceptable result.<sup>6, 24-28</sup> In our patient group there was no correlation between the risk factors and the recurrence of leukoplakia.

In the present study, the incidence in males (87%) was high and may be correlated with a greater involvement of etiologic factors such as more smoking and an outdoor occupation. In all cases the leukoplakia was located on the lower lip; the everted aspect of the lower lip has a larger area of exposure to sunlight than the corresponding upper lip. For patients with an outdoor occupation, this larger area of exposure may explain why the lower lip is more often involved in (pre)malignant disease.

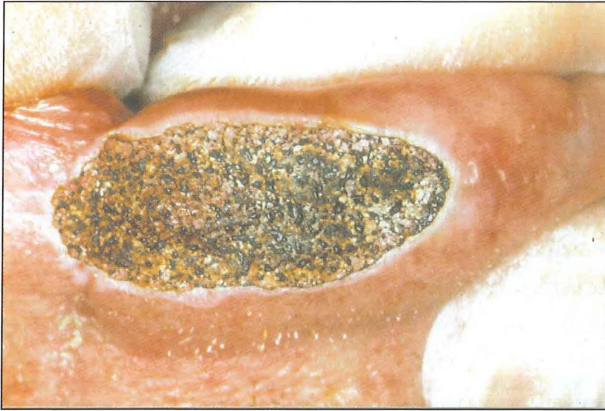Short-term follow-up after CO<sub>2</sub> laser evaporation showed excellent wound healing while during long-term follow-up no interference with normal lip function was observed (Figure 4).

The homogeneous type of leukoplakia of the lower lip (in this study 24/27) is usually asymptomatic and most patients therefore tend to wait (patient's delay) before seeking professional care. Despite this type of delay, in our study only 2/4 patients presented with a leukoplakia with severe dysplasia and/or carcinoma in situ.

All four recurrences were successfully retreated by CO<sub>2</sub> evaporation. The finding that 2/4 recurrences developed in the second primary leukoplakia supports the necessity of long-term follow-up.

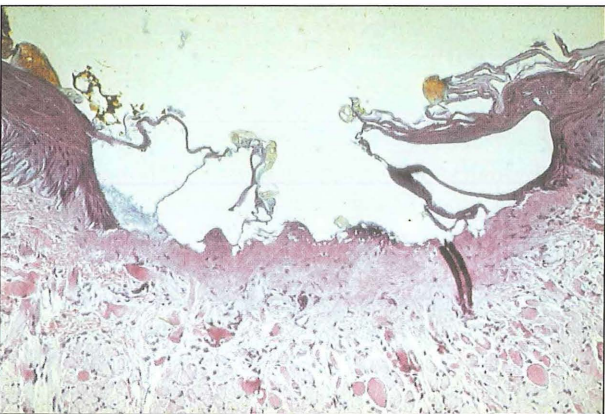A non-homogeneous aspect of leukoplakia and dysplasia are both signs of an increased risk of malignant transformation. Of the total group of 27 lesions, there was one recurrent lesion which had both risk factors; 2/27 showed a non-homogeneous verrucous aspect, but without dysplasia. Of the homogeneous lesions 8/24 presented with mild dysplasia, 2/24 with moderate dysplasia, and 2/24 with severe dysplasia (Table 1). According to the literature, the increased risk of malignant transformation of leukoplakia of the lip may range from 8 to 25%.<sup>32, 33</sup> In the present study, 15 lesions had an increased risk factor (3 verrucous lesions, 12 lesions with dysplasia) while no malignant transformation after CO<sub>2</sub> laser





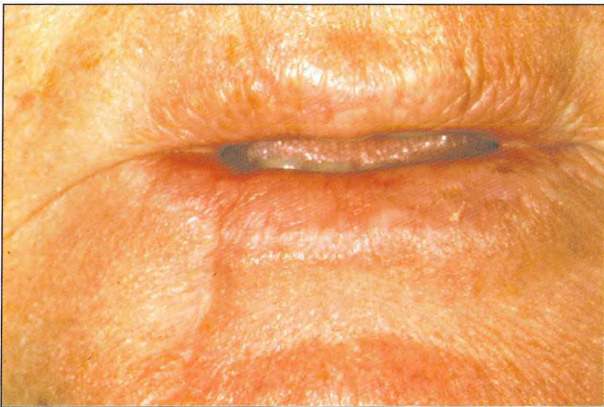**Figure 2**

*Photograph of the lower lip, immediately after treatment of leukoplakia with CO<sub>2</sub> laser evaporation.*



**Figure 3**

*Histological image of the area, as in Figure 2 treated with CO<sub>2</sub> laser evaporation; there is a zone of selective tissue removal. (Magnification =  $\times 40$ )*



**Figure 4**

*Photograph of the same lip as shown in Figure 2, six months after CO<sub>2</sub> laser treatment.*

treatment was observed. A cautious conclusion could be that CO<sub>2</sub> laser evaporation is an effective prophylactic treatment for malignant transformation of leukoplakia of the lower lip.

In summary, the advantages of CO<sub>2</sub> laser evaporation for treatment of leukoplakia of the lower lip are that it allows controlled selective removal of affected epithelium followed by excellent wound healing without functional or cosmetic disturbances of the lip, and low postoperative morbidity; the low recurrence rate (14.8%) in our study is favorable compared with the reported recurrence rate after surgery or cryosurgery. In addition, larger and multifocal lesions can be treated in several sessions under local anesthesia on an outpatient basis.

That use of CO<sub>2</sub> laser evaporation precludes histological examination of a specimen was previously considered an important disadvantage. However, after careful diagnosis, including one or even more incisional biopsies and a meticulous long-term follow-up, this method has proven to be a highly reliable treatment.

## References

1. Axéll T, Pindborg JJ, Smith CJ, Waal van der I and an International Collaborative Group on Oral White Lesions, with special reference to precancerous and tobacco related lesions: conclusions of an international symposium held in Uppsala, Sweden, May 18-21, 1994. *J Oral Pathol Med* 1996; 25: 49-54.
2. World Health Organisation, Collaborating Centre for Oral Precancerous Lesions. Definition of leukoplakia and related lesions: an aid to studies on oral precancer. *Oral Surg* 1978; 46: 518-39.
3. Axéll T, Holmstrup P, Kramer IRH, Pindborg JJ, Shear M. International seminar on oral leukoplakia and associated lesions to tobacco habits. *Comm Dental Oral Epidemiol* 1984; 12: 145-54.
4. Waal van der I, Bánóczy J and members. Panel Discussion, 23 August. 14th International Cancer Congress, Budapest, Hungary, 21-27 August 1986. Diagnostic and therapeutic problems of oral precancerous lesions. *Int J Oral Maxillofac Surg* 1986; 15: 790-8.
5. Schepman KP, Waal van der I. A proposal for a classification and staging system for oral leukoplakia: a preliminary study. *Oral Oncol, Eur J Cancer* 1995; 31 b: 396-8.
6. Waal van der I, Schepman KP, Meij van der EH, Smeele LE. Oral leukoplakia: a clinicopathological review. *Oral Oncol, Eur J Cancer* 1997; 33(5): 291-301.
7. Burkhardt A. Advanced methods in the evaluation of premalignant lesions and carcinomas of the oral mucosa. *J Oral Pathol* 1985; 14: 751-78.
8. Bánóczy J. In: Clinical and histopathological aspects of premalignant lesions. *Oral Oncol* Waal van der I, Snow GB eds, Martinus Nijhoff Publishing 1984; 3-31.
9. Scully C, Cawson R. Review. Potentially malignant oral lesions. *J Epidemiol Biostat* 1996; 1: 3-12.
10. Gupta PC, Mehta FS, Daftary DK et al. Incidence rate of oral cancer and natural history of oral precancerous lesions in a 10 year follow-up study of Indian villagers. *Comm Dental Oral Epidemiol* 1980; 8: 287-333.

11. Lumerman H, Freedman P, Kerpel S. Oral epithelial dysplasia and the development of invasive squamous cell carcinoma. *Oral Surg Oral Med Oral Pathol* 1995; 79: 321-9.
12. Abdel-Salam M, Mayall BH, Chew K, Silverman S Jr, Greenspan JS. Which oral white lesions will become malignant? An image cytometric study. *Oral Surg Oral Med Oral Pathol* 1990; 69: 345-50.
13. Pindborg JJ, Jolst O, Renstrup G, Roed-Petersen B. Studies in oral leukoplakia: A preliminary report on the period prevalence of malignant transformation in leukoplakia based on a follow-up study of 248 patients. *J Am Dental Assoc* 1968; 76: 767-71.
14. Silverman S Jr, Gorsky M, Kaugurs GE. Leukoplakia, dysplasia, and malignant transformation, Guest Editorial. *Oral Surg Oral Med Oral Pathol* 1996; 82: 117.
15. Hogewind WF, Kwast van der WAM, Waal van der I. Oral leukoplakia, with emphasis on malignant transformation. *J Craniomaxillofac Surg* 1989; 17: 128-33.
16. Roodenburg JLN, Panders AK, Vermey A, Verschueren RCJ. Treatment of superficial lesions of the oral mucosa with the carbon dioxide laser. *J Exp Clin Cancer Res* 1983; 3: 283-6.
17. Frame JW, Das Gupta AR, Dalton GA, Rhys Evans PH. Use of the carbon dioxide laser in the management of premalignant lesions of the oral mucosa. *J Laryngol Otolaryngol* 1984; 98: 1251-60.
18. Kardos TB, Holt T, Ferguson MM. Histological evaluation of the effect of a miniature carbon dioxide laser on oral mucosa. *Int J Oral Maxillofac Surg* 1989; 18: 117-20.
19. Catone GA. Laser management of oral precancer. In: Clayman I. *Lasers in Oral and Maxillofacial Surgery*. *Oral Maxillofac Surg Cl North Am* 1997; 9: 97-113.
20. Wilder-Smith P, Arrastia A, Lih-Heuh Liaw, Berns M. Incision properties and thermal effects of three CO<sub>2</sub> lasers in soft tissue. *Oral Surg Oral Med Oral Pathol* 1995; 79: 685-91.
21. Roodenburg JLN, Bosch ten JJ, Borsboom PCF. Measurement of the unaxial elasticity of oral mucosa *in vivo* after CO<sub>2</sub>-laser evaporation and surgical excision. *Int J Oral Maxillofac Surg* 1990; 19: 181-3.
22. Pogrel MA, Yen Chung-Kwan, Hansen LS. A comparison of carbon dioxide laser, liquid nitrogen cryosurgery, and scalpel wounds in healing. *Oral Surg Oral Med Oral Pathol* 1990; 69: 269-73.
23. Kaugurs GE, Silverman S Jr, Lovas JGL, Thompson JS, Brandt RB, Vishwa N. Use of antioxidant supplements in the treatment of human oral leukoplakia, Review Article. *Oral Surg Oral Med Oral Pathol* 1996; 81: 5-14.
24. Vedtofte P, Holmstrup P, Hjorting-Hansen E, Pindborg JJ. Surgical treatment of premalignant lesions of the oral mucosa. *Int J Oral Maxillofac Surg* 1987; 16: 656-64.
25. Roodenburg JLN, Panders AK, Vermey A. Carbon dioxide laser surgery of oral leukoplakia. *Oral Surg Oral Med Oral Pathol* 1991; 71: 670-4.
26. Kardos TB, Ferguson MM. Comparison of cryosurgery and the carbon dioxide laser in mucosal healing. *Int J Oral Maxillofac Surg* 1991; 20: 108-11.
27. Chu FWK, Silverman S Jr, Dedo HH. CO<sub>2</sub> laser treatment of oral leukoplakia. *Laryngoscope* 1988; 98: 125-30.
28. Horch HH, Gerlach KL, Schaefer HE. CO<sub>2</sub> laser surgery of oral premalignant lesions. *Int J Oral Maxillofacial Surg* 1986; 15: 19-24.

29. Roodenburg JLN, Horch HH. Der CO<sub>2</sub>-laser in der Mund-Kiefer-Gesichtschirurgie. *Fortschr Kiefer Gesichtschir* 1993; 38: 146-9.
30. Zelickson BD, Roenigk RK. Actinic cheilitis, treatment with the carbon dioxide laser. *Cancer* 1990; 65: 1307-11.
31. Dufresne RG, Curlin MU. Actinic cheilitis, a treatment review. *Dermatol Surgery* 1997; 23: 15-21.
32. Bánóczy J, Csiba A. Occurrence of epithelial dysplasia in oral leukoplakia. *Oral Surg Oral Med Oral Pathol* 1976; 42: 766-74.
33. Maerker R, Burkhardt A. Klinik oraler leukoplakien und präkanzerösen. retrospektive studie an 200 patienten. *Dtsch Z Mund-Kiefer-Gesichtschir* 1978; 2: 206-20.

## Chapter 5

# Frozen Section Examination of the Margins for Resection of Squamous Cell Carcinoma of the Lower Lip

P.J.J. Gooris<sup>1</sup>, A. Vermey<sup>2</sup>, J.G.A.M. de Visscher<sup>3</sup>, J.L.N. Roodenburg<sup>4</sup>

---

<sup>1</sup>Department of Oral and Maxillofacial Surgery  
Amphia Hospital Breda, The Netherlands

<sup>2</sup>Department of Surgery/ Head and Neck Surgery  
Groningen University Hospital, The Netherlands

<sup>3</sup>Department of Oral and Maxillofacial Surgery  
Leeuwarden Medical Center, The Netherlands

<sup>4</sup>Department of Oral and Maxillofacial Surgery/ Oncology  
Groningen University Hospital, The Netherlands

Journal of Oral and Maxillofacial Surgery, accepted (June 2002)



## **Abstract**

### **Objectives**

To evaluate the role of frozen section margin examination in the surgical management of squamous cell carcinoma of the lower lip.

### **Materials and Methods**

Frozen section examination of the resection surfaces of 131 consecutive patients surgically treated for squamous cell carcinoma of the lower lip during the period January 1980 until January 1999 were reviewed.

When invasive carcinoma or carcinoma in situ was present at the resection surface, the margin was defined as positive and re-resection was performed.

### **Results**

A positive margin during the surgical removal of the lip tumor was seen in 18/131 (14%).

In 8 patients (6%) a local recurrence developed.

### **Conclusions**

Frozen section examination for margin assessment in the surgical treatment of lip cancer is a reliable technique to control the radicality of the procedure; the indication for a secondary surgical procedure or postoperative radiotherapy can be reduced. However, a tumor free resection surfaces does not guarantee that local recurrence will not occur.

## **Introduction**

Cancers of the lower lip are almost exclusively squamous cell carcinomas (SCCLL). These tumors are primarily treated either by surgical excision, radiotherapy or a combination of these modalities.<sup>1-6</sup>

Well-controlled, radical excision of the tumor is most important when surgery is employed. Literature reports that obtaining clear surgical cut surfaces of the margin, which largely depends upon eradicating the tumor as well as all of its microscopic extensions will result in better local control of malignant disease.<sup>7-11</sup> Although a clear surgical margin does not guarantee that local recurrence will not

occur, it has been shown that involved surgical margins imply an increased risk of local recurrence and subsequently have an adverse effect on survival of patients with lip carcinoma.<sup>1, 8, 10-16</sup>

A margin of 5 to 10 mm of healthy appearing tissue is generally accepted when surgically removing a lip cancer.<sup>3-6, 11</sup> However, resection of the visible and palpable tumor mass including a wide margin does not always result in radical removal.<sup>4, 17, 18</sup> If, despite wide removal, frozen section analysis shows that the resection margin is not clear of malignant disease, re-excision should be performed and the new margin submitted for additional frozen section evaluation until a clear margin is obtained.<sup>4, 7</sup> It is therefore that frozen section analysis for peroperative margin assessment has become a valuable intra-operative guide in the management of SCCLL as it allows the surgeon to make an instant therapeutic decision which may prevent surgical reintervention or postoperative radiotherapy.<sup>12, 19-25</sup>

Apart from margin examination, frozen section is a most valuable tool to confirm the presence of malignant disease which has important implications for the further management of the patient with a malignancy.

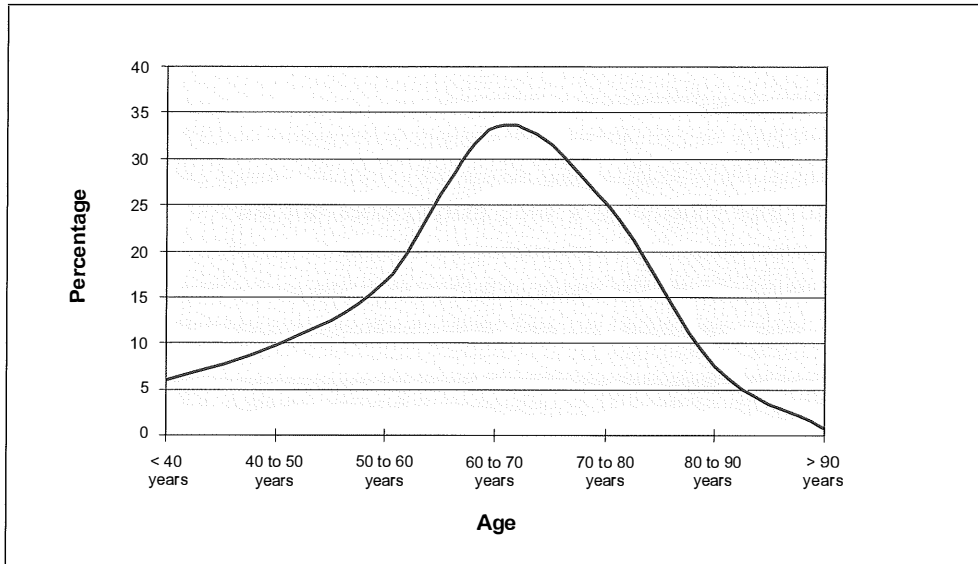
The purpose of this retrospective study was to establish the value of intraoperative frozen section examination for margin assessment in the surgical treatment of primary SCCLL. The impact of margin status on local recurrence was analyzed.

## **Patients and Methods**

The medical records of 131 consecutive patients diagnosed with a primary SCCLL were retrospectively reviewed. The patients were treated at the Department of Head and Neck Surgery and at the Department of Oral and Maxillofacial Surgery of the University Hospital Groningen during the period January 1980 until December 1998. All patients underwent surgical treatment including frozen section examination of the resection surface of the margins. Patients who received adjuvant radiotherapy and patients diagnosed with a second primary SCCLL were excluded from this study.

The study population included 115 men and 16 women. The mean age was 64 years, median 65 years (range 30-92 years) (Figure 1). The clinical tumor stage was assigned retrospectively according to the 1997 American Joint Committee on Cancer staging system, which corresponds with the UICC classification (Table 1). The surgical procedure consisted of a full thickness wedge-excision in 122 patients and a rectangular excision in 9 patients.





**Figure 1** *The age distribution in decades of 131 patients with a SCCLL.*

**Table 1** *Distribution of cTNM of SCCLL in 131 patients.*

TNM classification	Patients (n)	%
T1N0	119	91
T2	6	5
T3	3	2
T1N1	2	1
T2N2b	1	1
<b>Total</b>	<b>131</b>	<b>100</b>

The reports of the frozen section analysis with regard to the cut surfaces of both resection margins (full length, full thickness) were carefully reviewed. A distinction was made between a margin either positive or negative for tumor involvement. A surgical margin was classified as positive when there was carcinoma in situ or invasive carcinoma in the plane of the resection surface.

In this study, the presence of dysplasia at the resection surface was analyzed separately in this study as was a “close” margin i.e. tumor within 5 mm of that resection surface. Neither of these was considered as a positive margin in our patient group.

In case of a tumor positive margin on frozen section analysis, immediate re-resection during that same surgical procedure was performed. The wound was closed after a negative margin was confirmed.

When dysplasia was present at the margin, re-excision or CO<sub>2</sub> laser evaporation were used at a later stage as the treatment of choice versus close observation. Patients with a close margin preferably underwent observation.

The corresponding final histopathology report on paraffin section was reviewed and compared with the result of frozen section examination.

Tumors were classified as well differentiated, moderately differentiated, poorly differentiated or undifferentiated (Table 2).

The mean follow up of the 131 patients was 6.5 years, median 5.8 years (range 3-236 months).

The incidence of a local recurrence was recorded. A patient was designated as having a local recurrence if another lip cancer developed within 5 years after having been treated for a prior lip cancer and within 2 cm of that primary site.<sup>1,26</sup>

It was determined whether the patients who developed a local recurrence had a positive margin, close margin or dysplasia diagnosed on the frozen section specimen during the surgical excision of the lip tumor.

**Table 2** *Tumor grade of SCCLL in 131 patients.*

<b>Tumor grade</b>	<b>patients (n)</b>	<b>%</b>
Well differentiated	94	72
Moderately differentiated	33	25
Poorly differentiated	3	2
Undifferentiated	1	1
<b>Total</b>	<b>131</b>	<b>100</b>

## Results

A total of 131 patients underwent a frozen section cut surface assessment of the margins for resection during the surgical excision of the SCCLL. In 17/131 (13%) patients, examination of the frozen sections reported a tumor positive margin. In 5/17 (29%) positive margins, both resection surfaces were involved. Of the 17 patients with a positive margin, 16 patients were diagnosed with a T1N0M0 SCCLL, and in one patient with a T3N0M0 SCCLL.

Dysplasia at the margin was present in 13 patients. In 2 patients both tumor and dysplasia were diagnosed in the frozen section specimen of the margin. A 'close' margin was reported in 9 patients.

Table 3 shows the histopathologic grade related to the margin status.

In case of a positive margin, immediate re-resection was employed in all 17 patients. The post frozen section treatment is summarized in Table 4.

In one patient a negative report on frozen section cut surface of the margin was followed by positive findings of invasive tumor at the permanent paraffin section examination.

During the follow up period 8 (6 %) patients developed a local recurrence.

Of the 17 patients with a positive margin, 1/17 (6 %) patient developed a local recurrence. In 7/114 (6 %) patients with a negative margin on the initial surgical removal a local recurrence developed: in 2 patients dysplasia was diagnosed, in 2 other patients a close margin. In one of the above-mentioned patients, both dysplasia and a close margin was reported (Table 5).

The mean period of time between the surgical excision and the diagnosis of the local recurrence was 15 months, median 12 months (range 5-35 months).

**Table 3** Tumor grade of SCCLL related to frozen section margin assessment, degree of dysplasia at the margin and a "close" margin.

	Tumor grade				Total
	Well	Moderately	Severely	Undifferentiated	
<i>Frozen section</i>					
Free margin	86	26	2		114
Positive margin	7	8	1	1	17
Total	93	34	3	1	131
<i>Dysplasia</i>					
Total	11	2	0	0	13
<i>Close margin</i>					
Total	6	3	0	0	9

**Table 4** Type of treatment after the report of the frozen section margin assessment for SCCLL.

	Re-excision	XRT	CO <sub>2</sub>	Observation	Total
<i>Frozen section</i>					
Positive margin	17				17
<i>Dysplasia</i>	4	1	4	4	13
<i>Close margin</i>	1		2	6	9

XRT = Radiotherapy

**Table 5** *Relation between margin status, T-stage, tumor grade, the post frozen section treatment and development of local recurrence (n=8).*

	Margin positive	Margin negative			
		Dysplasia <sup>1</sup>	Close <sup>2</sup>	Both <sup>1 and 2</sup>	Absence of <sup>1 and 2</sup>
Local recurrence	1	1	1	1	4
TN-stage	T1N0	T1N0	T1N0	T1N0	T1N0 x 2 T1N1 T2N2b
Grade	well	well	mod.	well	mod. x 4
Post F.S. treatment	re-excision	obs.	obs.	obs.	no treatment

mod. = moderately

F.S. = frozen section

obs. = observation

dysplasia = dysplasia at the margin<sup>1</sup>

close = close margin<sup>2</sup>

## Discussion

Intra-operative frozen section was first performed by Welch in 1891 and has become a widely accepted method since.<sup>19</sup> It is well recognized that the use of the technique of frozen section examination, apart from providing an immediate diagnosis of the malignancy, plays an important role in determining the extent of the resected tumor and the adjacent margins.<sup>6, 10, 20</sup> The frozen section examination includes an assessment of the cut surfaces of both resection margins (full length, full thickness). A distinction should be made between a margin and the actual resection surface. The margin in fact consists of an area of “healthy” tissue surrounding the tumor which is confined by the resection i.e. cut surface. In this study, a margin was considered positive only when there was actual tumor involvement at the resection surface, although it has been reported that resection margins containing dysplasia or margins within 5 mm of carcinoma should also be regarded as positive.<sup>14, 17</sup>

Frozen section has proven to be a reliable technique for both diagnosis of the malignancy and for assessing the resection margin: the overall accuracy is generally high (>90%) in patients with a T1-T3 SCCLL tumor, depending on the source and nature of the material.<sup>6, 17, 20-23, 27, 28</sup> In the present study, in 1/131 patient the finding on frozen section of the cut surfaces was reported negative; subsequently positive tumor findings on the permanent paraffin specimen were diagnosed, resulting in an accuracy rate of 99%. The material used for paraffin section analysis

was different, more close to the tumor than the material used for frozen section margin examination.

When treating head and neck cancer, frozen section examination for margin assessment during tumor removal is commonly employed; when not treated adequately due to anatomic limitations or other patient factors, margins involved by tumor increase the likelihood of local failure.<sup>1, 7, 8, 10, 12-15, 17</sup> Re-excision should be performed, preferably during that same surgical session until a clear margin is obtained. Obviously, re-excision at a later stage or postoperative radiotherapy is uncomfortable for the patient and time consuming and should be avoided; length and costs of hospitalization will thereby be reduced. Moreover, reports on the role of additional radiotherapy differ: a relative ineffectiveness of adjuvant postoperative radiotherapy is reported in such cases.<sup>2, 5, 7, 8, 12, 17, 29, 30</sup>

When treating oral squamous cell carcinoma, depending on the site of the tumor, 1 to 2 cm of healthy appearing tissue is considered a "safe" margin to ensure tumor removal.<sup>3, 4</sup> In our study, the clinical width of the free margin was evaluated by palpation: a margin of 5 to 10 mm around the lip tumor was considered adequate for radical surgical excision. Despite this "safe" margin, there was a positive resection surface in 17/131 (13%) patients which necessitated re-excision. This finding emphasizes the need for frozen section margin assessment in lip tumor removal. The routine use of frozen section, depending on the site of the tumor, however may be questionable.<sup>31</sup>

Local recurrence after treatment of SCCLL occurred in 8/131 (6 %) of our patients. Apart from the lower lip as subsite, factors that correlate with increased risk of local recurrent disease include a size greater than 2 cm, depth of invasion 4 mm or more, poor histologic differentiation, perineural involvement, previous treatment (locally recurrent tumors), and malignancies in immunosuppressed patients.<sup>1, 32-34</sup> According to several reviews, local recurrence ranges from 1.5% (Mohs' surgery) to 35%; the results of the present study compare favorably with most of the published data.<sup>1, 4, 7-10, 14, 16, 27, 32, 33</sup>

In the present study, all patients with a positive margin by frozen section underwent an additional resection, which implicates that all 131 patients were treated with an eventually confirmed negative margin by frozen section analysis. This most likely explains why no differences in local recurrence rate were seen between the patient group diagnosed with a negative margin and the patient group diagnosed with a positive margin. In the patients, diagnosed with dysplasia (13 patients) and a close margin (9 patients), 2/13 (15 %) and 2/9 (22 %) patients respectively developed a local recurrence. The additional management of these four

patients consisted of observation. The patients with dysplasia who were treated with a re-excision (n=4), radiotherapy (n=1) or CO<sub>2</sub> laser evaporation (n=4) remained free of local disease, as did the remaining two patients who were followed by observation. These findings suggest that both confirmed dysplasia at the margin or a close margin, neither of which were considered a positive margin in this study, should be considered an indication for treatment.

In spite of a negative margin, local recurrence may still occur; local control of disease is not guaranteed.<sup>10, 11</sup> Either the margin is not truly negative or is close or field cancerization may occur.<sup>17</sup> Iatrogenic tumor spread by the surgical procedure itself may also contribute to local recurrence of malignant disease.

Because there are indications for the use of frozen section examination for margin assessment, there undoubtedly are limitations to its value. Besides the disadvantage of a prolonged operative time, frozen section examination can be limited by the degree of overall accuracy. Sampling of non representative tissue may interfere with the outcome of margin assessment.<sup>6, 23, 24, 28</sup>

In ideal circumstances the quality of an Hematoxylin & Eosin stained frozen section should approximate that of a section of routinely processed and paraffin embedded specimen. When the appropriate cutting temperature of the submitted tissue is not available however, artifacts may be encountered.<sup>6, 24</sup>

Another source of error is a false interpretation by the pathologist including inter-interpretation differences between pathologists. To maximize accuracy of margin assessment, there must be an effective communication between the surgeon and the pathologist involved.<sup>6, 7, 23</sup> When there is any doubt about the accuracy of the frozen section examination, the final pathology report on the paraffin sections remains the determinant for the definitive therapeutic approach.

Recently, there is an increasing interest in the use of more tissue saving surgical procedures.<sup>6, 25</sup> Especially in the face, there is a tendency to minimize free margins so as to preserve critical anatomic landmarks.<sup>6</sup> Because of the smaller width of the margin of "healthy" surrounding tissue in these patients, well controlled tumor resection will include a higher demand for frozen section margin evaluation.

In summary, the fact that in the present study 17/131 (13%) patients were diagnosed with a positive margin indicates that frozen section control of the margin is valuable. A positive resection surface requires immediate or early re-excision to enhance local control.

Therefore, our data and earlier reports allowed to conclude that frozen section examination of the margins provides a useful and accurate tool in the surgical

removal of a T1-T3 SCCLL, especially when the width of the margin is further reduced.<sup>7, 10, 19, 20, 30</sup>

However, a negative margin based on frozen section examination does not necessarily exclude the development of local recurrent tumor.<sup>10, 17, 28</sup> The surgeon must understand the limitations of frozen section: careful long term follow-up remains indicated.

## References

1. Zitsch RP, Park CW, Renner GJ, Lee Rea J. Outcome analysis for lip carcinoma. *Otolaryngol Head Neck Surg* 1995; 113: 589-96.
2. Veness M. Lip cancer: Important management issues. *Austr J Dermatol* 2001; 42: 30-2.
3. Hjortdal O, Naess A, Berner A. Squamous cell carcinomas of the lower lip. *J Cranio Maxillofac Surg* 1995; 23: 34-7.
4. Cruse CW, Radocha RF. Squamous cell carcinoma of the lip. *Plast Reconstr Surg* 1987; 80: 787-91.
5. Baker SR. Current management of cancer of the lip. *Oncology* 1990; 4: 107-24.
6. Campbell JP. Surgical management of lip carcinoma. *J Oral Maxillofac Surg* 1998; 56: 955-61.
7. Grover R, Douglas RG, Shaw JHF. Carcinoma of the lip in Auckland, New Zealand, 1969-1987. *Head Neck* 1989; 11: 264-8.
8. Loree TR, Strong EW. Significance of positive margins in oral cavity squamous carcinoma. *Am J Surg* 1990; 160: 410-4.
9. Mohs FE, Snow SN. Microscopically controlled surgical treatment for squamous cell carcinoma of the lower lip. *Surg Gyn Obst* 1985; 160: 37-41.
10. Byers RM, Bland KI, Borlase B, Luna M. The prognostic and therapeutic value of frozen section determinations in the surgical treatment of squamous cell carcinoma of the head and neck. *Am J Surg* 1978; 136: 525-8.
11. Chen TY, Emrich LJ, Driscoll DL. The clinical significance of pathological findings in surgically resected margins of the primary tumor in the head and neck carcinoma. *Int J Radiat Oncol Biol Phys* 1987; 13: 833-7.
12. Zieske LA, Johnson JT, Meyers EN, et al. Squamous cell carcinoma with positive margins: surgery and postoperative radiation. *Arch Otolaryngol Head Neck Surg* 1986; 112: 863-6.
13. Spiro RH, Guillaumondegui O, Paulino AF, Huvos AG. Pattern of invasion and margin assessment in patients with oral tongue cancer. *Head Neck* 1999; 21: 408-13.
14. Looser KG, Shah JP, Strong EW. The significance of "positive" margins in surgically resected epidermoid carcinoma. *Head Neck* 1978; 1: 107-11.
15. Ravasz LA, Slootweg PJ, Hordijk GJ, Smit F, van der Tweel I. The status of the resection margin as a prognostic factor in the treatment of head and neck carcinoma. *J Cranio Maxillofac Surg* 1991; 19: 314-8.

16. Cook A, Jones AS, Phillips DE, Soler Lluch E. Implications of tumour in resection margins following surgical treatment of squamous cell carcinoma of the head and neck. *Clin Otolaryngol* 1993; 18: 37-41.
17. Ord RA, Aisner S. Accuracy of frozen sections in assessing margins in oral cancer resection. *J Oral Maxillofac Surg* 1997; 55: 663-9.
18. Frable WJ. Accuracy of frozen sections in assessing margins in oral cancer resection: discussion. *J Oral Maxillofac Surg* 1997; 55: 669-71.
19. Challis D. Frozen section and intra-operative diagnosis. *Pathol* 1997; 29: 165-74.
20. Nakazawa H, Rosen P, Lane N, Lattes R. Frozen section experience in 3000 cases. *Am J Clin Pathol* 1968; 49: 41-51.
21. Kaufman Z, Lew S, Griffel B et al. Frozen section diagnosis in surgical pathology: A prospective analysis of 526 frozen sections. *Cancer* 1986; 57: 377-9.
22. Remsen KA, Lucente FE, Biller HF. Reliability of frozen section diagnosis in head and neck neoplasms. *Laryngoscope* 1984; 94: 519-24.
23. Gandour-Edwards RF, Donald PJ, Wiese DA. Accuracy of intra-operative frozen section diagnosis in head and neck surgery: experience at a university medical center. *Head Neck* 1993; 15: 33-8.
24. Ackerman IV, Ramirez GA. The indications for and limitations of frozen section diagnosis. A review of 1269 consecutive frozen section diagnoses. *Br J Surg* 1959; 46: 336-50.
25. Klimberg VS, Harms S, Korourian S. Assessing margin status. *Surg Oncol* 1999; 8: 77-84.
26. Warren S, Gates O. Multiple primary malignant tumors. A survey of the literature and a statistical study. *Am J Cancer* 1932; 16: 1358-414.
27. Holmkvist KA, Roenigk RK. Squamous cell carcinoma of the lip treated with Mohs micrographic surgery: Outcome at 5 years. *J Am Acad Dermatol* 1998; 38: 960-6.
28. DiNardo LJ, Lin J, Karageorge LS, Powers CN. Accuracy, utility, and cost of frozen section margins in head and neck cancer surgery. *Laryngoscope* 2000; 110: 1773-6.
29. Sadeghi A, Kuisk H, Tran LM et al. The role of radiation therapy in squamous cell carcinoma of the upper aerodigestive tract with positive margins. *Am J Clin Oncol* 1986; 9: 500-3.
30. Ikemura K, Ohya R. The accuracy and usefulness of frozen section diagnosis. *Head Neck* 1990; 12: 298-302.
31. Cataldo PA, Stoddard PB, Reed WP. Use of frozen section analysis in the treatment of basal cell carcinoma. *Am J Surg* 1990; 159: 561-3.
32. Renner GJ, Zitsch RP. Cancer of the lip. In: Myers EN, Suen JY. *Cancer of the Head and Neck*. 3rd edition Philadelphia : W.B. Saunders; 1996. 294-320.
33. Rowe DE, Carroll RJ, Day CL. Prognostic factors for local recurrence, metastasis, and survival rates in squamous cell carcinoma of the skin, ear, and lip. *J Am Acad Dermatol* 1992; 26:976-90.
34. Baker SR, Krause CJ. Carcinoma of the lip. *Laryngoscope* 1980; 90: 19-27.



# Surgical Margins for Resection of Squamous Cell Carcinoma of the Lower Lip

J.G.A.M. de Visscher<sup>1</sup>, P.J.J.Gooris<sup>2</sup>, A. Vermey<sup>3</sup>, J.L.N. Roodenburg<sup>4</sup>

---

<sup>1</sup>Department of Oral and Maxillofacial Surgery  
Leeuwarden Medical Center, The Netherlands

<sup>2</sup>Department of Oral and Maxillofacial Surgery  
Amphia Hospital Breda, The Netherlands

<sup>3</sup>Department of Surgery/ Head and Neck Surgery  
Groningen University Hospital, The Netherlands

<sup>4</sup>Department of Oral and Maxillofacial Surgery/ Oncology  
Groningen University Hospital, The Netherlands

International Journal of Oral and Maxillofacial Surgery 2002; 31: 154-7



## Abstract

A prospective study was undertaken to evaluate the efficacy of 3 mm margins of resection with surgical excision of squamous cell carcinoma of the lower lip (SCCLL) in its early stages whereby the margins were checked with the systematic use of frozen section examination. During the period 1991-1998, 72 consecutive patients with a primary stage I and II SCCLL underwent surgical excision as the initial treatment. There were 58 (81%) males and 14 (19%) females with a median age of 66.8 years (range 37-91). The majority of cases (94.4%) were stage I tumors. Treatment consisted of a full-thickness excision including a 3 mm margin of clinically uninvolved tissue. Intraoperative frozen section analysis of the margins of the excised specimen was used to confirm tumor-free margins. Clinically determined margins were tumor free in 89.9% on initial excision. The false-positive rate associated with frozen section analysis was 1.4%. Minimal follow-up for all patients was two years (median 5.1 years, range 2-9 years). Local recurrence was found in two (2.8%) patients. A 3 mm margin of clinically normal tissue with excision of early SCCLL seems to be appropriate, if the margins are controlled by systematic use of frozen section analysis.

## Introduction

Cancers of the lip cancer comprise almost exclusively squamous cell carcinomas (SCC's), the majority originating from the vermilion border of the lower lip. Lip cancer is predominantly a disease of elderly, fair-complexioned males. Although the incidence of SCC of the lower lip (SCCLL) varies throughout the world, it is a common malignancy of the head and neck.<sup>1</sup> Owing to the prominent location, SCCLLs are readily accessible for early detection. The vast majority of SCCLLs are diagnosed at an early stage.<sup>2-7</sup>

Early and medium sized tumors can be treated by surgery or radiotherapy. Both treatment modalities produce nearly similar cure rates.<sup>7, 8</sup> An advantage of radiotherapy is that it is non-invasive and in general offers better cosmetic and functional results, particularly in large tumors, as opposed to extensive surgery. The disadvantages of radiotherapy are its prolonged treatment time and the need for protection of the vulnerable, atrophic epithelium of the vermilion against environmental factors for a considerable period of time. For early and medium sized tumors, surgery offers several advantages including immediate eradication of the

disease, a one-stage procedure, absence of effect on adjacent normal tissue and the opportunity of assessment of radicality and various histological features of the primary tumor. Some of the histological parameters are thought to reflect the biological behavior of the tumor and seem to have prognostic value.<sup>4, 7, 9</sup> A major disadvantage of surgery is that it is an invasive procedure and results in loss of uninvolved tissue. Generally, surgical resection for primary SCCLL requires some kind of full-thickness excision including clinically uninvolved, surrounding tissue. The determination of what constitutes an adequate margin seems to be arbitrary and variable, ranging from 8-10 mm,<sup>2-6, 10-14</sup> although 3-5 mm margins seem to be sufficient.<sup>15, 16</sup> Smaller safety margins result in less sacrifice of normal tissue with potentially better preservation of function and cosmetic appearance.

The current study was undertaken to evaluate the results of surgical treatment of primary SCCLL with standard clinical margins of 3 mm of normal-appearing tissue, whereby the margins were checked with the systematic use of frozen section examination.

## **Patients and Methods**

The prospective investigation was carried out on a series of 72 consecutive patients with primary stage I and II SCCLL, who underwent surgical resection as the primary form of treatment at the Department of Oral and Maxillofacial Surgery of the Leeuwarden Medical Center between January 1, 1991 and January 1, 1999. The diagnosis of SCC was confirmed by an incisional or punch biopsy.

There were 58 (80.6%) males and 14 (19.4%) females with a median age of 66.8 years (range 37-91). All patients were Caucasian. The main characteristics of these patients are summarized in Table 1. Tumor sizes were clinically categorized in 5 mm intervals. Advanced tumors, e.g. T3 and T4 lesions, were treated by radiotherapy or a combination of surgery and radiotherapy and are, therefore, not included in this study.

Patients were operated on in an outpatient setting under uni- or bilateral mental nerve block anesthesia. Treatment consisted of a full-thickness V- or W-shaped excision including a standard 3 mm margin beyond the clinically recognized borders of the tumor (Figures 1A-B). When on palpation the entire tumor was larger than the visible portion of the tumor, the 3 mm margin was determined by the palpable tumor extension. Immediate assessment of the full-length of both margins of the excised specimen during surgery using frozen section examination was done to confirm

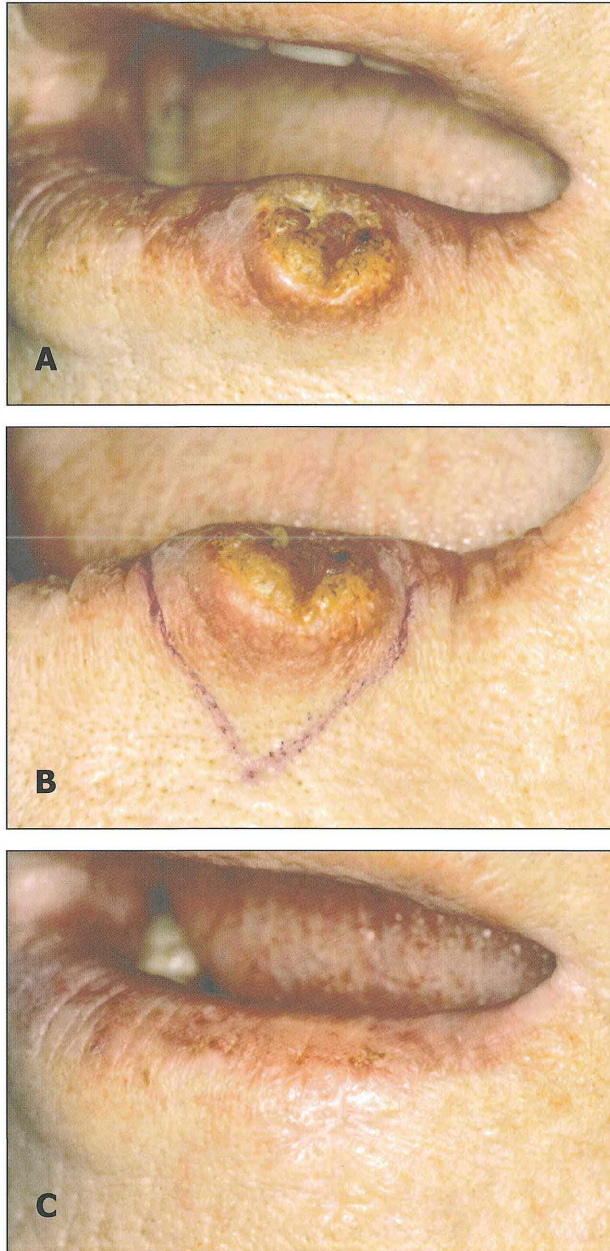
**Table 1** *Characteristics of 72 patients with squamous cell carcinoma of the lower lip*

Variable	No. of patients (%)
Gender	
Male	58 (80.6)
Female	14 (19.4)
Side lesion	
Left-side	30 (41.7)
Middle third	28 (38.9)
Right-side	14 (19.4)
Tumor size (mm)	
1-5	2 (2.8)
6-10	16 (22.2)
11-15	32 (44.4)
16-20	18 (25)
21-25	4 (5.6)
Differentiation grade	
Well	33 (45.8)
Moderately	37 (51.4)
Poorly	2 (2.8)
Undifferentiated	-
Follow-up in years; median	2-9; 5.1
Vital status at end	
Alive	57 (79.2)
Dead	15 (20.8)

tumor-free margins. The frozen section specimen consisted of the mucosal and the deep margin. Frozen section analysis took on average 20 minutes. Lesions with microscopic tumor at one or both margins were reexcised with an additional 3-mm margin until declared tumor-free by frozen section analysis (Figure 2). The defect was repaired by primary closure (Figure 1C).

After fixation, the resected specimen was cut into 2 to 3-mm thick vertical sections. Paraffin sections were also prepared of the assessed frozen sections. Histological criteria evaluated were tumor grade (well, moderately, poorly differentiated, undifferentiated), tumor thickness (measured by an ocular grid), growth pattern (endophytic or exophytic), invasion pattern (pushing or infiltrative borders), host response (scanty, moderate or intense) and perineural and vessel invasion.

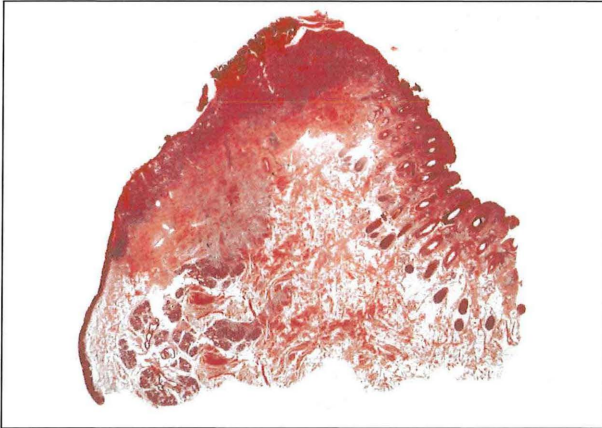
Minimum follow-up period for all patients was 2 years, with a median of 5.1 years (range 2-9 years). Recurrent disease was defined as tumor growth at the same site within 5 years of completion of initial therapy.



**Figure 1**

- A Squamous cell carcinoma of lower lip.*
- B Ink marks indicate margins for excision of lesion; the margins of the excised specimen were tumor-free by frozen section examination*
- C Result six months after treatment*

The data was analyzed using the SPSS program (SPSS Inc., Chicago, Ill., USA). Statistical significance was set at the .05 level.



**Figure 2**  
*Surgical margin containing SCC (arrow) (Hematoxylin-eosin stain).*

## Results

Nine patients (12.5%) had a surgical margin containing SCC on frozen section analysis, which was confirmed in eight patients on final pathological analysis resulting in a false-positive rate associated with frozen section analysis of 1.4%. Therefore, eight (11.1%) out of 72 tumors had been excised initially without tumor-free margins.

There were two local recurrences (2.8%) after 7 and 17 months, respectively. In one of these patients, frozen section analysis and final pathological examination showed microscopic disease in one of the resection margins; the additional resected margin was tumorfree. None of the remaining seven patients with initial margins positive for SCC had treatment failure at the primary site (mean follow-up 41 months, range 27-64 months). Of the lesions that had been excised completely at the first excision, one (1.4%) recurred. The two failures were controlled by surgical excision.

Since the number of recurrences was too small, statistical analysis to determine the relevance of studied variables with respect to recurrent disease was not applicable.

## Discussion

One reason for recurrence is incomplete excision of the lesion. Local recurrence has also shown to be associated with an increased risk of regional lymph node metastasis thereby influencing the prognosis adversely.<sup>4, 7, 9, 17, 18</sup> A safe margin of 10 mm of normal-appearing tissue beyond the recognized limits of the tumor is usually recommended.<sup>3, 4, 10, 12-14</sup> The adult lower lip is approximately 7 cm in width. Excision

of a 1.5 cm lesion with 1 cm safety margins results in a 3.5 cm defect, e.g. 50% loss of lip length. Although the lip stretches with use, in most patients with a defect of 50% or more of the entire lip width primary closure results in microstomia. To prevent microstomia a type of full-thickness flap reconstruction is required. Although the cosmetic results are generally good, reconstructive procedures quite often result in a smaller oral opening and loss of elasticity that may cause functional deficits such as insufficient access during dental treatment and inability to insert dentures.

It can be questioned whether a 10 mm margin is required for tumor eradication. Smaller margins may be too narrow and may risk a chance of incomplete excision of the tumor. To ensure complete removal of the tumor with small margins, thereby reducing the sacrifice of uninvolved tissue, immediate examination of the margins of the excised specimen during surgery using frozen section analysis can be done to confirm tumor-free margins. In a series of 1119 patients with stage I (83%) and stage II (17%) SCCLL treated with Mohs' micrographic surgery, the 5-year local recurrence rate was 1.5%.<sup>19</sup> In another study using Mohs' technique, the 5-year cure rate was 91% in 45 patients with mainly stage I SCCLL.<sup>20</sup> Treatment failure rates in the above mentioned studies and the present one using small surgical margins and frozen analysis sections compare at least favorable to those of others using resected margins of 5-10 mm without frozen section analysis; the latter studies reported 5 year local recurrence rates of between 3-17%.<sup>3, 4, 7, 9, 17, 18</sup> In a meta-analysis from the literature, the reported local recurrence rate with Mohs' technique was 2.3%, whereas those treated with non-Mohs' treatment modalities had a local failure rate of 10.5%.<sup>21</sup> A disadvantage of Mohs' surgery is its cost due to the total operative time and the use of a great deal of pathological resources<sup>11</sup>. Full-thickness excision of SCCLL allows assessment of only 2 surgical margins by frozen section analysis, thereby reducing time and costs.

The justification of smaller margins depends largely upon the accuracy of determining clinically the margins of the tumor. No local recurrence was observed after a follow-up period of more than 2 years in a series of 17 patients with mainly stage I SCCLL, who had been treated with a full-thickness wedge excision with 3-4 mm safety margins without a prior biopsy and frozen section analysis in only a few cases.<sup>16</sup>

Therefore, it can be questioned whether or not all lesions resected with 3-mm margins should be checked with frozen sections. It was found that 3-5 mm margins examined by frozen section analysis achieved an 81% clearance in 32 patients with stage I SCCLL.<sup>15</sup> In the present series, clinically determined margins on initial excision were tumor-free in about 90% of the patients, indicating that 10% of the



lesions would have been resected incompletely and require re-excision in a second procedure, with all of its associated morbidity and costs. Although the majority of lesions can be excised completely on the basis of clinical judgement, carefully oriented frozen section control of margins seems to be a valuable and indispensable tool and, in our opinion, should be used with efficacious resection of stage I and II SCCLL with 3 mm margins. If the margins are not checked with frozen sections, a 6 mm margin seems to be justified.

## References

1. Parkin DM, Whelan SL, Ferlay J, Raymond L, Young J. Cancer Incidence in Five Continents, Vol. VII. IARC Scientific Publication No. 143. Lyon: International Agency for Research on Cancer, 1997.
2. Bailey BJ. Management of carcinoma of the lip. *Laryngoscope* 1977; 87: 250-60.
3. Blomgren I, Blomqvist G, Lauritzen C, Lilja J, Peterson LE, Holmström H. The step technique for the reconstruction of lower lip defects after cancer resection. A follow-up study of 165 cases. *Scand J Plast Reconstr Surg* 1988; 22: 103-11.
4. Cruse CW, Radocha RF. Squamous cell carcinoma of the lip. *Plast Reconstr Surg* 1987; 80: 787-91.
5. Holt GR. Surgical therapy of oral cavity tumors: lip tumors. In: Thawley SE, Panje WR, ed.: *Comprehensive Management of Head and Neck Tumors*. Philadelphia: WB Saunders, 1987; 538.
6. Luce EA. Carcinoma of the lower lip. *Surg Clin North Am* 1986; 66: 3-11.
7. Zitsch RP, Park CW, Renner GJ, Rea JL. Outcome analysis for lip carcinoma. *Otolaryngol Head Neck Surg* 1995; 113: 589-96.
8. De Visscher JGAM, Botke G, Schakenraad ACM, Van der Waal I. A comparison of results after radiotherapy and surgery for stage I squamous cell carcinoma of the lower lip. *Head Neck* 1999; 21: 526-30.
9. De Visscher JGAM, Van den Elsaker K, Grond AJK, Van der Wal JE, Van der Waal I. Surgical treatment of squamous cell carcinoma of the lower lip: evaluation of long-term results and prognostic factors. A retrospective analysis of 184 patients. *J Oral Maxillofac Surg* 1998; 56: 814-20.
10. Califano L, Zupi A, Massari PS, Giardino C. Lymph-node metastasis in squamous cell carcinoma of the lip. A retrospective analysis of 105 cases. *Int J Oral Maxillofac Surg* 1994; 23: 351-5.
11. Campbell JP. Surgical management of lip carcinoma. *J Oral Maxillofac Surg* 1998; 56: 955-61.
12. Hoşal IN, Önerci M, Kaya S, Turan E. Squamous cell carcinoma of the lower lip. *Am J Otolaryngol* 1992; 13: 363-5.
13. Knabel MR, Koranda FC, Olejko TD. Surgical management of primary carcinomas of the lower lip. *J Dermatol Surg Oncol* 1982; 8: 979-83.

14. Pitkänen, J, Lahti A, Sundell B. Carcinoma of the lip. A retrospective study of 70 patients. *Plast Reconstr Surg* 1985; 19: 289-94.
15. Breuninger H. Aspekte zur operativen Therapie des Unterlippenkarzinoms. *Z Hautkr* 1987; 62: 937-46.
16. Hjortdal O, Naess A, Berner A. Squamous cell carcinomas of the lower lip. *J Craniomaxillofac Surg* 1995; 23: 34-7.
17. Baker SR, Krause CJ. Carcinoma of the lip. *Laryngoscope* 1980; 90: 19-27.
18. Grover R, Douglas RG, Shaw JHF. Carcinoma of the lip in Auckland, New Zealand, 1969-1987. *Head Neck* 1989; 11: 264-8.
19. Mohs FE, Snow SN. Microscopically controlled surgical treatment for squamous cell carcinoma of the lower lip. *Surg Gynecol Obstet* 1985; 160: 37-41.
20. Holmkvist KA, Roenigk RK. Squamous cell carcinoma of the lip treated with Mohs micrographic surgery: outcome at 5 years. *J Am Acad Dermatol* 1998; 38: 960-6.
21. Rowe DE, Carroll RJ, Day CL. Prognostic factors for local recurrence, metastasis, and survival rates in squamous cell carcinoma of the skin, ear, and lip. *J Am Acad Dermatol* 1992; 26: 976-90.

## Chapter 7

# Supraomohyoid Neck Dissection in the Management of Cervical Lymph Node Metastases of Squamous Cell Carcinoma of the Lower Lip

P.J.J. Gooris<sup>1</sup>, A. Vermeij<sup>2</sup>, J.G.A.M. de Visscher<sup>3</sup>  
F.R. Burlage<sup>4</sup>, J.L.N. Roodenburg<sup>5</sup>

---

<sup>1</sup>Department of Oral and Maxillofacial Surgery  
Amphia Hospital Breda, The Netherlands

<sup>2</sup>Department of Surgery/ Head and Neck Surgery  
Groningen University Hospital, The Netherlands

<sup>3</sup>Department of Oral and Maxillofacial Surgery  
Leeuwarden Medical Center, The Netherlands

<sup>4</sup>Department of Radiotherapy  
University Hospital Groningen, The Netherlands

<sup>5</sup>Department of Oral and Maxillofacial Surgery/ Oncology  
Groningen University Hospital, The Netherlands

Head and Neck 2002; 24: 678-83



## Abstract

### Background

Supraomohyoid neck dissection (SOHND) is generally considered an adequate staging procedure in selected patients with squamous cell carcinoma (SCC) of the lip and oral cavity, with clinically negative nodes in the neck that are at increased risk for occult metastatic disease.

The potential role of SOHND as a therapeutic surgical procedure for cervical metastasis limited to level I is controversial.

### Methods

A series of 44 patients with clinical cervical lymph node metastases at level I from SCC of the lower lip is reported to evaluate the results of a treatment protocol, consisting of therapeutic SOHND on indication followed by radiotherapy.

### Results

Regional recurrences were observed in four (9%) patients. All recurrences developed within the SOHND dissected area only.

### Conclusions

A therapeutic SOHND, on indication followed by radiotherapy, can be an oncologically sound and effective procedure in the management of regional lymph node metastases at level I from SCC of the lower lip.

## Introduction

With an incidence of 1 to 2 per 100,000 individuals, cancer of the lip is a relatively rare tumor in the Netherlands.<sup>1, 2</sup> Lip cancers are almost exclusively squamous cell carcinomas (SCC) of which most are located on the vermilion border of the lower lip.<sup>2-4</sup> The prognosis for patients with cancer of the lower lip is generally favorable, which is attributed to the early detection (small tumor size) and the relatively infrequent occurrence of regional metastasis.<sup>3, 5</sup> When cervical lymph node metastasis develops, the 5-year determinant survival rate decreases from 70-99% to 40-80%.<sup>2, 3, 5</sup>

There is a predictable pattern of lymphatic spread to the cervical lymph nodes from SCC's of the upper aerodigestive tract, which is related to the specific anatomic site of the primary tumor.<sup>6-8</sup> Regional metastases associated with lower lip cancer are generally located in the submental and submandibular areas (level I).<sup>5, 6</sup> If metastases are limited to level I, then the risk of level IV or V containing lymph node metastases is extremely low.<sup>6-11</sup> Therapeutic lymphadenectomy of level I, II and III using a selective neck dissection i.e. SOHND may, therefore, be considered adequate treatment in case of metastatic nodal disease confined to level I. The well established indication for SOHND is the elective lymphadenectomy in patients with a primary SCC of the lip and oral cavity with clinically negative nodal disease and a more than 20% risk for occult cervical metastasis.<sup>9, 12-15</sup> The potential therapeutic role of SOHND for nodal metastasis in level I, however, remains controversial.<sup>8, 13, 15-18</sup>

The objective of the present study was to analyze the results of a protocol used in a series of 44 patients with lymph node metastases from SCC of the lower lip, clinically confined to level I, all treated with therapeutic SOHND on indication followed by radiotherapy.

To investigate the value of therapeutic SOHND, the incidence of regional recurrence within and beyond the dissected area was analyzed.

## Patients and Methods

Between January 1, 1975, and January 1, 1998, 44 patients underwent a therapeutic SOHND because of clinically suspicious and cytologically or histologically verified cervical lymph node metastasis of level I associated with SCC of the lower lip. Of

these patients, 34 were treated at the Groningen University Hospital and 10 at the Leeuwarden Medical Center, the Netherlands.

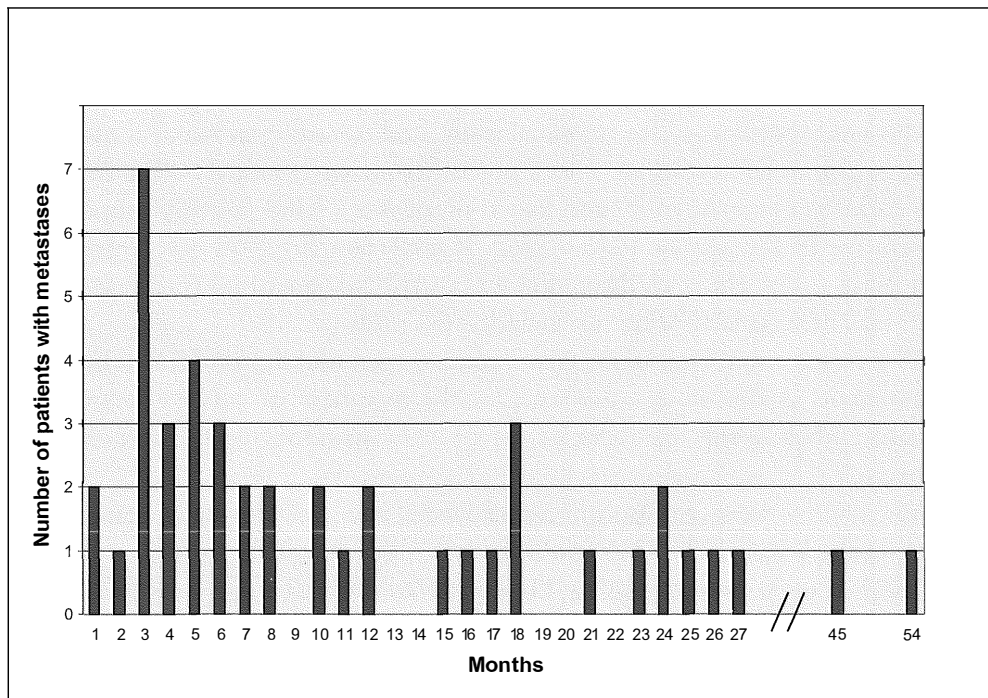
Patients with a local recurrence of the primary tumor of the lip were excluded from this study because of the potential associated reseeding of cervical metastatic disease, which then results in a less precise recurrence rate. During SOHND, jugulo-digastric (=subdigastric) and jugulo-omohyoid (=mid-jugular) lymph nodes were sent for frozen section examination. If metastatic invasion was diagnosed in one of these nodes, the neck dissection was converted to a (modified) radical neck dissection. These patients were not included the study.

All patients were Caucasian; there were 40 men and 4 women. All but three of the patients in this study were seen for the treatment of cervical lymph node metastases, whereas the treatment of the primary lip tumor had been performed elsewhere.

All patients were retrospectively clinically and pathologically restaged according to the UICC 1997 TNM classification.<sup>19</sup> The distribution of the clinical T-stage resulted in 31 patients with a T1, 9 patients with a T2 and 4 patients with a T3 lesion. The histopathological grading of the preceding lip tumor showed a well-differentiated lesion in 11 cases, a moderately differentiated lesion in 28 cases and a poorly differentiated lesion in 5 cases.

The mean age at the time of diagnosis of nodal disease was 65.4 years (median, 68.1 years; range 38-90 years). Metastases developing six or more months after completion of the treatment of the primary lip tumor were termed metachronous (24 patients); those that developed earlier were termed synchronous (20 patients). Most of the metastases (89%) occurred within 24 months after treatment of the lip tumor. In two patients the lymph node metastases developed 45 and 54 months, respectively, after the treatment of the primary lip tumor. The mean period of time between the diagnosis of the primary lip tumor and development of metastasis was 14 months (median 9 months; range 1-54 months) (Figure 1).

Level I lymph node metastases were mostly ipsilateral to the primary tumor. However, in four patients a bilateral submandibular and in two patients a contralateral submandibular nodal involvement was observed (six patients with a pN2c-neck). Separate staging of the sides of the neck in the four patients with the bilateral submandibular metastases resulted in six patients with a pN1-neck and two patients with a pN2a-neck, both with one patient who was also diagnosed with extracapsular tumor spread.



**Figure 1** *Distribution of patients with level I cervical metastasis, developing after the treatment of primary squamous cell carcinoma of the lower lip (n=44 patients)*

According to protocol, patients with one metastatic node in the first echelon,  $\leq 3$  cm and without extracapsular spread were treated with SOHND only. All other patients, diagnosed with a pN1-neck with extracapsular spread and patients with multiple involved nodes in level I (pN2-neck) with or without extracapsular spread, were treated with SOHND and adjuvant radiotherapy (minimum dose 50 Gy/5 weeks) to both sides of the neck, preferably started within six weeks after the surgical procedure, i.e. radiotherapy on indication.

In three patients, the SOHND was performed simultaneously with the surgical removal of the lip tumor; in all other patients the SOHND was carried out as the sole procedure. A bilateral SOHND was performed in the six patients who were diagnosed with a pN2c-neck.

Histopathologic examination of the metastases included size of the lymph node, number of nodes containing metastatic disease and the presence or absence of extracapsular spread. With regard to the nodal staging, a differentiation was made between the clinical (cN) and the pathologic (pN) staging (Table 1). Of the



**Table 1** *Clinical (c) and pathological (p) staging of the neck in 44 patients*

cN	pN
cN1 = 24	pN1 = 24
cN2a = 9	pN2a = 8
	pN2b = 1
cN2b = 5	pN2b = 5
cN2c = 6	pN2c = 6

Values are number of patients

44 patients, 24 patients had a pN1-neck and 20 patients had a pN2-neck. Extracapsular tumor spread was observed in 28 patients (64%).

Postoperative radiotherapy was applied in 32 patients. In 4 of 32 patients the presence of more than one metastatic node (pN2-neck) and in 12 of 32 patients extracapsular spread was the indication for the radiotherapy treatment; in 16 of 32 patients a combination of more than one metastatic node and extracapsular spread was the dual indication for combined treatment.

Radiotherapy was started within a mean period of 5 weeks (median, 4 weeks; range 3-8 weeks) after the SOHND and consisted of megavoltage therapy to both sides of the neck and the primary tumor site if the lymph nodes became apparent within 2 years, with the exception of one patient, who was irradiated to the surgically treated side only. The mean dose was 61 Gy (median, 60 Gy; range 50-70 Gy) with a daily dose of 2 Gy, 5 fractions per week. The overall radiation treatment time ranged from 36 to 50 days.

The mean follow-up was 56 months (median, 55 months; range 2-199 months). In six patients, intercurrent death was the cause of a follow-up period of less than two years.

The incidence of recurrent metastatic disease was analyzed; a distinction was made between regional recurrent disease, originating within the dissected area (levels I, II and III) and recurrences that appeared outside this area.

### Statistical analysis

Survival curves of the patients were calculated by the Kaplan-Meier method. The overall actuarial survival was defined as the interval between the date of the SOHND and the date of the last consultation or date of death, from any cause. The disease-free survival was calculated from the date of treatment of the metasta-

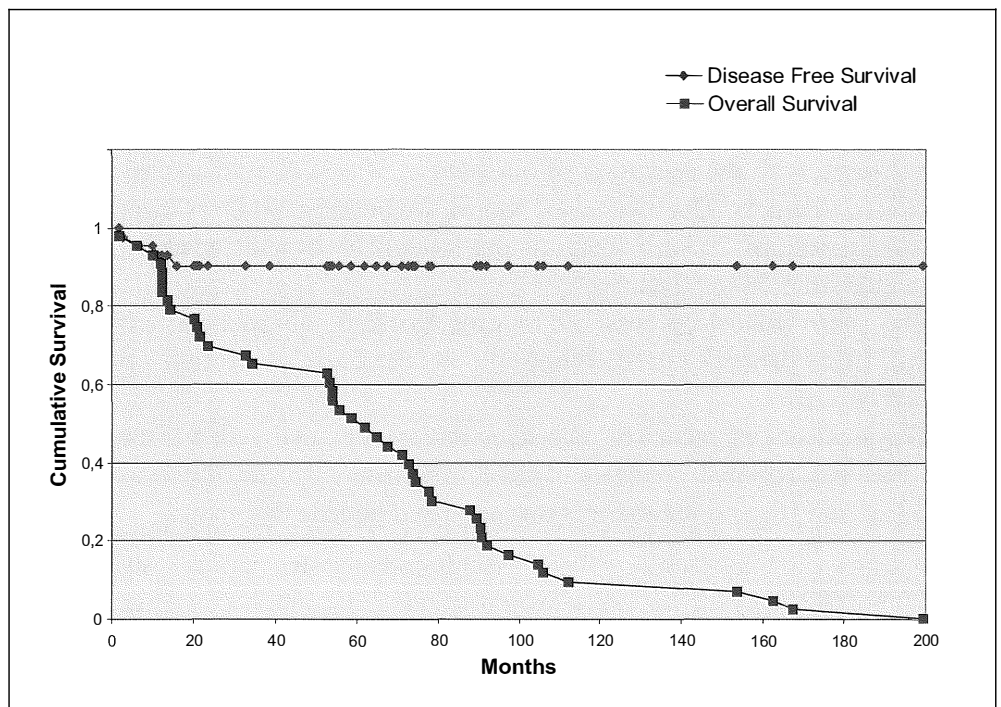
sis until the diagnosis of regional recurrence. In univariate analysis, Fisher's exact test was used to establish the relationship between two variables. Statistical significance was set at the .05 level.

To determine the potential association between the development of regional recurrent metastatic disease and the combined presence of a pN2 status and extracapsular tumor spread, statistical analysis was done using Pearson's Chi-square test for univariate analysis ( $p < 0.01$ ); Fisher's exact test was used because of the small numbers. Statistical significance was set at the .05 level. The odds ratio was 23.7.

## Results

The overall survival and disease-free survival curves are shown in Figure 2.

Regional recurrence was observed in four patients. The mean period between the treatment of the initial metastases and the diagnosis of the recurrence was 9



**Figure 2** The Kaplan-Meier overall and disease free survival of patients treated for level I cervical metastases associated with squamous cell carcinoma of the lower lip.

**Table 2** *Relation between T-classification (T-class.), timing of cervical metastases (S/M)\*, neck (pN) status, presence of extracapsular spread (ECS), the total tumor dose (Gy) of adjuvant radiation therapy (XRT), location regional recurrence (RR) and months (MO) between the SOHND and the diagnosis of the recurrence in 4 patients.*

T-class.	S/M	pN status	ECS	XRT	RR	MO
T1	M	pN2b	+	70 Gy	level I, ipsilateral	16
T1	M	pN2b	+	64 Gy	level I, ipsilateral	6
T3	S	pN2b	+	60 Gy	level II, ipsilateral	3
T3	M	pN2b	+	60 Gy	level II, ipsilateral	11

\*S = synchronous, M = metachronous

+ = positive

months (range 3-16 months). All four patients diagnosed with a recurrence underwent postoperative radiotherapy. Univariate analysis revealed that recurrence was associated with the combined presence of pN2 status and extracapsular tumor spread.

In the two patients with recurrent metastases ipsilateral in level I, the metastases developed in the submandibular node. In the two patients with a metastatic recurrence ipsilateral in level II, these metastases developed in the jugulo-digastric respectively jugulo-omohyoid node. Therefore, recurrent disease developed within the dissected area, ie levels I-III. The characteristics of these four patients are given in Table 2.

In the one patient who, after SOHND, had radiotherapy to the ipsilateral side only, a contralateral cervical metastatic node developed in level I 38 months after completion of the treatment. This contralateral metastatic disease was not recorded as a recurrence, because the nodal disease developed in the untreated side.

## Discussion

In the absence of cervical metastases, lower lip cancer is a highly curable disease. The presence and extension of regional lymph node involvement is considered the most important prognostic determinant for survival.<sup>2, 3, 5, 13, 20-23</sup> Large primary tumor size, local recurrence, degree of histologic differentiation, tumor thickness, an infiltrative invasion pattern and perineural invasion are factors considered to be associated with a higher rate of regional lymph node metastases.<sup>2, 3, 5, 10, 17, 21, 22, 24, 25</sup>

Subsequently, the type of therapeutic approach to control regional lymphatic spread in the neck plays an essential role in the ultimate prognosis; the efficacy of treatment is reflected by the regional control rate.

A (modified) radical neck dissection is a commonly used surgical procedure for the treatment of the N+ neck. However, because there is a development toward minimizing tissue loss from an extirpative procedure with preservation of function, this has resulted in an increasing interest in the use of various modifications of the radical neck dissection. It has been reported that, when using a more selective surgical procedure in selected patients with a N+ neck, regional control can be achieved comparable to that of (modified) radical neck dissection.<sup>8, 13, 15, 18, 23, 24, 26-29</sup> If multiple nodal metastases are present or when extracapsular spread is diagnosed, neck dissection alone is associated with a relatively high incidence of recurrence. Adjuvant radiotherapy can then more effectively reduce the incidence of recurrences in the neck when compared with surgery alone, resulting in better control of metastatic disease.<sup>11, 30-32</sup>

Compared with a radical neck (i.e. a modified radical neck) procedure, patients undergoing a SOHND will benefit from less long-term functional disability of the shoulder and minimal cosmetic deformity with better preservation of the volume of the neck after surgical treatment. The preservation of neck volume is of particular relevance with regard to the planning and the dose distribution of the postoperative radiotherapy.<sup>9-11, 18, 28</sup>

A disadvantage of SOHND may be that technically it is a relatively demanding surgical procedure.

In this study, in 4 of 44 (9%) patients, regional recurrent metastatic disease was observed. In all four patients the recurrences were located within the surgically treated area. The most consistent finding with respect to the development of recurrent metastases was the combined presence of a pN2 status and extracapsular spread. Of the group of 40 patients without recurrent disease, 11 of 40 (28%) patients had both a pN2 status and extracapsular spread. Univariate analysis showed that the development of regional recurrence of metastases was statistically significantly associated with the combined presence of a pN2 status and extracapsular tumor spread ( $p < .01$ ).

Further differentiation of the pN2 status showed that in the group of patients without recurrent disease, only 2 of 40 patients had a pN2b-neck diagnosed, one with and one without extracapsular spread, which is in contrast to the group of patients with recurrent metastases, all of whom were diagnosed with a pN2b status and extracapsular spread.

Although these data concern a small series, the data suggest that more extensive cervical metastatic tumor load and the presence of extracapsular spread seem to be correlated with a higher rate of recurrent metastatic disease, findings that are supported by the literature.<sup>3, 5, 14, 24, 28, 29, 31-35</sup>

Bilateral lymph node involvement was present in four patients; contralateral involvement was seen in two patients. However, none of these six patients with pN2c-neck had recurrent nodal disease develop.

The overall recurrence rate of 9% compares favorably with data presented by others who reported the results of therapeutic selective neck dissections in combination with radiotherapy; reports demonstrated regional recurrence rates of respectively 15%, 12.5% and 13% in patients with lip and oral SCC's undergoing selective neck dissection and adjuvant radiotherapy for the treatment of multiple cervical lymph nodes and/or extracapsular spread.<sup>8, 9, 13</sup>

The results of this study indicate a potential therapeutic role for SOHND in patients with regional metastatic lymph node involvement at level I from SCC of the lower lip. The extent of the nodal status (>pN1-neck) and the information obtained from the pathology report (presence of extracapsular tumor spread) dictate the need for adjuvant radiotherapy. Intraoperative findings (nodal involvement of > level I) will determine whether it is necessary to proceed to a comprehensive neck dissection.

## Conclusions

A group of 44 patients with lymph node metastases associated with SCC of the lower lip, confined to level I, underwent SOHND, on indication followed by radiotherapy. Recurrent disease (9%) was observed within the SOHND dissected area only.

The results of this study indicate that SOHND, on indication followed by radiotherapy, can be an oncologically sound and effective procedure for the treatment of regional metastatic disease at level 1 from SCC of the lower lip.

## References

1. Visser O, Coebergh JWW, Schouten LJ, van Dijck JAAM, editors. Incidence of Cancer in the Netherlands 1996; Utrecht: Vereniging van Integrale Kanker centra, 2000.

2. de Visscher JGAM, van den Elsakker K, Grond AJK, van der Wal JE, van der Waal I. Surgical treatment of squamous cell carcinoma of the lower lip: evaluation of long-term results and prognostic factors. A retrospective analysis of 184 patients. *J Oral Maxillofac Surg* 1998; 56: 814-20.
3. Renner GJ, Zitsch RP. Cancer of the lip. In: Myers EN, Suen JY. *Cancer of the Head and Neck*. Philadelphia: WB Saunders Company; 1996. p 294-320.
4. Muir C, Weiland L. Upper aerodigestive tract cancers. *Cancer* 1995; 75: 147-53.
5. Zitsch RP, Lee BW, Smith RB. Cervical lymph node metastases and squamous cell carcinoma of the lip. *Head Neck* 1999; 21: 447-53.
6. Lindberg R. Distribution of cervical lymph node metastases from squamous cell carcinoma of the upper respiratory and digestive tracts. *Cancer* 1972; 29: 1446-9.
7. Shah JP, Candela FC, Poddar AK. The patterns of cervical lymph node metastases from squamous cell carcinoma of the oral cavity. *Cancer* 1990; 66: 109-13.
8. Pellitteri PK, Robbins KT, Neuman T. Expanded application of selective neck dissection with regard to nodal status. *Head Neck* 1997; 19: 260-5.
9. Byers RM. Modified Neck Dissection. *Am J Surg* 1985; 150: 414-21.
10. Carvalho AL, Kowalski LP, Borges JAL, Aguiar S, Magrin J. Ipsilateral neck cancer recurrences after elective supraomohyoid neck dissection. *Arch Otolaryngol Head Neck Surg* 2000; 126: 410-2.
11. Skolnik EM, Yee KF, Friedman M, Golden TA. The posterior triangle in radical neck surgery. *Arch Otolaryngol* 1976; 102: 1-4.
12. Robbins KT, Medina JE, Wolfe GT, Levine PA, Sessions RB, Pruet CW. Standardizing Neck Dissection Terminology. Official report of the Academy's Committee for Head and Neck Surgery and Oncology. *Arch Otolaryngol Head Neck Surg* 1991; 117: 601-5.
13. Medina JE, Byers RM. Supraomohyoid neck dissection: rationale, indications, and surgical technique. *Head Neck* 1989; 11: 111-22.
14. Kowalski LP, Margrin J, Waksman G, Santo FE, Lopes MEF et al. Supraomohyoid neck dissection in the treatment of head and neck tumors. *Arch Otolaryngol Head Neck Surg* 1993; 119: 958-63.
15. Kolli VR, Datta RV, Orner JB, Hicks WL, Loree TR. The role of supraomohyoid neck dissection in patients with positive nodes. *Arch Otolaryngol Head Neck Surg* 2000; 126: 413-6.
16. Spiro RH, Morgan GJ, Strong EW, Shah JP. Supraomohyoid neck dissection. *Am J Surg* 1996; 172: 650-3.
17. Kerrebijn JDF, Freeman JL, Irish JC et al. Supraomohyoid neck dissection. Is it diagnostic or therapeutic? *Head Neck Surg* 1999; 21: 39-42.
18. Traynor SJ, Cohen JI, Gray J, Andersen PE, Everts EC. Selective neck dissection and the management of the node-positive neck. *Am J Surg* 1996; 172: 654-7.
19. Sobin LH, Wittekind CH. Editors. *UICC TNM Classification of malignant tumors*. 5th edition. New York: Wiley-Liss, 1997.
20. Sack JG, Ford CN. Metastatic squamous cell carcinoma of the lip. *Arch Otolaryngol* 1978; 104: 282-5.
21. McGregor GI, Davis NL, Hay JH. Impact of cervical lymph node metastases from squamous cell cancer of the lip. *Am J Surg* 1992; 163: 469-71.

22. Rowe DE, Carroll RJ, Day CL. Prognostic factors for local recurrence, metastasis, and survival rates in squamous cell carcinoma of the skin, ear, and lip. Implications for treatment modality selection. *Clinical Review. J Am Acad Dermatol* 1992; 26: 976-90.
23. Califano L, Zupi A, Massari PS, Giardino C. Lymph-node metastases in squamous cell carcinoma of the lip. *Int J Oral Maxillofac Surg* 1994; 23: 351-5.
24. Byers RM, Wolf PF, Ballantyne AJ. Rationale for elective modified neck dissection. *Head Neck Surg* 1988; 10: 160-7.
25. Brekel MWM van den, Waal I van der, Meijer CJLM, Freeman JL, Castelijns JA, Snow GB. The incidence of micrometastases in neck dissection specimens obtained from elective neck dissections. *Laryngoscope* 1996; 106: 987-91.
26. Hanna E, Eyre M, Vural E, Breau R, Suen JY. Selective neck dissection for N1 or greater neck disease: is it therapeutic? 5th Int Conf on Head and Neck Cancer. San Francisco, U.S.A. 2000 ; July 29–August 2; Final program and Abstract Book: p 161.
27. Andersen PE, Warren F, Burningham A, Wax M, Cohen J. Results of selective neck dissection in the treatment of the N+ neck. Abstract 5th Int Conf on Head and Neck Cancer. San Francisco, U.S.A. 2000; July 29 – August 2; Final program and Abstract Book: p 161.
28. Shah JP, Andersen PE. Evolving role of modifications in neck dissections for oral squamous carcinoma. *Br J Oral Maxillofac Surg* 1995; 33: 3-8.
29. Pinsolle J, Pinsolle V, Majoufre C, Duroux S, Demeaux H, Siberchicot F. Prognostic value of histologic findings in neck dissections for squamous cell carcinoma. *Arch Otolaryngol Head Neck Surg* 1997; 123: 145-8.
30. Strong EW. Preoperative radiation and radical neck dissection. *Surg Clin N Am* 1969; 49: 271-6.
31. Leemans CR, Tiwari R, Waal van der I, Karim ABMF, Nauta JJP, Snow GB. The efficacy of comprehensive neck dissection with or without postoperative radiotherapy in nodal metastases of squamous cell carcinoma of the upper respiratory and digestive tracts. *Laryngoscope* 1990; 100: 1194-8.
32. Vikram B, Strong E, Shah J, Spiro R. Failure in the neck following multimodality treatment for advanced head and neck cancer. *Head Neck Surg* 1984; 6: 724-9.
33. Shah JP, Cendon RA, Farr HW, Strong EW. Carcinoma of the oral cavity – factors affecting treatment failure at the primary site and the neck. *Am J Surg* 1976; 132: 504-7.
34. Cachin Y, Sancho-Garnier H, Micheau C, Marandas P. Nodal metastases from carcinomas of the oropharynx. *Otolaryngol Clin North Am* 1979; 12: 145-54.
35. Johnson JT, Barnes L, Meuers EN, Schramm VL, Borochovit D, Sigler BA. The extracapsular spread of tumors in cervical node metastasis. *Arch Otolaryngol* 1981; 107: 725-9.

...

...

...



---

# **Chapter 8**

## **General Discussion**



Squamous cell carcinoma of the lower lip (SCCLL), a relatively infrequent malignancy, is generally a readily curable disease since most cancers are diagnosed and treated at an early stage, due to the accessibility of the tumor.<sup>1-4</sup>

For patients presenting with a malignancy, the management of this disease plays an important role in the final outcome. Essential is the adherence to oncologically sound treatment principles.<sup>5, 6</sup> Although care for patients with a malignancy may vary among different institutions and among different disciplines involved, management should be based on multidisciplinary guidelines.<sup>6</sup>

The increasing knowledge of the biologic behavior of cancer and the ongoing refinement and variations of treatment techniques have made it possible to reduce the extensiveness of therapeutic procedures, without jeopardizing the oncological results.

The major objective of this thesis was to analyze aspects related to the management of patients with a SCCLL. Especially the value of less mutilating intervention is evaluated.

There is an increasing demand for an overall consensus and evidence-based treatment of malignant disease. A guideline should, apart from structuring diagnosis and treatment, serve as a monitor of patient management. Subsequently, quality control will be facilitated (Chapter 2).<sup>7</sup>

Since the mid-1970s, it has been common practice in the Netherlands to develop guidelines in oncology for diagnosis, treatment and follow-up with the aim to provide optimal care for patients with cancer. The absence of a uniform policy in the management of SCCLL may lead to a compromised oncological result (Chapter 3).<sup>8</sup> However, even despite the availability of guidelines, it has been shown that the degree of compliance may vary considerably.<sup>6</sup> Factors that may influence the level of compliance are the accessibility and the regular updating (including a review) to control the implementation of the guideline (Chapter 2). Also, the possibility to participate in the drafting of the guidelines can improve their acceptance; modern information and communication technology can be helpful and make guidelines more easily accessible.

Although the majority of SCCLL are T1 lip tumors (in the Netherlands more than 76%) and the overall incidence of SCCLL compared to the overall incidence of all registered malignancies is low (0.4% in males, 0.1% in females), multiple disciplines are involved in its management (Chapter 3).<sup>6, 8, 9</sup> This diversity in specialists involved and the lack of sufficient interdisciplinary communication may explain the relatively low level of compliance to available guidelines (Chapter 2).<sup>6</sup>

A multidisciplinary approach in a head and neck cancer center will provide the necessary communication during the work-up, management and follow-up of the patient presenting with a SCCLL, including the possibility to control the level of compliance to the guideline. Further studies will be necessary to verify to what extent this centralized management will result in a decrease in morbidity and mortality.

Early diagnosis and treatment of premalignant disease will contribute to a decrease in morbidity (minimal dysfunction, acceptable esthetic results) and decrease in mortality, resulting in a more successful outcome. Precancerous lesions such as leukoplakia, erythroplakia, actinic cheilitis and cheilitis glandularis which have the potential for malignant transformation need adequate management. Clinically, the risk of a malignant transformation is difficult to predict.<sup>10-14</sup> The indication for treatment of these lesions mainly depends on the result of histopathologic examination. Surgery, CO<sub>2</sub> laser evaporation (Chapter 4), cryosurgery, or photodynamic therapy can be used as a prophylactic treatment when dysplasia is confirmed by histopathologic examination, or when risk factors such as an erosive aspect of the lesion or earlier treated primary squamous cell carcinomas of the aerodigestive tract have been present.<sup>15, 16</sup> Although CO<sub>2</sub> laser evaporation, in contrast to a surgical excision does not provide the possibility to examine the whole specimen histologically, we have shown that the use of this laser is a reliable treatment method. Careful follow-up, however, remains necessary (Chapter 4).

Management of SCCLL's traditionally consists of either surgery, radiotherapy or a combination of both.<sup>1, 3, 17-21</sup> Apart from the primary goal to achieve an optimal oncological result, a tendency emerged to minimize tissue impairment and to improve the functional and esthetic result. Less extensive treatment, however, should not result in the violation of oncological principles.

Because of the complementary properties, the planned combination of surgery and radiotherapy have been introduced in the management of head and neck cancer since the late 1960s and 1970s.<sup>22-24</sup> Already in 1941 and in 1951 Hayes Martin described the combination of surgery and radiotherapy for the treatment of cervical metastatic cancer that had invaded surrounding structures.<sup>25, 26</sup> The role of preoperatively applied radiotherapy in metastatic squamous cell carcinoma in the neck was reported by Strong in 1969.<sup>27</sup> More recently, the advantages of administering the radiation therapy postoperatively became more fully understood: surgery of an irradiated area will result in a higher incidence of complicated wound healing

and, depending on intraoperative findings and histopathological examination, postoperative radiotherapy can be applied more selectively.<sup>23, 28</sup>

The concept of “the best of both” (Richard H. Jesse) evolved: less than maximum surgery in combination with less than maximum radiation therapy. This resulted in the judicious use of moderate doses of irradiation and a modified surgical procedure while maintaining adequate loco-regional tumor control. As a result, there is less mutilation and there are less radiation-related side effects.

The mutilation secondary to the surgical treatment of the lip depends on a large extent on the width of the resection and the experience of the surgeon involved. Due to the local biological behavior of this tumor and the reliability of frozen section examination of the margins, we have shown (Chapters 5 and 6) that it seems justified to reduce the width to a 3 mm margin.<sup>29</sup> The less extensive surgical procedure will result in a better functional and esthetic outcome while the necessary frozen section examination will reduce the indication for a later re-excision or postoperative radiotherapy. This more limited excision did not result in an increase of local recurrent disease, when compared with studies using a more, traditionally wider excision.

The tissue-saving concept is also applied for the treatment of the neck in SCCLL. The use of a limited, selective neck dissection on strict indication further contributes to maximize the preservation of function and esthetics. A therapeutic supraomohyoid neck dissection on indication followed by adjuvant radiotherapy in the management of cervical metastatic disease at level I, has been shown to be a justifiable treatment method, while avoiding the morbidity related to a (modified) radical neck dissection (chapter 7).<sup>30</sup> In the latter study, all regional recurrences developed within the treated area; more extensive surgical treatment would not have prevented the development of these cervical recurrent metastases. It is therefore concluded that, in selected cases of SCCLL, a limited regional procedure can be considered an acceptable treatment method.

## References

1. De Visscher JGAM, van den Elsaker K, Grond AJK, van der Wal JE, van der Waal I. Surgical treatment of squamous cell carcinoma of the lower lip: evaluation of long-term results and prognostic factors. A retrospective analysis of 184 patients. *J Oral Maxillofac Surg* 1998; 56: 814-20.
2. Zitsch RP, Lee BW, Smith RB. Cervical lymph node metastases and squamous cell carcinoma of the lip. *Head Neck* 1999; 21: 447-53.

3. Renner GJ, Zitsch RP. Cancer of the lip. In: Myers EN, Suen JY. *Cancer of the Head and Neck*. Philadelphia: W.B. Saunders; 1996: 294-320.
4. Zitsch RP, Park CW, Renner GJ, Rea JL. Outcome analysis for lip carcinoma. *Clinical epidemiology/outcomes research. Otolaryngol Head Neck Surg* 1995; 113: 589-96.
5. Grimshaw JM, Russell IT. Effect of clinical guidelines on medical practice: a systematic review of rigorous evaluations. *Lancet* 1993; 342: 1317-22.
6. Gooris PJJ, Schaapveld M, Vermey A, Otter R, Rispens A, Roodenburg JLN. Regional guideline for diagnosis and treatment of squamous cell carcinoma of the lip: what is the level of compliance? *Int J Quality Health Care* 2001; 13: 143-50.
7. Grimshaw JM, Russell IT. Effect of clinical guidelines on medical practice: a systematic review of rigorous evaluations. *Lancet* 1993; 342: 1317-22.
8. Gooris PJJ, Maat B, Vermey A, Roukema JA, Roodenburg JLN. Radiotherapy for cancer of the lip the need for a multidisciplinary management protocol: a long-term evaluation of 85 treated cases. *Oral Surg Oral Med Oral Pathol* 1998; 86: 325-30.
9. *Electronic Database; Data derived from the period 1989-1998*. Utrecht: Association of Comprehensive Cancer Centres the Netherlands, 2001.
10. Schepman KP, van der Meij EH, Smelee LE, van der Waal I. Malignant transformation of oral leukoplakia: a follow-up study of a hospital based population of 166 patients with oral leukoplakia from the Netherlands. *Oral Oncol* 1998; 34: 270-5.
11. Brufau C, Canteras M, Armijo M. Our experience in the surgical treatment of cancer and precancerous lesions of the lower lip. *J Dermatol Surg Oncol* 1985; 11: 908-12.
12. Picascia DD, Robinson JK. Actinic Cheilitis: a review of the etiology, differential diagnosis, and treatment. *J Am Acad Dermatol* 1987; 17: 255-64.
13. Nicolau SG, Băluș L. Chronic actinic cheilitis and cancer of the lower lip. *Br J Dermatol* 1964; 76: 278-89.
14. Michalowski R. Cheilitis glandularis, heterotopic salivary glands and squamous cell carcinoma of the lip. *Br J Dermatol* 1962; 74: 445-9.
15. Kardos TB, Ferguson MM. Comparison of cryosurgery and the carbon dioxide laser in mucosal healing. *Oral Surg Oral Med Oral Pathol* 1991; 71: 670-4.
16. Gooris PJJ, Roodenburg JLN, Vermey A, Nauta JM. Carbon dioxide laser evaporation of leukoplakia of the lower lip: a retrospective evaluation. *Oral Oncology* 1999; 35: 490-5.
17. De Visscher JGAM, Botke G, Schakenraad ACM, van der Waal I. A comparison of results after radiotherapy and surgery for stage I squamous cell carcinoma of the lower lip. *Head Neck* 1999; 21: 526-30.
18. Campbell JP. Surgical management of lip carcinoma. *J Oral Maxillofac Surg* 1998; 56: 955-61.
19. Veness M. Lip cancer: Important management issues. *Austr J Dermatol* 2001; 42: 30-2.
20. Stranc MF, Fogel M, Dische S. Comparison of lip function: surgery versus radiotherapy. *Br J Plastic Surg* 1987; 40: 598-604.
21. Ashley FL, McConnel DV, Machida R, Sterling HE, Galloway D, Grazer F. Cancer of the lip. A comparison of five year results after irradiation and surgical therapy. *Am J Surg* 1965; 110: 549-51.
22. Jesse RH, Fletcher GH. Treatment of the neck in patients with squamous cell carcinoma of the head and neck. *Cancer* 1977; 39: 868-72.

23. Fletcher GH. The role of irradiation in the management of squamous cell carcinomas of the mouth and throat. *Head Neck Surg* 1979; 1: 441-57.
24. Goffinet DR, Fee WE, Goode RL. Combined surgery and postoperative irradiation in the treatment of cervical lymph nodes. *Arch Otolaryngol* 1984; 110: 736-8.
25. Martin H. The treatment of cervical metastatic cancer. *Ann Surg* 1941; 114: 972-85.
26. Martin H, Del Valle B, Ehrlich H, Cahan WG. Neck dissection. *Cancer* 1951; 4: 441-99.
27. Strong EW. Preoperative radiation and radical neck dissection. *Surg Clin N Am* 1969; 49: 271-6.
28. Leemans CR, Tiwari RM, van der Waal I, Karim ABMF, Nauta JJP, Snow GB. The efficacy of comprehensive neck dissection with or without postoperative radiotherapy in nodal metastases of squamous cell carcinoma of the upper respiratory and digestive tracts. *Laryngoscope* 1990; 100: 1194-8.
29. De Visscher JGAM, Gooris PJJ, Vermey A, Roodenburg JLN. Surgical margins for resection of squamous cell carcinoma of the lower lip. *Int J Oral Maxillofac Surg* 2002; 31: 154-7.
30. Gooris PJJ, Vermey A, de Visscher JGAM, Burlage FR, Roodenburg JLN. Supraomohyoid neck dissection in the management of cervical lymph node metastases of squamous cell carcinoma of the lower lip. *Head Neck* 2002; 24: 678-83.

:

..

..

.....



---

## **Chapter 9**

### **Summary**

1

2

3

4

In the last decades, there has been an increasing tendency in the field of clinical head and neck oncology toward reducing the use of mutilating surgical procedures, and replacing it by more tissue-saving treatment methods. These current methods consist of a planned combination of less extensive surgery and more limited radiotherapy, and on indication chemotherapy. Some essential aspects of this up to date management for patients with a SCCLL were analyzed in this thesis. Six studies were undertaken to investigate the contribution each treatment strategy has made to the final oncological result.

In the Netherlands, SCCLL is a rather infrequent occurring malignancy: in the period 1989-1998 the incidence was 2.2 for males and 0.3 for females per 100,000 individuals. Chronic life-time exposure to ultraviolet light (sunlight) seems to be the most important etiological factor of SCCLL. Generally, SCCLL grows slowly. The tumor is easily detected clinically, and can therefore usually be diagnosed and treated at an early stage. The occurrence of regional metastasis to the neck varies with an average from 5-15% for smaller SCCLL (T1-T2).

Different surgical and non-surgical specialties are involved in the management of patients presenting with a tumor of the lip. It is imperative to treat these patients in a uniform manner so to offer adequate oncological care resulting in a maximum preservation of function and esthetics. Such uniformity of care can be promoted by a multidisciplinary, guideline-based approach. Treatment of a small primary tumor (T1) consists of either radiotherapy or surgery. The treatment of T2-T3 tumors should be individualized. When the lip tumor is responsible for minor damage, radiotherapy is preferably applied. When the tumor has caused destruction or a defect of the lip, surgery is the treatment of choice. Surgery offers the advantage of rapid treatment, generally complete eradication of the tumor and adequate control of the radicality of the procedure. It, however, concerns an invasive procedure with loss of (un)involved tissue. Radiotherapy has the advantage that it is much less invasive; the functional result and the cosmetic appearance compare favorably to that after a surgical procedure and reconstruction of the defect. Disadvantages are the prolonged time necessary for completion of the radiation treatment and the lack of a specimen for histological examination of the margins. After radiation a dry, atrophic lip may result, more sensitive for actinic environmental influences. At a later stage the radiation may cause fibrosis of the lip. It is for this reason, that in younger patients (< 60 years) there may be a preference for surgical therapy.

In the event of very advanced tumor (T4), generally a planned combination of both surgery and adjuvant radiotherapy is used. An identical combination is advocated for treatment of the neck when there is cytologically or histologically confirmed regional lymph node involvement.

Surgical excision of the primary tumor using a smaller safety margin has shown to be a justified procedure and resulted in a better preservation of perioral function and esthetics with an equally oncological result. Despite the use of less extensive surgical procedures, it is imperative to maintain adequate local tumor control. It is therefore recommended to use frozen section examination of the cut surfaces of the margins of the specimen of the primary tumor to minimize the chance of irradical tumor excision, and in this way reducing the indication for a re-excision at a later stage or postoperative irradiation.

For treatment of the neck, modifications of the radical neck dissection have been developed. This has resulted in a decreased mutilation and morbidity. Increased understanding of the biological behavior and the pattern of lymphatic spread of SCCLL has allowed for more tissue-saving treatment methods. A selective neck dissection for well-defined cervical metastasis at level I, on strict indication followed by adjuvant radiotherapy, has shown to be a valid treatment strategy with relatively low morbidity and a comparable rate of survival when compared with a radical neck dissection (**Chapter 1**).

**Chapter 2** presents the results of a study in which the medical records of 248 patients with squamous cell carcinoma of the lip were retrospectively analyzed to investigate to what extent diagnosis and treatment was carried out in accordance with a multidisciplinary determined regional guideline during the period 1989-1997. The material used was derived from the Comprehensive Cancer Centre Northern Netherlands. It was shown that in these 248 patients the level of compliance to the guideline ranged from 4-80%. It is therefore recommended that a regular review of both the guideline and its implementation is carried out to enhance its use.

**Chapter 3** describes the results of radiation therapy for the treatment of squamous cell carcinoma of the lip. The radiation was applied either as a single treatment modality or after irradical surgery for squamous cell carcinoma of the lip. During the period 1974-1994, 85 patients were treated radiotherapeutically for lip cancer. The radiation therapy consisted of either external beam radiation therapy (EBRT);

orthovoltage 200-300kV, and megavoltage electrons 2-10 MeV), versus brachytherapy (BT; 70 Gy, dose rate 40-80 cGy/hr).

In 69 of the 85 patients EBRT was applied, in 15 patients because of irradical surgery. The other 16 of the 85 patients underwent BT, in four patients after irradical surgical therapy. Eventually, in 19 surgically treated patients incomplete removal dictated the need for adjuvant radiotherapy. These findings support the routine use of frozen section margin evaluation.

A local recurrence was diagnosed in four patients, of whom all were treated initially using EBRT only.

Additionally, the pattern of care was retrospectively analyzed: in 71 of the 85 patients (83%) a pretreatment multidisciplinary consultation was not carried out properly: the treatment strategy was determined monodisciplinary by which door the patient entered.

**Chapter 4** discusses the results of an evaluation of the treatment using CO<sub>2</sub> laser evaporation for leukoplakia of the lower lip in 27 patients during the period 1978-1996.

Short-term evaluation showed a complete epithelialisation four weeks after the CO<sub>2</sub> application. The long-term results showed minimal scar formation without any disturbance of lip function.

During the follow up four recurrences (15%) of leukoplakia were diagnosed; no carcinoma developed in the CO<sub>2</sub> treated area. The recurrence rate after CO<sub>2</sub> evaporation is low when compared to the recurrence rate after surgical excision (10-35%). It is concluded that CO<sub>2</sub> laser evaporation is an effective treatment option for this precancerous disease.

**Chapter 5** presents the results of an evaluation of the use of frozen section examination of the margins for resection of SCCLL. Incomplete tumor resection will increase the risk of local failure. Obtaining clear surgical margins is a condition sine qua non for curative surgery. The medical records of 131 consecutive patients surgically treated for SCCLL during the period 1980-1998 were reviewed. Wedge excision of the SCCLL included a margin of 5-10 mm beyond the tumor. For both resection margins, the full length and full thickness were reviewed. A margin was classified positive when carcinoma in situ or invasive carcinoma was present at the resection surface.

A positive margin was seen in 17 of the 131 patients (13%); immediate re-excision was employed in all 17 patients. In 1 of these 17 patients (6%) a local

recurrence was diagnosed. In the remaining group of 114 patients, 7 patients (6%) developed a local recurrence.

The results of this study demonstrate that frozen section examination of the margins is a useful tool to control the radicality of the surgical procedure. The important advantage in comparison with a definitive decision based on histopathologic examination is that a secondary resection or postoperative radiation can be avoided which otherwise would have been necessary when no frozen section was carried out and the irradicality would have been shown at the final histologic examination of the specimen. However, despite the report of a tumor-free resection surface based on frozen section margin examination, local recurrence may still develop.

In **Chapter 6** the results of the evaluation of the efficacy of a 3 mm margin of resection in the surgical management of SCCLL are reported. The cut surfaces of the margins were peroperatively evaluated by frozen section examination. In this prospective study, 72 consecutive patients underwent wedge- excision, including a 3 mm margin, as the initial treatment for SCCLL during the period 1991-1998. In 9 of the 72 patients (12.5%), the surgical margin contained squamous cell carcinoma, in 8 of the 72 patients (11%) confirmed by final pathologic examination. Local recurrence was found in 2 of the 72 patients (3%): one local recurrence in the patientgroup with tumor free margins, one local recurrence in the patientgroup with tumor in the resected margins. These results indicate that narrowing the surgical margin may be appropriate, provided this more selective surgical approach is accompanied by the routine use of frozen section margin examination.

**Chapter 7** provides an evaluation of the results using a selective neck dissection for the treatment of regional lymph node metastases of SCCLL. It concerns a therapeutic supraomohyoid neck dissection (SOHND), on indication followed by radiotherapy in the management of cervical lymph node metastases (cN1), located in level I of the neck. A total of 44 patients was treated for this metastatic cervical nodal disease during the period 1975-1998.

Patients with a single metastatic node, smaller than 3 cm and without extracapsular spread (n=12) were treated by SOHND only. All others (n=32) were treated by SOHND, followed by megavoltage therapy (mean dose 61 Gy, range 50-70 Gy, daily dose 2 Gy, 5 fractions per week).

Regional recurrence was observed in 4 of the 44 patients (9%). The most consistent findings in the patients presenting with a recurrence was the combined

presence of both a pN2b nodal status and extracapsular tumor spread. The four recurrences developed in respectively level I (2 patients) and level II (2 patients). No recurrences were diagnosed beyond the surgically treated area.

When using a selective neck dissection, regional control can be achieved to a level comparable to that after a (modified) radical neck dissection. It is concluded from the results of this study that the use of this more tissue-saving less mutilating therapeutic SOHND, on indication followed by radiotherapy, may be considered an oncologically sound and effective procedure in the management of cervical metastatic disease resulting from SCCLL, limited to level I of the neck.

**Chapter 8** contains the general discussion and conclusions. The need for a multidisciplinary approach for diagnosis and treatment is emphasized. Management should be employed according to available guidelines.

Early diagnosis and treatment of leukoplakia, being considered a premalignant disease will result in a reduction of the development of lipcancer. The CO<sub>2</sub> laser evaporation has proven to be an effective treatment method.

Surgery and radiotherapy, or a combination of both treatment modalities for SCCLL are discussed. The concept of a planned multimodality therapy offers the advantage of less than maximum surgery and less than maximum radiation, which results in less mutilation and less early and late radiation-related side effects. The use of a smaller margin implicates less mutilation when resecting a lip tumor. The surgical resection, however, needs to be accompanied by frozen section margin examination to contribute to a reduced need for a secondary surgical procedure or postoperative radiotherapy.

In view of the development of less mutilating procedures it is shown to be justified that, instead of a (modified) radical neck dissection a selective neck dissection may be used for the treatment of cervical metastatic disease (cN1) located in level I of the neck, on strict indication followed by radiotherapy. This will prevent the morbidity and the mutilation, generally associated with a (modified) radical neck dissection.

The increased knowledge of the biologic behaviour and the planned multidisciplinary diagnosis and treatment of squamous cell carcinoma of the lip has allowed for more tissue-saving procedures without compromising the oncological result.

1

2

3

4

5



---

# Samenvatting

1  
2  
3  
4  
5  
6  
7  
8  
9  
10  
11  
12  
13  
14  
15  
16  
17  
18  
19  
20  
21  
22  
23  
24  
25  
26  
27  
28  
29  
30  
31  
32  
33  
34  
35  
36  
37  
38  
39  
40  
41  
42  
43  
44  
45  
46  
47  
48  
49  
50  
51  
52  
53  
54  
55  
56  
57  
58  
59  
60  
61  
62  
63  
64  
65  
66  
67  
68  
69  
70  
71  
72  
73  
74  
75  
76  
77  
78  
79  
80  
81  
82  
83  
84  
85  
86  
87  
88  
89  
90  
91  
92  
93  
94  
95  
96  
97  
98  
99  
100

Op het gebied van de klinische hoofd-halsoncologie is in de laatste decennia een ontwikkeling gaande om mutilerende chirurgische procedures te vervangen door meer weefselsparende operaties. Deze huidige behandelmethoden bestaan uit een geplande combinatie van minder uitgebreide chirurgie, beperkter radiotherapie en op indicatie chemotherapie. Enkele essentiële aspecten van deze moderne zorg voor patiënten met een plaveiselcelcarcinoom van de onderlip worden in dit proefschrift geanalyseerd. Een zestal studies werd uitgevoerd om vast te stellen welke bijdrage elke afzonderlijke benadering en behandelstrategie heeft geleverd aan het oncologisch resultaat.

Het plaveiselcelcarcinoom van de onderlip is in Nederland een betrekkelijk zeldzame maligniteit: de incidentie gedurende de periode 1989-1998 bedroeg 2,2 voor mannen en 0,3 voor vrouwen per 100.000 individuen. Chronische cumulatieve blootstelling aan ultraviolette straling (zonlicht) lijkt de belangrijkste oorzakelijke factor voor het plaveiselcelcarcinoom van de onderlip. Over het algemeen groeit het plaveiselcelcarcinoom van de onderlip langzaam. De tumor is gemakkelijk klinisch te detecteren en kan daardoor meestal in een vroeg stadium worden gediagnosticeerd en behandeld. Regionale metastasering naar de hals treedt gemiddeld in 5 tot 15% van de patiënten op, indien er sprake is van kleinere plaveiselcelcarcinomen (T1 en T2) van de onderlip.

Er zijn verschillende chirurgische en niet-chirurgische specialismen bij de zorg voor patiënten met een lipcarcinoom betrokken. Het is noodzakelijk deze patiënten op een uniforme wijze te behandelen, opdat adequate oncologische zorg met een maximum aan behoud van functie en esthetiek kan worden geboden. Een dergelijke uniformiteit van zorg kan worden bevorderd door een multidisciplinaire, op een richtlijn gebaseerde benadering. Behandeling van een kleine primaire tumor (T1) bestaat uit ofwel radiotherapie dan wel chirurgie. De behandeling van T2-T3 tumoren dient per geval te worden beoordeeld. Indien de lip slechts in geringe mate door tumor beschadigd is, verdient radiotherapie de voorkeur. Is er ten gevolge van de tumor sprake van weefselverlies (defect) van de lip, dan is een chirurgische benadering aangewezen. Chirurgie biedt het voordeel van een snelle en complete tumorverwijdering met controle over de radicaliteit van de ingreep. Het betreft echter een invasieve procedure met opoffering van weefsel. Bestraling heeft als voordeel dat de anatomie van de lip grotendeels behouden blijft, waardoor het functionele resultaat en het cosmetisch aspect beter zijn dan na chirurgische behandeling en eventuele reconstructie van het defect. Nadelen zijn onder meer de lange tijdsperiode van de bestralingsbehandeling en het ontbreken van

een preparaat voor histologisch onderzoek van de sneevlakken. Er kan een droog, atrofisch aspect van de lip ontstaan, meer gevoelig voor actinische invloeden. Voorts kan de bestraling in een later stadium aanleiding geven tot fibrose van het lippenrood. Dit heeft ertoe geleid, dat bij jongere patiënten (< 60 jaar) er een voorkeur kan bestaan voor een chirurgische behandeling. In geval van een voortgeschreden primaire tumor (T4) wordt in het algemeen gebruik gemaakt van een geplande combinatie van chirurgie en radiotherapie. Een overeenkomstige combinatie wordt aanbevolen voor de behandeling van de hals, wanneer er sprake is van cytologisch of histologisch bevestigde regionale lymfekliermetastasen.

Chirurgische excisie van de primaire tumor van de onderlip met een kleinere marge rondom de tumor blijkt verantwoord en resulteert in een beter behoud van de peri-orale functie en esthetiek bij een tenminste gelijkblijvend oncologisch resultaat. Ondanks de toepassing van minder uitgebreide chirurgie blijft het streven naar maximale locale tumor controle voorwaarde. Daarom wordt geadviseerd per-operatief vriescoupeonderzoek van de sneevlakken van het excisiepreparaat uit te voeren om de kans op irradicale verwijdering, en daarmee de noodzaak voor re-excisie in een tweede zitting danwel postoperatieve radiotherapie, te minimaliseren.

Ten aanzien van de behandeling van de hals zijn er in de loop van de tijd verschillende modificaties met betrekking tot de radicale halsklierdissectie ontwikkeld. Dat heeft geleid tot een geringere mutilatie en morbiditeit. Het toegenomen inzicht in het biologische gedrag en het lymfogene metastaseringspatroon van het plaveiselcelcarcinoom van de onderlip heeft de toepassing van meer weefselsparende behandelmethoden mogelijk gemaakt. Het blijkt dat een selectieve halsklierdissectie voor halskliermetastasering in niveau I van de hals, op indicatie gevolgd door radiotherapie een valide behandelmethode is met een beperkter morbiditeit en een vergelijkbaar goede kans op genezing in vergelijking met de radicale halsklierdissectie (**Hoofdstuk 1**).

**Hoofdstuk 2** geeft een overzicht van de resultaten van een studie waarbij de medische dossiers van 248 patiënten met een plaveiselcelcarcinoom van de lip retrospectief werden geanalyseerd om te beoordelen, in hoeverre diagnostiek en behandeling in de periode 1989-1997 werd uitgevoerd volgens een multidisciplinair bepaalde regionale richtlijn. Het onderzoek werd verricht aan de hand van gegevens van 248 patiënten afkomstig uit het verzorgingsgebied van het Integraal Kankercentrum Noord-Nederland (IKN). Aangetoond werd dat bij deze patiënten in 4-80% van de gevallen volgens de richtlijn werd gediagnosticeerd en behandeld.

Naar aanleiding van de resultaten van dit onderzoek wordt geadviseerd zowel de richtlijn alsmede de implementatie ervan regelmatig te beoordelen om op deze wijze het gebruik van richtlijnen te bevorderen.

In **Hoofdstuk 3** worden de resultaten besproken van radiotherapie van het plaveiselcelcarcinoom van de lip. De bestralingsbehandeling werd enerzijds toegepast als primaire behandelmodaliteit en anderzijds als behandeling na niet-radical chirurgie.

Gedurende de periode 1974-1994 werden 85 patiënten met een plaveiselcelcarcinoom van de lip bestraald. De radiotherapie bestond uit uitwendige bestraling (orthovolt 200-300 kV en megavolt elektronen 2-10 MeV) dan wel brachytherapie (60-66 Gy, dosistempo 40-80 cGy/uur).

Bij 69 van de 85 patiënten werd uitwendige bestraling toegepast, in 15 gevallen wegens niet-radical chirurgie. Bij de overige 16 van de 85 patiënten werd brachytherapie aangewend; bij vier patiënten als gevolg van incomplete chirurgische verwijdering.

Aldus was bij 19 patiënten (22%), die primair chirurgisch werden behandeld, een niet-radical tumorverwijdering de indicatie voor de postoperatieve radiotherapie. Deze bevindingen ondersteunen het advies routinematig vriescoupeonderzoek van de sneevlakken te verrichten.

Bij vier patiënten werd een lokaal recidief gediagnosticeerd; alle vier recidieven traden op in de groep patiënten die primaire uitwendige bestraling ondergingen.

Daarnaast werd het patroon van de zorg retrospectief geanalyseerd. Bij 71 van de 85 patiënten (83%) vond geen aan de behandeling voorafgaand multidisciplinair overleg plaats: de behandelkeuze werd monodisciplinair door het poortspecialisme bepaald.

In **Hoofdstuk 4** worden de resultaten beschreven van 27 patiënten met een leukoplakie van de onderlip, die met behulp van CO<sub>2</sub>-laserverdamping werden behandeld in de periode 1978-1996.

Kortetermijn evaluatie toont dat er vier weken na de behandeling sprake is van een volledige epithelialisatie. De langetermijn resultaten tonen een minimale verlittekening zonder verstoring van de lipfunctie.

Gedurende de follow-up werden vier recidieven (15%) gediagnosticeerd, bij geen van de patiënten heeft zich een maligniteit ontwikkeld in het behandelde gebied. Het percentage recidieven na CO<sub>2</sub>-laserverdamping is laag in vergelijking

met het percentage recidieven na chirurgische verwijdering (10-35%). Geconcludeerd wordt dat de CO<sub>2</sub>laserverdamping is een effectieve behandelmethode voor deze premaligne afwijking.

In **Hoofdstuk 5** worden de resultaten besproken van een evaluatie van het gebruik van peroperatief vriescoupeonderzoek van de sneevlakken bij resectie van het plaveiselcelcarcinoom van de onderlip. Incomplete resectie van de tumor betekent een verhoogd risico van het optreden van een lokaal recidief. Het verkrijgen van vrije sneevlakken is een *conditio sine qua non* voor curatie.

Er vond een analyse plaats van de gegevens uit de medische dossiers van 131 chirurgisch behandelde patiënten. De wigexcisie werd uitgevoerd inclusief een 5-10 mm marge rondom de tumor. Beide resectievlakken werden peroperatief met vriescoupeonderzoek over de volle lengte en breedte beoordeeld. Een sneevlak werd 'positief' bevonden indien er carcinoma *in situ* dan wel invasief carcinoom in het resectievlak werd aangetroffen.

Een positief sneevlak was aanwezig bij 17 van de 131 patiënten (13%); resectie in dezelfde zitting vond plaats bij alle 17 patiënten. Bij 1 van de 17 patiënten (6%) met een positief sneevlak trad een lokaal recidief op. Bij de overige 114 patiënten met een vrij sneevlak trad bij 7 patiënten (6%) een lokaal recidief op.

De resultaten van dit onderzoek tonen aan dat vriescoupeonderzoek van de sneevlakken een goede methode is voor peroperatieve controle van de radicaliteit van de chirurgische ingreep. Dit heeft als belangrijk voordeel boven het nemen van het besluit op basis van de uitslag van het definitieve pathologisch onderzoek dat een secundaire resectie of postoperatieve radiotherapie kan worden voorkomen, hetgeen noodzakelijk zou zijn indien geen vriescoupe werd uitgevoerd en de irradicaliteit van de resectie pas duidelijk wordt bij definitief histologisch onderzoek. Ondanks een tumorvrij resectievlak op basis van vriescoupeonderzoek van de sneevlakken is het optreden van een lokaal recidief niet uitgesloten.

In **Hoofdstuk 6** worden de resultaten besproken van een evaluatie naar de doelmatigheid van het gebruik van een 3 mm marge bij de chirurgische verwijdering van een plaveiselcelcarcinoom van de onderlip. De sneevlakken werden peroperatief door middel van vriescoupeonderzoek beoordeeld.

In het prospectief onderzoek werd bij 72 patiënten een wigexcisie met een marge van 3 mm als initiële behandeling voor een plaveiselcelcarcinoom van de onderlip uitgevoerd. Bij 9 van de 72 patiënten (12,5%) werd met vriescoupeonderzoek tumor aangetoond in de sneevlakken, bij 8 van de 72 patiënten (11%) nadien

bevestigd door definitief histopathologisch onderzoek. Bij 2 van de 72 patiënten (3%) trad een lokaal recidief op; 1 recidief ontwikkelde zich in de patiëntengroep bekend met tumorvrije sneevlakken, 1 recidief in de patiëntengroep met niet tumorvrije sneevlakken.

De resultaten tonen aan dat een smallere chirurgische marge verantwoord kan worden toegepast, mits deze meer selectieve chirurgische benadering wordt gecombineerd met routinematig vriescoupeonderzoek van de sneevlakken.

In **Hoofdstuk 7** worden de resultaten beschreven van het gebruik van een selectieve halsklierdissectie voor de behandeling van regionale lymfekliermetastasen van een plaveiselcelcarcinoom van de onderlip. Het betreft een therapeutische supra-omohyoidale halsklierdissectie (SOHKD), op indicatie gevolgd door radiotherapie, voor de behandeling van halskliermetastasering (cN1), gelokaliseerd in niveau I van de hals. In totaal werden 44 patiënten op deze wijze behandeld.

Patiënten met slechts één kliermetastase, kleiner dan 3 cm en zonder extracapsulaire groei (n=12) werden uitsluitend met een SOHKD behandeld. De overige patiënten (n=32) ondergingen een SOHKD, gevolgd door megavolt radiotherapie (gemiddelde dosis 61 Gy, variatiebreedte 50-70 Gy, dagelijkse dosis 2 Gy, 5 fracties per week).

Bij 4 van de 44 patiënten (9%) trad een regionaal recidief op. De meest constante bevinding bij alle vier patiënten die een regionaal recidief ontwikkelden was de gecombineerde aanwezigheid van een pN2b klierstatus en extracapsulaire groei. De recidieven ontwikkelden zich in respectievelijk niveau I (2 patiënten) en niveau II (2 patiënten). Er heeft zich geen recidief ontwikkeld buiten het chirurgisch behandelde gebied.

Met het gebruik van een selectieve halsklierdissectie blijkt een regionale controle te kunnen worden bereikt, vergelijkbaar met die na een (gemodificeerde) radicale halsklierdissectie. Deze studie toont aan dat de meer weefselsparende en minder mutilerende SOHKD, op indicatie gevolgd door postoperatieve radiotherapie, beschouwd kan worden als een oncologisch verantwoorde procedure voor de behandeling van halskliermetastasering van een plaveiselcelcarcinoom van de onderlip, dat zich heeft beperkt tot niveau I van de hals.

**Hoofdstuk 8** omvat de algemene discussie en conclusies. De noodzaak van een multidisciplinaire benadering voor de diagnostiek en behandeling van patiënten met een lipcarcinoom wordt benadrukt. De zorg dient volgens daartoe beschikbare richtlijnen te worden uitgevoerd.

Vroegtijdige diagnostiek en behandeling van leukoplakie als premaligne aandoening van de onderlip draagt bij tot een reductie van het ontstaan van een lipcarcinoom. De CO<sub>2</sub>laserverdamping is een effectieve behandelmethode gebleken.

Chirurgie, radiotherapie of een combinatie van deze behandelmodaliteiten voor de behandeling van het plaveiselcelcarcinoom van de onderlip worden besproken. Het concept van een geplande multimodale behandelingsstrategie heeft als belangrijk voordeel dat het gebruik van minder dan maximale chirurgie en minder dan maximale bestraling mogelijk wordt, hetgeen resulteert in een verminderde mutilatie en een afname van het aantal vroege en late bestralingsgerelateerde neveneffecten. Het gebruik van een smallere marge resulteert bij de verwijdering van een plaveiselcelcarcinoom van de onderlip in een geringere mutilatie. De resectie dient vergezeld te gaan van peroperatief vriescoupeonderzoek van de sneevlakken waardoor de indicatie voor een tweede chirurgische procedure of postoperatieve radiotherapie kan worden gereduceerd.

Op stricte indicatie kan een chirurgisch minder mutilerende benadering van de hals plaatsvinden: een selectieve in plaats van een (gemodificeerd) radicale halsklierdissectie.

Het toegenomen inzicht in het biologisch gedrag en de multidisciplinaire diagnostiek en behandeling van het plaveiselcelcarcinoom van de lip heeft geleid tot meer weefselsparende procedures zonder de kans op curatie geweld aan te doen.



## Dankwoord

Voor het schrijven van een manuscript is steun van anderen onontbeerlijk. Nu de voltooiing van het proefschrift nadert, is de tijd aangebroken voor enige bezinning. Vele uren zijn doorgebracht met vele anderen; het wordt nu tijd om deze “anderen” te bedanken voor hun inspanningen.

Lieve Christel, vele omzwervingen hebben we samen gemaakt totdat we uiteindelijk in Breda zijn beland. Inmiddels heb je zelf vele inspanningen moeten leveren op je eigen vakgebied die hebben geresulteerd in een orthodontiepraktijk met een goede reputatie. Je hebt mij vervolgens de ruimte gegeven, en het is met name ook dankzij jouw inzet en geduld dat het na al die jaren gelukt is dit proefschrift te laten verschijnen. Naast de dagelijkse kaakchirurgische praktijkbeslommeringen was ik heel veel avonden “afwezig”, zat ik achter de computer vaak tot in de nachtelijke uurtjes. Gedurende deze periode heb je achtereenvolgens Pim, Anne-Sophie en Haye op de wereld gebracht. Chris, je bent een onmisbare kracht voor ons gezin, ons boekje is nu klaar; lieve kindjes, pa krijgt nu meer tijd om aan het fantastische gezinsleven deel te nemen.

Prof.dr. J.L.N. Roodenburg, hooggeachte promotor, beste Jan. Vanaf het prille begin hebt u samen met professor Vermey het vele werk begeleid. Mede door uw inspanningen en uw vakkundige begeleiding is het mij mogelijk gebleken dit manuscript te doen verschijnen. Het klinisch werk werd voor mij toegankelijk gemaakt door het feit dat ik gebruik heb mogen maken van uw beschikbare patiëntenmateriaal, zodat mijn onderzoek kon plaats vinden. Het was altijd weer plezierig om “terug” te zijn op de afdeling in Groningen. Het wekelijks telefonisch overleg gedurende al die jaren heeft mij veel deugd gedaan. Ik heb veel geleerd van uw specifieke kennis; uw niet aflatende enthousiasme was vaak een belangrijke steun in de rug op afstand. Ik ben u zeer erkentelijk voor alle aangereikte hulp bij het tot stand komen van dit proefschrift.

Prof.dr. A. Vermey, hooggeachte promotor, beste Bert. Destijds hebt u een onderzoek naar kanker van de lip voorgesteld. Daaropvolgend hebben wij zeer vele uren ‘samen’ doorgebracht. Vaak dankbaar gebruikmakend van de gastvrijheid bij de leermeester thuis, maar vaker nog via de telefoon. E-mail teksten werden

nauwkeurig met het zeeffe gelezen en becommentarieerd: “geronk” moest uit de tekst worden geschrapt. Naast onze vaste wekelijkse sessies was het u nooit teveel indien ik soms op ongebruikelijke momenten wederom gebruik wilde maken van uw kennis en kunde. In een aantal hoofdstukken zult u zeker aspecten van uw toegewijde oncologische werkwijze uit het verleden terug vinden. Professor Vermeij, ik ben u zeer dankbaar voor uw talloze momenten van onderwijzen, die voor mij een belangrijke bijdrage zijn geweest voor het oncologisch leren denken.

Dr. R. Otter, zeer geleerde referent, beste Renée. Graag wil ik u bedanken voor de enorme gastvrijheid en uw enthousiaste steun bij het verzamelen en verwerken van patiëntengegevens, welke zijn ondergebracht bij het Integraal Kankercentrum Noord-Nederland (IKN). Opvallend was altijd uw efficiënte zeer doelgerichte aanpak bij de uitvoering van wetenschappelijk onderzoek. U bracht een duidelijke structuur aan en wist hoofd- en bijzaken goed te scheiden: zowaar een belangrijke voorwaarde voor onderzoek.

Dr. J.G.A.M. de Visscher, zeer geleerde referent, beste Jan. Zonder twijfel bent u een belangrijke en bijzondere stimulans geweest bij de bewerking van dit proefschrift. Uw uitgebreide kennis op dit specifiek oncologische terrein alsmede uw behulpzaamheid hebben voor mij een waardevolle bijdrage betekend. U bezit het vermogen de zaken op de juiste momenten te relativieren, een eigenschap die een belangrijk aspect vormt bij de bewerking van een manuscript. Daarnaast ontbrak vrijwel nooit een humoristische kwinkslag, van evenzo groot belang voor een vruchtbare samenwerking.

Dhr. M. Schaapveld, beste Michael. Dank voor de hulp bij de voorbereidingen voor het onderzoek van patiëntenmateriaal, beschikbaar gesteld door het IKN.

Dhr. F.R. Burlage, beste Fred. Dank voor uw medewerking bij het tot stand komen van dit proefschrift.

Dr. B. Maat en Drs. Ph.M.P. Poortmans, beste Ben en Philip. Beiden ben ik u zeer erkentelijk voor uw hulp bij het onderzoek naar de resultaten van de toepassing van radiotherapie (Dr. B. Verbeeten Instituut) bij patiënten met een lipcarcinoom.

Dr J.W.W. Coebergh, Ir. M. Louwman (Integraal Kankercentrum Zuid), ik heb uw beider voortvarende medewerking bij het verzamelen van epidemiologische informatie met betrekking tot het lipcarcinoom in Nederland ten zeerste gewaardeerd.

Dr. J.A. Roukema, beste Anne. Dank voor uw positieve belangstelling gedurende de toen nog prille onderzoeksfase.

Dr. J.J.G.M. Pilon, beste Jack. Dank voor uw kritische bewerking van het uiteindelijke manuscript vanuit Zeebrugge.

De leden van de beoordelingscommissie, Prof.dr. F.W.J. Albers, Prof.dr. H.J. Hoekstra en Prof.dr. R. Koole wil ik hartelijk danken voor hun snelle en kritische analyse van het manuscript.

Prof.dr. G. Boering, Prof.dr. P.J.W. Stoelinga, beste Geert, beste Paul. U beiden wil ik hartelijk danken voor het door u in mij gestelde vertrouwen en uw stimulerende onderwijsactiviteiten. Dr. P. Worthington, dear Philip. Thank you so much for your warm support during my specialty training in Oral and Maxillofacial Surgery at the University of Washington, Seattle. Our mutual interest in Mongolian Beef and Beck's Beer will never fade.

Dhr J. Bosker, medisch administratief medewerker afdeling Chirurgie, Academisch Ziekenhuis Groningen. Het steeds maar weer opnieuw aanleveren van "oude" patiëntendossiers was voor u nimmer aanleiding tot enig commentaar; dank voor uw inzet bij dit onderzoek.

Dames van het secretariaat van de afdeling Mondziekten en Kaakchirurgie van het AZG, mw. M. Been, mw. W. Ganesh, mw. S.E. Schweertmann en mw. N.E. Jaeger, beste Miranda, Wadia, Sya en Nienke, allen hartelijk dank voor de plezierige medewerking.

Laraine Visser, uw vele Engelstalige correcties hebben menig stuk tekst aanzienlijk verbeterd en daardoor beter toegankelijk gemaakt voor publicatie, hiervoor mijn hartelijke dank.

Dr. B. van der Kuijl, beste Bart. Dankzij uw nauwgezette instelling en uw betrokkenheid is het definitieve concept van het manuscript inclusief de uiteindelijke lay-out snel tot stand gekomen, mijn bijzondere dank hiervoor.

Mw. E. van Peer, beste Evelien. Gedurende al die jaren van onderzoek kon ik altijd een beroep doen op uw deskundige en vlotte hulp; gedane afspraken misten nooit. Hopelijk komen er nog vele jaren van een overeenkomstige samenwerking.

Leden van onze maatschap Mondziekten en Kaakchirurgie, Amphia Ziekenhuis te Breda, Dr. J.E. Bergsma, D. Besling, F.R.C. Lippens, Dr. J.I.J.F. Vermeeren, Dr. A.B.E Voûte, V.G.M.J. Wolters, beste Eelco, Dick, Frank, Jacques, Bert en Vincent. Dank voor de bereidwilligheid om mij deze wetenschappelijke klus naast de gebruikelijke dagelijkse werkzaamheden te laten klaren.

Dhr. J.M.A. de Laet en Dhr. L.J. van Rijn, beste Jan en René. Dank voor de vele deskundige automatiseringsadviezen.

Mw. I.C.J. van Nuland en mw. J. de Grauw, beste Irene en José, bedankt voor jullie immer beschikbare, onontbeerlijke oppasfaciliteiten.

Dhr C. Morgan, beste Cole. Ik stel het zeer op prijs, dat ik een van uw kunstwerken voor de omslag van dit proefschrift heb mogen gebruiken.

Dhr W.H.J. Kuipers en Mw G. Kuipers-Wetering, beste Willy, lieve Geesje. Dank voor jullie talrijke inspanningen gedurende het totstandkomen van dit proefschrift.

Lieve Pa en Ma, zonder uw warme belangstelling, uw tomeloze inzet en begeleiding gedurende mijn school en studiejaren had ik dit nimmer kunnen bereiken. Pa, altijd weer was u de stimulerende motor om vooral toch goede studieresultaten te behalen. Zin had ik niet altijd, toch lukte het u om mij te motiveren goed te presteren. De laatste jaren hebben we samen heel wat ritjes naar Groningen gemaakt in het kader van het onderzoek; u zorgde voor gezelligheid, warme worstenbroodjes en koffie. Dit proefschrift is mede een kroon op uw inspanningen.

Peter Gooris

## Curriculum vitae

The author of this thesis was born in Oss, the Netherlands in 1954. He finished secondary school at the Christelijk Lyceum in Apeldoorn in 1975 (VWO exam) and in 1982 received his dental degree (DMD) at the Subfaculty of Dentistry of the University of Groningen, the Netherlands. From 1982 to 1985 he practiced general dentistry in Rosmalen, the Netherlands.

During 1985 to 1989 he served as a resident at the Department of Oral and Maxillofacial Surgery, University Hospital, University of Washington, Seattle WA, USA (Professor and Chairman: Philip Worthington, MD, BSc, FDSRCS). This residency included a six months rotation at the Department of Oral and Maxillofacial Surgery of the Rijnstate Hospital, Arnhem, the Netherlands (Head at that time: P.J.W. Stoelinga, MD, DMD, PhD).

From 1989 to 1990 he was involved at the Department of Oral and Maxillofacial Surgery, Groningen University Hospital (Professor and Chairman at that time: G. Boering, DDS, PhD). In 1990, he was registered as an oral and maxillofacial surgeon in the Netherlands.

From 1989 to 1992 he studied medicine at the Faculty of Medical Sciences, University of Groningen, where he completed his medical degree (MD) in November 1992. Since December 1992 he is active as an oral and maxillofacial surgeon in the Amphia Hospital (at that time St. Ignatius Hospital) in Breda, the Netherlands.

In September 2000, he completed the examination of the European Board of Oro-Maxillofacial Surgery (FEBOMS) in Edinburgh, UK.

