

# Human Amniotic Membrane Is Not Suitable for the Grafting of Colon Lesions and Prevention of Adhesions in a Xenograft Rat Model

Surgical Innovation

1–8

© The Author(s) 2017

Reprints and permissions:

[sagepub.com/journalsPermissions.nav](http://sagepub.com/journalsPermissions.nav)

DOI: 10.1177/1553350617709828

[journals.sagepub.com/home/sri](http://journals.sagepub.com/home/sri)

Dimitri Barski, MD<sup>1</sup>, Holger Gerullis, PhD<sup>2</sup>, Thorsten Ecke, PhD<sup>3</sup>, Gabriella Varga, PhD<sup>4</sup>, Mihaly Boros, PhD<sup>4</sup>, Isabel Pintelon, PhD<sup>5</sup>, Jean-Pierre Timmermans, PhD<sup>5</sup>, and Thomas Otto, PhD<sup>1</sup>

## Abstract

**Introduction.** New biological materials are needed for specific applications in reconstructive bowel surgery and for the prevention of adhesion formation. Amniotic membranes (AMs) are assumed to have a number of unique characteristics that enhance the ingrowth of the surrounding tissue. The aim of the present study was to provide proof of these qualities in a xenograft model. **Materials and methods.** A multilayer human AM (HAM) was applied to repair defined colon wall defects in Sprague-Dawley rats ( $n = 18$ ). The control group was repaired with a suture ( $n = 6$ ). The animals were killed humanely at 7, 21, and 42 days after implantation. Adhesions and perioperative complications were examined. Histological and immunohistological analyses were performed to assess a number of parameters, including degradation of the HAM, inflammation, graft rejection, and smooth muscle ingrowth. **Results.** Two rats in the treated group died. No other severe complications were observed. Adhesion formation was more prominently visible in the HAM group ( $P < .05$ ). The initially increased inflammation in the HAM group reduced over time but remained significantly increased ( $P < .05$ ). The HAM degraded over time and a subtle transient glomerulitis could be observed. **Conclusion.** HAMs were found to increase adhesion formation and were not suitable for bowel augmentation in the presented xenograft model.

## Keywords

amniotic membrane, xenolog transplantation, bowel lesion, anastomosis, adhesions, IDEAL recommendations

## Introduction

Anastomotic leakage (AL) is a major complication of bowel reconstructive surgery, occurring in 4.8% to 37.5% of cases.<sup>1–3</sup> AL causes consecutive peritonitis, adhesions, and fistula formation with significant morbidity and mortality. Adhesion formation is a serious issue of bowel surgery and has been found to be highly prevalent in patients with a history of multiple abdominal operations or peritonitis. These patients are at a high risk of development serious intraoperative complications during a subsequent operation if adhesiolysis is performed. These complications include bowel perforation, ureteral or bladder injury, and vascular injury.<sup>4,5</sup> Much research efforts have been devoted to finding materials and improved surgical techniques to protect high-risk gastrointestinal anastomosis during the critical days of healing. Allogeneic (peritoneum), xenolog (collagen), and synthetic materials (polymers) and sealants

(fibrin) have been previously tested to protect the anastomosis and prevent AL and adherence formation.<sup>6–10</sup> Most of the trials were animal trials and have not yet been able to identify the optimal barrier to prevent adhesions in a sustainable way.<sup>11</sup> In most trials, detailed information on materials and methods according to IDEAL criteria is missing.<sup>12</sup> Synthetic materials, such as polymers, are available but give rise to additional complications, and serious concerns

<sup>1</sup>Lukas Hospital Neuss, Germany

<sup>2</sup>Carl von Ossietzky University, Oldenburg, Germany

<sup>3</sup>Helios Hospital, Bad Saarow, Germany

<sup>4</sup>University of Szeged, Hungary

<sup>5</sup>University of Antwerp, Belgium

## Corresponding Author:

Dimitri Barski, Department of Urology, Lukas Hospital Neuss, Preussenstr 84, 41464 Neuss, Germany.  
Email: [dbarski@lukasneuss.de](mailto:dbarski@lukasneuss.de)

have recently been expressed about the use of alloplastic materials.<sup>8,13</sup>

We hypothesized that application of hypoallergenic human amniotic membranes (HAMs) containing multiple growth factors could improve the regeneration of the colon wall and prevent adhesions caused by their anti-inflammatory characteristics. Outcomes of reconstruction of an experimental colon wall defect using a HAM graft were compared with outcomes in a group that was repaired with suture only. Mechanical characteristics, such as dehiscence and adhesion formation, were examined, and a number of parameters, including AM degradation, inflammation, possible rejection, and tissue ingrowth, were histologically analyzed. Following the IDEAL-D system of surgical innovations, we established a preclinical xenograft model in an attempt to provide evidence that HAMs are instrumental in repairing rat bowel defects. These experiments can be categorized as a stage 0 preclinical study.<sup>12,14</sup>

## Materials and Methods

### Human Amniotic Membrane

HAMs were obtained immediately after elective cesarean sections with normal gestation. The donors were screened for infections, including HIV, hepatitis, and syphilis, after informed consent. The placenta was cleaned of blood clots with sterile phosphate-buffered saline (PBS), and the amnion was separated from the chorion by blunt dissection under laminar flow conditions. The separated membranes were cut into blocks of at least  $5 \times 5 \text{ cm}^2$  with the epithelial side up. After several rinsing steps, the HAMs were frozen at  $-20^\circ\text{C}$  for 24 hours until further use. For further processing, the HAMs were defrosted in water, sterilized in peracetic acid and alcohol mixture, and then incubated for 2 hours on the shaker. After rinsing, the amnion was prepared in 4 layers applied on a sterile silicon scaffold in order to hold shape and dried under laminar flow.

### Experimental Animals

The animal experiment was conducted at the Institute for Experimental Surgery of the University of Szeged, Hungary, in accordance with the National Institutes of Health (NIH) guidelines (Guide for the Care and Use of Laboratory Animals). The experimental protocol was approved by the Animal Welfare Committee at the University of Szeged (license number V./146/2013). The experiments were performed according to the EU Directive 2010/63/EU on the protection of animals used for experimental and other scientific purposes and carried out in strict adherence to the NIH guidelines for the use of experimental animals. The study

was approved by the National Scientific Ethical Committee on Animal Experimentation (National Competent Authority).

A total of 27 male Sprague Dawley rats, weighing between 320 and 380 g and 3 months old, were housed and cared for at Szeged University's farm for experimental animal studies. All animals had free access to food and water and were cared for by an educated keeper and routinely inspected by a veterinarian.

### Operation Procedure

The procedures were performed by 2 surgeons (DB and HG) using sterile surgical techniques. The 27 adult male Sprague-Dawley rats were anesthetized by intraperitoneal injection of 40 mg/kg of ketamine 10%. The abdomen was shaved and prepared with an ethanol-propanol solution. Rats were operated in the supine position. A microscope and microsurgical instruments were used. A midline laparotomy was performed under antiseptic conditions. The colon was identified and a defined 0.5 cm of the cecum wall was resected. In the treated amnion group (A,  $n = 18$ ), a multilayer amnion patch was trimmed overlapping the defect size ( $10 \times 10 \text{ mm}^2$ ) and fixed to the colonic wall with 3 or 4 interrupted 6-0 Monocryl sutures (Ethicon, Norderstedt, Germany). Additionally, human fibrin glue (Evicel, OMRIX Biopharmaceuticals LTD, Israel) was used to seal the lesion. In the first control group (C1,  $n = 6$ ), the defect was closed with a single Monocryl 6-0 running suture and fibrin glue. In the second control group (C2,  $n = 3$ ), the amnion graft was sutured to the colonic wall without prior lesion. Fluid loss was compensated by administering 3 mL of 0.9% saline intraperitoneally at the end of surgery. The abdominal muscle layer and skin were closed separately with absorbable Vicryl 5-0 running sutures and Monocryl 4-0 interrupted sutures (Ethicon). Animals were fed with standard rat chow and water starting at the sixth hour postlaparotomy.

The animals were killed humanely at 1 (A,  $n = 5$ ; C1,  $n = 2$ ; C2,  $n = 1$ ), 3 (A,  $n = 6$ ; C1,  $n = 2$ ; C2,  $n = 1$ ), and 6 (A,  $n = 5$ ; C1,  $n = 2$ ; C2,  $n = 1$ ) weeks after surgery. Subsequently, tissue samples (colon, kidneys, spleen) were harvested and stored in 10% formalin solution for 2 hours and then stored in PBS at  $4^\circ\text{C}$ .

### Clinical Assessment

During postmortem examination, the grafts were examined macroscopically by 2 surgeons (DB and HG). Existence of peritonitis, and abscess and adhesion formation were recorded. The colon wall was assessed regarding adhesions and inflammation. The adhesion-covered area was graded semiquantitatively between 0 and 3 according to the score developed by van der Hamm et al.<sup>15</sup> (Table 1). Results were documented by photographs. After

**Table 1.** Adhesion Grading Scale.<sup>15</sup>

0	No adhesions
1	Minimal adhesions, mainly between the omentum and the bowel graft
2	Moderate adhesions, that is, between the bowel graft and the omentum or a loop of the small bowel or the abdominal wall
3	Severe and extensive adhesions, that is, between the bowel graft and several loops of small bowel and the abdominal wall, including abscess formation

macroscopic assessment, the grafted or sutured regions were excised with at least a 2-cm rim of surrounding tissue. The complications were examined according to Clavien-Dindo classification.<sup>16</sup>

### Histology and Immunohistochemistry

The histological examination was performed by Laboratory of Cell Biology and Histology, University of Antwerp, Belgium. All specimens were fixed and embedded in paraffin wax. Deparaffinized sections (5  $\mu\text{m}$ ) were used for staining with hematoxylin and eosin (H&E) to visualize tissue architecture and cell infiltration. Particular attention was paid to the slides of the transition zone between the amnion graft and normal colon wall. A semiquantitative score from 0 to 3 for inflammation and from 0 to 2 for vascularization were used. Inflammation of the implant region was scored by counting lymphocytes in 10 fields of 0.25  $\text{mm}^2$  in 3 observer-randomized H&E slides (semiquantitative score: 0 = <5% cells/field; 1 = 5%-25%; 2 = 25%-50%; 3 = >50%; 200 $\times$  magnification). A similar score was applied for vascularization (0 = 0 vessels/ $\text{mm}^2$ ; 1 = 1-3 vessels/ $\text{mm}^2$ ; 2 = >3 vessels/ $\text{mm}^2$ ; 200 $\times$  magnification). AM thickness was measured in micrometers to assess degradation and inflammation. Immunohistochemical staining was performed using anti-smooth muscle actin ( $\alpha$ -actin; A2547; Sigma-Aldrich, Bornem, Belgium) to confirm the presence of smooth muscle fibres. After deparaffinization and a heat-induced antigen retrieval, the slides were incubated with the primary antibody of the corresponding antigen. The antibody was visualized using a streptavidin-biotin-peroxidase method, followed by diaminobenzidine chromogen solution. Digital images of H&E and  $\alpha$ -actin were used for the evaluation of smooth muscle content within the reconstructed colon wall.

### Statistical Analysis

Qualitative variables were presented as frequencies and percentages. Quantitative variables were expressed as means  $\pm$  SDs. Data from different groups were compared using the Mann-Whitney *U* test and 2-way ANOVA,

respectively. Statistical significance was assumed at  $P < .05$ . Statistical analysis was performed using the GraphPadPrism 6.0 statistical software package.

## Results

### Clinical Course and Functional Results

Two animals (11%) died in the treated group (A)—1 animal as a result of postoperative sepsis and 1 during the anesthesia—and were hence excluded from analysis. No animal from the control groups C1 and C2 died. No other severe complications higher than grade II (Clavien-Dindo classification) were observed.

### Macroscopic Examination

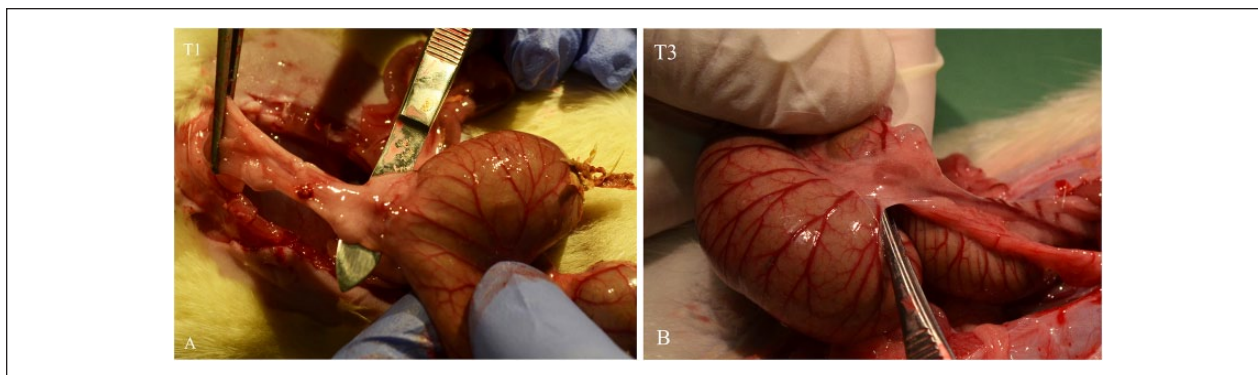
**At 7 Days.** No signs of severe inflammation were found in the abdominal cavity during resurgery. Strong adhesions of the HAM graft to the small bowel and abdominal wall that withstood tractions were detected in most treated cases. In 2 of 5 cases, there was a blister and edema formation (Figure 1). The average adhesion formation differed significantly among groups. Specifically, a higher adhesion score with a larger coverage area was found in the amnion group A ( $1.8 \pm 0.45$ ) versus the C1 group ( $0.5 \pm 0.7$ ;  $P < .05$ ; Figure 2). However, similar adhesion scores were detected for C1 and C2. The AM appeared as a thick edematous graft infiltrated by inflammation signs. The inflammation was less present in the control groups (C1 and C2).

**At 21 Days.** The HAM was still well defined, albeit with reduced inflammation. The edema and adhesions were less conspicuous, and the amnion graft appeared as a thinner reddish layer on the colon wall. The adhesion score was higher in the amnion group A ( $1.8 \pm 0.84$ ) when compared with the C1 group ( $1 \pm 0$ ;  $P = .178$ ) but did not reach the significance level (Figure 2).

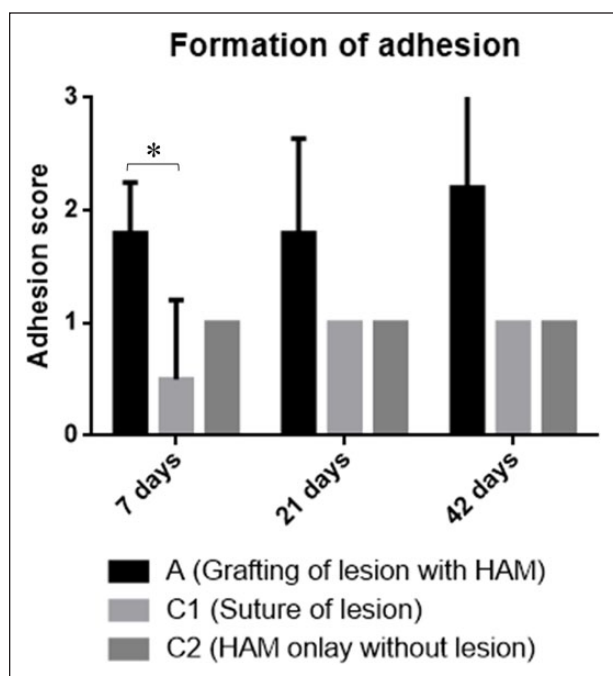
**At 42 Days.** The HAM was hardly recognizable and in some cases not detectable. The control group C2 was characterized by the absence of the HAM, which had been completely degraded. The signs of inflammation reduced; however, they were still stronger in the amnion group A. The adhesions increased in the amnion group when compared with the C1 and C2 groups ( $P = .052$ ; Figures 1 and 2).

### Microscopic Examination

**At 7 Days.** The xenotransplanted HAM graft covered the colon wall and maintained its architecture in the treated group. The lesions could be recognized as the regions that



**Figure 1.** Macroscopic evaluation of adhesion score in the amnion treated group A (Table 1). A. Strong adhesions to small bowel and abdominal wall with edema and inflammation of the lesion site were detected at time point T1 (7 days). B. Moderate adhesions without signs of inflammation were detected at time point T3 (42 days).



**Figure 2.** Adhesion formation in the 3 groups: Group A, grafting of lesion with amnion; group C1, closure of colon lesion with suture; group C2, amnion onlay without lesion. Time point 1: 7 days; time point 2: 21 days; and time point 3: 42 days. Means  $\pm$  standard errors are plotted. Overall comparisons with 2-way ANOVA test ( $P < .05$ ) for time points 7, 21, and 42 days. A higher adhesion score was found in the amnion group A versus the C1 group ( $P < .05$  for time point 1) and slight increase of adhesion in the amnion group over time.

Abbreviation: HAM, human amniotic membrane.

lacked smooth muscle cells. Strong inflammation with abundant increased numbers of lymphocytes and blood vessels was observed in the amnion layers and between the amnion and the submucosa of colon, which resulted

in an enlarged amnion. A lower but still strong inflammation was found in the control groups C1 and C2 as well (Figures 3 and 4).

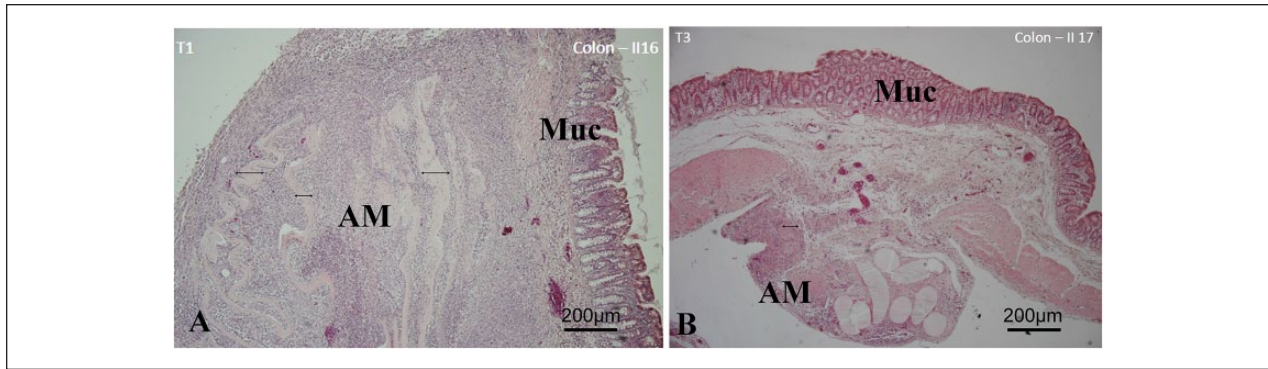
**At 21 Days.** The amnion, including its different layers, was mostly still clearly recognizable. Its thickness reduced (Figure 5), and inflammation was significantly diminished ( $P < .05$ ; Figures 3 and 4). No change in vascularization was observed compared with time point 1 (data not shown). Connective tissue bundles and scattered smooth muscle cells appeared in the area of the lesion (Figure 3). In the control group C1, signs of inflammation (presence of lymphocytes) had mostly disappeared, and there were also no clear signs of regeneration of smooth cells in the lesion region.

**At 42 Days.** It became more difficult to verify the presence of the amnion in the treated group; the different layers of the amnion could no longer be distinguished, and the amnion, which was significantly reduced in thickness, formed a thinner layer on the colon wall (Figures 3 and 5). In the control group without lesion (C2), the amnion was completely degraded and could no longer be detected. Inflammation was markedly reduced in the amnion and in the zone between the amnion and the colon wall but was still significantly higher compared with the control group C1 ( $P < .05$ ; Figures 3 and 4). Despite the presence of scattered smooth muscle cells and bundles, it was difficult to measure if there was a clear regeneration of smooth muscle compared with the control group C1 (Figure 3).

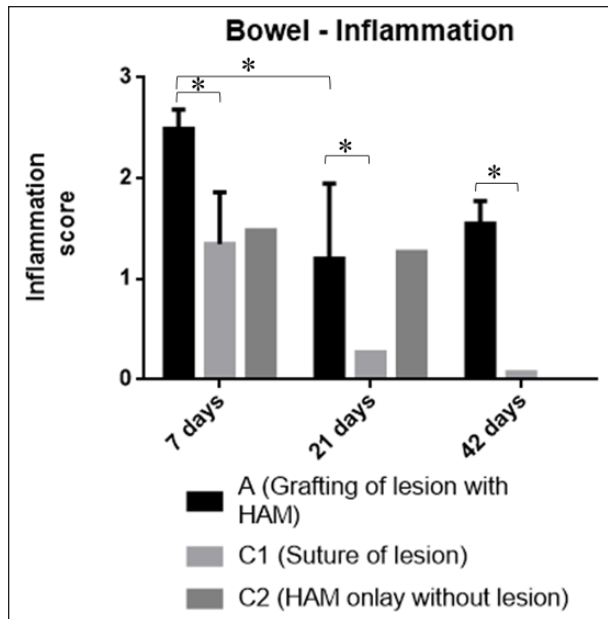
### Rejection

No macroscopic signs of rejection were found in the kidney and spleen specimens. However, 4 out of 6 animals in the treated group showed an affected kidney at time point 2. The changes were subtle, with slightly enlarged tubuli



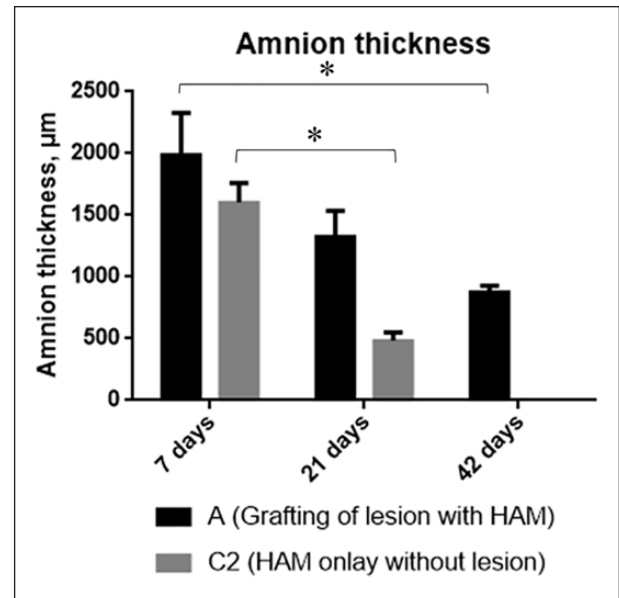


**Figure 3.** Histological evaluation of AM degradation and inflammation in the treated group over time (A: 7 and B: 42 days after grafting). Arrows show the AM thickness. Significant AM degradation and reduction of inflammation over time can be seen. Decreased inflammatory cells and increased vascularization in the periamniotic transition zone were detected. Scale bar 200  $\mu$ m. Abbreviations: AM, amniotic membrane; Muc, colon mucosa.



**Figure 4.** Reduction of inflammation over time, semiquantitative analyses of inflammatory cells: means  $\pm$  standard errors are plotted. T1: 7 days; T2: 21 days; T3: 42 days. Group A, grafting of lesion with amnion; group C1, closure of colon lesion with suture; group C2, amnion onlay without lesion. Semiquantitative score: 0 = <5% cells/field; 1 = 5%-25%; 2 = 25%-50%; 3 = >50%; 200 $\times$  magnification. A significant decrease of inflammation in the treated group T2 versus T1 was detected ( $P < .05$ ). However, the presence of inflammatory cells was significantly higher in the treated versus control/lesion group at every time point ( $P < .05$ ). Abbreviation: HAM, human amniotic membrane.

and urinary space. The glomeruli appeared more dense. No presence of immune cells or other signs of transplant rejection were found. At time point 3, only the kidneys of 2 out of 5 animals were still slightly affected, whereas no



**Figure 5.** Thickness of the multilayer amniotic membrane in micrometers: means  $\pm$  standard errors are plotted. T1: 7 days; T2: 21 days; T3: 42 days. Group A, amnion graft repair of colon lesion; group C2, amnion onlay without lesion. A significant reduction of human amniotic membrane (HAM) thickness was seen over time T3 versus T1 in both groups ( $P < .05$ ).

such changes were detected in the controls without amnion. Taken together, a transient, subtle transplant glomerulitis is suggested in the rat HAM grafts.

### Discussion

The HAM has several characteristics that make it ideal for use as biological material in surgical interventions. Since their introduction in the 1990s as a promising

cryopreservation method with interesting long-term storage possibilities,<sup>17</sup> HAMs have been broadly applied in a wide range of clinical studies as corneal replacement, skin graft donor-side dressing in burn patients, and graft for oropharyngeal fistula.<sup>17-21</sup> Currently, there is a growing interest in extending the application possibilities of HAMs because of their wide availability, low costs, and biological properties.

The aim of our study was to assess the mechanical, inflammatory and allergenic properties of HAMs in a xenograft rat model in the hope that successful xenotransplantation might pave the way for clinical applications according to the IDEAL stages of surgical innovation.<sup>12</sup> Here, we present a preclinical stage 0 animal study according to the IDEAL-D system.<sup>14</sup> However, the present study demonstrated that the use of AMs for repair of bowel lesions in a xenograft model is not beneficial compared with standard therapy. Moreover, the incidence of adhesion formation (89% in the treated group vs 33% in the control group,  $P < .05$ ) and inflammatory reactions was significantly higher in the amnion group. However, HAM proper seems to have no antigenic effect, as also corroborated by the results of a human allogeneic experiment showing no acute transplant rejection of subcutaneously implanted HAMs.<sup>22</sup> Although we did not find any clinical signs of rejection in our xenolog experiment, we did observe extended adhesions and an inflammatory reaction in the amnion. Similar increased number of inflammatory cells were reported by other groups.<sup>18,23,24</sup> Additionally, most animals of the amnion group presented a subtle acellular transplant glomerulitis. The changes can be classified as borderline mild acute rejection according to the Banff classification.<sup>25</sup> However, because of the limited 6-week follow-up period, it was not possible to assess whether chronic glomerulitis with interstitial fibrosis and tubular atrophy would occur.

The formation of adhesions is a frequently observed process following surgical interventions in the peritoneal cavity.<sup>11,26</sup> It is now well accepted that the inflammatory system plays an important role in the regulation of both the coagulation and fibrinolytic systems, which are crucial for the genesis of adhesions.<sup>26</sup> Several strategies for the prevention of adhesions have been proposed, including inhibition of inflammation, prevention of fibrin formation, promotion of fibrinolysis, and antiangiogenesis and tissue engineering.<sup>6,27-29</sup> We assumed that the HAM's anti-inflammatory properties would reduce the formation of adhesions. For this purpose, we decided to use the epithelial side of the HAM facing the abdominal cavity.<sup>24</sup> However, our results showed that the adhesions could not be prevented and were even increased in the amnion group, probably as a result of increased inflammation by insufficient bowel sealing with amnion graft and rejection in the xenograft model.

Adequate bowel perfusion is a key determinant of successful healing.<sup>30</sup> The nutrition of amnion is ensured by diffusion. Additionally, HAMs contain growth factors that promote epithelial wound healing. Although we expected faster regeneration of the "neo-colon" wall in the amnion group because of growth factors, our results were not significant, and it was not possible to compare the regeneration in a standardized way because of the small size of the grafts and an overlap with the normal colon wall.

Only a few groups have applied HAMs in reconstructive bowel surgery to date. Schmidt et al<sup>24</sup> used a patch of monolayer HAM to repair an 8-mm duodenal lesion in 42 Wistar rats. The animals were followed up for 28 days, and adhesions were detected in all animals. Two animals presented with obstruction, and 1 animal died from peritonitis. The HAMs degraded after 14 days, and the regeneration of mucosa and smooth muscle increased after time. Epithelialization of the HAMs started 3 days after surgery and was completed between 3 and 4 weeks. The authors concluded that HAMs can be used as a temporary seal to reestablish the duodenal wall structure. The colon bacteria digest the amnion tissue and cause the degradation of the patch. Several studies could show the degradation of the extracellular matrix components by bacterial-derived metalloproteases in colon.<sup>31,32</sup> If applied as a graft, a fast degradation of amnion is reported between 14 and 90 days, depending on the grafted tissue and number of layers.<sup>18,24</sup> In the case of monolayer amnion, the degradation is almost completed 2 weeks postimplantation. Transformation of multilayer HAMs and tissue reorganization and degradation were observed between 21 and 42 days in our experiment. In our study, additionally, fibrin glue was used to seal the lesions in all groups. No adverse effects of fibrin glue on adhesion formation were reported previously.<sup>33</sup>

Using a peritonitis rat model, a Turkish group covered a cecum anastomosis with a 10-mm amnion wrap. The AL rate amounted to up to 25% in the standard anastomosis group versus 0% in the amnion group after a 7-day follow-up period. Neoangiogenesis, fibroblast activity, and collagen deposition were significantly higher in the groups with AMs ( $P < .05$ ).<sup>23,34</sup> Unlike in our model, the authors reported a high dehiscence rate of 40% to 50% in the control group with standard anastomosis; this is probably the result of a different experimental model used.<sup>23</sup> In our study, no signs of dehiscence were detected in the C1 group with suture of a small bowel wall defect. However, the increased initial inflammation and adhesions in the amnion group appear to be signs of insufficient bowel sealing with amnion graft. Additionally, 1 case of postoperative peritonitis and sepsis was detected in the HAM group. Another study used light-activated HAM wrap to strengthen colonic anastomosis and reduce perianastomotic adhesions in Sprague-Dawley rats.<sup>35</sup> A

1-cm wide strip of HAM (stromal side down) was wrapped around the anastomotic line and sealed to the serosal surface by illumination with 532 nm light. The illumination provided photochemical bonding and better sealing of HAM with less AL and less inflammatory reaction, unlike in our experiments.

There were limitations of our study because of small grafts ( $10 \times 10 \text{ mm}^2$ ), short follow-up, and small sample size. Another limitation was the absent blinding of the investigators. However, the investigator bias is not apparent because the study reports negative results. Another reason to choose the same surgeons for the implantation and explantation of HAM was their expertise to find the difficult region of interest during the postmortem examination. Because an innovative proof-of-principle study is presented, a small number of cases were used. HAM regeneration in large constructs and anastomosis protection with improved sealing techniques in a high-risk situation (eg, peritonitis model) need further evaluation.

In conclusion, we suggest that HAMs alone are not a suitable barrier to prevent adhesions and inflammation and, therefore, are not beneficial to a standard suture for the reconstruction of the bowel wall in the presented xenograft model.

### Acknowledgments

The authors highly appreciate the outstanding support throughout the experiments from Albert Ramon from International Tissue Engineering Research Association, Jin Yang from Affiliated Hospital of Chengdu University, China, and Peter Ponsaerts, Laboratory of Experimental Hematology, University of Antwerp, Belgium. Special thanks for the laboratory support go to Annette Wiggen-Kremer, Institute of Tissue Engineering and Regenerative Medicine (ITERM), Lukas Hospital Neuss, Germany.

### Author Contributions

Study concept and design: Dimitri Barski, Holger Gerullis, Thorsten Ecke, Isabel Pintelon, Jean-Pierre Timmermans, Gabriella Varga, Mihaly Boros and Thomas Otto

Acquisition of data: Dimitri Barski, Holger Gerullis and Isabel Pintelon

Analysis and interpretation: Dimitri Barski, Holger Gerullis, Thorsten Ecke, Isabel Pintelon and Thomas Otto

Study supervision: Jean-Pierre Timmermans, Gabriella Varga, Mihaly Boros and Thomas Otto

### Declaration of Conflicting Interests

The author(s) declared no potential conflicts of interest with respect to the research, authorship, and/or publication of this article.

### Funding

The author(s) received no financial support for the research, authorship, and/or publication of this article.

### References

1. Contant CM, Hop WC, van't Sant HP, et al. Mechanical bowel preparation for elective colorectal surgery: a multi-centre randomised trial. *Lancet*. 2007;370:2112-2117.
2. Marinello FG, Baguena G, Lucas E, et al. Anastomotic leaks after colon cancer resections: does the individual surgeon matter? *Colorectal Dis*. 2016;18:624-625.
3. Wang C, Li X, Meng X, Zhou J, Qin F, Hou L. Prevention of experimental postoperative peritoneal adhesions through the intraperitoneal administration of tanshinone IIA. *Planta Med*. 2014;80:969-973.
4. Beck DE, Opelka FG, Bailey HR, Rauh SM, Pashos CL. Incidence of small-bowel obstruction and adhesiolysis after open colorectal and general surgery. *Dis Colon Rectum*. 1999;42:241-248.
5. Ellis H, Moran BJ, Thompson JN, et al. Adhesion-related hospital readmissions after abdominal and pelvic surgery: a retrospective cohort study. *Lancet*. 1999;353:1476-1480.
6. Kawanishi K, Yamato M, Sakiyama R, Okano T, Nitta K. Peritoneal cell sheets composed of mesothelial cells and fibroblasts prevent intra-abdominal adhesion formation in a rat model. *J Tissue Eng Regen Med*. 2016;10:855-866.
7. Cueto J, Barrientos T, Rodriguez E, et al. Further experimental studies on a biodegradable adhesive for protection of colorectal anastomosis. *Arch Med Res*. 2014;45:331-336.
8. Hoare T, Yeo Y, Bellas E, Bruggeman JP, Kohane DS. Prevention of peritoneal adhesions using polymeric rheological blends. *Acta Biomater*. 2014;10:1187-1193.
9. Zhou B, Ren J, Ding C, et al. Protection of colonic anastomosis with platelet-rich plasma gel in the open abdomen. *Injury*. 2014;45:864-868.
10. Wenger FA, Szucsik E, Hoinoiu BF, Cimpean AM, Ionac M, Raica M. Circular anastomotic experimental fibrin sealant protection in deep colorectal anastomosis in pigs in a randomized 9-day survival study. *Int J Colorectal Dis*. 2015;30:1029-1039.
11. Brochhausen C, Schmitt VH, Rajab TK, et al. Intraperitoneal adhesions—an ongoing challenge between biomedical engineering and the life sciences. *J Biomed Mater Res A*. 2011;98:143-156.
12. McCulloch P, Altman DG, Campbell WB, et al. No surgical innovation without evaluation: the IDEAL recommendations. *Lancet*. 2009;374:1105-1112.
13. Otto T, Klosterhalfen B, Klinge U, Boros M, Ysebaert D, Williams K. Implants in urogynecology. *Biomed Res Int*. 2015;2015:354342.
14. Sedrakyan A, Campbell B, Merino JG, Kuntz R, Hirst A, McCulloch P. IDEAL-D: a rational framework for evaluating and regulating the use of medical devices. *BMJ*. 2016;353:i2372.
15. van der Ham AC, Kort WJ, Weijma IM, van den Ingh HF, Jeekel H. Effect of antibiotics in fibrin sealant on healing colonic anastomoses in the rat. *Br J Surg*. 1992;79:525-528.
16. Clavien PA, Barkun J, de Oliveira ML, et al. The Clavien-Dindo classification of surgical complications: five-year experience. *Ann Surg*. 2009;250:187-196.

17. Kim JC, Tseng SC. Transplantation of preserved human amniotic membrane for surface reconstruction in severely damaged rabbit corneas. *Cornea*. 1995;14:473-484.
18. Kesting MR, Loeffelbein DJ, Steinstraesser L, et al. Cryopreserved human amniotic membrane for soft tissue repair in rats. *Ann Plast Surg*. 2008;60:684-691.
19. Kesting MR, Wolff KD, Mücke T, et al. A bioartificial surgical patch from multilayered human amniotic membrane: in vivo investigations in a rat model. *J Biomed Mater Res B Appl Biomater*. 2009;90:930-938.
20. Loeffelbein DJ, Rohleder NH, Eddicks M, et al. Evaluation of human amniotic membrane as a wound dressing for split-thickness skin-graft donor sites. *Biomed Res Int*. 2014;2014:572183.
21. Salehi SH, As'adi K, Mousavi SJ, Shoar S. Evaluation of amniotic membrane effectiveness in skin graft donor site dressing in burn patients. *Indian J Surg*. 2015;77(suppl 2):427-431.
22. Akle CA, Adinolfi M, Welsh KI, Leibowitz S, McColl I. Immunogenicity of human amniotic epithelial cells after transplantation into volunteers. *Lancet*. 1981;2:1003-1005.
23. Uludag M, Citgez B, Ozkaya O, et al. Effects of amniotic membrane on the healing of primary colonic anastomoses in the cecal ligation and puncture model of secondary peritonitis in rats. *Int J Colorectal Dis*. 2009;24:559-567.
24. Schmidt LR, Cardoso EJ, Schmidt RR, et al. The use of amniotic membrane in the repair of duodenal wounds in Wistar rats. *Acta Cir Bras*. 2010;25:18-23.
25. Bhowmik DM, Dinda AK, Mahanta P, Agarwal SK. The evolution of the Banff classification schema for diagnosing renal allograft rejection and its implications for clinicians. *Indian J Nephrol*. 2010;20:2-8.
26. Hellebrekers BW, Kooistra T. Pathogenesis of postoperative adhesion formation. *Br J Surg*. 2011;98:1503-1516.
27. Avsar FM, Sahin M, Aksoy F, et al. Effects of diphenhydramine HCl and methylprednisolone in the prevention of abdominal adhesions. *Am J Surg*. 2001;181:512-515.
28. Topal E, Ozturk E, Sen G, Yerci O, Yilmazlar T. A comparison of three fibrinolytic agents in prevention of intra-abdominal adhesions. *Acta Chir Belg*. 2010;110:71-75.
29. Chaturvedi AA, Lomme RM, Hendriks T, van Goor H. Ultrapure alginate gel reduces adhesion reformation after adhesiolysis. *Int J Colorectal Dis*. 2014;29:1411-1416.
30. Urbanavičius L, Pattyn P, de Putte DV, Venskutonis D. How to assess intestinal viability during surgery: a review of techniques. *World J Gastrointest Surg*. 2011;3(5):59-69.
31. Pasternak B, Matthiessen P, Jansson K, Andersson M, Aspenberg P. Elevated intraperitoneal matrix metalloproteinases-8 and -9 in patients who develop anastomotic leakage after rectal cancer surgery: a pilot study. *Colorectal Dis*. 2010;12(7, online):e93-e98.
32. Shogan BD, Belogortseva N, Luong PM, et al. Collagen degradation and MMP9 activation by *Enterococcus faecalis* contribute to intestinal anastomotic leak. *Sci Transl Med*. 2015;7:286ra268.
33. Kanellos I, Christoforidis E, Kanellos D, Pramateftakis MG, Sakkas L, Betsis D. The healing of colon anastomosis covered with fibrin glue after early postoperative intraperitoneal chemotherapy. *Tech Coloproctol*. 2006;10:115-120.
34. Uludag M, Ozdilli K, Citgez B, et al. Covering the colon anastomoses with amniotic membrane prevents the negative effects of early intraperitoneal 5-FU administration on anastomotic healing. *Int J Colorectal Dis*. 2010;25:223-232.
35. Senthil-Kumar P, Ni T, Randolph MA, Velmahos GC, Kochevar IE, Redmond RW. A light-activated amnion wrap strengthens colonic anastomosis and reduces peri-anastomotic adhesions. *Lasers Surg Med*. 2016;48:530-537.