

University of Groningen

Active Specific Immunotherapy in the Management of Adenocarcinoma of the Pancreas

YACYSHYN, BR; LONGENECKER, BM; BIERMANN, WA; MCCLURE, D; Poppema, Sibrandes; BOWENYACYSHYN, MB

Published in:
Canadian journal of gastroenterology

DOI:
[10.1155/1995/491787](https://doi.org/10.1155/1995/491787)

IMPORTANT NOTE: You are advised to consult the publisher's version (publisher's PDF) if you wish to cite from it. Please check the document version below.

Document Version
Publisher's PDF, also known as Version of record

Publication date:
1995

[Link to publication in University of Groningen/UMCG research database](#)

Citation for published version (APA):

YACYSHYN, B. R., LONGENECKER, B. M., BIERMANN, W. A., MCCLURE, D., Poppema, S., & BOWENYACYSHYN, M. B. (1995). Active Specific Immunotherapy in the Management of Adenocarcinoma of the Pancreas. *Canadian journal of gastroenterology*, 9(4), 213-216. DOI: 10.1155/1995/491787

Copyright

Other than for strictly personal use, it is not permitted to download or to forward/distribute the text or part of it without the consent of the author(s) and/or copyright holder(s), unless the work is under an open content license (like Creative Commons).

Take-down policy

If you believe that this document breaches copyright please contact us providing details, and we will remove access to the work immediately and investigate your claim.

Downloaded from the University of Groningen/UMCG research database (Pure): <http://www.rug.nl/research/portal>. For technical reasons the number of authors shown on this cover page is limited to 10 maximum.

Active specific immunotherapy in the management of adenocarcinoma of the pancreas

BR YACYSHYN MD FRCPC, BM LONGENECKER PHD, WA BIERMANN MD, D McCLURE MD,
S POPPEMA PHD FRCPC, MB BOWEN-YACYSHYN PHD

BR YACYSHYN, BM LONGENECKER, WA BIERMANN, D McCLURE, S POPPEMA, MB BOWEN-YACYSHYN. Active specific immunotherapy in the management of adenocarcinoma of the pancreas. *Can J Gastroenterol* 1995;9(4):213-216.

Active specific immunotherapy for pancreatic adenocarcinoma and subsequent immunohistochemical analysis of tumour tissue have not been previously reported. To date, the therapy of pancreatic adenocarcinoma has been largely unsuccessful. A patient treated with a therapeutic 'cancer vaccine' and the immunological impact on the primary tumour of this potential new therapy are described. To the authors' knowledge, this is both the first patient to be treated with active specific immunotherapy for pancreatic adenocarcinoma and the first to be studied immunologically by flow cytometry and immunohistochemistry with an apparent positive clinical impact.

Key Words: Active specific immunotherapy, Immunohistochemistry, Pancreatic adenocarcinoma

Immunothérapie active spécifique pour le traitement de l'adénocarcinome du pancréas

RÉSUMÉ : L'immunothérapie active spécifique dans les cas d'adénocarcinome du pancréas et l'analyse immunohistochimique subséquente du tissu tumoral n'ont encore jamais fait l'objet d'un rapport. À ce jour, le traitement de l'adénocarcinome pancréatique a souvent échoué. Un patient traité par un vaccin anticancer thérapeutique et l'impact immunologique sur la tumeur primitive de ce nouveau traitement expérimental sont décrits ici. À la connaissance de l'auteur, il s'agit du premier patient à être traité par immunothérapie active spécifique pour un adénocarcinome du pancréas et le premier à être étudié sur le plan immunologique par flux-cytométrie et épreuves d'immunohistochimie avec des résultats cliniques apparemment favorables.

Department of Medicine, Division of Gastroenterology, and Department of Immunology, University of Alberta; Department of Pathology, Cross Cancer Institute; and Biomira Inc, Edmonton, Alberta; Jefferson Medical College, Thomas Jefferson University, Philadelphia, Pennsylvania, USA

Correspondence and reprints: Dr Bruce Yacyshyn, Department of Medicine, Division of Gastroenterology, 2E3.11 WMHSC, University of Alberta, Edmonton, Alberta T6G 2R7. Telephone 403-492-5957, Fax 403-492-3340, e-mail bruce@nshade.uah.ualberta.ca

Received for publication October 5, 1994. Accepted November 24, 1994

IN 1984, SPRINGER DESCRIBED THE presence of blood group precursor antigens Tn and T on carcinomas (1). Further studies have shown that Tn, the monosaccharide precursor of TF, and its sialylated form STn are expressed on 90% of adenocarcinomas, and the amount of these epitopes expressed appears to be correlated with carcinoma aggressiveness (1). Many adenocarcinomas have been found to secrete immunosuppressive mucins which have these normally cryptic carbohydrates exposed. Fung et al (2) have synthesized these carbohydrate haptens and conjugated them to the protein carrier keyhole limpet hemacyanin (KLH). These glycoconjugates have been shown to be protective against lethal tumour challenge in mice (2). In 1989, human clinical trials began using TF-KLH and STn-KLH (a synthetic glycoconjugate consisting of STn – a sialylated blood group precursor – attached chemically to a KLH protein backbone) with the hope of circumventing the immunosuppression in adenocarcinoma patients and creating a humoral and cellular antitumour response (2).

We report the first case of active specific immunotherapy (ASI) used as primary therapy for adenocarcinoma of the pancreas. This form of treatment has been previously shown to have

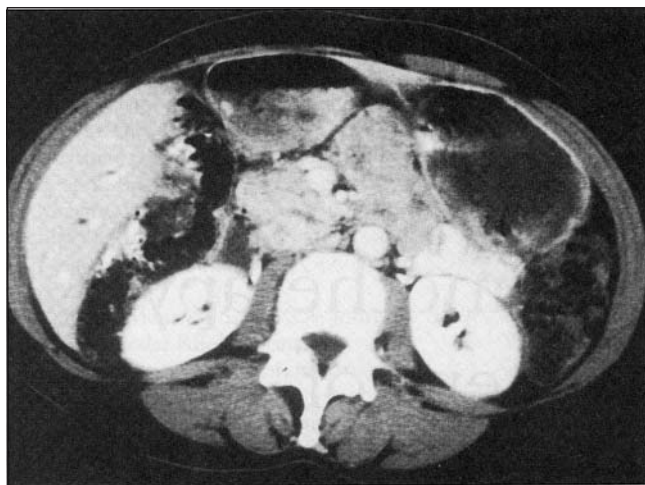


Figure 1) Computed tomography scan of abdomen. A 4x4 cm mass is identified involving the uncinate process with associated pancreatic, common bile duct and intrahepatic duct dilation

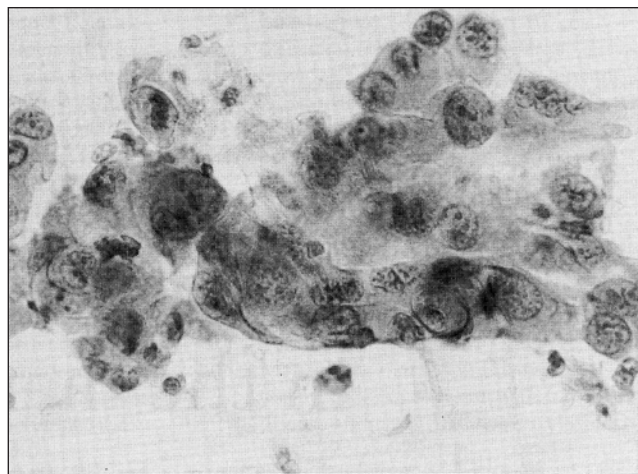


Figure 2) Cytopathology before active specific immunotherapy. Adenocarcinoma cells are consistent with the patient's clinical presentation and computed tomography scan

benefit in treatment of neoplasms in several animal and human trials. A tumour-associated carbohydrate antigen sialyl-Tn (D_{Ac}Neu α 2-6GalNAc) was synthesized and attached chemically to a KLH protein carrier. This antigen was emulsified in DETOX adjuvant (RIBI Immunochem Research, Inc, Montana) and injected subcutaneously into a patient after cyclophosphamide pretreatment. After two courses of ASI, a Whipple's procedure was performed and the primary tumour obtained surgically was analyzed by immunohistochemistry. The patient survived 14 months from diagnosis and suffered no adverse reactions from the ASI injections, unlike from chemotherapy or radiation.

CASE PRESENTATION

A 52-year-old woman was seen July 13, 1992, on referral from her family physician after three weeks of progressive jaundice. Symptoms compatible with obstructive jaundice were elicited on history with dark urine and pale stool colour. A computed tomography (CT) scan was performed (Figure 1) which revealed a 4x4 cm mass involving the uncinate process of the pancreas with associated pancreatic, common bile duct and intrahepatic duct dilation. On July 28, the patient underwent a Roux-en-Y choledochojejunostomy with needle aspiration of the uncinate process of the pancreas. Cytopathology confirmed adenocarci-

noma of the pancreas (Figure 2). The patient consented to participate in a study of ASI as the sole therapy for her malignancy. The patient underwent standard protocol pretreatment for ASI with cyclophosphamide (300 mg/m²) followed by two courses of ASI with STn-KLH (100 μ g) plus adjuvant DETOX B (RIBI) given October 2 and 16, 1992. Peripheral blood was obtained for peripheral blood mononuclear cell immunophenotyping by flow cytometry before ASI and three months after the last injection. No adverse events were noted by the patient.

Subsequently, in an effort to seek more definitive therapy, the patient sought an opinion from a second surgeon who consented to excise the primary tumour. CT scan and angiography performed preoperatively October 21, 1992 confirmed no progression in tumour size with persistence of a 4x4 cm mass in the pancreatic head, and no metastatic disease was found. A Whipple's procedure was performed November 2, 1992 and the patient underwent an unremarkable postoperative recovery. Frozen sectioning of the pancreatic head confirmed the gross findings of an ill-defined, 2.5 cm average diameter, extremely firm indurated head of pancreas and no involved lymph nodes. Fixed tumour tissue was studied in detail by immunohistochemistry to identify the nature of the immune response initiated in the pancreas. Unfortunately, a liver metastasis was

identified in February 1993 and fine needle aspiration biopsy confirmed metastatic pancreatic adenocarcinoma. The patient submitted to additional palliative care and was mobile up to one week before death in late September 1993 from metastatic pancreatic adenocarcinoma and inferior vena cava obstruction, 14 months from initial diagnosis.

FLOW CYTOMETRY AND IMMUNOHISTOCHEMISTRY

Flow cytometry performed before and after the patient's course of ASI vaccines revealed a stable CD4:CD8 ratio greater than 1, increased expression of CD25 on the CD4 subset after immunization (indicating interleukin-2 receptor was present on these 'activated cells'), and stable B and NK populations. Immunohistochemistry of fixed and imbedded tumour was performed using the Dakopatts ABC technique (Dako, California). A marked paucity of tumour cells was noted in all sections stained, with evidence of chronic inflammation. An inflammatory infiltrate was seen in several sections, and consisted mainly of CD8+ T lymphocytes (Figure 3). Additional staining confirmed an activated lymphocyte infiltrate by CD45RB (a lymphocyte CD45 transitional isoform, not shown) and MT1 (CD43) on activated lymphocytes (Figure 4) (3).

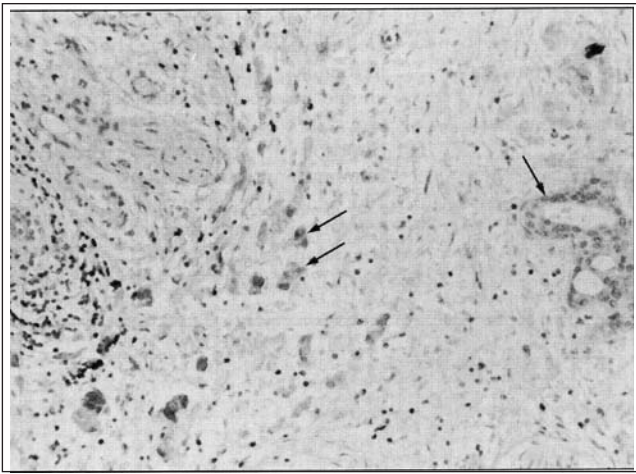


Figure 3) CD8+ T lymphocytes in a postactive specific immunotherapy pancreatic adenocarcinoma. CD8+ T lymphocytes are seen (dark cells) in an area of scarring, with a lack of adenocarcinoma cells. The area sectioned was consistent with the primary tumour. The arrows indicate foci of adenocarcinoma

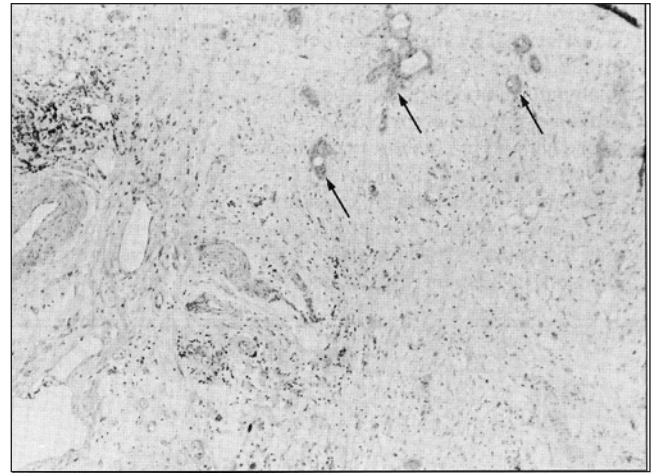


Figure 4) MT1 (CD43) activated lymphocytes in a postactive specific immunotherapy pancreatic adenocarcinoma. Activated CD43+ T lymphocytes are identified (dark staining cells) in an area with a lack of adenocarcinoma. The area stained is the same as in Figure 3. The arrows indicate foci of adenocarcinoma

DISCUSSION

ASI attempts to involve the recognition of specific T cells challenged by synthetic glycoconjugates vaccinated into a recipient afflicted by cancer to incite an immune response against that tumour. Of phase II trials underway for a number of malignancies, we present one such patient who, to date, is the first patient to survive statistically beyond that expected by nonoperative management alone (4). Survivals of 11 to 21 months for patients with pancreatic cancer treated with radiotherapy and chemotherapy have been described (5). No information about the immune status of long term survivors regarding the peripheral blood and tumour lymphocyte composition that may allow long term survival has been identified (5). Our patient had peripheral blood lymphocyte analysis both before and after therapy, as well as immunohistochemistry of the resected tumour removed at Whipple's procedure.

In this paper we describe prolonged survival in a patient treated with two courses of ASI and investigated with immunohistochemistry of the primary malignancy. The recent use of ASI in carcinoma of the breast and ovary has created interest in oncology due to the minimal side effects with such treatment (6,7). Our patient entered this phase II study treatment protocol with informed consent, and received pretreatment with cyclophosphamide.

Cyclophosphamide pretreatment is thought to augment an immune response in humans by depleting suppressor T lymphocytes (8-10). Two courses of vaccination treatment with STn-KLH were administered subcutaneously with no adverse local or systemic reactions (6). Immunohistochemistry of the primary tumour after surgical resection revealed a fibrotic, scarred tumour with a paucity of malignant cells. Although dense, peritumour fibrosis has been described in cancer of the pancreas, this contrasts with the pretreatment aspiration needle biopsy of the same area where cytology revealed abundant tumour cells. The cellular infiltrate found on immunohistochemistry revealed positive lymphocyte staining with CD8, CD43 and CD45RO. This supports an immune response in the area of the primary neoplasm which may not be attributable to ASI.

ASI has been considered and administered in a number of animal and human trials. The benefit of generating T cell-dependent immunoglobulin G responses to carbohydrate antigens conjugated to protein carriers has been tested in other malignancies (7). Pilot studies of ASI in ovarian cancer and metastatic breast cancer have been promising (6,7). Moreover, toxicity in these studies has been largely minimal, consisting of local granulo-

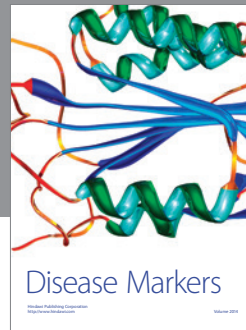

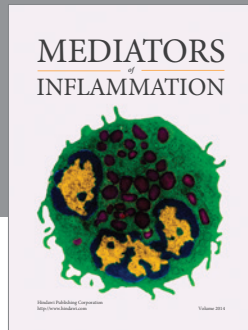
mata at vaccine sites. To date, these studies have shown some surprising clinical outcomes in patients even with preexisting metastatic disease. ASI plus chemotherapy, or as in our case with surgical resection, may improve or prolong disease-free survival. Such therapy will be further assessed in adenocarcinoma of the pancreas, a disease where there has been obvious lack of clinical progress.

ACKNOWLEDGEMENTS: Thanks to Wendy McEachern for her expert secretarial assistance in the preparation of this manuscript. Thanks as well to Dr GK Nguyen for photographs of cytopathology.

REFERENCES

1. Springer GF. T and Tn, general carcinoma autoantigens. *Science* 1984;224:1198-206.
2. Fung PYS, Madej M, Koganty RR, Longenecker BM. Active specific immunotherapy of a murine mammary adenocarcinoma using a synthetic tumor-associated glycoconjugate. *Cancer Res* 1990;50:4308-14.
3. Poppema S, Visser L. Preparation and application of monoclonal antibodies: B-cell panel and paraffin tissue reactive panel. *Biotest Bull* 1987;3:131-9.
4. MacLean GD, Bowen-Yacyshyn MB, Samuel J, et al. Active immunization of human ovarian cancer patients against a common carcinoma (Thomsen-Friedenreich) determinant using a synthetic carbohydrate antigen. *J Immunother* 1992;11:292-305.

5. Gastrointestinal Tumour Study Group. Treatment of locally unresectable carcinoma of the pancreas: Comparison of combined-modality therapy (chemotherapy plus radiotherapy) to chemotherapy alone. *J Natl Cancer Inst* 1988;80:751.
 6. MacLean GD, Reddish MA, Koganty R, et al. Immunization of breast cancer patients using a synthetic sialyl-Tn glycoconjugate plus DETOX adjuvant. *Cancer Immunol Immunother* 1993;36:215-22.
 7. Berd D, Mastrangelo MJ, Engstrom PF, et al. Augmentation of the human immune response by cyclophosphamide. *Cancer Res* 1982;42:4862-6.
 8. Berd D, Maguire HC, Mastrangelo MJ. Potentiation of human cell-mediated and humoral immunity by low-dose cyclophosphamide. *Cancer Res* 1984;44:5439-43.
 9. Mastrangelo MJ, Berd D, Maguire H. Cell-mediated immunity. The immunoaugmenting effects of cancer chemotherapeutic agents. *Semin Oncol* 1986;13:186-94.
 10. Swanson MA, Schwartz RS. Immunosuppressive therapy. The relation between clinical response and immunologic competence. *N Engl J Med* 1967;277:163-70.
-
-



Hindawi
Submit your manuscripts at
<http://www.hindawi.com>

