

Case Report

Hyperprolinemia as a clue in the diagnosis of a patient with psychiatric manifestations

Marco Duarte^{a,*}, Joana Afonso^a, Ana Moreira^b, Diana Antunes^c, Cristina Ferreira^d, Hildeberto Correia^d, Margarida Marques^a, Sílvia Sequeira^e

^a Child and Adolescent Psychiatric Department, Hospital de Dona Estefânia, Lisbon, Portugal

^b Neuropaediatric Department, Hospital de Dona Estefânia, Lisbon, Portugal

^c Genetic Department, Hospital de Dona Estefânia, Lisbon, Portugal

^d Unit of Cytogenetics of the Human Genetic Department, INSA, Lisbon, Portugal

^e Metabolic Unit, Hospital de Dona Estefânia, Lisbon, Portugal

Received 25 October 2016; received in revised form 18 January 2017; accepted 19 January 2017

Abstract

Lately, microdeletions of the 22q region, responsible for DiGeorge syndrome or velocardiofacial syndrome, have been increasingly related to neuropsychiatric disorders including schizophrenia and bipolar disorder. These manifestations seem to be related to certain genes located in the hemideleted region such as the proline dehydrogenase (*PRODH*) and the catechol-o-methyltransferase (*COMT*) genes.

We describe a teenager who started his adolescent psychiatric care presenting cognitive impairment, irritable mood and aggressive behaviour with schizophrenia-like symptoms that scored 153 in the Positive and Negative Symptoms Scale (PANSS) assessment.

Worsening of symptoms when the patient was treated with valproic acid, and plasma aminoacids showing an increase in alanine and proline, suggested a mitochondrial involvement of the proline metabolic pathway. Mild dysmorphic features also suggested a possible 22q11 deletion syndrome that was confirmed. A mutation for Hyperprolinemia type I was also detected.

Knowledge of the correct diagnosis was crucial for an adequate treatment.

© 2017 The Japanese Society of Child Neurology. Published by Elsevier B.V. All rights reserved.

Keywords: Hyperprolinemia type I; *PRODH* gene; 22q11 deletion syndrome; Schizophrenia; Valproic acid

1. Introduction

Patients with a 22q11.2 deletion syndrome, usually present developmental delay, poor growth, distinctive facial features, microcephaly, cleft palate, heart abnormalities and immunological problems. Recent studies

show that some are likely to develop psychotic symptoms, depression, anxiety and bipolar disorder [1]. The loss of one copy of susceptible genes located in the 22q11del region such as the *COMT* gene, an intracellular postsynaptic enzyme that modulates dopamine clearance, and *PRODH* gene may ultimately lead to a psychiatric dysfunction [2].

The *PRODH* gene encodes proline dehydrogenase or proline oxidase (POX), a mitochondrial enzyme involved in proline catabolic pathway converting proline to

* Corresponding author at: Centro Hospitalar Psiquiátrico de Lisboa, Avenida do Brasil 53, 1700-063 Lisboa, Portugal. Fax: +351 217 952 989.

E-mail address: marcoduarte@chpl.min-saude.pt (M. Duarte).

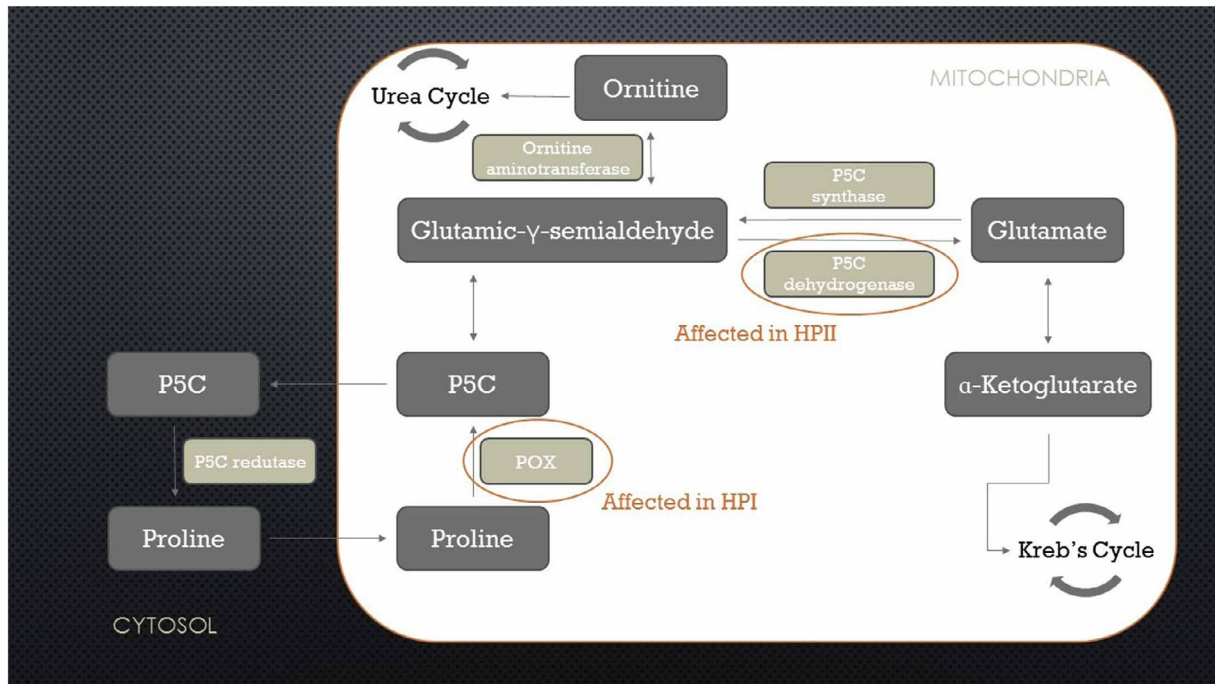


Fig. 1. Proline metabolism. P5C: pyrroline-5-carboxylate; POX: proline oxidase; HPI: Hyperprolinemia type I; HPII: Hyperprolinemia type II.

delta-1-pyrroline-5-carboxylate (Δ^1 -P5C) [3]. Proline plays a role in urea cycle where it can be endogenously synthesized (Fig. 1). Several disorders in proline metabolism have been identified, such as deficiency of POX or Hyperprolinemia type I (HPI) and deficiency of the activity of Δ^1 -P5C dehydrogenase or Hyperprolinemia type II (HPII). Both rare diseases, inherited as autosomal recessive disorders and characterized biochemically by high proline levels [4–6]. Although the neuropsychiatric phenotype has been primarily associated with HPII [6,7], a growing number of patients with these features, in particular schizophrenia, have been documented for HPI [8].

2. Case report

We describe a 17-year-old male patient, whose relevant family history includes only a maternal great-uncle with schizophrenia.

He presented mild hypotonia in infancy and later on difficulties in motor coordination (but walking independently at the age of 14 months) and language delay (first words at 3 years and joining words at the age of 4) requiring physiotherapy and speech therapy with subsequent learning difficulties. Karyotype and fragile-X studies were normal. As he grew older, he started showing some manifestations in daily life suggesting obsessive behaviour leading sometimes to bullying and refusal to go to school.

When he had his first observation in the Psychiatric Outpatient Unit at the age of 15, he presented compulsive and obsessive symptoms, anxiety, a mixed depressive/irritable mood and aggressive behaviour. The speech was impaired, with some difficulty in articulating

words. Paranoid and reference delusions were suspected. Wechsler Intelligence Scale for Children (WISC) III was performed and scored medium low in the Verbal IQ and very low in the Non-Verbal IQ.

The mood, irritability, anxiety and disrupted behaviour improved with the prescription of quetiapine but over the following months he revealed a disorganized behaviour with paranoid, reference and grandiose delusions.

When admitted to the Inpatient Unit at the age of 17, he appeared to be restless, tense, with an irritable mood and auditory hallucinations. The Positive and Negative Symptoms Scale (PANSS) performed at admission scored 153: 33 for Positive Symptoms, 45 for Negative Symptoms and 75 for General Symptoms Subscale. Routine blood tests, including calcemia and investigations for psychosis were within normal range. Brain MRI revealed only non-specific findings and EEG was unremarkable.

Olanzapine caused partial improvement of his psychotic symptoms and aggressive behaviour but he maintained an irritable mood. Valproic acid was then added but during the increase to therapeutic values, he deteriorated (aggressive behaviour, long periods of isolation and drowsiness) leading to the discontinuation of this drug. As liver function tests showed normal values, a valproate intoxication was excluded and a mitochondrial disorder was suspected.

Treatment with lithium and olanzapine led to improvement in behaviour and psychotic symptoms.

Further investigations revealed normal lactic acid and ammonia values, elevation in proline (511 and 403 $\mu\text{M/L}$; RV:51–271 $\mu\text{M/L}$) and alanine (623.7 and 594 $\mu\text{M/L}$; RV < 400 $\mu\text{M/L}$) levels. Urinary organic

acids showed no pyroline-5-carboxylate (P5C), leading to the diagnosis of a possible HPI.

Considering slightly dysmorphic features (low set ears and hirsute eyebrows) despite normal growth and no major abnormalities and the knowledge that HPI is located on chromosome 22q11, a multiplex ligation-dependent probe amplification (MLPA) test was performed using the probemix P250-B1 (MRC-Holland, Amsterdam, The Netherlands) that confirmed a heterozygous 22q11 deletion from gene *CLTCL1* to gene *LZTR1*. Another probemix, P324-A2 (MRC-Holland, Amsterdam, The Netherlands) that contains three probes for *PRODH* gene confirmed this deletion spanning from 17,298,536 to 19,779,435 bp (hg18), comprising both the *PRODH* and the *COMT* genes. Cardiac evaluation was normal.

The high proline levels are not usually observed in patients with 22q11 deletions and as HPI and HPII are autosomal recessive disorders, molecular studies for the investigation of the *PRODH* gene, were performed and revealed a p.L289M (c.1865T > A) mutation in heterozygosity.

3. Discussion

Most patients with the 22q11 deletion have congenital abnormalities which is not the case of this patient that manifests solely mild dysmorphic features. As described previously our patient had hypotonia, psychomotor and language delay but unlike most of the described patients could speak fluently and attended normal schooling [9]. Also, our case had lower values of proline when compared with a similar case described (930–1000 $\mu\text{mol/L}$ [9] and didn't had any cardiac abnormalities.

Nevertheless the cognitive and psychological impairment he presents are not so well known. Most genes in chromosome loci 22q11 are expressed in the brain and hypothetically related to executive functions [2,3].

A metabolic disorder was suspected due to the presence of the cognitive delay associated with psychotic features as well as deterioration after the initiation of valproic acid as normal liver function excluded toxicity. Valproate metabolization occurs primarily in the liver mitochondria, and thus should be avoided in cases of mitochondrial disorders, as it may stress vital pathways that intensify the genetic damage [10].

The knowledge that HPI is caused by mutations in the chromosome 22q11 led to further investigations that confirmed the 22q11 deletion. Nevertheless, considering the moderate elevation of proline and that HPI is autosomal recessive, these findings could not be explained solely by the detected deletion. Complementary investigations showed heterozygous p.L289M (c.1865T > A) mutation in the *PRODH* gene already described in schizophrenic patients and that may lead to a decrease of a 30% activity of POX [11,12].

The 22q11 deletion that includes the *PRODH* gene region and a heterozygous mutation on the *PRODH* gene on the other allele may somehow result in a composed heterozygosity of this gene and have a moderate effect on POX activity [3,12].

This decreased activity could influence the proline/glutamate levels related with apoptosis in selected neurons [2,3]. It is possible that the overall phenotype of cognitive and psychiatric anomalies could be a consequence of several genes affected in this locus deletion or their interaction.

This case is also clear evidence that knowing the aetiology of psychiatric manifestations is important in the management of patients preventing use of deleterious drugs or creating new therapeutic approaches. It also shows that it may be difficult to diagnose chromosomal abnormalities in patients with no clear malformations and mild dysmorphic features as the pleiotropism of the gene/deletion could probably lead to different phenotypes.

References

- [1] Schneider M, Debbané M, Bassett AS, Chow EW, Fung WL, van den Bree M, et al. Psychiatric disorders from childhood to adulthood in 22q11.2 deletion syndrome: results from the international consortium on brain and behavior in 22q11.2 deletion syndrome. *Am J Psychiatry* 2014;171:627–39.
- [2] Karayiorgou M, Simon TJ, Gogos JA. 22q11.2 microdeletions: linking DNA structural variation to brain dysfunction and schizophrenia. *Nat Rev Neurosci* 2010;11:402–16.
- [3] Di Rosa G, Nicotera AG, Lenzo P, Spano M, Tortorella G. Long-term neuropsychiatric follow-up in hyperprolinemia type I. *Psychiatr Genet* 2014;24:172–5.
- [4] Schafer IA, Scriver CR, Efron ML. Familial hyperprolinemia, cerebral dysfunction and renal anomalies occurring in a family with hereditary nephropathy and deafness. *N Engl J Med* 1962;267:51–60.
- [5] Mitsubuchi H, Nakamura K, Matsumoto S, Endo F. Inborn errors of proline metabolism. *J Nutr* 2008;138:2016S–20S.
- [6] Phang JM, Hu CA, Valle D. Disorders of proline and hydroxyproline metabolism. New York: McGraw Hill; 2001.
- [7] van de Ven S, Gardeitchik T, Kouwenberg D, Kluijtmans L, Wevers R, Morava E. Long-term clinical outcome, therapy and mild mitochondrial dysfunction in hyperprolinemia. *J Inher Metab Dis* 2014;37:383–90.
- [8] Guilmatre A, Legallic S, Steel G, Willis A, Di Rosa G, Goldenberg A, et al. Type I hyperprolinemia: genotype/phenotype correlations. *Hum Mutat* 2010;31:961–5.
- [9] Afenjar A, Moutard ML, Doummar D, Guët A, Rabier D, Vermersch AI, et al. Early neurological phenotype in 4 children with biallelic *PRODH* mutations. *Brain Dev* 2007;29:547–52.
- [10] Silva MF, Aires CC, Luis PB, Ruiten JP, IJlst L, Duran M, et al. Valproic acid metabolism and its effects on mitochondrial fatty acid oxidation: a review. *J Inher Metab Dis* 2008;31:205–16.
- [11] Bender HU, Almashanu S, Steel G, Hu CA, Lin WW, Willis A, et al. Functional consequences of *PRODH* missense mutations. *Am J Hum Genet* 2005;76:409–20.
- [12] Jacquet H, Raux G, Thibaut F, Hecketsweiler B, Houy E, Demilly C, et al. *PRODH* mutations and hyperprolinemia in a subset of schizophrenic patients. *Hum Mol Genet* 2002;11:2243–9.