

University of Groningen

## Ectopic hidradenitis suppurativa on the dorsal foot of a road maker

Rondags, Angelique; Diercks, G.F.H.; Werker, Paul; Jonkman, Marcel F.; Horvath, Barbara

*Published in:*  
JAAD case reports

*DOI:*  
[10.1016/j.jdc.2017.06.002](https://doi.org/10.1016/j.jdc.2017.06.002)

**IMPORTANT NOTE: You are advised to consult the publisher's version (publisher's PDF) if you wish to cite from it. Please check the document version below.**

*Document Version*  
Publisher's PDF, also known as Version of record

*Publication date:*  
2017

[Link to publication in University of Groningen/UMCG research database](#)

*Citation for published version (APA):*

Rondags, A., Diercks, G. F., Werker, P. M. N., Jonkman, M. F., & Horváth, B. (2017). Ectopic hidradenitis suppurativa on the dorsal foot of a road maker. *JAAD case reports*, 3(5), 429-431. DOI: 10.1016/j.jdc.2017.06.002

**Copyright**

Other than for strictly personal use, it is not permitted to download or to forward/distribute the text or part of it without the consent of the author(s) and/or copyright holder(s), unless the work is under an open content license (like Creative Commons).

**Take-down policy**

If you believe that this document breaches copyright please contact us providing details, and we will remove access to the work immediately and investigate your claim.

*Downloaded from the University of Groningen/UMCG research database (Pure): <http://www.rug.nl/research/portal>. For technical reasons the number of authors shown on this cover page is limited to 10 maximum.*

# Ectopic hidradenitis suppurativa on the dorsal foot of a road maker



Angelique Rondags, MD,<sup>a</sup> Gilles F. Diercks, MD, PhD,<sup>b</sup> Paul M. N. Werker, MD, PhD,<sup>c</sup>  
Marcel F. Jonkman, MD, PhD,<sup>a</sup> and Barbara Horváth, MD, PhD<sup>a</sup>  
Groningen, The Netherlands

**Key words:** acne inversa; ectopic hidradenitis suppurativa; hidradenitis suppurativa; mechanical stress; mechanical friction.

## INTRODUCTION

Hidradenitis suppurativa (HS) is a chronic, often debilitating, inflammatory skin condition that affects approximately 1% of the general population.<sup>1,2</sup> HS is characterized by painful subcutaneous nodules or abscesses, and in a later stage tunnels (sinus tracts) are formed in the dermis and subcutaneous fat and eventually scarring can occur.<sup>1</sup> These lesions are mainly seen in the inverse body areas, like the axillary, inguinal, anogenital, and inframammary regions.<sup>1</sup> All these locations contain apocrine glands, are humid, and have a predisposition to mechanical stress.<sup>3,4</sup>

The diagnosis of HS, based on the modified Dessau definition, is in general a clinical one; it is based on the patient's history, chronicity, and recurrence of typical lesions in prototypical body areas, with the possibility of typical HS lesions in atypical (ectopic) locations.<sup>2</sup> Therapy of HS is still challenging; a combination therapy that involves both anti-inflammatory medicine and surgery is often needed to induce (partial) remission.<sup>2</sup>

Here, we report the case of a male patient who had an HS lesion on his dorsal foot possibly caused by a predisposition of HS in combination with mechanical pressure and friction from occupational-related factors.

## CASE PRESENTATION

A 28-year-old man presented with a bleeding 1.5-cm ulcer with raised edges and laterally a dark

### Abbreviation used:

HS: hidradenitis suppurativa

subcutaneous, blanchable area of 1 × 2 cm on his right dorsal foot (Fig 1, A). His foot was erythematous, swollen, and painful. Skin symptoms started 5 months earlier as a purple, slowly progressive papule. There were no systemic symptoms, such as fever or malaise. The patient had a normal body weight and was a smoker. He had a history of pilonidal sinus (excision 3 years ago), acne conglobata, and HS. A derroofing of an HS lesion in the axilla took place previously with good treatment outcome.

At the moment of first presentation of the ulcer, the HS was active in femoral and perianal regions (Hurley stage I) and was being treated with clindamycin, 300 mg twice daily, and rifampicin, 300 mg twice daily. Detailed occupational history found that the patient is a road maker, who paves streets with bricks or stones, and mostly worked in a right-legged kneeling position causing bending of his right working shoe. He had just received a new, rigid pair of tight-fitting work shoes.

Differential diagnosis included atypical (ectopic) presentation of HS, infectious wound, traumatic ulcer, hypertensive leg ulcer (Martorell ulcer), infected hematoma, pyoderma gangrenosum in association with PASH (pyoderma gangrenosum, acne and suppurative hidradenitis) syndrome, and

From the Departments of Dermatology,<sup>a</sup> Pathology,<sup>b</sup> and Plastic Surgery,<sup>c</sup> University Medical Center Groningen.

Funding sources: None.

Conflicts of interest: Dr Jonkman reports personal fees from Roche and grants from Amicus outside the submitted work; Dr Horváth reports personal fees from ABBVIE, grants from Novartis, and grants and personal fees from Janssen outside the submitted work. The other authors have no conflicts of interest to declare.

Ethical considerations: the subject in this case report gave his written permission to use his personal information and images.

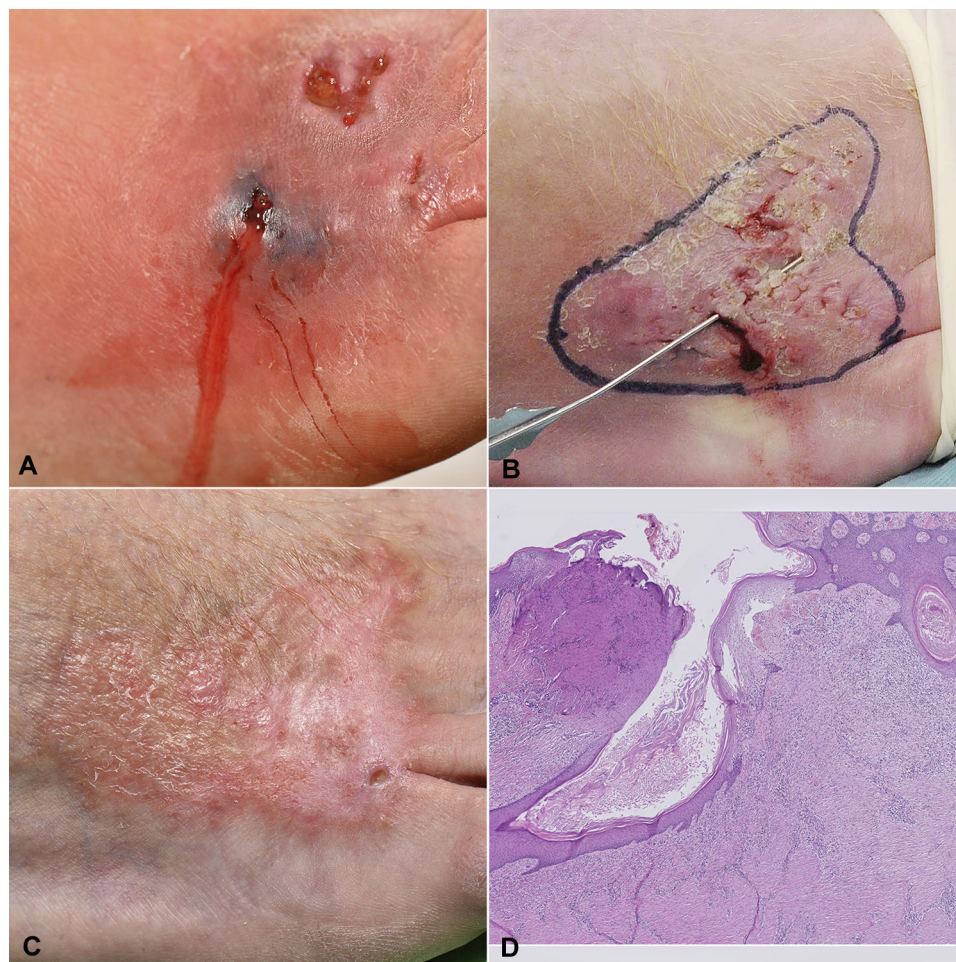
Correspondence to: Angelique Rondags, MD, Department of Dermatology, University Medical Center Groningen, PO Box 30.001, 9700 RB Groningen, The Netherlands. E-mail: [a.l.v.rondags@umcg.nl](mailto:a.l.v.rondags@umcg.nl).

JAAD Case Reports 2017;3:429-31.

2352-5126

© 2017 by the American Academy of Dermatology, Inc. Published by Elsevier, Inc. This is an open access article under the CC BY-NC-ND license (<http://creativecommons.org/licenses/by-nc-nd/4.0/>).

<http://dx.doi.org/10.1016/j.jdc.2017.06.002>



**Fig 1.** Ectopic hidradenitis suppurativa on the dorsal foot of a road maker. **A**, Initial clinical presentation of wound on dorsal right foot. **B**, Four months after initial presentation, during surgery. Probe shows interconnected sinus tracts between lesions. **C**, Eight months postsurgery. Nearly complete wound healing. **D**, Histologic findings. Sinus tract formation in a background with extensive fibrosis and a chronic infiltrate. Right upper corner follicular occlusion. (**D**, Hematoxylin-eosin stain.)

actinomycosis. It was decided to stop the rifampicin and change the clindamycin scheme from 300 mg twice daily to 300 mg 3 times a day, and ciprofloxacin was started additionally at 500 mg twice daily.

Despite antibiotic treatment, symptoms progressed. Small ulcers with brown/yellow discharge and sinus tract formation developed into a dark erythematous plaque (Fig 1, B). Further diagnostic tests found a normal blood glucose level (ruling out underlying diabetes) and a negative wound bacterial culture by swab of the exudate. Based on the clinical presentation, diagnostics, and anamneses, the diagnosis of ectopic HS was made.

Because of the progression, surgical excision (a skin tissue–sparing excision with electrosurgical peeling procedure) was performed with split-thickness skin graft. Successful secondary wound healing had occurred after initial split-thickness skin

graft failure (Fig 1, C). Furthermore, the patient was strongly advised to wear comfortable nonfrictional shoes and clothing in general. Histologic investigation of the removed tissue found follicular plugging, sinus tract formation, and dermal fibrosis with chronic active inflammation, consistent with a diagnosis of HS (Fig 1, D).

## DISCUSSION

The pathogenesis of HS remains to be elucidated. Most likely, HS originates in the follicular pilosebaceous unit and the surrounding tissue. The first event is the infundibular hyperkeratinization with subsequent dilatation of the follicle that leads to rupture, causing inflammation in the skin. The role of mechanical stress is proposed as a (contributive) factor in the pathogenesis of HS, by stimulating interfollicular hyperplasia; however, evidence is still limited.<sup>4</sup>

Several case reports support the contribution of mechanical stress in the development of HS. For instance, an HS-like lesion on the stump was diagnosed in a case report of a limb amputee after wearing a leg prosthesis. In this report, the leg prosthesis increased mechanical friction at the stump area and created a warm, moist, occlusive environment, similar to the predisposed intertriginous areas in classic presentations of HS.<sup>5</sup>

Another report presented the case of an obese woman with a history of classic HS, in which HS was significantly reduced after weight loss. The HS particularly improved around the waistband, which was mentioned to be an area highly exposed to friction.<sup>6</sup> Recently, another similar case was described of an obese woman with classic HS, who had HS lesions exactly where her bra strap was exerting mechanical pressure and friction on the skin.<sup>4</sup>

The theory of mechanical stress as a causative factor in HS development in subjects with aberrant hair follicles is also hypothesized in the case of a young child known with a nevus comedonicus in the groin area, with histologically dilated hair follicles, who had HS there just after she became mobile.<sup>7</sup>

Furthermore, the role of mechanical stress as a trigger factor for HS is supported by a histologic study showing that the basement membrane zone of the sebafollicular junction at the follicle pilosebaceous unit in perilesional HS skin seems to be aberrant, indicating fragility of the hair follicle.<sup>8</sup> One can speculate that increased epidermal mechanical stress more easily leads to follicle rupture. However, there is contradictory evidence regarding the integrity of the basement membrane zone.<sup>9</sup>

We report a case of ectopic HS in a predisposed male subject that is consistent with the theory of mechanical stress as a contributive cause of HS. We propose that the HS lesion on the patient's dorsal foot resulted from repetitive pressure and mechanical friction on the skin because of his too-tight-fitting working shoe, which created a warm and humid environment as well.

The authors thank Piet Toonder for providing the clinical presentation images.

#### REFERENCES

1. Jemec GB. Hidradenitis suppurativa. *N Engl J Med*. 2012;366(2):158-164.
2. Zouboulis CC, Desai N, Emtestam L, et al. European S1 guideline for the treatment of hidradenitis suppurativa/acne inversa. *J Eur Acad Dermatol Venereol*. 2015;29(4):619-644.
3. Revuz J. Hidradenitis suppurativa. *J Eur Acad Dermatol Venereol*. 2009;23(9):985-998.
4. Boer J, Nazary M, Riis PT. The role of mechanical stress in hidradenitis suppurativa. *Dermatol Clin*. 2016;34(1):37-43.
5. de Winter K, van der Zee HH, Prens EP. Is mechanical stress an important pathogenic factor in hidradenitis suppurativa? *Exp Dermatol* 2012;21(3):176-177.
6. Boer J. Resolution of hidradenitis suppurativa after weight loss by dietary measures, especially on frictional locations. *J Eur Acad Dermatol Venereol*. 2016;30(5):895-896.
7. Dufour DN, Bryld LE, Jemec GB. Hidradenitis suppurativa complicating naevus comedonicus: the possible influence of mechanical stress on the development of hidradenitis suppurativa. *Dermatology*. 2010;220(4):323-325.
8. Danby FW, Jemec GBE, Marsch WC, Von Laffert M. Preliminary findings suggest hidradenitis suppurativa may be due to defective follicular support. *Br J Dermatol*. 2013;168(5):1034-1039.
9. Blok JL, Janse IC, Horváth B, Jonkman MF. Increased expression of integrin  $\alpha 6 \beta 4$  in the basement membrane zone lining the sebaceous glands in hidradenitis suppurativa. *Acta Derm Venereol*. 2015;95(8):994-996.