

University of Groningen

**Diagnostic yield and accuracy of CT angiography, MR angiography, and digital subtraction angiography for detection of macrovascular causes of intracerebral haemorrhage**

van Asch, Charlotte J. J.; Velthuis, Birgitta K.; Rinkel, Gabrel J. E.; Algra, Ale; de Kort, Gerard A. P.; Witkamp, Theo D.; de Ridder, Johanna C. M.; van Nieuwenhuizen, Koen M.; de Leeuw, Frank-Erik; Schonewille, Wouter J.

*Published in:*  
British Medical Journal

*DOI:*  
[10.1136/bmj.h5762](https://doi.org/10.1136/bmj.h5762)

**IMPORTANT NOTE: You are advised to consult the publisher's version (publisher's PDF) if you wish to cite from it. Please check the document version below.**

*Document Version*  
Publisher's PDF, also known as Version of record

*Publication date:*  
2015

[Link to publication in University of Groningen/UMCG research database](#)

*Citation for published version (APA):*

van Asch, C. J. J., Velthuis, B. K., Rinkel, G. J. E., Algra, A., de Kort, G. A. P., Witkamp, T. D., ... DIAGRAM Investigators (2015). Diagnostic yield and accuracy of CT angiography, MR angiography, and digital subtraction angiography for detection of macrovascular causes of intracerebral haemorrhage: prospective, multicentre cohort study. *British Medical Journal*, 351, [5762]. DOI: 10.1136/bmj.h5762

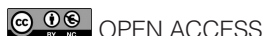**Copyright**

Other than for strictly personal use, it is not permitted to download or to forward/distribute the text or part of it without the consent of the author(s) and/or copyright holder(s), unless the work is under an open content license (like Creative Commons).

**Take-down policy**

If you believe that this document breaches copyright please contact us providing details, and we will remove access to the work immediately and investigate your claim.

*Downloaded from the University of Groningen/UMCG research database (Pure): <http://www.rug.nl/research/portal>. For technical reasons the number of authors shown on this cover page is limited to 10 maximum.*



# Diagnostic yield and accuracy of CT angiography, MR angiography, and digital subtraction angiography for detection of macrovascular causes of intracerebral haemorrhage: prospective, multicentre cohort study

Charlotte J J van Asch,<sup>1</sup> Birgitta K Velthuis,<sup>2</sup> Gabriël J E Rinkel,<sup>1</sup> Ale Algra,<sup>1,3</sup> Gérard A P de Kort,<sup>2</sup> Theo D Witkamp,<sup>2</sup> Johanna C M de Ridder,<sup>1</sup> Koen M van Nieuwenhuizen,<sup>1</sup> Frank-Erik de Leeuw,<sup>4</sup> Wouter J Schonewille,<sup>5</sup> Paul L M de Kort,<sup>6</sup> Diederik W Dippel,<sup>7</sup> Theodora W M Raaymakers,<sup>8</sup> Jeannette Hofmeijer,<sup>9</sup> Marieke J H Wermer,<sup>10</sup> Henk Kerkhoff,<sup>11</sup> Korné Jellema,<sup>12</sup> Irene M Bronner,<sup>13</sup> Michel J M Remmers,<sup>14</sup> Henri Paul Bienfait,<sup>15</sup> Ron J G M Witjes,<sup>16</sup> Jacoba P Greving,<sup>3</sup> Catharina J M Klijn<sup>1,4</sup> on behalf of the DIAGRAM Investigators

For numbered affiliations see end of article.

Correspondence to: C J J van Asch c.j.j.vanasch@gmail.com

Additional material is published online only. To view please visit the journal online (<http://dx.doi.org/10.1136/bmj.h5762>)

Cite this as: *BMJ* 2015;351:h5762 doi: 10.1136/bmj.h5762

Accepted: 16 October 2015

## ABSTRACT

### STUDY QUESTION

What are the diagnostic yield and accuracy of early computed tomography (CT) angiography followed by magnetic resonance imaging/angiography (MRI/MRA) and digital subtraction angiography (DSA) in patients with non-traumatic intracerebral haemorrhage?

### METHODS

This prospective diagnostic study enrolled 298 adults (18-70 years) treated in 22 hospitals in the Netherlands over six years. CT angiography was performed within seven days of haemorrhage. If the result was negative, MRI/MRA was performed four to eight weeks later. DSA was performed when the CT angiography or MRI/MRA results were inconclusive or negative. The main outcome was a macrovascular cause, including arteriovenous malformation, aneurysm, dural arteriovenous fistula, and cavernoma. Three blinded neuroradiologists independently evaluated the images for macrovascular causes of haemorrhage. The reference standard was the best available evidence from all findings during one year's follow-up.

### STUDY ANSWER AND LIMITATIONS

A macrovascular cause was identified in 69 patients (23%). 291 patients (98%) underwent CT angiography; 214 with a negative result underwent additional MRI/MRA and 97 with a negative result for both CT angiography and MRI/MRA underwent DSA. Early CT angiography detected 51 macrovascular causes (yield 17%, 95% confidence interval 13% to 22%). CT angiography with MRI/MRA identified two additional macrovascular causes (18%, 14% to 23%) and these modalities combined with DSA another 15 (23%, 18% to 28%). This last extensive strategy failed to detect a cavernoma, which was identified on MRI during follow-up (reference strategy). The positive predictive value of CT angiography was 72% (60% to 82%), of additional MRI/MRA was 35% (14% to 62%), and of additional DSA was 100% (75% to 100%). None of the patients experienced complications with CT angiography or MRI/MRA; 0.6% of patients who underwent DSA experienced permanent sequelae. Not all patients with negative CT angiography and MRI/MRA results underwent DSA. Although the previous probability of finding a macrovascular cause was lower in patients who did not undergo DSA, some small arteriovenous malformations or dural arteriovenous fistulas may have been missed.

### WHAT THIS STUDY ADDS

CT angiography is an appropriate initial investigation to detect macrovascular causes of non-traumatic intracerebral haemorrhage, but accuracy is modest. Additional MRI/MRA may find cavernomas or alternative diagnoses, but DSA is needed to diagnose macrovascular causes undetected by CT angiography or MRI/MRA.

### FUNDING, COMPETING INTERESTS, DATA SHARING

Dutch Heart Foundation and The Netherlands Organisation for Health Research and Development, ZonMw. The authors have no competing interests. Direct requests for additional data to the corresponding author.

### Introduction

Non-traumatic intracerebral haemorrhage accounts for 10-15% of all strokes<sup>1,2</sup> and arises from an underlying macrovascular cause, including arteriovenous malformation, aneurysm, dural arteriovenous fistula, cavernoma, and cerebral venous sinus thrombosis in

## WHAT IS ALREADY KNOWN ON THIS TOPIC

Large variability exists in the diagnostic approach to identify a macrovascular cause in patients with intracerebral haemorrhage (ICH)

The diagnostic accuracy of both CT angiography and MRI/MRA (with digital subtraction angiography (DSA) as the reference standard) seems high, but methodological shortcomings of previous studies may have led to overestimation of diagnostic accuracy

Baseline clinical and radiological characteristics, such as (absence of) hypertension and lobar haematoma location, seem useful to identify patients with a high likelihood of an underlying macrovascular cause

## WHAT THIS STUDY ADDS

Accuracy of CT angiography for the detection of macrovascular causes of ICH is modest, less than previously assumed, and warrants digital subtraction angiography when the result of CT angiography is negative

The additional value of MRI/MRA after negative CT angiography consists mainly of diagnosis of non-macrovascular causes of ICH

Both posterior fossa location in the absence of hypertension and the absence of signs of small vessel disease on non-contrast CT seem to be independent predictors of an underlying macrovascular cause of ICH

1 of 4 to 1 of 7 patients.<sup>3,5</sup> Detection of these macrovascular causes is vital as this may have immediate therapeutic and prognostic implications.<sup>6</sup> The best strategy for identifying a macrovascular cause in patients with non-traumatic intracerebral haemorrhage is unknown. Following the identification of non-traumatic intracerebral haemorrhage on non-contrast computed tomography (CT), immediate angiographic assessment using CT angiography is easy to perform; this procedure is widely available in the Netherlands. The additional diagnostic value of magnetic resonance imaging/magnetic resonance angiography (MRI/MRA) in patients with negative CT angiography results is unknown, as is the additional value of digital subtraction angiography after a negative result for CT angiography or for both CT angiography and MRI/MRA. Baseline patient and non-contrast CT characteristics, such as age less than 45 years and lobar location of the haemorrhage seem useful for identifying those with a high likelihood of an underlying macrovascular cause,<sup>4,7-9</sup> but there are no reliable data on how to select patients for (invasive) angiographic examination.<sup>10-12</sup> Consequently, large variability exists in the diagnostic approach of patients with non-traumatic intracerebral haemorrhage.<sup>13</sup>

We determined the diagnostic yield and accuracy of CT angiography as a single modality performed in the acute phase after non-contrast CT; the yield of CT angiography and MRI/MRA combined; the yield of CT angiography, MRI/MRA, and digital subtraction angiography combined; and the additional accuracy of MRI/MRA and of digital subtraction angiography in patients with a negative CT angiography result. We also investigated the influence of patient and radiological characteristics on the probability of finding an underlying macrovascular cause.

## Methods

### Setting

The prospective, multicentre Diagnostic AngioGRAPHy to find vascular Malformations (DIAGRAM) study included patients with non-traumatic intracerebral haemorrhage aged between 18 and 70 years, treated in 22 participating hospitals in the Netherlands between July 2008 and June 2014. Inclusion criteria were independence before stroke, defined as a modified Rankin score  $<3$ <sup>14</sup> and the ability to undergo investigations. We excluded patients aged more than 45 years with hypertension and non-traumatic intracerebral haemorrhage in the basal ganglia, thalamus, or posterior fossa, because of the low probability of finding an underlying macrovascular cause.<sup>8</sup> Patients were considered to have hypertension when at least one of three criteria was met: documented history of hypertension, use of antihypertensive drugs before the non-traumatic intracerebral haemorrhage, or evidence of left ventricular hypertrophy on an admission electrocardiogram (Sokolow-Lyon criteria).<sup>15</sup> Other exclusion criteria were a diagnosis of a known macrovascular abnormality or tumour established before the haemorrhage occurred, and use of oral anticoagulants with an international normalised ratio of

more than 2.5 at the time of the haemorrhage. For risk assessment, we collected data on clinical condition at admission, smoking, alcohol consumption, drug misuse, patient and family history of cardiovascular disease, diabetes mellitus, use of anticoagulants or platelet inhibitors, use of antihypertensive drugs, and serum lipid levels. We defined high alcohol intake as consumption of four or more units a day.<sup>16</sup> All participants provided written informed consent for inclusion in the study.

### Procedures

Patients underwent CT angiography within seven days of the non-traumatic intracerebral haemorrhage, preferably within 48 hours after non-contrast CT. If the result of CT angiography was negative, MRI/MRA was performed four to eight weeks after the haemorrhage, or earlier if indicated clinically. Patients underwent digital subtraction angiography when the results of CT angiography or MRI/MRA were inconclusive or negative. Digital subtraction angiography was also performed in patients with an arteriovenous malformation or dural arteriovenous fistula found on CT angiography or MRI/MRA, to plan treatment. Digital subtraction angiography was not mandatory if an aneurysm,<sup>17</sup> a cerebral venous sinus thrombosis, or an underlying cavernoma was identified by CT angiography or MRI/MRA.<sup>18</sup> All patients were followed for at least one year by telephone interviews at four weeks, three months, and 12 months after the onset of the haemorrhage, to obtain information on complications of diagnostic procedures, recurrent non-traumatic intracerebral haemorrhage, and findings of angiographic assessment, follow-up imaging, neurosurgical inspection, and pathological examination. For patients with a follow-up of longer than 12 months during the study period as part of clinical practice, we collected data on recurrent non-traumatic intracerebral haemorrhage during this extended follow-up and an underlying cause if found.

### Imaging protocols

CT angiography was performed using a multidetector CT scanner with 16 or more slices. An unenhanced and late enhanced brain CT with 6 mm maximum slice thickness were performed as well as a CT angiography with contrast timing, from level C2 of the cervical spine upwards to the vertex.

MRI/MRA studies were done on 1.5T or 3T magnetic resonance scanners and included a sagittal T1 weighted scan, transversal T1 weighted scan, T2 turbo-spin-echo, and T2 gradient echo scans, 3D multichunk gradient-echo time-of-flight MRI/MRA after a single dose (0.1 mmol/kg) of intravenous gadolinium contrast injection to increase distal vessel and venous opacification, and a transversal 3D T1 weighted contrast enhanced scan.

Digital subtraction angiography consisted of selective catheterisation of the internal and external carotid arteries or vertebral artery of the symptomatic hemisphere. On the asymptomatic side, the common carotid artery was catheterised, with further catheterisation of the internal and external carotid arteries if abnormalities were seen. Participating sites that did not routinely

perform cerebral digital subtraction angiography referred their patients to centres with this expertise.

We collected data on complications of the investigations (type of complication and clinical consequences). We asked all participating centres to adhere to these imaging protocols, with allowance of some local variation.

#### *Radiological assessment*

Two of three experienced neuroradiologists (BKV, GAPdK, or TDW) independently assessed the images of each non-contrast CT, CT angiography, and MRI/MRA, blinded to age, sex, and clinical characteristics of the patients. The neuroradiologists reported on the characteristics of the haematoma, signs of small vessel disease or previous infarcts on non-contrast CT (see supplementary box 1), and presence of microbleeds or old non-traumatic intracerebral haemorrhage on MRI. We defined signs of small vessel disease on non-contrast CT as the presence of white matter lesions, or an infarct in basal ganglia, thalamus, or posterior fossa. A third observer resolved differences between readings.

When additional digital subtraction angiography was performed, a third assessment was done (GAPdK) to review the combination of CT angiography, MRI/MRA, and digital subtraction angiography. The volume of non-traumatic intracerebral haemorrhage was calculated with Analyze software (Biomedical Imaging Resource, Mayo Clinic, Rochester, MN), not including perihematoma oedema.

#### **Statistical analysis**

The main outcome measure was the presence of a macrovascular cause, including arteriovenous malformation, aneurysm, dural arteriovenous fistula, developmental venous anomaly, cerebral venous sinus thrombosis, and cavernoma. The reference standard was the best available evidence from all findings during one year of follow-up.

We calculated the probability of detection of a macrovascular cause in both the presence and the absence of clinical and radiological characteristics, and calculated prevalence ratios with 95% confidence intervals for each characteristic. Diagnostic accuracy measures were calculated twice: first with inconclusive results regarded as a positive outcome and subsequently with inconclusive results regarded as a negative outcome, with 95% confidence intervals. We calculated the diagnostic yield of CT angiography as a single modality, of combined CT angiography and MRI/MRA, and of combined CT angiography, MRI/MRA, and digital subtraction angiography, with 95% confidence intervals. In the calculation of yield of the diagnostic strategy, we included patients in whom no MRI/MRA or digital subtraction angiography was performed because the previous modality had revealed a macrovascular cause.

#### *Sample size calculations*

Based on the literature, we estimated the prevalence of macrovascular abnormalities in the study domain to be 40%.<sup>8</sup> Estimated sensitivity and specificity of CT angiography, MRI/MRA, and digital subtraction angiography for the detection of macrovascular causes were based on

a retrospective pilot study of 451 patients who had been admitted to the University Medical Center Utrecht because of non-traumatic intracerebral haemorrhage between 1990 and 1998. Digital subtraction angiography showed a vascular malformation as cause of the haemorrhage in 30 (27%, 95% confidence interval 19% to 35%) of the 112 patients in whom either a CT angiography or MRI/MRA result was negative. We estimated a sensitivity of 50% and a specificity of 95% for the combination of CT angiography and MRI/MRA for detecting a macrovascular cause, and 95% and 98%, respectively, for digital subtraction angiography. Thus we expected to find a positive predictive value of 87% (95% confidence interval 77% to 94%) for CT angiography and MRI/MRA and 97% (92% to 99%) for digital subtraction angiography. This would mean an increase in positive predictive value of digital subtraction angiography in comparison with CT angiography and MRI/MRA of 10% (1% to 18%). The negative predictive value would increase even more, by 23% (17% to 29%) comparing digital subtraction angiography (97%, 93% to 99%) and the combination of CT angiography and MRI/MRA (74%, 68% to 80%).

We aimed to build a multivariable logistic regression model with a maximum of 12 predictors. Based on the rule of thumb that each predictor would need 10 outcomes,<sup>19</sup> we therefore required 120 patients with an underlying macrovascular cause, a sample size of 300 patients in total.

#### *Multivariable logistic regression*

With a multivariable logistic regression model we assessed which of six predefined determinants (patient characteristics: age as a continuous variable, hypertension, current smoking, heavy drinking, and radiological characteristics: deep, lobar, or posterior fossa location; and signs of small vessel disease on non-contrast CT) discerned best between the presence and absence of a macrovascular cause. Missing values were imputed for alcohol consumption and smoking.<sup>19</sup> We used restricted cubic spline functions and graphs to decide whether age could be analysed as a linear term or needed transformation.<sup>20</sup> We selected variables for the final multivariable regression model with a backward selection procedure (exclusion if  $P > 0.20$ ).

Analyses were performed with IBM SPSS Statistics (version 21.0) and R 2.15.2 software. Results are reported according to the standards for reporting of diagnostic accuracy criteria for diagnostic tests.<sup>21</sup>

#### **Patient involvement**

No patients were involved in setting the research question or the outcome measures, nor were they involved in the design and implementation of the study. There are no plans to involve patients in dissemination of the results.

#### **Results**

Overall, 302 patients were included in the study between July 2008 and July 2014. In three patients, CT angiography was not performed and in one patient MRI was contraindicated (protocol violations); these four patients were excluded from further analyses.

**Table 1 | Causes of intracerebral haemorrhage in participants**

Causes	No (%) of patients (n=298)
Macrovascular:	
Arteriovenous malformation	34 (11)
Dural arteriovenous malformation	13 (4)
Cavernoma	10 (3)
Cerebral venous sinus thrombosis	4 (1)
Aneurysm	7 (2)
Developmental venous anomaly*	1 (0.3)
Subtotal	69 (23)
Other:	
Probable cerebral amyloid angiopathy <sup>27</sup>	18 (6)
Hypertensive vasculopathy†	36 (12)
Neoplasm	3 (1)
Cocaine use	1 (0.3)
Haemorrhagic infarction	2 (0.7)
Unknown‡	169 (57)
Subtotal	229 (77)

\*Partially thrombosed large developmental venous anomaly without evidence of adjacent cavernoma.  
†Intracerebral haemorrhage in basal ganglia, thalamus, or posterior fossa in presence of hypertension.  
‡In 30 of these patients, lobar haemorrhage in the presence of hypertension was observed.

The mean age of the remaining 298 patients was 53.0 years (SD 11.5 years), and the median volume of non-traumatic intracerebral haemorrhage was 11 mL (interquartile range 4-26 mL). According to the reference standard, 69 patients (23%) had an underlying macrovascular cause (table 1). In 68 patients a macrovascular cause was identified by the diagnostic investigations as described in the study protocol. In one patient a cavernoma was not detected by investigations but was identified by repeated MRI during follow-up as part of the reference strategy. The median duration of follow-up of the 298 patients was 450 days (interquartile range 371-1150 days). During this time seven patients had recurrent non-traumatic intracerebral haemorrhage; in none was a macrovascular cause found. Cerebral amyloid angiopathy was diagnosed in one of these patients after the initial clinical investigations and in another patient at the time of recurrent non-traumatic intracerebral haemorrhage, in two patients the presumed cause was hypertensive vasculopathy, and no underlying cause was found in three patients. Central reading of all imaging detected one dural arteriovenous fistula that was not detected during local reading at the participating centre.

Table 2 lists the prevalences and prevalence ratios of a macrovascular cause according to the presence or absence of clinical and radiological characteristics.

### Radiological assessment

Assessment of 291 of the 298 patients (98%) was by CT angiography. In seven patients the quality of the images was insufficient for assessment (figure). CT angiography was stopped in one patient who was unable to keep still; in the other six patients the vessels in the area of the haematoma were not depicted because CT angiography was limited to the circle of Willis. MRI/MRA was successful in 255 patients (86%). Three of 154 digital subtraction angiograms were of insufficient quality for

assessment. The main reason for not performing MRI/MRA was immediate diagnostic and therapeutic investigation after a positive CT angiography result (see supplementary box 2). The main reason for not performing digital subtraction angiography in patients with negative CT angiography results was an alternative diagnosis on MRI/MRA, or the reluctance of the patients or their treating doctors (see supplementary box 2). The median interval between non-contrast CT and CT angiography was 1 day (interquartile range 0-2 days), between CT angiography and MRI/MRA was 46 (32-64) days, and between MRI/MRA and digital subtraction angiography was 33 (3-60) days.

Of the 291 CT angiograms assessed, 59 were scored as positive, 12 as inconclusive, and 220 as negative (figure).

Including inconclusive CT angiograms test results as positive, the positive predictive value was 74% (95% confidence interval 62% to 84%) and the negative predictive value 92% (88% to 95%, table 3). In 51 of 298 patients a macrovascular cause was diagnosed with CT angiography, resulting in a yield of 17% (13% to 22%), in 47 of these patients the CT angiography result was scored as positive and in four it was scored as inconclusive (table 3).

Additional MRI/MRA was performed in 214 of 232 patients with a negative or inconclusive CT angiography test result. Of these 214 MRI/MRAs, six were scored as a positive result, 11 as inconclusive, and 197 as negative. With inconclusive MRI/MRA results included in the positive test results, the positive predictive value was 32% (13% to 57%) and the negative predictive value was 93% (89% to 96%). In 53 of 298 patients a macrovascular cause was detected by combined CT angiography and MRI/MRA, giving a yield of 18% (14% to 23%). In 51 of these patients, MRI/MRA (or CT angiography) was scored as a positive result and in two patients the MRI/MRA was scored as inconclusive.

Digital subtraction angiography was assessed in 103 of 232 patients with negative or inconclusive CT angiography test results, of whom 97 also had negative or inconclusive MRI/MRA test results. The result of digital subtraction angiography was positive in 13 of these 97 patients (13%), resulting in a positive predictive value of 100% (75% to 100%) and a negative predictive value of 100% (96% to 100%) (table 3). The yield of combined CT angiography, MRI/MRA, and digital subtraction angiography was 23% (18% to 28%), with a macrovascular cause detected in 68 of 298 patients. Table 4 lists the accuracy of the combination of CT angiography and MRI/MRA and of the combination of CT angiography, MRI/MRA, and digital subtraction angiography.

In 59 of 230 patients (26%) without a macrovascular cause, an alternative explanation for the non-traumatic intracerebral haemorrhage was found, mainly on MRI (table 1). None of the 63 patients with microbleeds had an underlying macrovascular cause (table 2). In two patients an incidental aneurysm was found that was unrelated to the non-traumatic intracerebral haemorrhage.

### Complications

None of the patients had complications with CT angiography or with MRI/MRA. Complications with digital

**Table 2 | Prevalences and prevalence ratios of a macrovascular cause in 298 patients with intracerebral haemorrhage according to presence or absence of clinical and radiological characteristics. Values are numbers (percentages) unless stated otherwise**

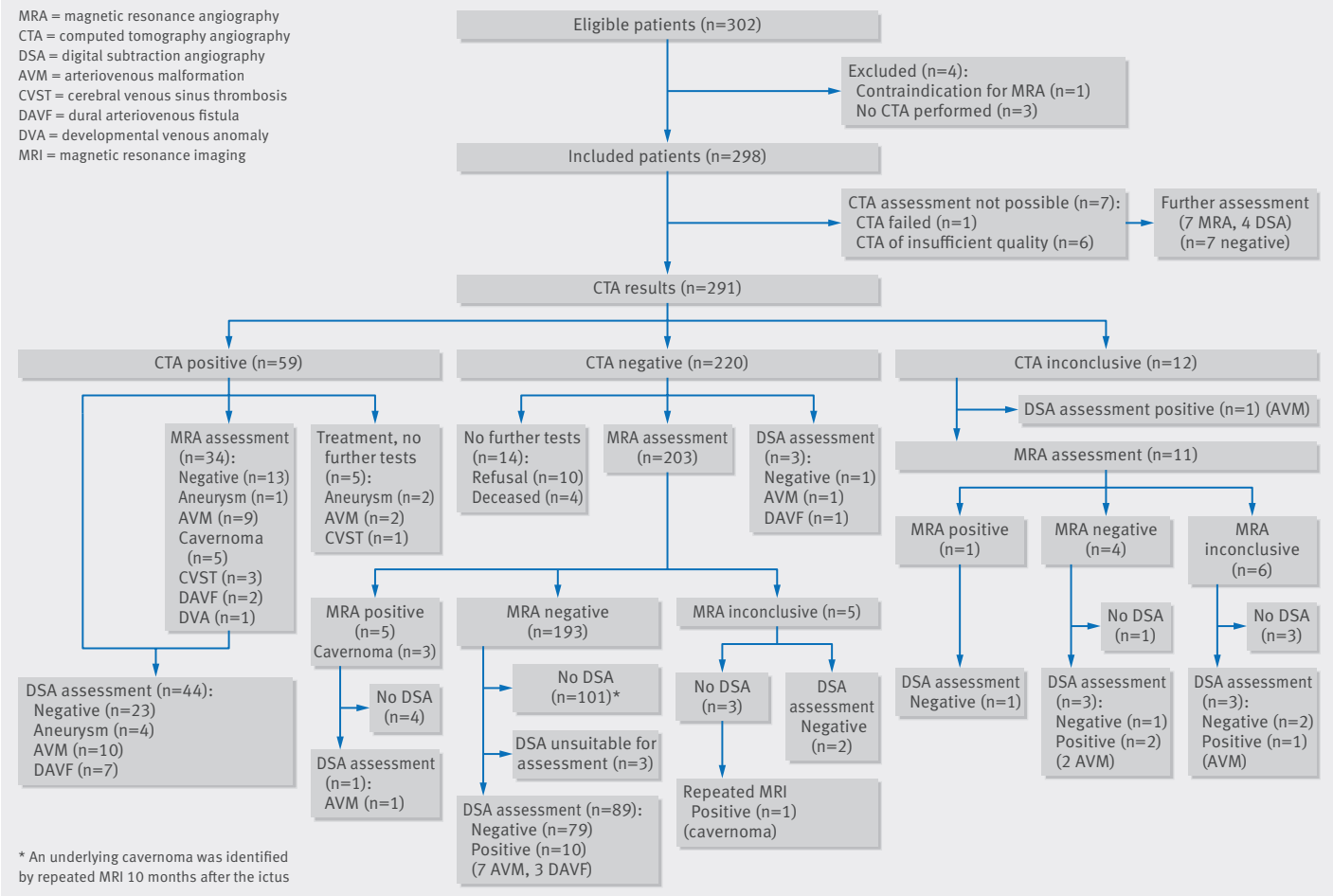
Characteristics	Characteristic present	Characteristic absent	Prevalence ratio (95% CI)
<b>Clinical characteristics</b>			
Age <50 years	42/112 (37.5)	27/186 (14.5)	2.58 (1.69 to 3.94)
Male sex	45/185 (24.3)	24/113 (21.2)	1.15 (0.74 to 1.77)
Glasgow coma score on admission:			
3-11	10/28 (35.7)	34/165 (20.6)*	1.73 (0.97 to 3.10)
12-14	12/55 (21.8)	34/165 (20.6)	1.06 (0.59 to 1.90)
Verbal score not applicable (aphasia)	13/50 (24.0)	34/165 (20.6)	1.26 (0.72 to 2.20)
Alcohol intake†:			
None	24/114 (21.1)	41/144 (28.5)‡	0.74 (0.48 to 1.15)
High (≥4/day)	4/36 (11.1)	41/144 (28.5)	0.39 (0.15 to 1.02)
Current smoking	20/72 (27.8)	49/226 (21.7)	1.28 (0.82 to 2.00)
Drug misuse before ICH§	5/12 (41.7)	64/283 (22.6)	1.84 (0.91 to 3.73)
Hypertension	16/95 (16.8)	53/203 (26.1)	0.65 (0.39 to 1.07)
Diabetes mellitus¶	1/18 (5.6)	68/279 (24.6)	0.23 (0.03 to 1.55)
Hypercholesterolemia**	5/26 (19.2)	37/176 (21.0)	0.91 (0.40 to 2.12)
History of CVD†	2/12 (16.7)	67/282 (23.8)	0.70 (0.19 to 2.53)
Family history of CVD††	12/55 (21.8)	51/228 (22.4)	0.98 (0.56 to 1.70)
Oral anticoagulants§	0/5 (0.0)	69/291 (23.7)	P=0.59‡‡
Daily antiplatelet use	3/31 (9.7)	68/267 (25.5)	0.38 (0.13 to 1.14)
<b>Radiological characteristics</b>			
Non-contrast CT assessment:			
ICH location:			
Basal ganglia or thalamus	5/85 (5.9)	49/178 (27.5)§§	0.21 (0.09 to 0.51)
Posterior fossa	15/35 (42.9)	49/178 (27.5)	1.56 (0.99 to 2.44)
ICH volume >11 mL (median)	34/148 (23.0)	35/150 (23.3)	0.98 (0.65 to 1.49)
Subarachnoid haemorrhage	21/56 (37.5)	48/242 (19.8)	1.89 (1.24 to 2.88)
Extension to frontal operculum	6/12 (50.0)	63/286 (22.0)	2.27 (1.24 to 4.16)
Intraventricular extension	23/71 (32.4)	46/227 (20.3)	1.60 (1.05 to 2.44)
Mass effect	45/191 (23.6)	24/107 (22.4)	1.05 (0.68 to 1.62)
Oedema	39/192 (20.3)	30/107 (28.0)	0.72 (0.48 to 1.10)
Haematoma density, homogeneous	55/239 (23.0)	14/59 (23.7)	0.97 (0.58 to 1.62)
White matter lesions	4/113 (3.5)	65/185 (35.1)	0.10 (0.04 to 0.27)
Hypodensity in basal ganglia, thalamus or posterior fossa	1/37 (2.7)	68/261 (26.1)	0.10 (0.01 to 0.72)
Small vessel disease¶¶	4/120 (3.3)	65/178 (36.5)	0.09 (0.03 to 0.24)
Enlarged vessels along ICH margins	11/13 (84.6)	58/285 (20.4)	4.16 (3.00 to 5.76)
Calcifications along ICH margins	7/7 (100.0)	62/291 (21.3)	4.69 (3.76 to 5.85)
Hyperattenuation within dural venous sinus or cortical vein	6/10 (60.0)	63/288 (21.9)	2.74 (1.58 to 4.76)
MRI assessment:			
Microbleeds***	0/63 (0.0)	40/163 (24.5)	P<0.01‡‡
Previous ICH***	0/30 (0.0)	40/196 (20.4)	P<0.01‡‡
White matter lesions†††	9/147 (6.1)	34/109 (31.2)	0.20 (0.10 to 0.39)
Previous infarct†††	1/70 (1.4)	42/186 (22.6)	0.06 (0.01 to 0.45)

ICH=intracerebral haemorrhage; CVD=cardiovascular disease; CT=computed tomography; MRI=magnetic resonance imaging.  
 \*15 was taken as reference.  
 †Missing values for four patients.  
 ‡Sporadic or moderate was taken as reference.  
 §Missing values for three patients.  
 ¶Missing values for one patient.  
 \*\*Total cholesterol concentration was available for 202 patients, cut-off value 5.6 mmol/L.  
 ††Missing values for 15 patients.  
 ‡‡P value Fisher's exact test.  
 §§Lobar was taken as reference.  
 ¶¶Defined as presence of white matter lesions, or an ischaemic lesion in basal ganglia, thalamus, or posterior fossa.  
 \*\*\*Assessment possible for 226 patients.  
 †††Assessment possible for 256 patients.

subtraction angiography included a groin haematoma in three patients (2%) and (possible) thromboembolic complications in three patients (2%); one with transient aphasia, one with a permanent visual deficit (homonymous hemianopia), and one with transient decreased consciousness. The proportion of patients with a complication resulting in permanent sequelae from the digital subtraction angiography was 0.6% (1/154).

### Multivariable logistic regression

In the multivariable logistic regression model, non-traumatic intracerebral haemorrhage in the posterior fossa was the strongest predictor (odds ratio 13.0, 95% confidence interval 3.7 to 46.5, reference: basal ganglia or thalamus), followed by the absence of signs of small vessel disease on non-contrast CT (8.5, 2.9 to 25.3), lobar location of the non-traumatic



Flow chart of angiographic examinations carried out between July 2008 and July 2014

intracerebral haemorrhage (5.5, 2.0 to 15.3), and age (0.96, 0.93 to 0.99).

### Discussion

This study shows that in preselected patients with non-traumatic intracerebral haemorrhage, the overall yield of CT angiography and MRI/MRA for detection of a macrovascular cause is slightly higher than that of early CT angiography as a single modality (18% v 17%), whereas the overall yield is increased to 23% by the combination of CT angiography, MRI/MRA, and digital subtraction angiography. After a negative CT angiography result, MRI/MRA can identify patients with a cavernoma or an alternative diagnosis such as a neoplasm or cerebral amyloid angiopathy, but is not useful to exclude an arteriovenous malformation or dural arteriovenous fistula. Digital subtraction angiography is accurate in the detection of arteriovenous malformations and dural arteriovenous fistula in patients in whom the underlying cause was not found by CT angiography and MRI/MRA.

Non-traumatic intracerebral haemorrhage located in the posterior fossa or lobar region is an important predictor of an underlying macrovascular cause, as is absence of small vessel disease on initial non-contrast CT. The probability of finding an underlying macrovascular cause diminishes with increasing age.

Based on the finding that all but one macrovascular lesions was detected at local reading, a strategy with independent assessment of vascular imaging studies by a second reader is not indicated.

Diagnostic strategies in patients with non-traumatic intracerebral haemorrhage vary among specialties and countries.<sup>13</sup> Some have suggested CT angiography as the initial examination,<sup>22</sup> whereas others prefer to start with magnetic resonance.<sup>23</sup> A recent Cochrane review reported high accuracy for MRI/MRA for detection of macrovascular causes of non-traumatic intracerebral haemorrhage as a first diagnostic modality.<sup>24</sup> In our study, MRI/MRA was performed four to eight weeks after non-traumatic intracerebral haemorrhage in patients in whom CT angiography had not found a cause of the haemorrhage. Therefore, our study does not provide information on the diagnostic accuracy of MRI/MRA as an initial investigation after non-contrast CT.

In this study, none of the patients with microbleeds had a macrovascular cause for non-traumatic intracerebral haemorrhage. The predictive value of microbleeds independently of signs of small vessel disease on non-contrast CT cannot be determined from our study because not all patients with negative CT angiography results and microbleeds on MRI underwent digital subtraction angiography.





**Table 4 | Results of assessment of computed tomography angiography (CTA), of the combination of CTA and magnetic resonance imaging/magnetic resonance angiography (MRI/MRA), and of the combination of CTA, MRI/MRA, and digital subtraction angiography (DSA)**

Test results	Reference standard*		Accuracy‡, % (95%CI)			
	Positive	Negative	Sensitivity	Specificity	PPV	NPV
CTA (n=291):						
Test result positive	47	12	74 (62 to 84)	—	—	—
Test result negative	18	202	—	91 (86 to 94)	—	—
Test result inconclusive	4	8	—	—	72 (60 to 82)	92 (88 to 95)
CTA+MRI/MRA (n=273):						
Test results positive	51	11	82 (71 to 90)	—	—	—
Test results negative	12	179	—	91 (86 to 95)	—	—
Test results inconclusive	4	16	—	—	77 (65 to 86)	94 (89 to 97)
CTA+MRI/MRA+DSA (n=151):						
Test results positive	99	0	99 (95 to 100)	—	—	—
Test results negative	1§	51	—	100 (93 to 100)	—	—
Test results inconclusive	0	0	—	—	100 (96 to 100)	98 (90 to 100)
Accuracy‡, % (95%CI)						
			Sensitivity	Specificity	PPV	NPV
			68 (56 to 79)	—	—	—
			—	95 (91 to 97)	—	—
			—	—	80 (67 to 89)	91 (86 to 94)
			76 (64 to 86)	—	—	—
			—	95 (91 to 97)	—	—
			—	—	82 (70 to 91)	92 (88 to 96)
			NA	—	—	—
			—	NA	—	—
			—	—	NA	NA

PPV=positive predictive value; NPV=negative predictive value; NA=not applicable.

\*Reference standard was best available evidence from all findings during follow-up.

†Inconclusive result regarded as positive outcome.

‡Inconclusive result regarded as negative outcome.

§Underlying cavernoma was identified by repeated MRI 10 months after ictus.

macrovascular causes and found prevalences of 13%<sup>5</sup> and 15%,<sup>3</sup> and therefore more true negative results. Another explanation for the lower sensitivity and specificity of CT angiography in our study compared with that of previous studies,<sup>3,5,26</sup> is that we regarded an underlying cavernoma as a positive outcome; half of the detected cavernomas in our study were not identified on early CT angiography.

## Implications

Our results indicate that CT angiography is an appropriate initial investigation for non-traumatic intracerebral haemorrhage, as it identifies around three quarters of macrovascular causes of such haemorrhages, is widely available, is feasible in patients with a poor clinical condition on admission, and has few complications (none in our study). However, we found that the accuracy of CT angiography is lower than previously reported. Additional MRI/MRA rarely detects additional macrovascular causes after a negative CT angiography result but it does provide important information on alternative diagnoses such as cerebral amyloid angiopathy. Digital subtraction angiography is able to detect with high accuracy small macrovascular causes not detected by CT angiography.

## Unanswered questions and future research

Future research will be helpful to establish the diagnostic value of MRI/MRA as an initial diagnostic modality after non-contrast CT, and to determine whether further evaluation with digital subtraction angiography is indicated in patients with microbleeds on MRI.

## AUTHOR AFFILIATIONS

<sup>1</sup>Department of Neurology and Neurosurgery, Brain Center Rudolf Magnus, University Medical Center Utrecht, PO box 85500, 3508 GA Utrecht, Netherlands

<sup>2</sup>Department of Radiology, University Medical Center Utrecht, Utrecht, Netherlands

<sup>3</sup>Julius Center for Health Sciences and Primary Care, University Medical Center Utrecht, Utrecht, Netherlands

<sup>4</sup>Department of Neurology, Donders Institute for Brain, Cognition and Behaviour, Radboud University Medical Center, Nijmegen, Netherlands

<sup>5</sup>Department of Neurology, St Antonius Hospital, Nieuwegein, Netherlands

<sup>6</sup>Department of Neurology, St Elisabeth Hospital, Tilburg, Netherlands

<sup>7</sup>Department of Neurology, Erasmus MC, University Medical Center Rotterdam, Rotterdam, Netherlands

<sup>8</sup>Department of Neurology, Meander Medical Center, Amersfoort, Netherlands

<sup>9</sup>Department of Neurology, Rijnstate Hospital, Arnhem, Netherlands

<sup>10</sup>Department of Neurology, Leiden University Medical Center, Leiden, Netherlands

<sup>11</sup>Department of Neurology, Albert Schweitzer Hospital, Dordrecht, Netherlands

<sup>12</sup>Department of Neurology, MCH Westeinde, The Hague, Netherlands

<sup>13</sup>Department of Neurology, Flevo Hospital, Almere, Netherlands

<sup>14</sup>Department of Neurology, Amphia Hospital, Breda, Netherlands

<sup>15</sup>Department of Neurology, Gelre Hospital, Apeldoorn, Netherlands

<sup>16</sup>Department of Neurology, Tergooi Hospitals, Blaricum, Netherlands

We thank the participants for taking part in this study, the (research) nurses, secretaries, neurologists, radiologists, and residents for assistance in patient recruitment and logistics, and Adel Kandil for his technical assistance in image processing.

**DIAGRAM Investigators:** F E de Leeuw, H B Boogaarts, and E J van Dijk (Radboud University Nijmegen Medical Center (academic hospital), Nijmegen; 27 patients enrolled), W J Schonewille, W M J Pellicaan, and C Puppels-de Waard (St Antonius hospital (non-teaching hospital), Nieuwegein; n=22), P L M de Kort, J P Peluso, and J H van Tuijl (St Elisabeth Hospital Tilburg (non-academic teaching hospital), Tilburg; n=20), J Hofmeijer, F B M Joosten (Rijnstate Hospital (non-teaching hospital), Arnhem; n=16), D W Dippel, L Khajeh (Erasmus MC University Medical Center (academic hospital), Rotterdam; n=16), T W M Raaijmakers (Meander Medical Center (non-teaching hospital), Amersfoort; n=16), M J Wermer and M A van Walderveen (Leiden University Medical Center (academic hospital), Leiden; n=14), H Kerkhoff and E Zock (Albert Schweitzer Hospital (non-teaching hospital), Dordrecht; n=14), K Jellema and G J Lycklama à Nijeholt (Medical Center Haaglanden (non-academic teaching hospital), the Hague; n=12), I M Bronner (Flevo Hospital (non-academic teaching hospital), Almere; n=12), M J M Remmers (Amphia Hospital (non-teaching hospital), Breda; n=9), R J G M Witjes (Tergooi Hospital (non-teaching hospital), Blaricum; 8), H P Bienfait, K E Droogh-Greve (Gelre Hospital (non-teaching hospital), Apeldoorn; n=8), R C J M Donders (Diaconessen Hospital (non-teaching hospital), Utrecht; n=6), V I H Kwa (now: Onze Lieve Vrouwe Gasthuis (non-teaching hospital), Slotervaart Hospital (non-teaching hospital), Amsterdam; n=4), T H Schreuder and C L Franke (Atrium Medisch Centrum (non-teaching hospital), Heerlen; n=4), J S Straver (Hofpoort Hospital (non-teaching hospital), Woerden; n=2), C Jansen (Gelderse Vallei Hospital (non-teaching hospital), Ede; n=1), S L M Bakker and C C Pleiter (Sint Franciscus Gasthuis (non-teaching hospital), Rotterdam; n=1), M C Visser (Free University Medical Center (academic hospital), Amsterdam; n=1), and C J J van Asch, B K Velthuis, G J E Rinkel, K M van Nieuwenhuizen, and C J M Klijn (University Medical Center Utrecht (academic hospital); n=90).

**Contributors:** CJMK, BKV, GJER, and AA designed the study. CJvA, BV, JCMdR, and CJMK organised the study and were responsible for its execution. BV, GAPdK, and TW assessed brain images. CJvA, KMvN, FEDL, WJS, PLMdK, DWD, TWMR, JH, MJHW, HK, KJ, IMB, MJMR, HPB, RJGMW, and CJMK collected data. CJvA, GJER, AA, JPG, and CJMK carried out the statistical analyses. CJvA drafted the paper, and all authors reviewed and commented on the report. CJMK is the guarantor.

**Funding:** This study was supported by a Dutch Heart Foundation grant (No 2007B048, to CJMK). CJMK is also supported by a clinical established investigator grant of the Dutch Heart Foundation (grant No 2012 T077), and an Aspasia grant from the Netherlands Organisation for Health Research and Development, ZonMw (015008048). Statement of independence of researchers from funders: The corresponding and the guarantor (CJMK) had full access to all study data and final responsibility for the decision to submit for publication.

**Competing interests:** All authors have completed the ICMJE uniform disclosure form at [www.icmje.org/doi\\_disclosure.pdf](http://www.icmje.org/doi_disclosure.pdf) and declare: no support from any organisation for the submitted work; no financial relationships with any organisations that might have an interest in the submitted work in the previous three years; no other relationships or activities that could appear to have influenced the submitted work.

**Ethical approval:** This study was approved by the medical ethics committee of the University Medical Center Utrecht, the Netherlands, as well as local approval from all participating hospitals.

**Data sharing:** Requests for data sharing should be sent to the corresponding author ([c.j.j.vanasch@gmail.com](mailto:c.j.j.vanasch@gmail.com)) and will be considered on approval by the DIAGRAM Investigators.

**Transparency:** The lead author (CJMK) affirms that this manuscript is an honest, accurate, and transparent account of the study being reported; that no important aspects of the study have been omitted; and that any discrepancies from the study as planned (and, if relevant, registered) have been explained.

This is an Open Access article distributed in accordance with the Creative Commons Attribution Non Commercial (CC BY-NC 4.0) license, which permits others to distribute, remix, adapt, build upon this work non-commercially, and license their derivative works on different terms, provided the original work is properly cited and the use is non-commercial. See: <http://creativecommons.org/licenses/by-nc/4.0/>.

- 1 Al-Shahi Salman R, Labovitz DL, Stapf C. Spontaneous intracerebral haemorrhage. *BMJ* 2009;339:284-9.
- 2 Vaartjes I, Reitsma JB, de Bruin A, et al. Nationwide incidence of first stroke and TIA in the Netherlands. *Eur J Neurol* 2008;15:1315-23.
- 3 Delgado Almandoz JE, Schaefer PW, Forero NP, et al. Diagnostic accuracy and yield of multidetector CT angiography in the evaluation of spontaneous intraparenchymal cerebral hemorrhage. *Am J Neuroradiol* 2009;30:1213-21.

- 4 Van Asch CJ, Velthuis BK, Greving JP, et al. External validation of the secondary intracerebral hemorrhage score in The Netherlands. *Stroke* 2013;44:2904-6.
- 5 Bekelis K, Desai A, Zhao W, et al. Computed tomography angiography: improving diagnostic yield and cost effectiveness in the initial evaluation of spontaneous nonsubarachnoid intracerebral hemorrhage. *J Neurosurg* 2012;117:761-6.
- 6 Ohtani R, Kazui S, Tomimoto H, et al. Clinical and radiographic features of lobar cerebral hemorrhage: hypertensive versus non-hypertensive cases. *Intern Med* 2003;42:576-80.
- 7 Delgado Almandoz JE, Schaefer PW, Goldstein JN, et al. Practical scoring system for the identification of patients with intracerebral hemorrhage at highest risk of harboring an underlying vascular etiology: the Secondary Intracerebral Hemorrhage Score. *Am J Neuroradiol* 2010;31:1653-60.
- 8 Zhu XL, Chan MS, Poon WS. Spontaneous intracranial hemorrhage: which patients need diagnostic cerebral angiography? A prospective study of 206 cases and review of the literature. *Stroke* 1997;28:1406-9.
- 9 Olavarría V, Bustamante G, López MJ, et al. Diagnostic accuracy of a simple clinical score to screen for vascular abnormalities in patients with intracerebral hemorrhage. *J Stroke Cerebrovasc Dis* 2014;23:2069-74.
- 10 Morgenstern LB, Hemphill JC, Anderson C, et al. Guidelines for the management of spontaneous intracerebral hemorrhage: a guideline for healthcare professionals from the American Heart Association/American Stroke Association. *Stroke* 2010;41:2108-29.
- 11 Masdeu JC, Irimia P, Asenbaum S, et al. EFNS guideline on neuroimaging in acute stroke. Report of an EFNS task force. *Eur J Neurol* 2006;13:1271-83.
- 12 Steiner T, Al-Shahi Salman R, Beer R, et al. European Stroke Organisation (ESO) guidelines for the management of spontaneous intracerebral hemorrhage. *Int J Stroke* 2014;9:840-55.
- 13 Cordonnier C, Klijn CJM, van Beijnum J, et al. Radiological investigation of spontaneous intracerebral hemorrhage: systematic review and trinational survey. *Stroke* 2010;41:685-90.
- 14 Van Swieten JC, Koudstaal PJ, Visser MC, et al. Interobserver agreement for the assessment of handicap in stroke patients. *Stroke* 1988;19:604-7.
- 15 Ang D, Lang C. The prognostic value of the ECG in hypertension: where are we now? *J Hum Hypertens* 2008;22:460-7.
- 16 Casolla B, Dequatre-Ponchelle N, Rossi C, et al. Heavy alcohol intake and intracerebral hemorrhage: characteristics and effect on outcome. *Neurology* 2012;79:1109-15.
- 17 Westerlaan H, van Dijk J, Jansen-van der Weide M, et al. Intracranial aneurysms in patients with subarachnoid hemorrhage: CT Angiography as a primary examination tool for diagnosis-systematic review and meta-analysis. *Radiology* 2011;258:134-45.
- 18 Hegde A, Mohan S, Lim CCT. CNS cavernous haemangioma: 'popcorn' in the brain and spinal cord. *Clin Radiol* 2012;67:380-8.
- 19 Moons KG, de Groot JA, Bouwmeester W, et al. Critical appraisal and data extraction for systematic reviews of prediction modelling studies: the CHARMS checklist. *PLoS Med* 2014;11.
- 20 Janssen KJ, Donders AR, Harrell FE Jr, et al. Missing covariate data in medical research: to impute is better than to ignore. *J Clin Epidemiol* 2010;63:721-7.
- 21 Bossuyt PM, Reitsma JB, Bruns DE, et al. Towards complete and accurate reporting of studies of diagnostic accuracy: the STARD initiative. *Clin Radiol* 2003;58:575-80.
- 22 Macellari F, Paciaroni M, Agnelli G, et al. Neuroimaging in intracerebral hemorrhage. *Stroke* 2014;45:903-8.
- 23 Domingues R, Rossi C, Cordonnier C. Diagnostic evaluation for nontraumatic intracerebral hemorrhage. *Neuro Clin* 2015;33:315-28.
- 24 Josephson CB, White PM, Krishan A, et al. Computed tomography angiography or magnetic resonance angiography for detection of intracranial vascular malformations in patients with intracerebral haemorrhage (Review). *Cochrane Database Syst Rev* 2014;9:1-55.
- 25 Kadkhodayan Y, Delgado Almandoz JE, Kelly JE, et al. Yield of catheter angiography in patients with intracerebral hemorrhage with and without intraventricular extension. *J Neurointerv Surg* 2012;4:358-63.
- 26 Wong GK, Siu DYW, Abrigo JM, et al. Computed tomographic angiography and venography for young or nonhypertensive patients with acute spontaneous intracerebral hemorrhage. *Stroke* 2011;42:211-3.
- 27 Linn J, Halpin A, Demaerel P, et al. Prevalence of superficial siderosis in patients with cerebral amyloid angiopathy. *Neurology* 2010;74:1346-50.

© BMJ Publishing Group Ltd 2015

**Web appendix:** box showing assessed radiological characteristics on admission non-contrast computed tomography, and box showing reasons for not performing MRI/MRA and digital subtraction angiography in patients with negative or inconclusive CT angiography results