

University of Groningen

Acute Myeloid Leukemia in a Patient with Shwachman-Diamond Syndrome

Choi, Goda; Snijder, S; Zeerleder, S.

Published in:
Annals of Hematology & Oncology

IMPORTANT NOTE: You are advised to consult the publisher's version (publisher's PDF) if you wish to cite from it. Please check the document version below.

Document Version
Publisher's PDF, also known as Version of record

Publication date:
2015

[Link to publication in University of Groningen/UMCG research database](#)

Citation for published version (APA):
Choi, G., Snijder, S., & Zeerleder, S. (2015). Acute Myeloid Leukemia in a Patient with Shwachman-Diamond Syndrome. *Annals of Hematology & Oncology*, 2(1), [1020].

Copyright

Other than for strictly personal use, it is not permitted to download or to forward/distribute the text or part of it without the consent of the author(s) and/or copyright holder(s), unless the work is under an open content license (like Creative Commons).

Take-down policy

If you believe that this document breaches copyright please contact us providing details, and we will remove access to the work immediately and investigate your claim.

Downloaded from the University of Groningen/UMCG research database (Pure): <http://www.rug.nl/research/portal>. For technical reasons the number of authors shown on this cover page is limited to 10 maximum.

Special Article - Hematology

Acute Myeloid Leukemia in a Patient with Shwachman-Diamond Syndrome: Complex Cytogenetics Redefined

G Choi^{1*}, S Snijder² and S S Zeerleder^{1,3}¹Department of Hematology, Academic Medical Center, University of Amsterdam, Netherlands²Department of Clinical Genetics, Academic Medical Center, University of Amsterdam, Amsterdam, Netherlands³Department of Immunopathology, Sanquin Research and Landsteiner Laboratory of the AMC, Amsterdam, Netherlands

*Corresponding author: G Choi, Department of Hematology, University Medical Center Groningen

Hanzeplein 19713 GZ Groningen, The Netherlands, Tel: +31 50 361 2354; Fax: +31 50 361 5960; Email: c.w.choi@umcg.nl

Received: December 04, 2014; Accepted: January 05, 2015; Published: January 07, 2015

Shwachman-(Bodian)-Diamond Syndrome (SDS) is a rare autosomal recessive disorder (OMIM #260400): A homozygous or compound heterozygous mutation in the *SBDS* gene causes karyotypic instability, predisposing hematopoietic cells to malignant transformation. We here present a 21-year-old male patient with SDS who has had chronic leukopenia and thrombocytopenia since 4 years before presenting with pancytopenia. Bone marrow aspirate showed massive infiltration with myeloid blasts (**Figure, left panel**). Cytogenetic analysis showed highly complex chromosomal abnormalities: 97~101, XYY,-3,-5,+6,+6,+7,-8,-9,-

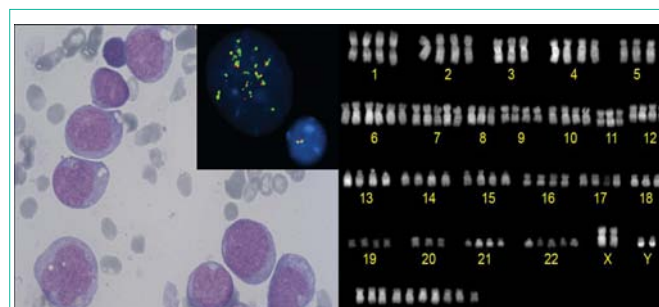


Figure: Giemsa stain, showing irregularly shaped myeloid blasts with monocytic morphology (left panel); karyogram showing multiple chromosomal abnormalities and hypertetraploidy (right panel); malignant cells had >20 signals for *KMT2A* vs 2 signals in the normal cell (inset).

11,-18,+22,+7~13mar [cp6] / 46,XY [4] (**Figure, right panel**) with FISH revealing *KMT2A* (*MLL*) amplification (11q23) (**Figure inset**). The diagnosis of poor risk acute myeloid leukemia was made. The patient was treated with high-dose chemotherapy followed by a Stem Cell Transplantation (SCT) from an unrelated donor. There are ongoing discussions whether SCT should be recommended to young adults with SDS before malignant transformation. It remains to be established whether the benefits of SCT outweigh the risk of treatment-related complications.