

University of Groningen

Long-term effects of cholinergic basal forebrain lesions on neuropeptide Y and somatostatin immunoreactivity in rat neocortex

Gaykema, R.P.A.; Compaan, J.C.; Nyakas, Csaba; Horvath, E.; Luiten, P.G.M.

Published in:
Brain Research

DOI:
[10.1016/0006-8993\(89\)90878-0](https://doi.org/10.1016/0006-8993(89)90878-0)

IMPORTANT NOTE: You are advised to consult the publisher's version (publisher's PDF) if you wish to cite from it. Please check the document version below.

Document Version
Publisher's PDF, also known as Version of record

Publication date:
1989

[Link to publication in University of Groningen/UMCG research database](#)

Citation for published version (APA):

Gaykema, R. P. A., Compaan, J. C., Nyakas, C., Horvath, E., & Luiten, P. G. M. (1989). Long-term effects of cholinergic basal forebrain lesions on neuropeptide Y and somatostatin immunoreactivity in rat neocortex. *Brain Research*, 489(2), 392-396. DOI: 10.1016/0006-8993(89)90878-0

Copyright

Other than for strictly personal use, it is not permitted to download or to forward/distribute the text or part of it without the consent of the author(s) and/or copyright holder(s), unless the work is under an open content license (like Creative Commons).

Take-down policy

If you believe that this document breaches copyright please contact us providing details, and we will remove access to the work immediately and investigate your claim.

Downloaded from the University of Groningen/UMCG research database (Pure): <http://www.rug.nl/research/portal>. For technical reasons the number of authors shown on this cover page is limited to 10 maximum.

BRE 23555

Long-term effects of cholinergic basal forebrain lesions on neuropeptide Y and somatostatin immunoreactivity in rat neocortex

R.P.A. Gaykema¹, J.C. Compaan¹, C. Nyakas¹, E. Horvath² and P.G.M. Luiten¹

¹Department of Animal Physiology, University of Groningen, Haren (The Netherlands) and ²Neurobiology Department, Troponwerke, Cologne (F.R.G.)

(Accepted 28 February 1989)

Key words: cholinergic basal forebrain lesion; Somatostatin; Neuropeptide Y; Neocortex; Rat

The effect of cholinergic basal forebrain lesions on immunoreactivity to somatostatin (SOM-i) and neuropeptide-Y (NPY-i) was investigated in the rat parietal cortex, 16–18 months after multiple bilateral ibotenic acid injections in the nucleus basalis complex. As a result of the lesion, the cholinergic fiber density in the cortex decreased by 66% with a concurrent increase in SOM-i fibers by more than 50% and a 124% increase in NPY-i fiber innervation. The neuropeptidergic sprouting response on cholinergic denervation does not match the concurrent cholinergic and peptidergic decline in Alzheimer's disease and as such does not support the cholinergic lesion alone as an animal model for this neurodegenerative disorder.

The systemic breakdown of the magnocellular basal forebrain complex, which is the subcortical source of cholinergic innervation of cortex and hippocampus^{16,18}, is the most consistent transmitter-specific change found in Alzheimer's disease (AD). These findings led to the cholinergic hypothesis for dementia, which assumes a major role of specific cholinergic decline of the basal forebrain system in the causation of the neuropathology found in Alzheimer's disease^{2,6} and its characteristic impairment of learning and memory. Ever since, a large number of studies were initiated on experimental cholinergic basal forebrain lesions in search for an animal model for this neurodegenerative disorder^{1,7,13,15,20,22}. To validate the cholinergic forebrain lesion as a dementia model, or in general to study complex learning-memory functions of the forebrain, this experimental model should meet several criteria. First, cholinergic forebrain lesions should mimic the persistent amnesic deficits characteristic for the dementia syndromes. Indeed, experimental damage to the magnocellular basal nucleus and the medial septal area under certain conditions results in a permanent deterioration of the performance of animals in a

variety of learning and memory tasks^{13–15,20,22}. Second, the specific cholinergic forebrain lesion should lead to similar biochemical and anatomical effects in cortex and hippocampus which define the neuropathology in AD. In this respect, several neurotransmitter and neuropeptidergic systems in the cortical mantle appear to be affected^{3,4,9}. For neuropeptides there is ample evidence that somatostatin (SOM) and neuropeptide Y (NPY) systems in cortex and hippocampus are severely damaged and involved in the formation of neurofibrillary tangles and neuritic plaques^{3,4,8}. In the present investigation we aimed at assessing whether the concurrent cholinergic and peptidergic decline in AD are causally related or independent degenerative phenomena. In the currently used experimental design the cholinergic lesion and prolonged cortical cholinergic denervation was obtained by multiple injections in the magnocellular basal forebrain complex (MBN) with the excitotoxin ibotenic acid, followed by extended survival periods of 16–18 months. In our view such long-term effects of cholinergic lesions into the aging stage of the experimental animal bear more resemblance to the human neuropathology. From recent

Correspondence: P.G.M. Luiten, Department of Animal Physiology, P.O. Box 14, 9750 AA Haren, The Netherlands.

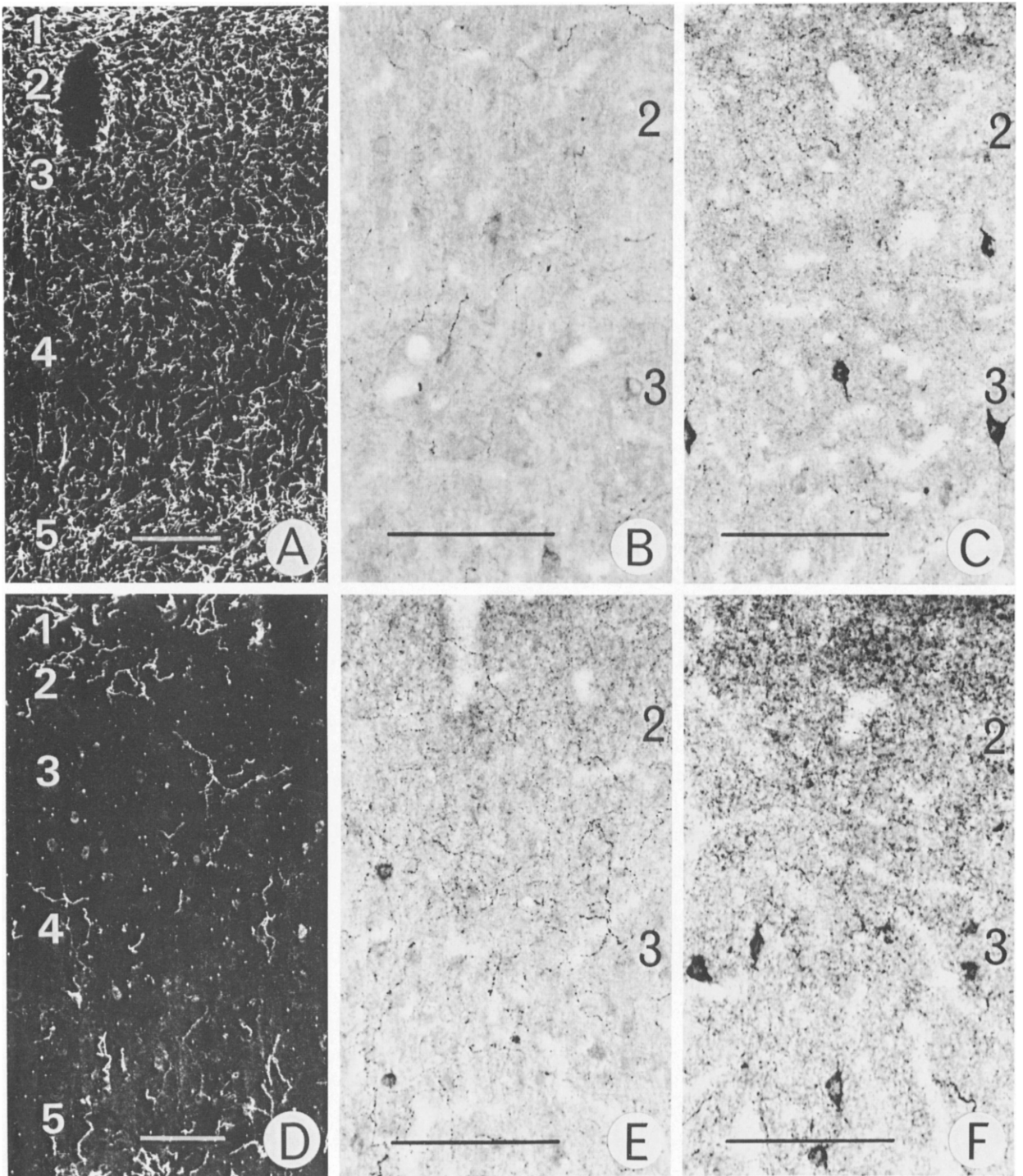


Fig. 1. Photomicrographs of layers 2-5 of the parietal cortex stained for AChE (A and D), with dark-field illumination, NPY (B and E) and SOM (C and F). The upper row (A-C) represents the control condition with intact cholinergic innervation and concomitant moderate normal fiber density of SOM-i and NPY-i. D-F illustrate comparable cortex layers in an MBN lesioned case with strong decline of cholinergic fibers (D) and concurrent increased immunoreactivity of NPY and SOM. Figures 2-5 refer to cortical layers. Bar = 100 μ m.

studies it may indeed be concluded that certain effects of cholinergic lesions only become manifest after long survival periods, while remaining unnoticed shortly after experimental damage¹.

The data presented here on acetylcholinesterase (AChE)-positive, and on SOM- and NPY-immunoreactive fiber innervation in the neocortex are based on 4 MBN-lesioned and 6 sham-operated male albino Wistar rats. The lesions were performed at the age of 10 months by 5 bilateral pressure injections of 0.5 µl ibotenic acid (1 mg/ml in saline, pH = 7.4²¹) in the MBN using stereotaxic procedures and according to the following coordinates (relative in mm to interaural point).

	1	2	3	4	5
A-P	6.3	6.3	7.3	7.3	8.3
L-R ±	± 4.3	± 4.3	± 3.6	± 3.0	± 2.5
D-V	2.6	3.4	3.8	2.6	1.8

The sham-operated animals received drilled holes in the skull at the appropriate coordinates and served as controls. Before histological treatment the animals underwent extensive behavioral testing. All lesioned cases revealed persistent learning/memory deficits as reported elsewhere¹³. At 16–18 months after lesioning, the animals were transcardially perfused briefly with saline, followed by a fixative solution of 3% paraformaldehyde and 0.01% glutaraldehyde in 0.05 M phosphate buffer, pH 7.4. The

brains were cut at 20 µm transverse sections on a cryostat microtome after overnight dehydration in 30% sucrose at 4 °C. Every eighth section was postfixed overnight in buffered 2.5% glutaraldehyde and stained for AChE according to the procedure of Hedreen et al.¹¹. The Hedreen method combined with glutaraldehyde postfixation yields crisply stained AChE-positive fibers against a pale yellowish background. Adjacent sections were processed for immunocytochemical identification of SOM and NPY, respectively (Fig. 1). Both for SOM and NPY immunostaining the following incubation steps were carried out⁵: preincubation in 10% normal goat serum, primary antibody incubation (rabbit anti-SOM 28, 1:2000 or rabbit anti-NPY, 1:1500) for 72 h at 4 °C, a second incubation in goat anti-rabbit IgG (Nordic, 1:50) overnight at 4 °C and a final exposure to rabbit peroxidase–antiperoxidase complex (DAKO, 1:500) again overnight at 4 °C. The peroxidase was visualized by standard processing with DAB and hydrogen peroxide.

The relative density of AChE-positive, SOM-i (-immunoreactive) and NPY-i fibers was assessed in the parietal cortex area 1²⁴ at 3 anterior–posterior levels (–0.3, –0.8 and –1.3 mm relative to Bregma²⁴). Quantification of the fibers was performed by projecting the sections via a drawing tube of the microscope on a square counting grid consisting of 5

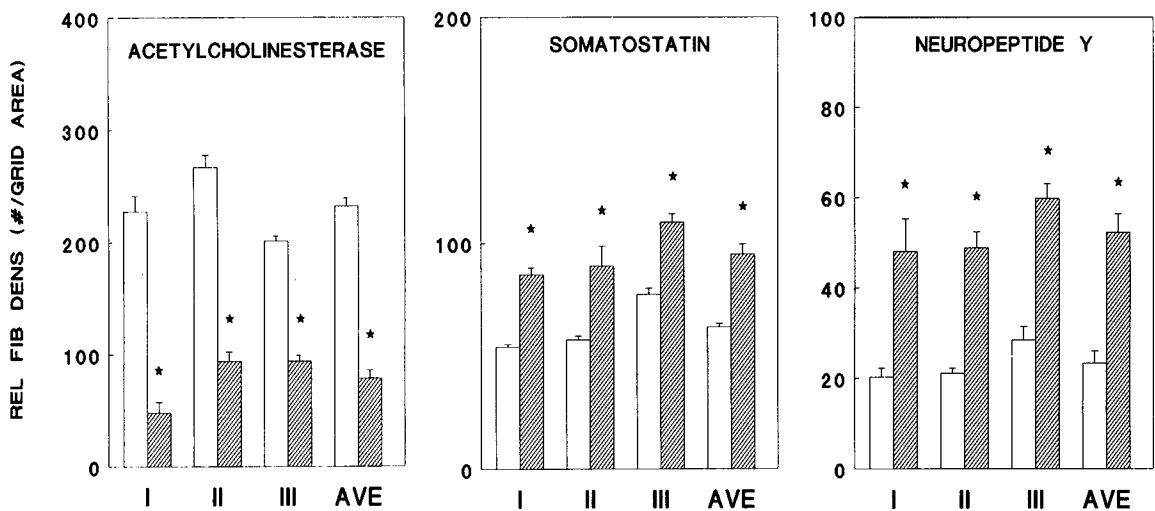


Fig. 2. Quantitative figures on relative fiber density in 3 sublayers of the parietal neocortex as counted by fibers crossing a line pattern in a grid of 240 × 240 µm (see text). Open bars represent control cases, hatched bars the cases lesioned in the MBN. I–III indicates the 3 cortical sublayers counted (see text) and AVE the average of the 3 sublayers. Asterisk indicates statistical significance calculated with the Mann–Whitney *U*-test at *P* < 0.05.

horizontal and 5 vertical lines according to the method described by Stichel and Singer²³. With the magnification used, the grid measured $240 \times 240 \mu\text{m}$ and was projected upon 3 radially oriented positions (I, II and III in Fig. 2) corresponding to layers 2 and 3 (I), layers 4 and superficial layer 5 (II), and deep layer 5 and 6 (III) of the parietal cortex. The relative fiber density was established by counting the crossing of fibers with the horizontal and vertical lines of the grid. The counts for each of the three grid positions were averaged over the three A-P levels and the S.E.M.'s calculated. All quantifications of cholinergic and peptidergic fibers were compared between the lesioned and the control groups. Differences were analyzed for statistical significance by the Mann-Whitney *U*-test. Significance was assumed for $P < 0.05$.

All lesioned cases studied showed a remarkably stable pattern of decrease of AChE-positive fibers and a concurrent increase of both SOM-i and NPY-i axonal labeling in all cortical layers examined (Fig. 2). The normal cholinergic innervation pattern as demonstrated by AChE histochemistry is completely similar to the pattern of choline acetyltransferase immunoreactivity¹⁷. It is characterized by relatively dense fiber networks in layers 1, 2 and 3, a loose pattern in layer 4, a dense innervation in layer 5, slightly decreasing in layer 6. After MBN lesion, all layers showed a very strong decline in cholinergic fibers. This decline was calculated as an average for all cortical layers of 66% and was highest for the superficial layers 2 and 3 (Fig. 2). The consistency of this decline is illustrated by the low S.E.M. values. In contrast to the cholinergic denervation, there is a strong and equally consistent increase in SOM-i and NPY-i fibers. The relative density of SOM-i axons increased with an average of 51%, whereas an average of 124% more NPY-i fibers were counted in the lesioned cases. All figures showed moderate S.E.M. levels and were statistically significant. Furthermore, the degree of decrease of cholinergic denervation in the different cortical sublayers I-III seemed to be proportional to the level of increase in peptidergic fibers. Thus, the strongest decrease of cholinergic innervation in cortical layers 2 and 3 is accompanied by the highest increase in both neuropeptides' immunoreactivity.

The present findings clearly indicate highly sig-

nificant increases in SOM-i and NPY-i fibers after long-term cholinergic denervation in the neocortex. As such, our data corroborate the observations of Arendash et al.¹, who, with biochemical assays, found increases in SOM and NPY concentrations of 138 and 284%, respectively, 14 months after partial MBN lesions. The SOM-i and NPY-i increment after MBN lesion, however, appears to be related to the length of the post-lesion survival time. Our own unpublished observations on SOM-i and NPY-i fibers two weeks after MBN lesion do not show any significant change compared to controls. These findings are consistent with several previous reports on persistent peptidergic innervation levels up to 6 months after MBN lesioning^{1,7,9,19}. Hörtnagl and Sperk¹² reported on short-term changes in SOM- and NPY levels after cholinergic lesions which, however, returned to normal control levels after two week postlesion time.

The increased presence of SOM-i and NPY-i fiber networks may well be interpreted as a long-term heterotypic sprouting response of the intrinsic peptidergic innervation as a result of cholinergic denervation of the neocortex. However, since the peptides were demonstrated with immunocytochemical detection methods, we cannot exclude that the increased fiber density is the result of higher peptide concentrations in existing fibers which remain under the sensitivity threshold in the control cases. The latter explanation, however, seems unlikely since in all tissue sections studied the immunoprecipitate appeared crisply and strongly stained and not subject to a sensitivity gradient (see also Fig. 1). It appears more likely that cholinergic denervation on the long-term and possibly combined with aging-related factors, leads to heterotypic sprouting outgrowth of SOM-i and NPY-i axon collaterals. This, however, is in striking contrast with the simultaneous deterioration of cholinergic and peptidergic innervation observed in Alzheimer's disease. In that sense, the MBN lesion model in experimental animals suggests that a cholinergic denervation alone is unlikely to cause a decline of the peptidergic systems in the cortex of AD patients. Furthermore, it should be noted that currently used MBN lesion models are all based on a sudden, momentary destruction of MBN cells. A more gradual extinction of the cholinergic cortical innervation by a chronic excitotoxin lesion

model may better mimic the neuropathology occurring in AD. In summary, although the experimental cholinergic lesion shows a considerable analogy to the behavioral deficits in learning and memory in AD, the anatomical substrates underlying the human neuropathology remain to be understood.

- 1 Arendash, G.W., Millard, W.J., Dunn, A.J. and Meyer, E.M., Long-term neuropathological and neurochemical effects of nucleus basalis lesions in the rat, *Science*, 238 (1987) 952–956.
- 2 Bartus, R.T., Dean, III, R.L., Beer, B. and Lippa, A.S., The cholinergic hypothesis of geriatric memory dysfunction, *Science*, 217 (1982) 408–417.
- 3 Chan-Palay, V., Somatostatin immunoreactive neurons in the human hippocampus and cortex shown by immunogold/silver intensification on vibratome sections: coexistence with neuropeptide Y neurons, and effects in Alzheimer's type dementia, *J. Comp. Neurol.*, 260 (1987) 201–223.
- 4 Chan-Palay, V., Lang, W., Haesler, U., Köhler, C. and Yasargil, G., Distribution of altered hippocampal neurons and axons immunoreactive with antisera against neuropeptide Y in Alzheimer's type dementia, *J. Comp. Neurol.*, 248 (1986) 376–394.
- 5 Chronwall, B.M., DiMaggio, D.A., Massari, V.J., Pickel, V.M., Ruggiero, D.A. and O'Donohue, T.L., The anatomy of neuropeptide-Y-containing neurons in rat brain, *Neuroscience*, 15 (1985) 1159–1181.
- 6 Coyle, J.T., Price, D.L. and DeLong, M.R., Alzheimer's disease: a disorder of cortical cholinergic innervation, *Science*, 219 (1983) 1184–1189.
- 7 Epelbaum, J., Lamour, Y., Enjalbert, A., Hamon, M., Dutar, P. and Kordon, C., Modifications in the cortical regional distribution of choline acetyltransferase, somatostatin and somatostatin binding sites in the normal rat and following lesion of the nucleus basalis, *Brain Research*, 371 (1986) 376–379.
- 8 Ferrier, I.N., Cross, A.J., Johnson, J.A., Roberts, G.W., Crow, T.J., Corsellis, J.A.N., Lee, Y.C., O'Shaughnessy, D., Adrian, T.E., McGregor, G.P., Baracese-Hamilton, A.J. and Bloom, S.R., Neuropeptides in Alzheimer type dementia, *J. Neurol. Sci.*, 62 (1983) 159–170.
- 9 Fine, A., Pittaway, K., de Quidt, M., Czudek, C. and Reynolds, G.P., Maintenance of cortical somatostatin and monoamine levels in the rat does not require intact cholinergic innervation, *Brain Research*, 406 (1987) 326–329.
- 10 Hardy, J., Adolfsson, R., Alafuzoff, I., Bucht, G., Marcusson, J., Nyberg, P., Perdah, E., Wester, P. and Winblad, B., Transmitter deficits in Alzheimer disease, *Neurochem. Int.*, 7 (1985) 545–563.
- 11 Hedreen, J.C., Bacon, S.J. and Price, D.L., A modified histochemical technique to visualize acetylcholinesterase-containing axons, *J. Histochem. Cytochem.*, 33 (1985) 134–140.
- 12 Hörtnagl, H. and Sperk, G., Effect of cholinergic deficit induced by ethylcholine aziridium (AF64A) on somatostatin and neuropeptide Y levels in rat hippocampus, *Neurochem. Int.*, 13 (1988) 130.
- 13 Horvath, E., Spencer, D.G., Schuurman, T., Dompert, W.U. and Traber, J., 'Total' cholinergic basal forebrain lesions in the rat: long-term behavioral, histological and biochemical consequences, *ENA/EBBS Abstr.*, 99 (1988) 22.
- 14 Irle, E. and Markowitsch, H.J., Basal forebrain-lesioned monkeys are severely impaired in tasks of association and recognition memory, *Ann. Neurol.*, 22 (1987) 735–743.
- 15 Kesner, R.P., Adelstein, T. and Crutcher, K.A., Rats with nucleus basalis magnocellularis lesions mimic mnemonic symptomatology observed in patients with dementia of the Alzheimer's type, *Behav. Neurosci.*, 101 (1987) 451–456.
- 16 Luiten, P.G.M., Gaykema, R.P.A., Traber, J. and Spencer Jr., D.G., Cortical projection patterns of magnocellular basal nucleus subdivisions as revealed by anterogradely transported *Phaseolus vulgaris* leucoagglutinin, *Brain Research*, 413 (1987) 229–250.
- 17 Luiten, P.G.M., Wouterlood, F.G., Matsuyama, T., Strosberg, A.D., Buwalda, B. and Gaykema, R.P.A., Immunocytochemical applications in neuroanatomy. Demonstration of connections, transmitters and receptors, *Histochemistry*, 90 (1988) 85–97.
- 18 McKinney, M., Coyle, J.T. and Hedreen, J.C., Topographic analysis of the innervation of the rat neocortex and hippocampus by the basal forebrain cholinergic system, *J. Comp. Neurol.*, 217 (1983) 103–121.
- 19 Mufson, E.J., Kehr, A.D., Wainer, B.H. and Mesulam, M.-M., Cortical effects of neurotoxic damage to the nucleus basalis in rats: persistent loss of extrinsic cholinergic input and lack of transsynaptic effect upon the number of somatostatin-containing, cholinesterase-positive, and cholinergic cortical neurons, *Brain Research*, 417 (1987) 385–388.
- 20 Olton, D.S. and Wenk, G.L., Dementia: animal models of the cognitive impairments produced by degeneration of the basal forebrain cholinergic system. In H.Y. Meltzer (Ed.), *Psychopharmacology: The Third Generation of Progress*, Raven, New York, 1987, pp. 941–953.
- 21 Schwarcz, R., Foster, A., French, E., Wehtsell, W. and Köhler, C., Excitotoxic models for neurodegenerative disorders, *Life Sci.*, 35 (1984) 19–42.
- 22 Smith, G., Animal models of Alzheimer's disease: experimental cholinergic denervation, *Brain Res. Rev.*, 13 (1988) 103–118.
- 23 Stichel, C.C. and Singer, W., Quantitative analysis of the choline acetyltransferase-immunoreactive axonal network in the cat primary visual cortex. I. Adult cats, *J. Comp. Neurol.*, 258 (1987) 91–98.
- 24 Zilles, K.J., *The Cortex of the Rat. A Stereotaxic Atlas*, Springer, Berlin, 1985.

The authors wish to thank Drs. Jan de Mey, Fred van Leeuwen and Bibi Cronwall for their generous gifts of antibodies to SOM-28 and NPY. Mrs. J. Poelstra is acknowledged for typing the manuscript.