

## University of Groningen

### Hand Eczema

Coenraads, Pieter

*Published in:*  
New England Journal of Medicine

*DOI:*  
[10.1056/NEJMcp1104084](https://doi.org/10.1056/NEJMcp1104084)

**IMPORTANT NOTE: You are advised to consult the publisher's version (publisher's PDF) if you wish to cite from it. Please check the document version below.**

*Document Version*  
Publisher's PDF, also known as Version of record

*Publication date:*  
2012

[Link to publication in University of Groningen/UMCG research database](#)

*Citation for published version (APA):*  
Coenraads, P.-J. (2012). Hand Eczema. *New England Journal of Medicine*, 367(19), 1829-1837. DOI:  
[10.1056/NEJMcp1104084](https://doi.org/10.1056/NEJMcp1104084)

#### Copyright

Other than for strictly personal use, it is not permitted to download or to forward/distribute the text or part of it without the consent of the author(s) and/or copyright holder(s), unless the work is under an open content license (like Creative Commons).

#### Take-down policy

If you believe that this document breaches copyright please contact us providing details, and we will remove access to the work immediately and investigate your claim.

*Downloaded from the University of Groningen/UMCG research database (Pure): <http://www.rug.nl/research/portal>. For technical reasons the number of authors shown on this cover page is limited to 10 maximum.*

## CLINICAL PRACTICE

## Hand Eczema

Pieter-Jan Coenraads, M.D.

*This Journal feature begins with a case vignette highlighting a common clinical problem. Evidence supporting various strategies is then presented, followed by a review of formal guidelines, when they exist. The article ends with the author's clinical recommendations.*

**A 33-year-old woman presents with redness of the hands and reports the intermittent occurrence of tiny vesicles, scaling, and fissuring, accompanied by itching on the palms, fingers, and dorsal sides of the hands. She has two young children and works as a nurse in a nearby hospital. She has a history of childhood eczema and a contact allergy to nickel. How should this case be managed?**

## THE CLINICAL PROBLEM

Hand eczema, also called hand dermatitis, is an inflammation of the skin of the hands; some persons with hand eczema may also have foot eczema. Typical clinical signs are redness, infiltration of the skin, scaling, edema, vesicles, areas of hyperkeratosis, cracks (fissures), and erosions (Fig. 1A and 1B).<sup>1</sup> It is common, with a point prevalence of 4% among adults in the general population, and a 1-year prevalence of up to 10%, depending on whether the disease definition includes mild cases.<sup>2</sup> The incidence of work-related cases (which are usually more severe than cases in the general population) that are reported to occupational health authorities is between 0.7 and 1.5 cases per 1000 workers per year, with much higher incidences among certain occupations, such as hairdressing.<sup>3</sup>

Manifestations of hand eczema tend to vary in severity and appearance over time. Cracks and blisters may partially or completely prevent the performance of manual work, resulting in disability and economic loss.<sup>4,5</sup>

The most common external cause of hand eczema is contact with mild toxic agents or irritants (e.g., water and soaps), causing irritant contact dermatitis. Allergic contact dermatitis is less common than irritant contact dermatitis and reflects a contact allergy to a specific substance, such as rubber, nickel, or perfumes. Atopic dermatitis is an endogenous cause of hand eczema; one third to one half of patients with hand eczema may have atopy, and atopy may be manifested exclusively as dermatitis of the hands.<sup>2</sup> In many patients, hand eczema has more than one cause. In addition, there are several types of hand eczema with no known cause (Table 1). These are hyperkeratotic eczema (Fig. 1C), recurrent vesicular hand eczema (pompholyx, dyshidrotic eczema) (Fig. 1D), nummular eczema (Fig. 1E), and pulpitis (chronic fingertip dermatitis) (Fig. 1F). (Additional images are shown in the Supplementary Appendix, available with the full text of this article at NEJM.org.) The terms dyshidrotic eczema and pompholyx are sometimes reserved for acute vesicular hand eczema as opposed to chronic vesicular hand eczema.

## STRATEGIES AND EVIDENCE

## DIAGNOSIS

A thorough patient history is essential to diagnosis, especially with respect to exposure to irritants and allergens at home or at the workplace. The presence of children in the household (with associated exposures to soaps and detergents), occupations

From the Department of Dermatology, University of Groningen, University Medical Center Groningen, Groningen, the Netherlands. Address reprint requests to Dr. Coenraads at the Department of Dermatology, University Medical Center Groningen, P.O. Box 30.001, 9700 RB Groningen, the Netherlands, or at p.j.coenraads@med.umcg.nl.

N Engl J Med 2012;367:1829-37.

DOI: 10.1056/NEJMcp1104084

Copyright © 2012 Massachusetts Medical Society.



An audio version of this article is available at NEJM.org

## KEY CLINICAL POINTS

## HAND ECZEMA

- Prompt intervention is required in patients with hand eczema because it has a tendency to become chronic.
- In most cases, hand eczema reflects a combination of irritant contact dermatitis and endogenous factors (such as atopy), but contact allergy should be ruled out.
- Avoidance of irritants (and allergens, if relevant), frequent application of lipid-rich emollients (ointments), and the use of topical glucocorticoids are first-line treatments, although data from randomized trials on the benefits of these and other treatment options are limited.
- For patients with symptoms that are unresponsive to these initial therapies, options include phototherapy (where available) or oral retinoids (the latter are particularly helpful in patients with hyperkeratotic eczema).
- Oral immunosuppressive agents (usually cyclosporine) are a final resort. Oral glucocorticoids should be used only in short courses to achieve rapid control.

requiring frequent hand washing, and the use of occlusive gloves are recognized risk factors.<sup>12</sup> Contact allergens may be present in domestic and occupational products. A history of atopic dermatitis also predisposes patients to hand eczema.

Hand eczema may be confused with other skin conditions (Table 2), most frequently psoriasis and mycosis. Psoriasis is generally characterized by sharply demarcated lesions, the absence of itching, and the absence of vesicles (Fig. 2A). Hand eczema with infection may be confused with palmoplantar pustulosis, which is regarded by some experts as a variant of psoriasis (Fig. 2B). A skin biopsy of the palm is unlikely to help in distinguishing psoriasis from eczema. Fungal infection (mycosis) should always be ruled out by scraping some flakes for staining or culture, especially if only one hand is affected (Fig. 2C). Figures 2D and 2E show other conditions that mimic hand eczema.

Current classification systems for hand eczema are based on clinical and etiologic factors (Table 1)<sup>6-8</sup> and have been useful for outpatient populations.<sup>13,14</sup> Scoring systems based on the severity of symptoms have been developed but are not routinely used in practice.<sup>15</sup> Cases are classified according to cause when possible, with the acknowledgment that different causes of hand eczema may be indistinguishable on examination. In many cases, the clinician is restricted to a morphologic description.

Additional evaluation (beyond taking a detailed history) should be considered for patients in whom the causes of hand eczema remain undetermined. Patch testing may be useful in identifying a contact allergy to external agents.<sup>10</sup> Both the Amer-

ican Contact Dermatitis Society and the European Society of Contact Dermatitis recommend the use of standard screening trays (a baseline series) that contain the contact allergens that are most commonly found in the home and workplace (e.g., metals, rubber additives, glues, and the antibacterial and antimold agents in cosmetics).<sup>16</sup> Patch testing is recommended in all patients with chronic hand eczema. The sensitivity and specificity of patch testing depend on the patient's history and clinical appearance; according to a retrospective analysis conducted in the United States, expanding the standard number of test allergens would improve the rate of detection of contact allergic reactions from about 25% to about 50%.<sup>17</sup>

Prick testing, or determining allergen-specific IgE levels in the serum, is generally of limited value,<sup>18</sup> although it is informative in cases of protein contact dermatitis (Table 1) or contact urticaria caused by latex proteins or fish proteins (Fig. 2F). Recurrent contact urticaria can become eczematous (e.g., in persons handling food), making clinical diagnosis difficult; in such cases, prick testing can be valuable. Testing for sensitivity to inhalation allergens (e.g., the house-dust mite, cat dander, or pollen) is not recommended, since there is insufficient evidence showing that exposure to such allergens provokes or sustains hand eczema.

## TREATMENT

Although it would seem logical to assume that identifying and eliminating the causative factor could cure hand eczema, this feat is rarely accomplished in practice because the cause of disease, especially in patients with chronic hand eczema,

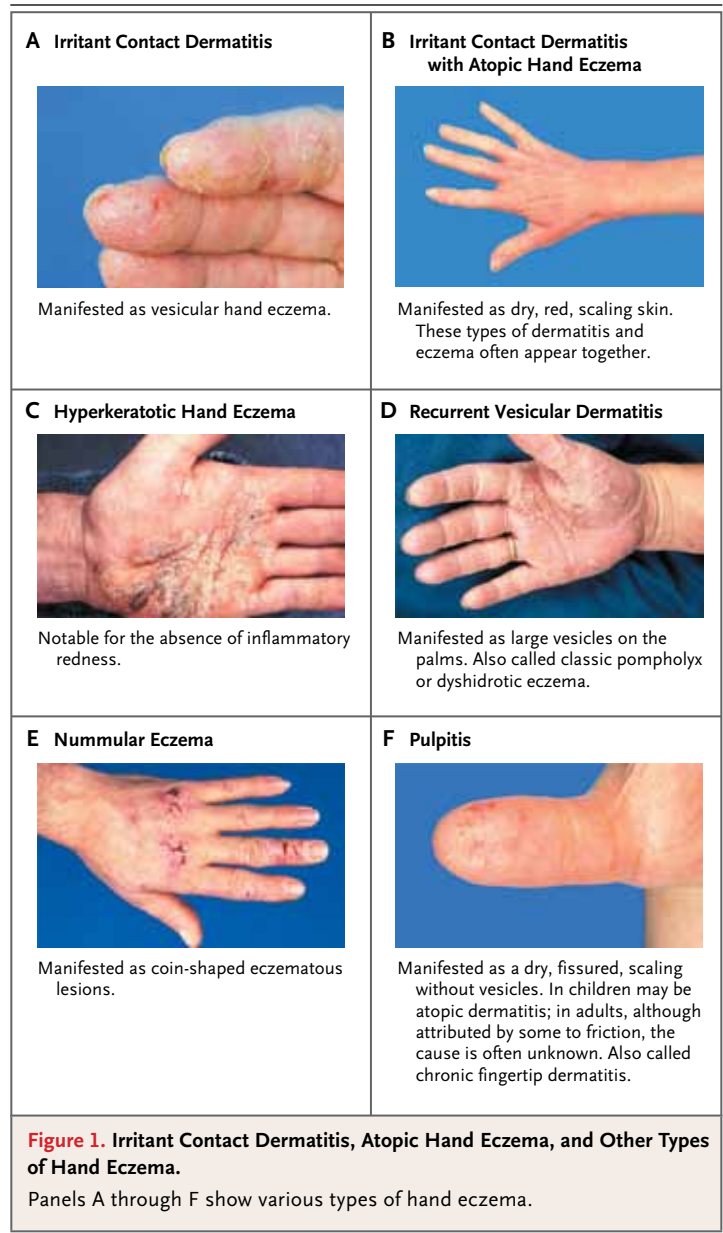
is often multifactorial. Nevertheless, treatment will be unsuccessful if causative or contributing factors are not eliminated.

Prompt treatment is recommended because hand eczema has a tendency to become chronic, in which case resistance to topical treatment is common.<sup>19</sup> Current treatment strategies are largely based on clinical experience and may differ from country to country.<sup>7,8,20</sup> Few therapies have been evaluated in randomized, controlled trials,<sup>21</sup> and the trials that have been conducted typically have not distinguished types of eczema. Figure 3 shows an algorithm for the management of hand eczema.

*Moisturizers, Emollients, and Skin Protection*

The frequent application of emollients and moisturizers is routinely recommended; in many randomized trials of other treatments for hand eczema, the use of emollients was allowed or encouraged in both treatment groups. Ointments are preferred over creams, because creams may contain potentially sensitizing preservatives and mildly irritating emulsifiers. In one small randomized trial that compared the efficacy of two emollients — a petrolatum-based emollient and an emollient containing ceramide (a skin lipid) — there was similar improvement in the two treatment groups at 2 months.<sup>23</sup> Another trial of 2 weeks' duration reported a nonsignificant benefit from the addition of a urea-containing moisturizer to a topical glucocorticoid (betamethasone) as compared with the use of topical betamethasone alone.<sup>24</sup> Barrier creams are often recommended for the prevention of occupational contact dermatitis, but a Cochrane systematic review concluded that there is insufficient evidence that such creams have a long-term protective effect.<sup>25</sup> A more recent trial involving 255 hospital workers with hand eczema showed a benefit from skin-care education and individual counseling.<sup>26</sup> The interventions included oral and written instructions regarding the use of gloves and recommendations on the avoidance of irritants at work and at home.

Job counselors should discourage employees from becoming exposed to irritants at work (especially in “wet work” — e.g., work that involves exposure of the hands to liquids, soaps, detergents, cutting oils, or vegetable juices); counselors should simultaneously encourage adequate skin-protection measures.<sup>27</sup> The role of protective gloves is controversial. Although gloves offer protection from irritants (especially during “wet work”),



prolonged occlusion may itself be a risk factor for hand eczema.<sup>28</sup> In accordance with practical experience and support from an experimental study involving volunteers without hand eczema, a cotton lining or inner glove is recommended.<sup>29</sup>

*Topical Glucocorticoids*

Potent topical glucocorticoids are first-line pharmacologic treatment for hand eczema, although there are limited data from randomized, controlled trials to confirm their efficacy. In an open-label study, topical mometasone furoate was applied freely for up to 9 weeks by patients with hand

**Table 1. Etiologic and Morphologic Classifications of Hand Eczema.\***

Etiologic Classification	Comments
Irritant contact dermatitis	Repeated exposure to irritants (mild toxic agents) over a prolonged period may cause an inflammatory response of the skin, compromising the skin's barrier function and making it susceptible to the development of contact allergy. In most patients there is a history of exposure to "wet" work (contact with soaps or solvents) or prolonged use of occlusive gloves.  There are no clinically useful tests to assess reactions to irritants; diagnosis is often based on the absence of contact allergy, which is determined with the use of patch testing.
Atopic hand dermatitis	Patients often have a history of asthma, hay fever, or "childhood eczema" (atopic dermatitis in childhood).  Both prick testing with inhalation or food allergens and determination of serum IgE levels are of limited value and not routinely recommended.  Because the barrier function of the skin is compromised, patients are predisposed to irritant contact dermatitis.
Allergic contact dermatitis	This condition generally reflects a delayed-type, T-lymphocyte-mediated contact allergy to a chemical substance.  Typical contact allergens include nickel (e.g., in tools or jewelry), chromate (e.g., in leather or cement), rubber additives (e.g., in gloves), and preservatives (e.g., in creams or cosmetics).  Ingestion of a substantial amount of the allergen (e.g., nickel) may also provoke hand eczema, but its occurrence is rare. <sup>9</sup>  Diagnosis is supported by a history of exposure in combination with a positive reaction to patch testing with contact allergens. <sup>10</sup>
Hybrid hand eczema	This type of eczema combines aspects of irritant contact dermatitis, atopic hand dermatitis, and allergic contact dermatitis.
Protein contact dermatitis	This subtype of allergic contact dermatitis frequently occurs in patients in professions involving food. Initially, the reaction to proteins is urticarial (contact urticaria), but eczema may develop. IgE reactions to specific proteins are often (but not always) detected with prick tests or serum analysis. Latex allergy is a related phenomenon.
Unclassified	In patients with chronic hand eczema, the original causative factor tends to become irrelevant.
<b>Morphologic</b>	
Recurrent vesicular, or dysidrotic, hand eczema; pompholyx	The classic presentation is an eruption of large vesicles on the palms that tends to recur; it also includes recurrent vesicular eruptions on the palms and the palmar and lateral sides of the fingers, which is known as macrovesicular eczema (these patients often also have eruptions on the soles of the feet). The name dysidrotic eczema is a misnomer, since the condition is not related to the sweat glands. The cause is unknown. A contact allergic reaction or atopic hand eczema may also be manifested as an identical vesicular eruption; in such cases, etiologic classification is preferable.
Hyperkeratotic hand eczema	Sharply demarcated areas of thick scaling or hyperkeratosis on the palms (and frequently on the soles) is characteristic, as are painful fissures. Vesicles are absent. The condition may be confused with psoriasis, but there is little or none of the redness and none of the scaling or nail changes typical of psoriasis. The condition is more common in middle-aged and elderly persons and in men. The cause is unknown. <sup>11</sup>
Chronic fingertip dermatitis or pulpitis	This condition is characterized by dry, fissured, scaling dermatitis of the fingertips, with occasional episodes of vesicles. On occasion, the cause may be a contact allergy. Although the presentation is mild, this condition may be a considerable handicap for patients who do office work. The cause is unknown.
Nummular hand eczema	This condition is notable for the round, coin-sized eczematous patches that appear on the back of the hands. It may be a manifestation of irritant or allergic contact dermatitis or atopic dermatitis, but often the cause remains unknown.
Dry, fissured hand eczema	Vesicles are absent, and the condition is often a manifestation of chronic hand eczema, irrespective of the cause.

\* Data are from Diepgen et al.,<sup>6</sup> Lynde et al.,<sup>7</sup> and Menné et al.<sup>8</sup>

eczema; almost half of patients had clearing at 3 weeks, and another quarter at 6 weeks. Those who had clearing of eczema then participated in a trial of maintenance therapy for up to 36 weeks. Participants underwent randomization to one of three groups: one in which topical mometasone furoate was applied three times a week, a second in which it was applied two times a week, and a third in which emollients alone were applied freely. Recurrence-free rates were significantly higher in the groups receiving a glucocorticoid (83% and 68%, respectively) than in the group

**Table 2. Differential Diagnosis of Hand Eczema.**

Conditions	Comments
<b>Common conditions with an appearance similar to hand eczema</b>	
Psoriasis	Lesions are dry, scaling, and sharply demarcated, and there is an absence of vesicles. Lesions elsewhere on the body are characteristic. Palmoplantar pustulosis, a variant of psoriasis, should be considered when sterile pustules are present.
Fungus	A fungal infection is especially likely when one hand is more prominently involved. Dry scaling of the palmar creases is characteristic.
<b>Other conditions with an appearance similar to hand eczema</b>	
Lichen planus	Sharply demarcated hyperkeratotic lesions are present. This condition may mimic hyperkeratotic hand eczema.
Scabies	Papules and burrows are present and especially likely to appear in the web spaces of the hands and the volar aspect of the wrists. Itchy papules are often present on the trunk and limbs.
Granuloma annulare	Round or oval patches, with a demarcated raised edge, are characteristic and appear primarily on the dorsal side of the hands.
Herpes simplex	In this condition, there are localized recurrent attacks of clustered vesicles, which are very painful but not itchy.
Self-induced lesions	Self-induced skin lesions are unusual in shape and distribution.
Erythema multiforme, pityriasis rubra pilaris, and dermatomyositis	These conditions are not necessarily confined to the hands. In rare cases, reactive scaling and hyperkeratosis of the palms are associated with cancer or diet.

using emollients only (26%).<sup>30</sup> However, skin atrophy is a risk of prolonged treatment with glucocorticoids. The American Academy of Dermatology recommends daily use for 1 month followed by maintenance therapy two to three times per week.<sup>31</sup> It also recommends ointments over creams.

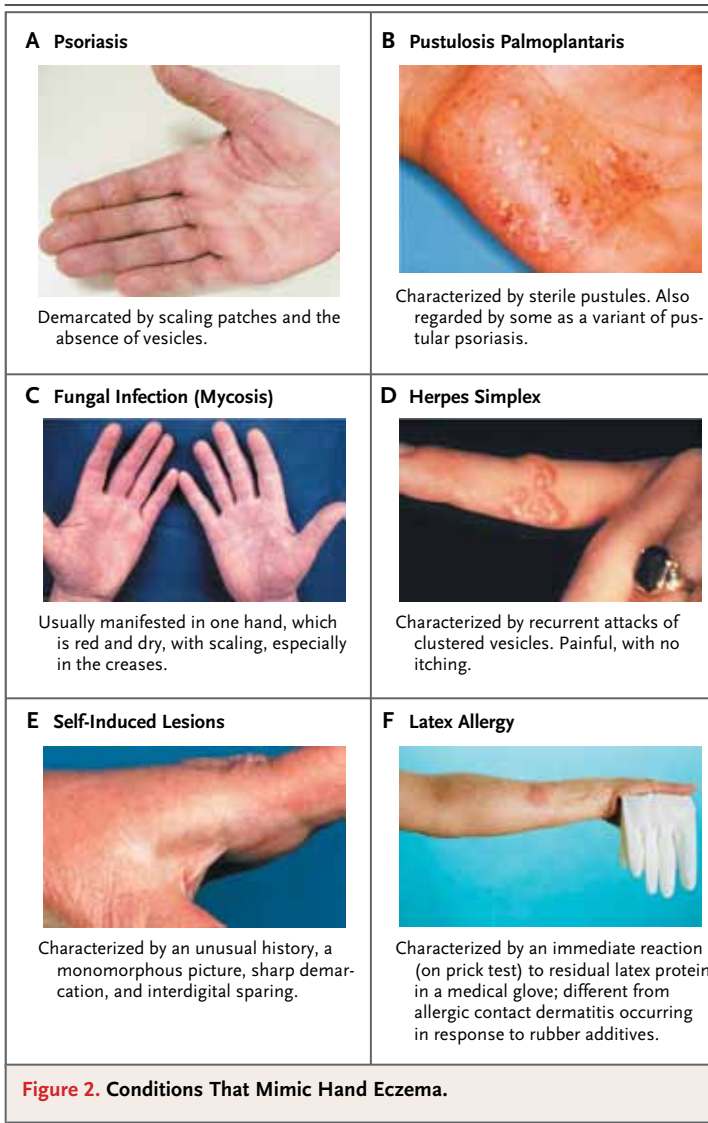
#### *Topical Tacrolimus and Pimecrolimus*

Although topical calcineurin inhibitors have been extensively investigated and are widely used to treat atopic dermatitis, evidence of their efficacy in hand eczema is limited. Side effects include a transient burning sensation and sensitivity to ultraviolet light. Pimecrolimus (applied twice daily) appeared to be slightly but not significantly more efficacious than vehicle cream alone in two large randomized clinical trials of 3 and 6 weeks' duration.<sup>32,33</sup> In a small trial conducted with patients who had chronic dyshidrotic palmar eczema, the administration of tacrolimus 0.1% twice daily resulted in improvement rates of 50% or more, but the rates were not significantly different from those associated with the use of topical mometasone furoate.<sup>34</sup> In another small randomized trial, of 12 weeks' duration, the use of tacrolimus ointment twice daily was compared with the use of vehicle cream alone among patients previously treated with a short course of oral glucocorti-

coids. The use of tacrolimus was associated with greater subjective improvement (as assessed by the patient) but was associated with no clear benefit with regard to other outcomes, including the time to recurrence.<sup>35</sup> In practice, one option is to alternate the use of these agents with topical glucocorticoids.<sup>8,34</sup>

#### *Phototherapy*

Phototherapy is widely used for hand eczema, and in many clinics it is used as second-line treatment for patients in whom topical therapy has failed. In a 12-week trial involving 35 patients, photochemotherapy with psoralen and ultraviolet A (PUVA) was compared with treatment with ultraviolet B (UVB) alone, both in two study groups and within the same patient (comparing a treated hand with an untreated hand). UVB was effective, but PUVA appeared to be more effective.<sup>36</sup> In another small trial involving patients with chronic hand eczema, no significant difference was reported between the use of PUVA and UVB.<sup>37</sup> Nausea (from the tablets of methoxsalen, a derivative of psoralen), edema, and pain are side effects of phototherapy. A long-term concern is the associated increased risk of non-melanoma skin cancer. Instead of administering an oral form of psoralen, many clinics use a top-



ical formulation (a cream, gel, or bath preparation).<sup>38,39</sup> The results of two randomized trials showed no significant difference in efficacy between topical and oral formulations of psoralen.<sup>39,40</sup> On the basis of clinical experience, topical glucocorticoids are often used in combination with phototherapy, especially early in the course of therapy.

#### Oral Retinoids

Oral retinoids may be used for severe chronic hand eczema, in particular the hyperkeratotic subtype. The oral retinoid alitretinoin is approved for severe chronic hand eczema in several European countries and Canada (but not in the United States). In

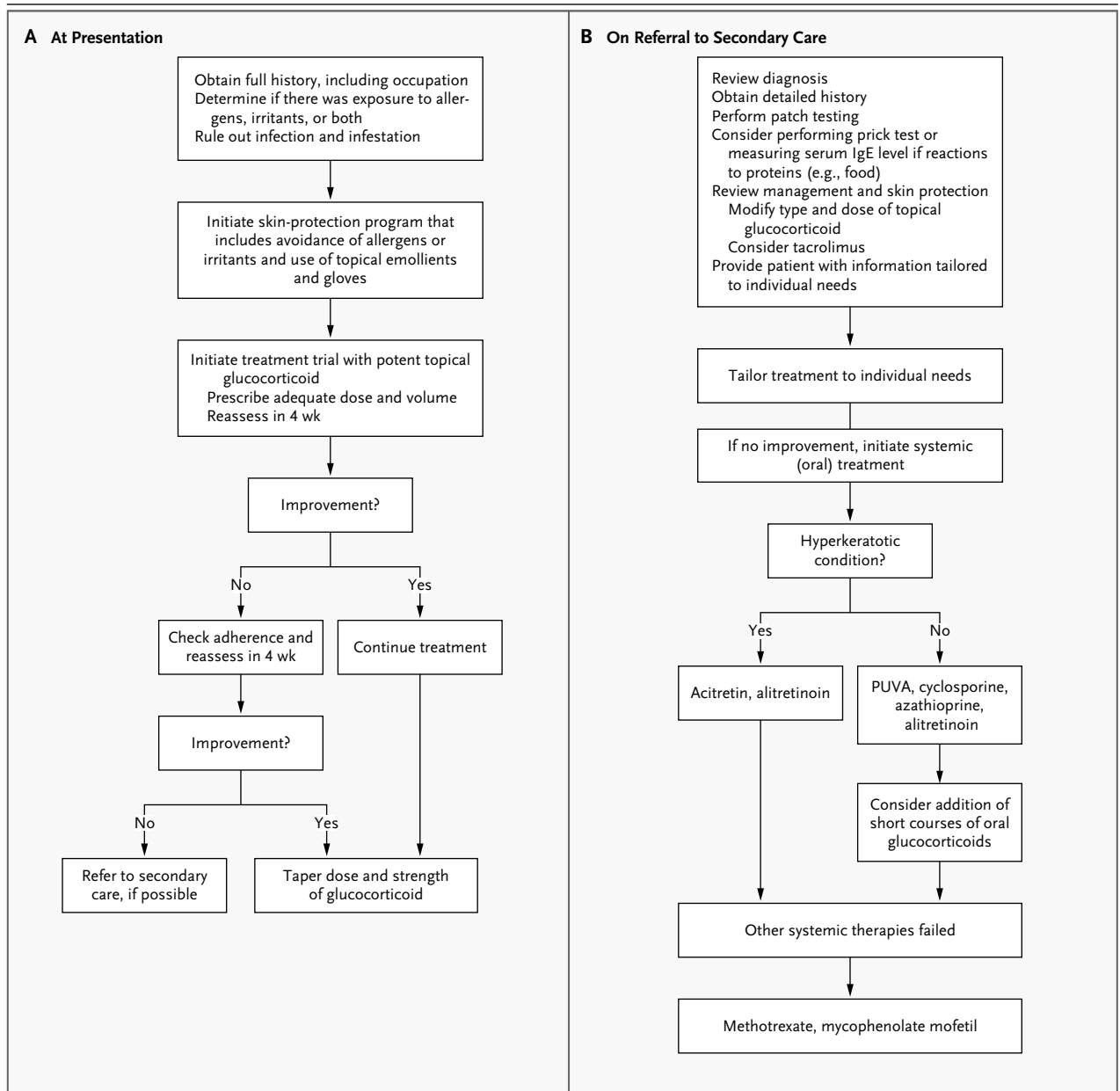
a randomized trial involving 1032 patients with chronic hand eczema (all types) that compared the use of 30 mg of alitretinoin daily, 10 mg of alitretinoin daily, and placebo for up to 24 weeks, the percentages of patients rating their hand eczema as “clear” or “almost clear” at the end of therapy were 40%, 24%, and 15%, respectively.<sup>41</sup> Patients with hyperkeratotic eczema had the highest response rates to alitretinoin, but those with vesicular eczema also appeared to benefit, although formal subgroup comparisons were not performed. The beneficial effects of alitretinoin as compared with placebo were confirmed in a retreatment trial among a subgroup of patients who had had a relapse.<sup>42</sup> Another oral retinoid, acitretin, administered at a dose of 30 mg per day, was also reported to be effective in a small placebo-controlled trial involving patients with the hyperkeratotic variant of hand eczema.<sup>43</sup> However, cross-study comparisons of the benefits of acitretin and alitretinoin are not possible because of differences in the study designs.

Retinoids tend to be preferred over oral immunosuppressive agents given their better safety profile. Common side effects associated with retinoids are dry skin (especially the lips) and an increase in levels of blood lipids. Retinoids are teratogenic, so it is mandatory for women of reproductive age to take measures to prevent pregnancy. Adequate contraceptive agents must be prescribed and a monthly pregnancy test administered; in some countries, signed informed consent is required.

#### Oral Immunosuppressive Agents

Immunosuppressive therapy is administered in patients who have chronic hand eczema that is unresponsive to topical treatment or phototherapy (or retinoids, when their use is appropriate). The use of immunosuppressive agents is based largely on evidence supporting their efficacy in the treatment of atopic dermatitis.<sup>44-46</sup> Cyclosporine is the most frequently used agent. Potential risks include hypertension, decreased kidney function, and sequelae of immunosuppression. The burden of eczema must be weighed against these risks.

Other agents occasionally used in practice include azathioprine, mycophenolate mofetil, and low-dose methotrexate,<sup>46-48</sup> although data from randomized trials are lacking to assess the efficacy of any of these agents in the treatment of



**Figure 3. Management of Hand Eczema.**

Clinical opinion differs with regard to the place of psoralen and ultraviolet A (PUVA) in treatment; it is often used before systemic treatment. Data are from English et al.<sup>22</sup>

hand eczema. Several weeks of azathioprine therapy are generally needed before there is an appreciable clinical response. Short courses of oral glucocorticoids are used in some cases to achieve rapid control. All immunosuppressive agents confer a risk of serious adverse events (hematologic and hepatic toxicity, infections, and other effects of long-term immunosuppressive therapy).

AREAS OF UNCERTAINTY

Once hand eczema becomes chronic, classification may be impossible. A better understanding of clinicopathological features of the different types of hand eczema may improve classification and the choice of therapy. Some progress has been made in the understanding of the role of genetic



and epigenetic changes in skin-barrier function<sup>49</sup>; further research in this area might help to identify patients who may benefit from barrier-strengthening strategies as opposed to anti-inflammatory or immunosuppressive treatment.

Additional data from randomized trials are needed to assess and compare the various therapies used for chronic hand eczema. More data are needed to inform the role of alitretinoin in the treatment of vesicular hand eczema.

## GUIDELINES

Guidelines have been published by professional medical societies in a few countries, including Denmark and Germany.<sup>8,20</sup> In addition, there is a consensus statement from the United Kingdom<sup>22</sup> and a guideline from a Canadian group of experts.<sup>7</sup> The American Academy of Dermatology has published guidelines on the use of topical glucocorticoids, the mainstay of treatment for hand eczema.<sup>31</sup> A British guideline on phototherapy includes a comment on the use of phototherapy in hand eczema.<sup>38</sup> The recommendations presented here are largely consistent with these guidelines and consensus statements.

## CONCLUSIONS AND RECOMMENDATIONS

The patient described in the vignette has vesicular-type atopic hand eczema. Her household, which includes small children, and her job as a nurse, which requires frequent hand washing and the use of occlusive gloves, are sources of continued exposure to irritants. Patch testing is recommend-

ed to rule out contact allergy to rubber components in medical gloves and to preservatives in liquid cleansers. Contact allergy to nickel, diagnosed by means of patch testing, is often observed in women, but its relevance to the cause of this patient's hand eczema is uncertain. Prick testing is not necessary.

Patients such as the one described should be counseled to avoid — or at least dramatically reduce — exposure to irritants (and contact allergens, when detected by patch testing) and should inform their employer of the recommendations. For this patient, I would recommend the use of impermeable gloves with a cotton lining when performing “wet” tasks. Frequent application of emollients (preferably ointments) is an essential part of management, in combination with application of potent topical glucocorticoids once or twice daily for at least 4 weeks. If topical glucocorticoids are not effective and the patient has access to PUVA treatment, I would recommend a course of PUVA combined with topical glucocorticoids. A short course (1 week) of oral glucocorticoids may be needed to achieve rapid control; long-term use is not recommended, given the adverse effects. For severe cases of hand eczema that are unresponsive to topical therapy or PUVA, oral cyclosporine may be considered. Other immunosuppressive agents are also an option, although they are used less frequently.

Dr. Coenraads reports receiving consulting fees from HEAP Research, Astellas Pharma, Basilea Pharmaceutica, and Procter & Gamble, grant support to his institution from Basilea Pharmaceutica, and lecture fees from GlaxoSmithKline. No other potential conflict of interest relevant to this article was reported.

Disclosure forms provided by the author are available with the full text of this article at NEJM.org.

## REFERENCES

1. Veien NK, Hattel T, Laurberg G. Hand eczema: causes, course, and prognosis II. *Contact Dermatitis* 2008;58:335-9.
2. Thyssen JP, Johansen JD, Linneberg A, Menne T. The epidemiology of hand eczema in the general population — prevalence and main findings. *Contact Dermatitis* 2010;62:75-87.
3. Diepgen TL. Occupational skin-disease data in Europe. *Int Arch Occup Environ Health* 2003;76:331-8.
4. Holness DL, Nethercott JR. Work outcome in workers with occupational skin disease. *Am J Ind Med* 1995;27:807-15.
5. Moberg C, Alderling M, Meding B. Hand eczema and quality of life: a population-based study. *Br J Dermatol* 2009;161:397-403.
6. Diepgen TL, Andersen KE, Brandao FM, et al. Hand eczema classification: a cross-sectional, multicentre study of the aetiology and morphology of hand eczema. *Br J Dermatol* 2009;160:353-8.
7. Lynde C, Guenther L, Diepgen TL, et al. Canadian hand dermatitis management guidelines. *J Cutan Med Surg* 2010;14:267-84. [Erratum, *J Cutan Med Surg* 2011;15:360.]
8. Menné T, Johansen JD, Sommerlund M, Veien NK. Hand eczema guidelines based on the Danish guidelines for the diagnosis and treatment of hand eczema. *Contact Dermatitis* 2011;65:3-12.
9. Jensen CS, Menné T, Johansen JD. Systemic contact dermatitis after oral exposure to nickel: a review with a modified meta-analysis. *Contact Dermatitis* 2006;54:79-86.
10. Belsito DV. Patch testing with a standard allergen (“screening”) tray: rewards and risks. *Dermatol Ther* 2004;17:231-9.
11. Hersle K, Mobacken H. Hyperkeratotic dermatitis of the palms. *Br J Dermatol* 1982;107:195-201.
12. Nilsson E, Mikaelsson B, Andersson S. Atopy, occupation and domestic work as risk factors for hand eczema in hospital workers. *Contact Dermatitis* 1985;13:216-23.
13. Johansen JD, Hald M, Andersen BL, et al. Classification of hand eczema: clinical and aetiological types: based on the guideline of the Danish Contact Dermatitis Group. *Contact Dermatitis* 2011;65:13-21.

14. Molin S, Diepgen TL, Ruzicka T, Prinz JC. Diagnosing chronic hand eczema by an algorithm: a tool for classification in clinical practice. *Clin Exp Dermatol* 2011; 36:595-601.
15. Weistenhöfer W, Baumeister T, Drexler H, Kütting B. An overview of skin scores used for quantifying hand eczema: a critical update according to the criteria of evidence-based medicine. *Br J Dermatol* 2010;162:239-50.
16. Alikhan A, Cheng LS, Ale I, et al. Revised minimal baseline series of the International Contact Dermatitis Research Group: evidence-based approach. *Dermatitis* 2011;22:121-2.
17. Saripalli YV, Achen E, Belsito DV. The detection of clinically relevant contact allergens using a standard screening tray of twenty-three allergens. *J Am Acad Dermatol* 2003;49:65-9.
18. Flohr C, Johansson SG, Wahlgren CF, Williams H. How atopic is atopic dermatitis? *J Allergy Clin Immunol* 2004; 114:150-8.
19. Hald M, Agner T, Blands J, et al. Clinical severity and prognosis of hand eczema. *Br J Dermatol* 2009;160:1229-36.
20. Diepgen TL, Elsner P, Schliemann S, et al. Guideline on the management of hand eczema ICD-10 code: L20, L23, L24, L25, L30. *J Dtsch Dermatol Ges* 2009;7: Suppl 3:S1-S16.
21. Van Coevorden AM, Coenraads PJ, Svensson A, et al. Overview of studies of treatments for hand eczema — the EDEN hand eczema survey. *Br J Dermatol* 2004; 151:446-51.
22. English J, Aldridge R, Gawkrödger DJ, et al. Consensus statement on the management of chronic hand eczema. *Clin Exp Dermatol* 2009;34:761-9.
23. Kucharekova M, Van De Kerkhof PC, Van Der Valk PG. A randomized comparison of an emollient containing skin-related lipids with a petrolatum-based emollient as adjunct in the treatment of chronic hand dermatitis. *Contact Dermatitis* 2003;48:293-9.
24. Lodén M, Wirén K, Smerud KT, et al. The effect of a corticosteroid cream and a barrier-strengthening moisturizer in hand eczema: a double-blind, randomized, prospective, parallel group clinical trial. *J Eur Acad Dermatol Venereol* 2012;26:597-601.
25. Bauer A, Schmitt J, Bennett C, et al. Interventions for preventing occupational irritant hand dermatitis. *Cochrane Database Syst Rev* 2010;6:CD004414.
26. Ibler KS, Agner T, Hansen JL, Glud C. The Hand Eczema Trial (HET): design of a randomised clinical trial of the effect of classification and individual counseling versus no intervention among health-care workers with hand eczema. *BMC Dermatol Pub Med* 2010;10:8-18.
27. Work healthy: asthma, eczema and your career. Stockholm: Karolinska Institutet School of Public Health, 2010 (<http://www.jobbafrisk.se/english>).
28. Kwon S, Campbell LS, Zirwas MJ. Role of protective gloves in the causation and treatment of occupational irritant contact dermatitis. *J Am Acad Dermatol* 2006;55:891-6.
29. Ramsing DW, Agner T. Effect of glove occlusion on human skin (II): long-term experimental exposure. *Contact Dermatitis* 1996;34:258-62.
30. Veien NK, Olholm Larsen P, Thestrup-Pedersen K, Schou G. Long-term, intermittent treatment of chronic hand eczema with mometasone furoate. *Br J Dermatol* 1999;140:882-6.
31. Drake LA, Dinehart SM, Farmer ER, et al. Guidelines of care for the use of topical glucocorticosteroids. *J Am Acad Dermatol* 1996;35:615-9.
32. Belsito DV, Fowler JF Jr, Marks JG Jr, et al. Pimecrolimus cream 1%: a potential new treatment for chronic hand dermatitis. *Cutis* 2004;73:31-8.
33. Hordinsky M, Fleischer A, Rivers JK, Poulin Y, Belsito D, Hultsch T. Efficacy and safety of pimecrolimus cream 1% in mild-to-moderate chronic hand dermatitis: a randomized, double-blind trial. *Dermatology* 2010;221:71-7.
34. Schnopp C, Remling R, Möhrenschrager M, Weigl L, Ring J, Abeck D. Topical tacrolimus (FK506) and mometasone furoate in treatment of dyshidrotic palmar eczema: a randomized, observer-blinded trial. *J Am Acad Dermatol* 2002; 46:73-7.
35. Krejci-Manwaring J, McCarty MA, Camacho F, et al. Topical tacrolimus 0.1% improves symptoms of hand dermatitis in patients treated with a prednisone taper. *J Drugs Dermatol* 2008;7:643-6.
36. Rosén K, Mobacken H, Swanbeck G. Chronic eczematous dermatitis of the hands: a comparison of PUVA and UVB treatment. *Acta Derm Venereol* 1987;67: 48-54.
37. Sezer E, Etikan I. Local narrowband UVB phototherapy vs. local PUVA in the treatment of chronic hand eczema. *Photodermatol Photoimmunol Photomed* 2007; 23:10-4.
38. Halpern SM, Anstey AV, Dawe RS, et al. Guidelines for topical PUVA: a report of a workshop of the British Photodermatology Group. *Br J Dermatol* 2000;142:22-31.
39. van Coevorden AM, Kamphof WG, van Sonderen E, Bruynzeel DP, Coenraads PJ. Comparison of oral psoralen-UV-A with a portable tanning unit at home vs hospital-administered bath psoralen-UV-A in patients with chronic hand eczema: an open-label randomized controlled trial of efficacy. *Arch Dermatol* 2004;140:1463-6.
40. Tzaneva S, Kittler H, Thallinger C, Honigsmann H, Tanew A. Oral vs. bath PUVA using 8-methoxypsoralen for chronic palmoplantar eczema. *Photodermatol Photoimmunol Photomed* 2009;25:101-5.
41. Ruzicka T, Lynde CW, Jemec GB, et al. Efficacy and safety of oral alitretinoin (9-cis retinoic acid) in patients with severe chronic hand eczema refractory to topical corticosteroids: results of a randomized, double-blind, placebo-controlled, multi-centre trial. *Br J Dermatol* 2008;158:808-17.
42. Bissonnette R, Worm M, Gerlach B, et al. Successful retreatment with alitretinoin in patients with relapsed chronic hand eczema. *Br J Dermatol* 2010;162:420-6.
43. Thestrup-Pedersen K, Andersen KE, Menné T, Veien NK. Treatment of hyperkeratotic dermatitis of the palms (eczema keratoticum) with oral acitretin: a single-blind placebo-controlled study. *Acta Derm Venereol* 2001;81:353-5.
44. Hughes R, Collins P, Rogers S. Further experience of using azathioprine in the treatment of severe atopic dermatitis. *Clin Exp Dermatol* 2008;33:710-1.
45. Schmitt J, Schmitt N, Meurer M. Cyclosporin in the treatment of patients with atopic eczema — a systematic review and meta-analysis. *J Eur Acad Dermatol Venereol* 2007;21:606-19.
46. Murray ML, Cohen JB. Mycophenolate mofetil therapy for moderate to severe atopic dermatitis. *Clin Exp Dermatol* 2007;32:23-7.
47. Granlund H, Erkko P, Eriksson E, Reitamo S. Comparison of cyclosporine and topical betamethasone-17,21-dipropionate in the treatment of severe chronic hand eczema. *Acta Derm Venereol* 1996; 76:371-6.
48. Egan CA, Rallis TM, Meadows KP, Krueger GG. Low-dose oral methotrexate treatment for recalcitrant palmoplantar pompholyx. *J Am Acad Dermatol* 1999; 40:612-4.
49. Kaae J, Menné T, Carlsen BC, Zachariae C, Thyssen JP. The hands in health and disease of individuals with filaggrin loss-of-function mutations: clinical reflections on the hand eczema phenotype. *Contact Dermatitis* 2012;67:119-24.

Copyright © 2012 Massachusetts Medical Society.