

University of Groningen

Mandibular Overdentures Supported by 6-mm Dental Implants

Gulje, Felix; Raghoobar, Gerry; Ter Meulen, Jan-Willem P.; Vissink, Arjan; Meijer, Hendrikus; Guljé, Felix

Published in:
Clinical Implant Dentistry and Related Research

DOI:
[10.1111/j.1708-8208.2011.00358.x](https://doi.org/10.1111/j.1708-8208.2011.00358.x)

IMPORTANT NOTE: You are advised to consult the publisher's version (publisher's PDF) if you wish to cite from it. Please check the document version below.

Document Version
Publisher's PDF, also known as Version of record

Publication date:
2012

[Link to publication in University of Groningen/UMCG research database](#)

Citation for published version (APA):

Gulje, F., Raghoobar, G. M., Ter Meulen, J-W. P., Vissink, A., Meijer, H. J. A., & Guljé, F. (2012). Mandibular Overdentures Supported by 6-mm Dental Implants: A 1-Year Prospective Cohort Study. *Clinical Implant Dentistry and Related Research*, 14(1), e59-e66. DOI: 10.1111/j.1708-8208.2011.00358.x

Copyright

Other than for strictly personal use, it is not permitted to download or to forward/distribute the text or part of it without the consent of the author(s) and/or copyright holder(s), unless the work is under an open content license (like Creative Commons).

Take-down policy

If you believe that this document breaches copyright please contact us providing details, and we will remove access to the work immediately and investigate your claim.

Downloaded from the University of Groningen/UMCG research database (Pure): <http://www.rug.nl/research/portal>. For technical reasons the number of authors shown on this cover page is limited to 10 maximum.

Mandibular Overdentures Supported by 6-mm Dental Implants: A 1-Year Prospective Cohort Study

Felix Guljé, DDS;* Gerry M. Raghoebar, DDS, MD, PhD;† Jan-Willem P. Ter Meulen, DDS;‡
Arjan Vissink, DDS, MD, PhD;† Henny J. A. Meijer, DDS, PhD§

ABSTRACT

Background: The extremely resorbed edentulous mandible, with a bone height of 8 mm or less, is still a challenge in implant dentistry. Recently, dental implants of 6 mm in length have been developed.

Purpose: The purpose of this 1-year prospective cohort study was to evaluate treatment outcome of mandibular overdentures supported by four 6-mm dental implants.

Materials and Methods: Twelve edentulous patients with a mandibular height between 6 and 8 mm participated. The patients were treated with an overdenture supported by four 6-mm OsseoSpeed™ dental implants (Astra Tech AB, Mölndal, Sweden). Clinical and radiographic parameters were evaluated 1 year after completion of the prosthetic treatment. Patients' satisfaction was scored before implant surgery and 1 year after prosthetic treatment.

Results: One-year implant survival rate was 96% (two implants were lost). One patient had a fracture of the mandible in the region of one of the implants 3 weeks after implant surgery. Mean scores for plaque, calculus, gingiva, bleeding, and pocket probing depth were low. Patients' satisfaction was high.

Conclusion: One-year follow-up data revealed that four 6-mm dental implants inserted in an extremely resorbed edentulous mandible provided a solid basis for a bar-retained overdenture.

KEY WORDS: edentulous mandible, extreme resorption, overdenture, prospective study, short dental implants

INTRODUCTION

Edentulous patients often experience problems with their mandibular complete dentures. Lack of stability

and retention of their mandibular denture, together with a decreased chewing ability are the main complaints of these patients.¹ A frequently used treatment possibility to solve lower denture problems is to place endosseous implants in the mandible to support an overdenture. One of the first studies concerning overdentures supported by endosseous implants was published by Engquist et al. in 1988.² After two decades, this treatment is still of great value in the rehabilitation of edentulous patients.^{3–6} The survival rate of implants, either placed as a one- or two-stage procedure, applied to support a mandibular overdenture in a moderately resorbed edentulous mandible (class IV–VI resorption of the mandible⁷), has been shown to be successful in over 95% of all cases in studies with a 5–10-year follow-up.^{5,8–13} For general application in the edentulous mandible, a treatment concept utilizing two dental implants to support a mandibular overdenture has been proposed as the first treatment of choice.¹⁴

However, whether short implants (<10 mm) can be used in the extremely resorbed mandible or whether a reconstructive surgical augmentation procedure to facilitate placement of implants of standard length

*Research associate, Department of Oral and Maxillofacial Surgery, University Medical Center Groningen, Groningen, the Netherlands and Center for Dental Implants De Mondhoek, Apeldoorn, the Netherlands; †professor, Department of Oral and Maxillofacial Surgery, University Medical Center Groningen, University of Groningen, Groningen, the Netherlands; ‡research associate, Center for Dental Implants, Ulft, the Netherlands; §professor, Department of Oral and Maxillofacial Surgery, University Medical Center Groningen, University of Groningen, Groningen, the Netherlands and Department of Fixed and Removable Prosthodontics, Dental School, University Medical Center Groningen, University of Groningen, Groningen, the Netherlands

Reprint requests: Prof. Dr. Henny J. A. Meijer, Department of Oral and Maxillofacial Surgery, University Medical Center Groningen, PO Box 30.001, NL-9700 RB Groningen, The Netherlands; e-mail: h.j.a.meijer@kchir.umcg.nl

Conflict of interest and sources of funding statement: The authors declare that there are no conflicts of interest in this study. No external funding was obtained.

© 2011 Wiley Periodicals, Inc.

DOI 10.1111/j.1708-8208.2011.00358.x

(≥ 10 mm) has the preference in the rehabilitation of these patients, is still subject of discussion in the literature.^{15,16} If treatment outcome is the same for both mentioned treatment options, short implants should be considered as favorable, because the advanced bone augmentation procedure involves higher morbidity and requires higher costs to the patient.^{17,18}

Several authors have given an overview of the literature on the use of short implants in the prosthodontic rehabilitation of variety of conditions.^{16,18–22} Unfortunately, these studies do not differentiate between the locations of the implants, fully or partially edentulous, or the type of superstructure. Renouard and Nissand²¹ performed a structured review about the impact of implant length and diameter on survival rates in fully and partially edentulous patients and demonstrated a trend for an increased failure rate with short implants. Two recent reviews have been published in which short implants were compared with standard implants. Kotsovilis et al.¹⁶ concluded that the placement of short (≤ 8 or < 10 mm) rough-surface implants is not a less efficacious treatment modality compared to the treatment of standard (≥ 10 mm) rough-surface implants. Romeo et al.²² concluded that recent literature has demonstrated a similar survival rate for short and standard implants. Vercruyssen et al.²³ performed a retrospective analysis on the long-term (5–25 years) outcome of two implants supporting an overdenture in the mandible, as well as the significance of some confounding factors (smoking, implant length, bone quality). Some of the implants in the study had a length of 8.5 or 7 mm. Analysis for subgroups showed that implant length had no impact on the cumulative failure rate. Finally, in a randomized clinical trial, Stellingsma et al.¹⁷ compared three treatment options for support of an overdenture in the extremely resorbed mandible, being a transmandibular implant, augmentation of the mandible with an autologous bone graft followed by four standard implants, and the placement of four short implants. After 2 years of evaluation, no implants were lost in the short-implants group and the authors concluded that placement of short implants is the most favorable treatment option. However, inclusion criterion for bone height in this study was up to 12 mm and 8- or 11-mm implants were placed, as these were considered as short implants those days. Nowadays, a bone height of 11 and 12 mm is not considered as extremely resorbed, and 11 mm implants are not considered as short.

In recent years, dental implants have become available in decreasing length up to 7 and 6 mm. To our knowledge, there has never been a prospective study published focusing on extremely resorbed edentulous mandibles and the use of short implants to support an overdenture. The purpose of this 1-year prospective cohort study was to assess the treatment outcome (survival of implants, surgical complications, condition of hard and soft peri-implant tissues, and patient satisfaction) of mandibular overdentures supported by four 6-mm dental implants.

MATERIALS AND METHODS

Patient Selection

Between July 2008 and July 2009, 12 consecutive patients were selected with an extremely resorbed edentulous mandible in two Centers for Dental Implants (Apeldoorn and Ulft, the Netherlands). The patients had been referred by their general dental practitioner to one of the centers. All patients were suffering from reduced stability and insufficient retention of their mandibular denture. Inclusion criteria for the study were an edentulous period of at least 2 years, class VII–VIII resorption of the mandible,⁷ and being edentulous in the upper jaw. The mandibular height and width was measured on a lateral cephalometric radiograph: height had to be between 6 and 8 mm, and width had to be at least 6 mm in the mandibular symphysis region. Excluded were patients with an abundance amount of soft tissue on the lingual and buccal side of the interforaminal region. Patients with a history of radiotherapy in the head and neck region, or a history of preprosthetic surgery or previous implant placement were also excluded. The patients were informed about the treatment option of placing four short implants instead of an augmentation procedure with bone of the iliac crest and inserting four standard implants. All patients agreed and written informed consent was obtained. The jawbone quality was scored according to the classification of Lekholm and Zarb.²⁴ The baseline characteristics of the group are summarized in Table 1.

Treatment Procedure

Incision was made approximately 5 mm from the top of the alveolar process in the buccal fold and extended laterally to the top of the crest. After reflection of the mucoperiosteum, the mental foramina were identified. The most lateral implants were placed bicortically at

TABLE 1 Baseline Characteristics of Study Group (*n* = 12)

Mean age in years (SD, range)	68.1 (8.8, 52–80)
Gender (number male/female)	2/10
Mean edentulous period lower jaw in years (SD)	37.3 (20.6)
Mean mandibular bone height in mm (SD)	7.2 (0.8)
Mean bone quality (possible score 1–4) (SD)	1.7 (0.5)

SD = standard deviation.

least 5 mm anterior to the mental foramen, and there was an equal distance between the four implants. The implants used were OsseoSpeed™ 4.0 S dental implants with a length of 6 mm and a diameter of 4 mm (Astra Tech AB, Mölndal, Sweden). Thinning of the mucosa took place and the flap was sutured in the depth of the buccal sulcus. Postoperative analgesics and chlorhexidine 0.2% mouth rinse were prescribed; antibiotics were not prescribed. Patients were not allowed to wear the lower denture during the first 2 weeks after surgery, and then the lower denture was adjusted and relined with a soft relining material (Coe-Soft, Coe Laboratories Inc., Chicago, IL, USA). Three months after insertion of the implants, the second stage of the surgery was performed under local anesthesia by the same surgeon. Uni Healing Abutments of 4 mm in length were used (Astra Tech AB). The lower denture was adjusted again.

Two weeks after abutment connection, the prosthodontic treatment was started. The prosthodontic treatment was performed by the patients' general dental practitioner according to a standardized protocol. The healing abutments were replaced by 20-degree Uni Abutments (Astra Tech AB). The implants were connected by an egg-shaped titanium bar with gold clip attachments in the overdenture. All patients received a new upper denture and an overdenture for the lower jaw. Two weeks after abutment connection, a standardized oral hygiene program was started, with frequent recall visits to optimize the individual oral hygiene (Figures 1–4).

Analysis

Outcome measures were implant survival and the change of peri-implant bone-level from surgery to 12 months follow-up. Next to this, soft tissue conditions

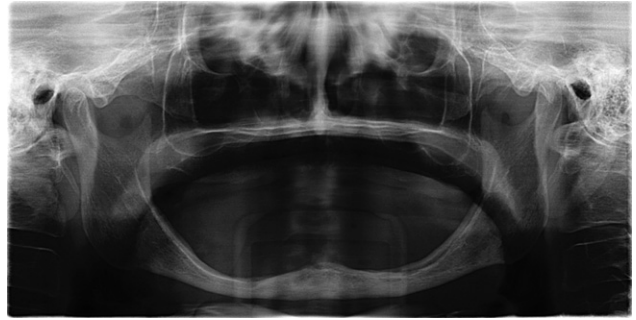


Figure 1 Baseline panoramic radiograph of a patient with extreme resorption of the edentulous mandible.

(plaque index, presence of calculus, gingiva index, sulcus bleeding index, and pocket probing depth) were scored 12 months after placement of the prosthesis and differences in patients' satisfaction between before treatment and 12 months after placement of the prosthesis.

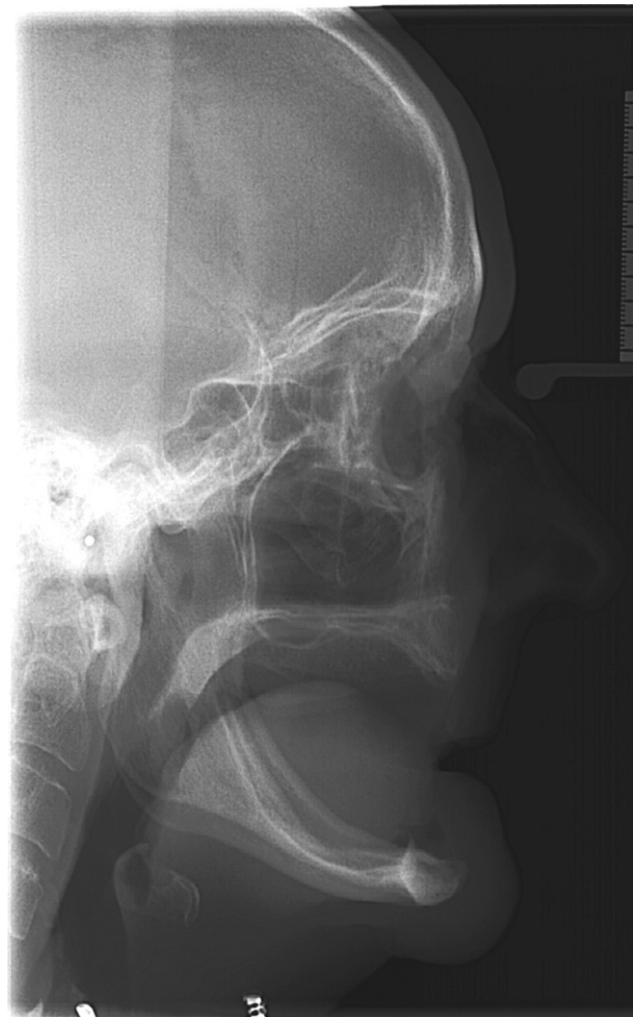

Figure 2 Baseline lateral cephalometric radiograph of the same patient as in Figure 1.

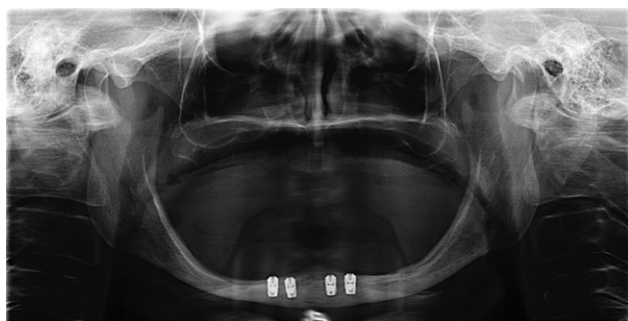

Figure 3 Panoramic radiograph of the same patient as in Figure 1 after insertion of four 6-mm implants in the interforaminal region of the mandible.

Loose and lost implants were scored any time after placement. Standardized panoramic radiographs (Center Apeldoorn: Orthopantomograph OC200D, Instrumentarium Dental, Tuusula, Finland, and Center Ulft: Sirona Orthophos, Sirona Dental Services GmbH, Bensheim, Germany) were taken just after surgery and 12 months after placement of the prosthesis and evaluated at the Medical University Center Groningen (Groningen, the Netherlands). The digital panoramic images were analyzed using a computer software to perform linear measurements on digital radiographs. The known implant length was used as a reference to transform the linear measurements into millimeter. Reference line for bone level evaluation was the outer border of the neck of the implant. Mesial and distal bone changes in this region were considered as peri-implant bone change and were defined as the difference in bone height between the photograph taken after surgery and the photograph taken 12 months after placement of the prosthesis.

For presence of plaque, the index according to Mombelli et al.²⁵ was used (score 0: no detection of plaque;

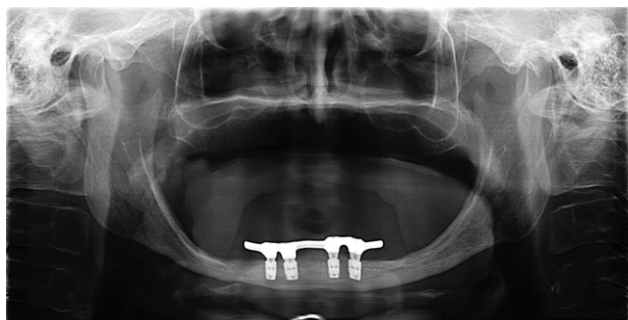

Figure 4 Panoramic radiograph of the same patient as in Figure 1 with bar-supported overdenture 1 year in function.

score 1: plaque can be detected by running a probe across the smooth marginal surface of the abutment and implant; score 2: plaque can be seen by the naked eye; score 3: abundance amount of plaque). The presence of calculus (score 1) or the absence of calculus (score 0) was scored. To qualify the degree of peri-implant inflammation, the modified Loe and Silness index²⁶ was used (score 0: normal peri-implant mucosa; score 1: mild inflammation, slight change in color, slight edema; score 2: moderate inflammation, redness, edema, and glazing; score 3: severe inflammation, marked redness, edema, and ulceration). For bleeding, the bleeding index according to Mombelli et al.²⁵ was used (score 0: no bleeding when using a periodontal probe; score 1: isolated bleeding spots visible; score 2: a confluent red line of blood along the mucosa margin; score 3: heavy or profuse bleeding). Probing depth was measured at four sites of each implant (mesially, labially, distally, lingually) by using a periodontal probe (Merit B, Hu Friedy, Chicago, IL, USA) after removal of the bar; the distance between the marginal border of the mucosa and the tip of the periodontal probe was scored as the probing depth.

Patients' satisfaction with their full denture was assessed using a validated questionnaire.²⁷ This questionnaire focused on complaints and consisted of 54 items. It was divided into six scales:

- A. Nine items concerning functional problems of the lower denture;
- B. Nine items concerning functional problems of the upper denture;
- C. Eighteen items concerning functional problems complaints in general;
- D. Three items concerning facial aesthetics;
- E. Three items concerning accidental lip, cheek, and tongue biting ("neutral space"); and
- F. Twelve items concerning aesthetics of the denture.

The extent of each specific complaint could be expressed on a four-point rating scale (0 = no complaints; 1 = little; 2 = moderate; 3 = severe complaints). The patient's overall denture satisfaction was expressed on a 10-point rating scale (1 = very bad to 10 = excellent). Patient satisfaction was scored before implant treatment and 12 months after placement of the prosthesis.

Surgical and prosthetic complications were scored from the day of surgery to the 12 months' evaluation visit.

Data Collection and Statistical Analysis

Data collection and analysis of the radiographs was done by the same observer. The worst score per implant of the clinical and radiographic parameters were used in the data analysis. Survival was presented at implant level. Differences between evaluation periods were tested with a paired Student's *t*-test. In all tests, a significance level of 0.05 was chosen. Analysis was done with PASW Statistics 18.0 (SPSS Inc. An IBM Company, IBM Corporation, Chicago, IL, USA).

RESULTS

All patients completed the 1-year evaluation period. Two implants were lost, both during the healing phase. In one patient, there was no primary stability of one of the implants after insertion. The implant was left in place, but 2 weeks after surgery, the patient complained about continuous pain in the same region as the implant without stability. It was decided to remove the implant without replacement. The site healed uneventful without complications or pain. In a second case, a patient complained about pain in the mandible 3 weeks after implant surgery. A radiograph was taken and this revealed a fracture of the mandible, without dislocation, in the region of one of the lateral implants. Examination showed no mobility of the mandible at the fracture sites and no wound dehiscence could be detected. There was an undisturbed sensibility in the lower lip. It was decided to prescribe antibiotics (amoxicillin 500 mg, three times daily for 7 days) and to follow a conservative treatment policy. The patient was instructed not to wear the conventional lower denture and a soft diet was advised. The pain disappeared, the fracture healed, but the implant at the fractured site appeared to be mobile at the second-stage operation procedure. It was decided to remove the implant without replacement. The titanium bar was connected to the remaining three implants. No other surgical complications occurred up to 1 year after placement of the prosthesis. In none of the patients did postsurgical sensory disturbances of the mental nerve occurred. One-year survival rate of the implants was 96%. The mean scores of the indices for plaque, calculus, gingival, and bleeding were very low (Table 2). The mean probing depth (Table 2) was 3.4 mm at the 1-year evaluation period. The mean loss of marginal bone between baseline and the 1-year evaluation was 0.1 mm (SD 0.3, range = 0.54 measured bone gain to 0.88

TABLE 2 Mean Values, Standard Deviation, and Range of Plaque-Index (possible score 0–3), Calculus-Index (possible score 0–1), Gingival-Index (possible score 0–3), Bleeding-Index (possible score 0–3), and Probing Depth in mm at 1 Year After Placement of the Overdenture

	Mean (SD), range
Plaque-index	1.4 (0.6), 0–2
Calculus-index	0.4 (0.4), 0–1
Gingival-index	0.5 (0.5), 0–2
Bleeding-index	0.6 (0.4), 0–2
Probing depth in mm	3.4 (1.3), 2–6

SD = standard deviation.

measured bone loss). Mean scores of the six scales of the questionnaire focusing on the complaints of the patients, together with the overall satisfaction score, are listed in Table 3. The functional complaints related to the lower denture had significantly improved at the 1-year evaluation ($p < .001$). Also, the other five scales and the overall satisfaction score (from 5.8 to 9.0; $p < .001$) showed significant improvements between the pretreatment and the posttreatment assessment.

DISCUSSION

This study showed that four short implants placed in the interforaminal region, connected with a bar, supply a proper base for the support of a mandibular overdenture in case of the prosthodontic rehabilitation of the extremely resorbed edentulous mandible. The 1-year implant survival rate was 96%. This percentage is comparable with other short-term prospective studies on the use of four implants to support a mandibular overdenture.^{8,10,17} Direct comparison of the results of our study with those of other studies is not possible because no other prospective studies on 6-mm implants to retain a mandibular overdenture have yet been published. The results of our study are, however, in line with the conclusion of Romeo et al.²² who stated that the literature has demonstrated a similar survival rate for short and standard implants. Complication rate on patient level is two out of 12. In one of our patients, a fracture of the mandible occurred. A percentage of 0.2 has been reported in the literature as occurrence of fractures of edentulous mandibles related to implants.²⁸ These authors state that fracture is most likely to occur in the very atrophic mandible. To evaluate whether the patient's anatomy allows

TABLE 3 Mean Score of Six Scales Concerning the Denture Complaints (possible range 0–3, minimum score 0 = no complaints, maximum score 3 = a lot of complaints) and the Overall Satisfaction Score (possible range 1–10, minimum score 1 = very bad, maximum score 10 = excellent) Before, and 1 Year After Treatment and Possible Significant Differences between the Groups

	Pretreatment (n = 12)	1 Year (n = 12)	Significance
Functional complaints about lower denture (SD)	1.4 (0.8)	0.1 (0.1)	<i>p</i> < .001
Functional complaints about upper denture (SD)	0.8 (0.6)	0.1 (0.1)	<i>p</i> = .002
Functional complaints in general (SD)	0.6 (0.5)	0.1 (0.1)	<i>p</i> = .002
Facial esthetics (SD)	1.7 (0.9)	0.3 (0.7)	<i>p</i> < .001
“Neutral Space” (SD)	0.6 (0.6)	0.1 (0.1)	<i>p</i> = .027
Aesthetics (SD)	0.5 (0.4)	0.1 (0.2)	<i>p</i> = .003
Overall satisfaction score (SD)	5.8 (1.4)	9.0 (0.9)	<i>p</i> < .001

SD = standard deviation.

insertion of implants, radiographs that demonstrate the height and the labial-lingual width are needed. Assessing the width is as important as assessing the height. Ideally, a few millimeters of cortical bone should remain on both the labial and the lingual sites after the hole for insertion of an implant has been drilled. The mechanical strength of the mandible is diminished, at least temporarily, by multiple implant site preparations. Fracture can occur during the surgery and during routine oral functioning postsurgery without any trauma to the mandible. Because this study group comprised of patients with extreme resorption (mean bone height 7.2 ± 0.8 mm), there is a higher risk of fracture. Patients should be warned for this higher risk.

The mean indices for plaque, calculus, gingiva, and bleeding were shown to be very low at the 1-year evaluation. The scores are comparable with the study of Meijer et al.⁵ in which the same criteria were used. The strict oral hygiene regime to which patients were subjected to, probably results in healthy peri-implant tissues. The mean probing depth is 3.4 mm. This depth is not different as reported in other studies and is accompanied with healthy peri-implant soft tissues.

Panoramic radiographs were used for this study. It is known that intraoral radiographs present a better image,²⁹ but because of the relatively high floor of the mouth in patients with extreme resorption, positioning of an aiming device for intraoral radiographs was not possible. Mean marginal bone loss was 0.1 mm after 1 year of function of the implants. This is well within the limits as formulated by Albrektsson et al.³⁰ being 1 mm bone loss during the first year and 0.1 mm subsequent annually. This phenomenon of up to 1 mm bone loss has

been described by Adell et al.³¹ and is thought to be related to maturation of bone after implant placement and adaptation of bone to withstand functional forces. In the present study, bone loss during the first year was negligible, viz. on average 0.1 mm. The reason for this very few and negligible loss could be that this study group comprised of patients with extreme resorption. Bone of the alveolar process has already been resorbed over time and only basal bone of the mandible is left. Bone loss because of maturation and adaptation to a new function might not be the case in such extremely resorbed mandibles. This minimum bone loss could also be due to the neck design of the implant with a platform switch and surface roughness up to the neck of the implant.³² However, according to Jacobs and van Steenberghe,³³ panoramic x-rays cannot discriminate bone changes <1 mm. Projection errors (7 to 8%), inherent to panoramic x-ray devices, and overlapping buccal and lingual bone ridges (super-positioning errors), are the reason for these problems with analysis. In this study, mean bone loss of 0.1 mm has been presented, which is 10-fold the reliability of the method used. Limited attention should be given to the number as such, but the finding of limited bone loss should be remembered.

The mean score of all six scales concerning the denture complaints and the overall denture satisfaction score improved significantly from before implant treatment to the 1-year evaluation. The same questions were asked in other study groups with mandibular implant overdentures, although applying standard implant lengths, and showed comparable results.^{3,5}

From this short-term study, it is concluded that four 6-mm implants placed in the interforaminal region,

connected with a bar, supply a proper base for the support of a mandibular overdenture in the edentulous patient with an extremely resorbed edentulous mandible and a full maxillary denture. Larger patient numbers and longer follow-up periods are needed to confirm the findings in this short-term study.

REFERENCES

1. Van Waas MAJ. The influence of clinical variables on patients' satisfaction with complete dentures. *J Prosth Dent* 1990; 63:307–310.
2. Engquist B, Bergendal T, Kallus T, Linden U. A retrospective multicenter evaluation of osseointegrated implants supporting overdentures. *Int J Oral Maxillofac Implants* 1988; 3:129–134.
3. Meijer HJA, Raghoobar GM, Van't Hof MA. Comparison of implant-retained mandibular overdentures and conventional complete dentures: a 10-year prospective study of clinical aspects and patient satisfaction. *Int J Oral Maxillofac Implants* 2003; 18:879–885.
4. Raghoobar GM, Meijer HJA, Van't Hof MA, Stegenga B, Vissink A. A randomized prospective clinical trial on the effectiveness of three treatment modalities for patients with lower denture problems. A 10 year follow-up study on patient satisfaction. *Int J Oral Maxillofac Surg* 2003; 32:498–503.
5. Meijer HJA, Raghoobar GM, Batenburg RHK, Visser A, Vissink A. Mandibular overdentures supported by two or four endosseous implants: a 10-year clinical trial. *Clin Oral Implants Res* 2009; 20:722–728.
6. Meijer HJA, Raghoobar GM, Batenburg RHK, Vissink A. Mandibular overdentures supported by two Brånemark, IMZ or ITI implants: a ten-year prospective randomized study. *J Clin Periodontol* 2009; 36:799–806.
7. Cawood JJ, Howell RA. A classification of edentulous jaws. *Int J Oral Maxillofac Surg* 1988; 17:232–236.
8. Batenburg RHK, Raghoobar GM, Van Oort RP, Heijdenrijk K, Boering G. Mandibular overdentures supported by two or four endosteal implants. A prospective, comparative study. *Int J Oral Maxillofac Surg* 1998; 27:435–439.
9. Buser D, Mericske-Stern R, Dula K, Lang NP. Clinical experience with one-stage, non-submerged dental implants. *Adv Dent Res* 1999; 13:153–161.
10. Wismeijer D, Van Waas MAJ, Mulder J, Vermeeren JI, Kalk W. Clinical and radiographical results of patients treated with three treatment modalities for overdentures on implants of ITI dental implant system. A randomized controlled clinical trial. *Clin Oral Impl Res* 1999; 10:297–306.
11. Visser A, Raghoobar GM, Meijer HJA, Batenburg RHK, Vissink A. Mandibular overdentures supported by two or four endosseous implants. A 5-year prospective study. *Clin Oral Impl Res* 2005; 16:19–25.
12. Heijdenrijk K, Raghoobar GM, Meijer HJA, Stegenga B, Van der Reijden WA. Feasibility and influence of the microgap of two implants placed in a non-submerged procedure: a five-year follow-up clinical trial. *J Periodontol* 2006; 77:1051–1060.
13. Stoker GT, Wismeijer D, Van Waas MAJ. An eight-year follow-up to a randomized clinical trial of aftercare and cost-analysis with three types of mandibular implant-retained overdentures. *J Dent Res* 2007; 86:276–280.
14. Thomason JM, Feine J, Exley C, et al. Mandibular two implant-supported overdentures as the first choice standard of care for edentulous patients – the York Consensus Statement. *Br Dent J* 2009; 207:185–186.
15. Stellingsma C, Vissink A, Meijer HJA, Kuiper C, Raghoobar GM. Implantology and the severely resorbed edentulous mandible. *Crit Rev Oral Biol Med* 2004; 15:240–248.
16. Kotsovilis S, Fourmoussis I, Karoussis IK, Bamia C. A systematic review and meta-analysis on the effect of implant length on the survival of rough-surface dental implants. *J Periodontol* 2009; 80:1700–1718.
17. Stellingsma K, Raghoobar GM, Meijer HJA, Stegenga B. The extremely resorbed mandible: a comparative prospective study of 2-year results with 3 treatment strategies. *Int J Oral Maxillofac Implants* 2004; 19:563–577.
18. Das Neves FD, Fones D, Bernardes SR, Do Prado CJ, Neto AJ. Short implants – an analysis of longitudinal studies. *Int J Oral Maxillofac Implants* 2006; 21:86–93.
19. Hagi D, Deporter DA, Pilliar RM, Arenovich T. A targeted review of study outcomes with short (< or =7 mm) endosseous dental implants placed in partially edentulous patients. *J Periodontol* 2004; 75:798–804.
20. Lee JH, Frias V, Lee KW, Wright RF. Effect of implant size and shape on implant success rates: a literature review. *J Prosthet Dent* 2005; 94:377–381.
21. Renouard F, Nisand D. Impact of implant length and diameter on survival rates. *Clin Oral Impl Res* 2006; 17 (Suppl 2):35–51.
22. Romeo E, Bivio A, Mosca D, Scanferla M, Ghisolfi M, Storelli S. The use of short dental implants in clinical practice: literature review. *Minerva Stomatol* 2010; 59:23–31.
23. Vercruyssen M, Marcelis K, Coucke W, Naert I, Quirynen M. Long-term, retrospective evaluation (implant and patient-centred outcome) of the two-implants-supported overdenture in the mandible. Part 1: survival rate. *Clin Oral Implants Res* 2010; 21:357–365.
24. Lekholm U, Zarb GA. Patient selection and preparation. In: Brånemark P-I, Zarb GA, Albrektsson T, eds. *Tissue-integrated prostheses: osseointegration in clinical dentistry*. Chicago, IL: Quintessence, 1985:199–209.
25. Mombelli A, Van Oosten MAC, Schürch E, Lang N. The microbiota associated with successful or failing osseointegrated titanium implants. *Oral Microbiol Immunol* 1987; 2:145–151.

26. Löe H, Silness J. Periodontal disease in pregnancy. II: correlation between oral hygiene and periodontal condition. *Acta Odontol Scand* 1963; 21:533–551.
27. Vervoorn JM, Duinkerke ASH, Luteijn F, Van Der Poel ACM. Assessment of denture satisfaction. *Com Dent Oral Epidemiol* 1988; 16:364–367.
28. Raghoobar GM, Stellingsma K, Batenburg RHK, Vissink A. Etiology and management of mandibular fractures associated with endosteal implants in the atrophic mandible. *Oral Surg Oral Med Oral Pathol Oral Radiol Endod* 2000; 89:553–559.
29. Meijer HJA, Steen WHA, Bosman F. Standardized radiographs of the alveolar crest around implants in the mandible. *J Prosthet Dent* 1992; 68:318–321.
30. Albrektsson T, Zarb G, Worthington P, Eriksson AR. The long-term efficacy of currently used dental implants: a review and proposed criteria for success. *Int J Oral Maxillofac Implants* 1986; 1:11–25.
31. Adell R, Lekholm U, Rockler B, Brånemark P-I. A 15-year study of osseointegrated implants in the treatment of the edentulous jaw. *Int J Oral Surg* 1981; 10:387–416.
32. Van de Velde T, Collaert B, Sennerby L, De Bruyn H. Effect of implant design on preservation of marginal bone in the mandible. *Clin Implant Dent Relat Res* 2010; 12:134–141.
33. Jacobs R, Van Steenberghe D. Radiographic planning and assessment of endosseous oral implants. Heidelberg: Springer Verlag, 1998:66–79.