

University of Groningen

Brain Volume Changes After Withdrawal of Atypical Antipsychotics in Patients With First-Episode Schizophrenia

Boonstra, Geartsje; van Haren, Neeltje E. M.; Schnack, Hugo G.; Cahn, Wiepke; Burger, Huibert; Boersma, Maria; de Kroon, Bart; Grobbee, Diederick E.; Pol, Hilleke E. Hulshoff; Kahn, Rene S.

Published in:
Journal of Clinical Psychopharmacology

DOI:
[10.1097/JCP.0b013e31820e3f58](https://doi.org/10.1097/JCP.0b013e31820e3f58)

IMPORTANT NOTE: You are advised to consult the publisher's version (publisher's PDF) if you wish to cite from it. Please check the document version below.

Document Version
Publisher's PDF, also known as Version of record

Publication date:
2011

[Link to publication in University of Groningen/UMCG research database](#)

Citation for published version (APA):

Boonstra, G., van Haren, N. E. M., Schnack, H. G., Cahn, W., Burger, H., Boersma, M., ... Kahn, R. S. (2011). Brain Volume Changes After Withdrawal of Atypical Antipsychotics in Patients With First-Episode Schizophrenia. *Journal of Clinical Psychopharmacology*, 31(2), 146-153. DOI: 10.1097/JCP.0b013e31820e3f58

Copyright

Other than for strictly personal use, it is not permitted to download or to forward/distribute the text or part of it without the consent of the author(s) and/or copyright holder(s), unless the work is under an open content license (like Creative Commons).

Take-down policy

If you believe that this document breaches copyright please contact us providing details, and we will remove access to the work immediately and investigate your claim.

Downloaded from the University of Groningen/UMCG research database (Pure): <http://www.rug.nl/research/portal>. For technical reasons the number of authors shown on this cover page is limited to 10 maximum.

Brain Volume Changes After Withdrawal of Atypical Antipsychotics in Patients With First-Episode Schizophrenia

Geartsje Boonstra, MD, MSc,*† Neeltje E.M. van Haren, PhD,* Hugo G. Schnack, PhD,*
Wiepke Cahn, MD, PhD,* Huibert Burger, MD, PhD,†‡ Maria Boersma, MSc,* Bart de Kroon, MSc,*
Diederick E. Grobbee, MD, PhD,† Hilleke E. Hulshoff Pol, PhD,* and René S. Kahn, MD, PhD*

Abstract: The influence of antipsychotic medication on brain morphology in schizophrenia may confound interpretation of brain changes over time. We aimed to assess the effect of discontinuation of atypical antipsychotic medication on change in brain volume in patients. Sixteen remitted, stable patients with first-episode schizophrenia, schizoaffective or schizophreniform disorder and 20 healthy controls were included. Two magnetic resonance imaging brain scans were obtained from all subjects with a 1-year interval. The patients either discontinued ($n = 8$) their atypical antipsychotic medication (olanzapine, risperidone, or quetiapine) or did not ($n = 8$) discontinue during the follow-up period. Intracranial volume and volumes of total brain, cerebral gray and white matter, cerebellum, third and lateral ventricle, nucleus caudatus, nucleus accumbens, and putamen were obtained. Multiple linear regression analyses were used to assess main effects for group (patient-control) and discontinuation (yes-no) for brain volume (change) while correcting for age, sex, and intracranial volume. Decrease in cerebral gray matter and caudate nucleus volume over time was significantly more pronounced in patients relative to controls. Our data suggest decreases in the nucleus accumbens and putamen volumes during the interval in patients who discontinued antipsychotic medication, whereas increases were found in patients who continued their antipsychotics. We confirmed earlier findings of excessive gray matter volume decrements in patients with schizophrenia compared with normal controls. We found evidence suggestive of decreasing volumes of the putamen and nucleus accumbens over time after discontinuation of medication. This might suggest that discontinuation reverses effects of atypical medication.

Key Words: antipsychotic agents, magnetic resonance imaging, schizophrenia, follow-up studies, withholding treatment

(*J Clin Psychopharmacol* 2011;31: 146–153)

Schizophrenia is a chronic disorder characterized by recurrent psychotic episodes and a decline in functioning. Treatment typically involves long-term antipsychotic use.

Increasing evidence suggests that the often replicated brain volume decrease in schizophrenia¹ is progressive over time.^{2–7} Although some of the progressive brain changes seem related to the course of illness,^{2,7–11} it has been an issue of debate what, if any, is the influence of medication. Some argue, based on research in monkeys, that the loss of gray matter in schizophrenia can be attributed to the use of typical or atypical antipsychotic medication.¹² In contrast, in studies in patients with schizophrenia, the loss of gray matter (GM) volume seems to be attenuated by atypical antipsychotics but not by haloperidol.^{13–15}

One of the best replicated findings in schizophrenia is the increase in caudate nucleus (NC) volume being related to the intake of typical antipsychotics.^{16,17} It has been suggested that changing treatment to atypical antipsychotics seems to “normalize” this effect.^{18–20} However, investigated longitudinally, the use of atypical antipsychotic medication has been related to stable,^{21–23} increasing,^{22,24} and decreasing^{18,19,25–27} volumes of basal ganglia.

Differentiating between antipsychotic-induced changes and those inherent to the disease would be most valid through randomization of antipsychotic-naïve first-episode patients to treatment or placebo in comparison with healthy controls. However, this design is clearly coupled with ethical issues. One alternative design is to longitudinally study brain volumes in patients who discontinue their medication, or not. Guidelines offer the psychiatrist the possibility to discontinue antipsychotic medication in remitted and stable patients with first-episode schizophrenia.²⁸ The National Institute for Health and Clinical Excellence guideline²⁹ states that “it is uncertain whether maintenance drug treatment is required for all people with schizophrenia. Around 20% of individuals will only experience a single episode”. To assess medication-related changes in brain volume over time, we compared remitted and stable patients with schizophrenia in whom atypical antipsychotic medication was either discontinued or continued in a 1-year follow-up magnetic resonance imaging (MRI) study.

MATERIALS AND METHODS

Subjects

After complete description of the study, written informed consent was obtained from all participants. The Medical Ethics Review Board of the University Medical Center Utrecht approved the study. Sixteen patients were included. They were aged 16 to 55 years and diagnosed with schizophrenia, schizophreniform, or schizoaffective disorder as assessed with the Structured Clinical Interview for *Diagnostic and Statistical Manual of Mental Disorders, Fourth Edition* Axis-I disorders (1996). They were treated in a tertiary or secondary psychiatric center in The Netherlands. Furthermore, only clinically remitted and stable first-episode patients with scores of 3 or less over the previous year on each core psychosis item (delusions, conceptual disorganization, hallucinatory behavior, and suspiciousness

From the *Department of Psychiatry, University Medical Center Utrecht; †Julius Center for Health Sciences and Primary Care, Utrecht; and ‡Interdisciplinary Center for Psychiatric Epidemiology, University of Groningen, Groningen, The Netherlands.

Received June 8, 2010; accepted after revision December 3, 2010.

Reprints: Geartsje Boonstra, MD, MSc, Julius Center for Health Sciences and Primary Care and Department of Psychiatry, Rudolf Magnus Institute of Neuroscience, University Medical Center Utrecht, HPN A01.126, Heidelberglaan 100, 3584 CX, Utrecht, The Netherlands (e-mail: geartsje.boonstra@gmail.com; g.boonstra@umcutrecht.nl).

This study was funded by the Netherlands Organization for Health Research and Development (ZonMw; No. 2100.0057) and by Eli Lilly and Company (H6U-UT-LRAC), which gave without contributing to or constraining the process of collection, analysis, and interpretation of the data, of writing the report, and of deciding if, when, how, or where to submit the paper for publication.

Copyright © 2011 by Lippincott Williams & Wilkins

ISSN: 0271-0749

DOI: 10.1097/JCP.0b013e31820e3f58

or persecution) of the Positive and Negative Syndrome Scale (PANSS)³⁰ were included. Exclusion criteria were medication noncompliance during the past year, use of mood stabilizers, severe neurological illness, current suicidal ideation, or a history of a serious suicide attempt. Duration of remission, suicidal ideation, and compliance were assessed by interviewing patients and their treating physician. Of the included patients, brain MR images were acquired at baseline (T0) and at 12 months' follow-up (T12) or, if possible, at relapse before T12 and before medication restart. To assess the influence of discontinuation of atypical antipsychotics on brain volume change (corrected for time interval: [volume T12 - volume T0]/[T12 - T0]), the included patients were divided in 2 subgroups: patients who tapered (in 6–12 weeks) and discontinued antipsychotic treatment (n = 8) and patients who continued antipsychotics (n = 8) between T0 and T12. A proportion of the participating patients (n = 10) was selected from a randomized trial investigating the effect of discontinuation versus continuation of antipsychotics on relapse risk (First author, accepted for publication). Half of the patients in this study were originally randomized to continuation (n = 4) or discontinuation (n = 4) and remained in that group. Two patients in the discontinuation group were originally randomized to continuation but tapered and discontinued after 6 months in the study. The remainder of the patients (n = 6) chose to continue or discontinue their antipsychotics. All subjects participating in this study were on atypical antipsychotic medication at inclusion. The type of drug had been determined by the treating physician, and not the researcher, and remained the responsibility of the

treating physician during the study. In retrospect, none of the patients changed their type of antipsychotic medication during the current study. During follow-up, the patients were evaluated every 2 months by a trained researcher, with extra visits in case of impending relapse. In each visit, the PANSS was administered and medication status was assessed. Haloperidol dose equivalents (HEQ) for quantification of antipsychotic exposure were calculated using patient charts as follows (ratio haloperidol–other antipsychotic): risperidone, 1:1; olanzapine, 1:2.5; quetiapine 1:100.³¹

In addition, 20 controls were included and scanned twice with an interval of an average of 1 year. The controls were group matched for age and sex to the patients. The control sample has been described previously.² Baseline characteristics are shown in Table 1. The controls had no mental (history) or physical illness at both baseline and follow-up measurements.

MRI Data Acquisition

Magnetic resonance images (MRIs) were acquired using a 1.5-T Philips NT scanner. A T1-weighted 3-dimensional (3D) fast field echo (echo time [TE], 4.6 milliseconds; repetition time [TR], 30 milliseconds; flip angle, 30 degrees; field of view [FOV], 256/80% mm) with 160 to 180 contiguous coronal 1.2-mm slices, and a T2-weighted dual echo turbo spin echo (TE1, 14 milliseconds; TE2, 80 milliseconds; TR, 6350 milliseconds; flip angle, 90 degrees; FOV, 256/80% mm) with 120 contiguous coronal 1.6-mm slices of the whole head were used for the quantitative measurements. In addition, a T2-weighted DE-TSE (Dual

TABLE 1. Baseline Characteristics of Normal Controls (NCS), All Patients (PTS), Patients Who Were Medication-Free at Follow-Up (OFF), and Patients on Medication at Follow-Up (ON)

Variables, N or Mean (SD)	NCS	PTS	P	PTS OFF	PTS ON	P
Sex, male/female	15/5	12/4	n.s.	6/2	6/2	n.s.
Age, y	27.97 (5.63)	28.8 (6.9)	n.s.	27.97 (8.24)	29.56 (5.72)	n.s.
Handedness (right/left/both hands)	16/4/0	13/2/1	n.s.	7/1/0	6/1/1	n.s.
Patients' level of education, y	14.40 (2.30)	12.94 (2.49)	n.s.	13.75 (2.12)	12.13 (2.70)	n.s.
Parental level of education, y	12.60 (2.14)	12.13 (3.00)	n.s.	13.93 (1.84)	10.56 (3.02)	0.02
Diagnosis: schizophrenia/schizoaffective/schizophreniform		8/6/2		4/3/1	4/3/1	n.s.
Scan interval, wk	53.76 (5.09)	55.63 (6.11)	n.s.	57.27 (8.55)	54.00 (0.84)	n.s.
Age at onset of illness, y		25.49 (7.04)		25.84 (8.16)	25.14 (6.27)	n.s.
Antipsychotic taken during interval olanzapine/risperidone/quetiapine		11/3/2		6/2/0	5/1/2	n.s.
Duration of psychosis before remission, y		1.19 (1.87)		0.96 (1.26)	1.42 (2.41)	0.02
Dosage of antipsychotics in H-EQ		3.38 (2.39)		3.50 (2.00)	3.25 (2.87)	n.s.
H-EQ taken during interval corrected for interval duration		856.55 (863.85)		547.37 (548.28)	1156.73 (1039.22)	0.005
Drugs/alcohol abuse or dependency ever before T0 (no/yes)	19/1	8/8	n.s.	4/4	4/4	n.s.
Drugs/alcohol abuse/dependence at T0 (no/yes)	17/3	14/2	0.03	7/1	7/1	n.s.
PANSS						
Positive scale		10.13 (2.66)		9.00 (1.60)	11.25 (3.11)	n.s.
Negative scale		12.75 (3.15)		13.13 (3.72)	12.38 (2.67)	n.s.
General scale		24.69 (5.34)		23.75 (2.61)	25.63 (7.23)	n.s.
GAF		61.31 (11.61)		58.13 (11.93)	64.50 (11.11)	n.s.
CGI		1.56 (0.63)		1.38 (0.52)	1.75 (0.71)	n.s.

All differences for baseline characteristics were checked with the Pearson χ^2 test for nominal variables, analysis of variance for normally distributed continuous variables, and Mann-Whitney *U* test for not normally distributed continuous variables.

CGI indicates Clinical Global Impression; GAF, Global Assessment of Functioning; H-EQ, haloperidol equivalents; n.s., nonsignificant; PANSS, Positive and Negative Syndrome scale.

Echo-Turbo Spin Echo) (TE1, 9 milliseconds; TE2, 100 milliseconds; TR, 2200 milliseconds; flip angle, 90 degrees; FOV, 250/100% mm) with 17 axial 5-mm slices and 1.2-mm gap of the whole head was acquired for clinical neurodiagnostic evaluation. The scans were processed on the neuroimaging computer network of the Department of Psychiatry at the University Medical Center Utrecht. Before quantitative assessments, 10 randomly chosen images were cloned for calculation of interrater reliability using the intraclass correlation coefficient (ICC). All images were coded to ensure blindness for subject identification. Scans were put into a Talairach frame (no scaling)³² and corrected for inhomogeneities in the magnetic field.³³

Volume measures of the intracranium, total brain (TB), cerebral gray (GM) and white matter (WM), cerebellum, and third (V3) and lateral ventricles (LV) were determined. Quantitative assessment of the intracranial volume was performed with the use of a fully automated computer program based on histogram analyses followed by mathematical morphological operators in the DE-TSE image. Quantitative assessment of the TB, GM, WM, cerebellar, V3, and LV volumes were performed based on histogram analyses, followed by mathematical morphological operators in the 3D fast field echo image, using the intracranial volume as mask.^{34,35} In addition, for the cerebellum and V3 and LV volumes, anatomical knowledge-based selection principles were used. For the cerebellum, this included a plane perpendicular to the sagittal plane through the aqueduct. For the V3, this included the coronal slices through the anterior commissure (AC) as anterior border, the coronal slice through the posterior commissure as posterior border, and a manually outlined roof to prevent leaks into the transverse cistern, drawn in the midsagittal reconstructed slice from a point superior to the thalamus and just inferior to the plexus choroideus. For the LVs, this included automated computer-incorporated anatomical knowledge of the anatomical location of the LVs in the brain (eg, they are surrounded by WM). All segmentations were checked after measurements and corrected manually if necessary. The interrater reliabilities of the volume measurements, determined by the ICC, were 0.95 and higher.

Basal ganglia structures were traced manually by a single experienced rater (B.K.). Nucleus caudatus (NC), putamen, and nucleus accumbens (NA) were outlined in contiguous coronal slices in an anterior-posterior direction. The sagittal and axial planes were used for reference. Segmentation procedures are based on previously described guidelines.^{18,36}

In the first segmentation slice, the NC had to be visible inferolateral of the LVs; in the last slice, either the posterior commissure appeared or the NC was still clearly discernible in the coronal view. Medially, the frontal horn and body of the LV bordered the NC and, laterally, the internal capsule. The interconnecting GM striae between the NC and putamen visible in the internal capsule were not included in the NC or putamen volumes. At the inferior border, the CA and the NA were separated by a horizontal line from the most basal extent of the LV to the most lateral point of the NC.

Putamen segmentation commenced in the first slice where the structure was clearly distinguishable, and it ended in the last slice where the boundaries were still clearly discernible. The anterior limb of the internal capsule and the globus pallidus formed the medial border and the external capsule the lateral border. Inferomedially, the putamen and the NA were separated by a vertical line from the most lateroinferior point of the internal capsule to the inferior border of the putamen/NA. In slices where the AC was visible, the most lateral point of the AC was used as the starting point of the vertical line separating the putamen and the NA.

In the first slice containing both NC and putamen, segmentation of the NA started, and it ended in the slice where the boundaries for the NA were still clearly discernible. Superolaterally, the putamen and NC bordered the NA, and inferomedially, they bordered the surrounding WM.

Ten scans were duplicated and randomly intermixed with the data set to allow for an estimation of intrarater reliability using ICCs. Intraclass correlation coefficient scores were 0.99 for NC, 0.97 for NA, and 0.90 for putamen volume.

Data Analysis

To investigate the effect of illness and antipsychotic treatment on brain volume (change) multiple linear regression analyses were performed using SPSS 15. Volumes of the total brain, cerebral GM and WM, LV, V3, nucleus accumbens, nucleus caudatus, and putamen were added as dependent variable. A group variable (patient/control) and a medication variable (on/off medication at follow-up) were added as independent variables. Age, intracranial volume, and sex were added as covariates. In case of significant group differences in (change in) basal ganglia volumes, baseline TB volume instead of the intracranial volume was added as a covariate. In addition, it was tested if baseline volume of the basal ganglia structures were correlated with volume change over time using Pearson correlations. If this were the case, baseline volume was added as a covariate.

As the patients and controls differed significantly on abuse of drugs and/or alcohol at baseline and the patient groups differed significantly on parental education, these variables were added separately as a covariate in case of significant findings. This will only be mentioned if it led to differences in the results.

The patient groups also differed significantly on duration of illness since the first start of antipsychotics, but because of the high correlations with age ($r = 0.92$, $P < 0.001$), adding this as a covariate will lead to the problem of multicollinearity. All statistical tests were 2-tailed. For the comparisons of volume (change) between the 2 patient groups, confidence interval, range, and median were given for significant results.

RESULTS

Demographic and Clinical Comparison of Groups

Baseline characteristics were comparable between the patients and the controls and between the patient groups. There were 4 exceptions (Table 1; Data Analysis section 2.3). The 1-year relapse rate was 50% in the discontinuation group and 13% in the continuation group.

Illness Effect

Baseline

At baseline V3 and putamen, the volume of patients was significantly larger than that of the controls (Table 2). The volume at V3 remained larger after exclusion of one outlier. Correction for TB instead of intracranial volume did not change these results.

Change

Gray matter and NC volume changes during the interval differed significantly between patients and controls (Table 3; Fig. 1, A and D). Whereas the controls showed an increase in GM and NC volumes, the patients showed decreases over time. In addition, the NA volume increase over time was more pronounced in the controls compared to that in the patients (Table 3; Fig. 1C). Furthermore, the WM volume in the patients' group showed a larger increase over time compared to that of the controls (Table 3; Fig. 1B). The significant changes in the basal

TABLE 2. Raw Baseline Brain Volume, Comparison Between Normal Controls (NCS) and All Patients (PTS) With Schizophrenia and Between Patients Who Continued (PTS-C) and Stopped Antipsychotic Medication (PTS-S)*

Brain Structure	Normal Controls Versus Patients				Patients Who Discontinued Versus Patients Who Continued Antipsychotic Medication							
	Baseline Volume		b	SE (b)	t	df = 31	P	Baseline Volume				
	NCS in mL (SD)	PTS in mL (SD)						PTS-S in mL (SD)	PTS-C in mL (SD)	b	SE (b)	t
Total brain	1 181.44 (127.39)	1 146.84 (139.89)	-3.16	15.32	-0.21	0.84	1 141.88 (133.94)	1 151.80 (154.73)	-19.08	18.31	-1.04	0.31
Cerebral GM	681.49 (60.04)	657.41 (79.91)	-12.08	14.56	-0.83	0.41	654.65 (71.40)	660.17 (92.57)	-0.09	17.40	-0.01	0.99
Cerebral WM	499.95 (81.16)	489.43 (64.30)	3.91	12.19	0.32	0.75	487.23 (65.39)	491.64 (67.63)	-8.77	14.57	-0.60	0.55
Lateral ventricles	15.67 (12.43)	18.10 (8.06)	2.35	3.66	0.64	0.53	16.15 (8.69)	20.04 (13.33)	1.39	4.38	0.32	0.75
Third ventricle	0.65 (0.28)	0.99 (0.53)	0.43	0.14	3.05	<0.01	1.04 (0.61)	0.93 (0.48)	-0.17	0.17	-1.00	0.33
Cerebellum	148.07 (13.52)	147.52 (18.69)	5.92	4.58	1.29	0.21	151.18 (19.53)	143.86 (18.35)	-8.96	5.47	-1.64	0.11
N. accumbens	2.09 (0.45)	2.01 (0.45)	0.07	0.16	0.46	0.65	2.10 (0.55)	1.92 (0.32)	-0.20	0.19	-1.07	0.29
N. caudatus	7.92 (1.10)	7.60 (0.94)	-0.08	0.35	-0.24	0.81	7.65 (1.07)	7.55 (0.86)	-0.23	0.41	-0.55	0.59
Putamen	9.11 (0.73)	9.61 (1.60)	1.41	0.31	4.61	<0.01	10.32 (1.40)	8.90 (1.54)	-1.49	0.37	-4.07	<0.01

Significant findings are in bold.

*Difference between groups expressed as unstandardized regression coefficients b ± SE (b) corrected for sex, age, and intracranial volume, in which b represents the corrected volume difference in milliliters.

TABLE 3. Raw Change in Brain Volume Over 1 Year, Comparison Between All Patients With Schizophrenia and Normal Controls and Between Patients Who Continued (PTS-C) and Stopped Antipsychotic Medication (PTS-S)*

Brain Structure	Normal Controls Versus Patients				Patients Who Continued Versus Patients Who Discontinued Antipsychotic Medication							
	Volume Change		b	SE (b)	t	df = 31	P	Volume Change				
	NCS in mL (SD)	PTS in mL (SD)						PTS-S in mL (SD)	PTS-C in mL (SD)	b	SE (b)	t
Total brain	7.98 (12.15)	5.77 (17.75)	0.12	7.12	0.00	0.99	9.73 (19.8)	1.80 (15.70)	-10.13	8.51	-0.26	0.24
Cerebral GM	7.35 (19.72)	-7.17 (13.92)	-16.02	7.50	-2.14	0.04	-9.73 (14.6)	-4.61 (13.63)	3.97	8.95	0.44	0.66
Cerebral WM	0.63 (17.58)	12.94 (17.27)	18.05	7.32	2.46	0.02	19.46 (15.2)	6.41 (17.67)	-12.74	8.75	-1.46	0.16
Lateral ventricles	0.07 (1.05)	-0.11 (0.90)	-0.43	0.43	-1.00	0.33	-0.38 (0.71)	0.16 (1.04)	0.55	0.52	1.07	0.30
Third ventricle	0.00 (0.08)	-0.01 (0.10)	-0.05	0.04	-1.46	0.15	-0.06 (0.07)	0.03 (0.12)	0.08	0.04	1.88	0.07
Cerebellum	1.05 (2.89)	0.44 (2.70)	0.66	1.17	0.57	0.58	1.68 (2.2)	-0.80 (2.70)	-2.67	1.40	-1.91	0.07
N. accumbens	0.05 (0.14)	0.01 (0.14)	-0.12	0.06	-2.07	0.05	-0.07 (0.11)	0.08 (0.13)	0.14	0.07	2.12	0.04
N. caudatus	0.04 (0.21)	-0.04 (0.21)	-0.19	0.09	-2.23	0.03	-0.13 (0.22)	0.06 (0.15)	0.19	0.10	1.89	0.07
Putamen	-0.17 (0.37)	0.28 (0.65)	0.02	0.17	0.13	0.89	-0.11 (0.27)	0.67 (0.70)	0.77	0.21	3.72	<0.01

Significant findings are in bold.

*Difference between groups expressed as unstandardized regression coefficients b ± SE (b) corrected for sex, age, and intracranial volume, in which b represents the corrected volume difference in milliliters.

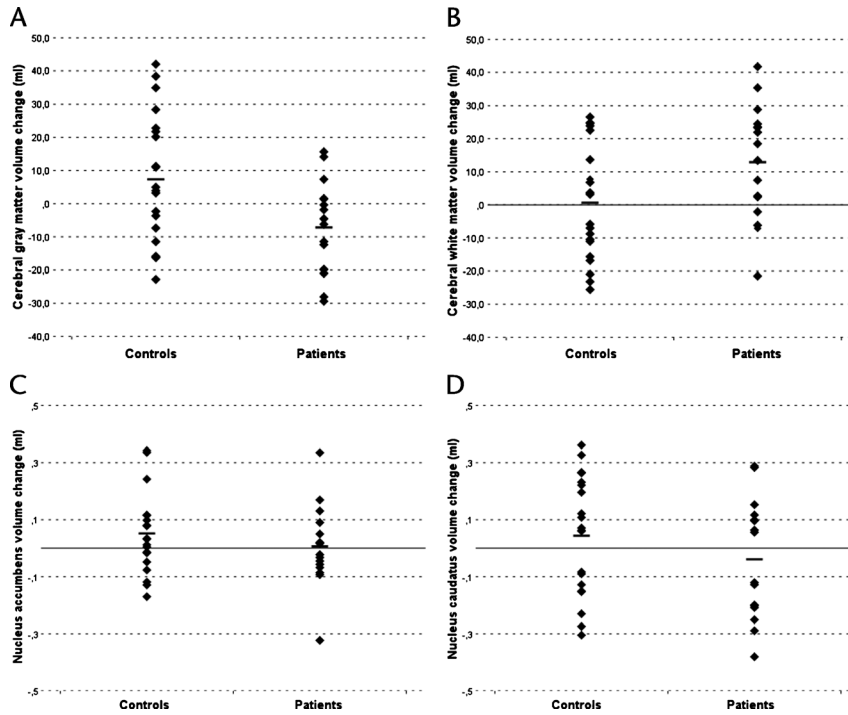


FIGURE 1. One-year (raw) volume change in controls and patients for cerebral GM (A), cerebral white matter (B), nucleus accumbens (C), and nucleus caudate (D).

ganglia remained significant after correction for the baseline TB volume and the baseline volume of the structure concerned. However, after exclusion of the largest outlier in the patients, the difference in the NA change was not significant ($P = 0.18$), and after correction for having a positive history of alcohol or drug abuse or dependency, the difference in the NA change was trend-level significant ($P = 0.06$).

Medication Effect

The 2 patient groups did not differ significantly on any of the volumes at baseline except for the putamen volume (Table 2; $b = -1.49$; 95% CI, -2.23 to -0.74); discontinuation group: range (8.52–13.12), median (10.07); continuation group: range (6.75–11.08), median (8.88).

Over time, a decrease in NA and putamen volumes was found in patients who discontinued medication, whereas increases were found in the patients who continued their antipsychotics (Table 3; Fig. 2, A and B; NA: $b = 0.14$; 95% CI,

0.01–0.28; discontinuation group: range $[-0.32$ to $0.02]$, median $[-0.04]$; continuation group: range $[-0.09$ to $0.33]$, median $[-0.07]$; putamen: $b = 0.77$; 95% CI, 0.35–1.20; discontinuation group: range $[-0.53$ to $0.21]$, median $[-0.03]$; continuation group: range $[-0.29$ to $1.93]$, median $[0.49]$). Correction for TB volume did not change these findings. However, after exclusion of the largest outlier in the patients, the difference in the NA changes was no longer significant ($P = 0.12$).

DISCUSSION

This study examined the effect of discontinuation of atypical antipsychotic medication on brain volume change during a 1-year interval in remitted and stable patients with first-episode schizophrenia. We replicated earlier findings of excessive decrease in cerebral GM volume in patients relative to controls. In addition, our results suggest that discontinuation or continuation of atypical antipsychotics does not influence GM volume change

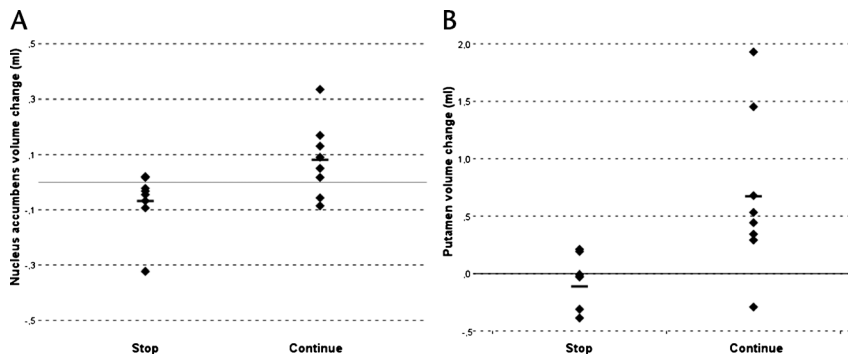


FIGURE 2. One-year (raw) nucleus accumbens (A) and putamen (B) volume change in patients who either stopped or continued antipsychotic treatment before a second MRI scan. Note the differences in range of the y-axis.

in patients. If anything, cerebral GM volume decrease over time seemed more pronounced in the patients who discontinued than in those who continued antipsychotic medication, although this difference was not significant. Our results suggest that the excessive reduction of GM volume occurs irrespective of atypical antipsychotic treatment continuation or discontinuation. This might indicate that the excessive loss of GM volume in patients with schizophrenia cannot be explained by the intake of atypical antipsychotic medication.

To date, only a limited number of longitudinal studies have been done that looked directly at the influence of atypical antipsychotic treatment on brain volume in a controlled manner. This is especially the case if one excludes studies in which the prestudy treatment was unknown and consisted of both atypical and typical antipsychotics, or where patients were analyzed together independently of being antipsychotic naive, or not, before the study.^{15,26,37-44} Findings so far indicate that GM volume increases after starting atypical antipsychotic treatment in antipsychotic-naive patients during a 4-week interval (although no control group was available)²⁻⁷ but also after changing from typical to atypical antipsychotic treatment.¹⁴ One randomized study identified GM loss after 1 year of treatment with haloperidol compared to olanzapine.¹⁵ Unfortunately, it was not mentioned what type of antipsychotics (typical/atypical) the patients used before the start of the study medication. Together, these findings suggest that atypical antipsychotics might prevent the loss of GM tissue. Indeed, in a large longitudinal study in a sample of both first-episode and chronically ill patients, cumulative intake of atypical medication was associated with less loss of GM tissue.¹¹

That GM tissue loss is most likely associated with the effects of the illness, and is not a consequence of (atypical) antipsychotic medication intake, is also supported by evidence that cerebral GM deficits in patients seem to be present before the start of antipsychotic medication⁴⁵⁻⁴⁸ or even before the start of the first symptoms.⁷ However, some studies report no differences between normal controls and medication-naive patients.^{14,49-52}

In contrast to our findings in humans, a randomized study in Macaque monkeys found that chronic treatment with atypical ($n = 6$, for 1.2 years) and typical ($n = 6$, for 2.2 years) antipsychotics resulted in a reduction of parietal GM volume compared with placebo.¹² However, it is difficult to extrapolate these regional postmortem animal findings to those occurring in vivo in the brains of patients with schizophrenia.

Antipsychotics may exert their effect in focal areas of the brain.⁵³ Here, we focused on the basal ganglia. At baseline, all patients were on atypical antipsychotic medication. The patients discontinuing atypical antipsychotics seemed to decrease in NA and putamen volumes over time. This is of particular interest inasmuch as the putamen volume seemed to increase in the patients compared to the controls at baseline. Moreover, the 2 patient groups did not differ on baseline brain volumes, except for the putamen, which was larger in the patients who discontinued their antipsychotic regimen compared to the patients who continued their antipsychotic medication. Outcome of the illness might be a possible explanation for this, as Buchsbaum et al¹⁰ identified a larger putamen in patients with good outcome of schizophrenia in comparison to those with a poor outcome and healthy controls. Indeed, the patients who stopped tolerated tapering and were able to not use medication without experiencing a relapse for a certain period of time. Whether this would have been the case in those that continued their antipsychotics is unknown.

It might be that the increase in putamen volume at baseline in the patients relative to the controls is an effect of taking

atypical antipsychotic medication (although this cannot be tested in our study, but see Glenthøj et al²²). If this were the case, our findings suggest that discontinuation reverses the effects of atypical medication, at least in the putamen and possibly, to some extent, in the NA.

Indeed, starting atypical antipsychotics in antipsychotic-naive patients resulted in volume increases in the NC,²⁴ NA,²⁴ and putamen²² compared to baseline²² or compared to the controls,²⁴ although some studies found no volume changes.^{21,22,24} In contrast, starting atypical antipsychotics after discontinuing typical antipsychotic medication has been associated with caudate^{18,25,27} and putamen volume reductions,¹⁹ whereas other studies found no caudate¹⁹ or putamen volume change.²⁷ These data imply that the consequences of atypical medication are dependent on the state of the brain, being medication-naive or being on typical medication.

Suggestive evidence was found for an excessive increase over time in cerebral WM volume in the patients compared to the controls, which, in the patients, did not seem to be influenced by either continuation or discontinuation of antipsychotics. Cerebral WM volume in the antipsychotic-naive patients was reported to be similar to the healthy controls^{14,46,49,51,52} (but for decreased WM, see Chua et al⁴⁵). Although the initiation of atypical antipsychotics in antipsychotic-naive¹⁴ or antipsychotic-free schizophrenia⁵⁴ did not result in WM volume changes, WM volume did decrease significantly in haloperidol-treated patients whose treatment was changed to clozapine.¹⁴

Strengths and Limitations

Studies like this one are complicated to carry out, resulting in a small number of included patients. Consequently, type II errors cannot be ruled out. To our knowledge, this is the first MRI study that compared brain volume change between patients who discontinued or continued atypical antipsychotic medication. Therefore, we are convinced that, despite the small sample size, it is important to present these data. In addition, this serves as the rationale for not applying a correction for multiple testing. Most of our findings would not have survived such a correction.

Half of the patients in this study were randomized to continuation ($n = 4$) or discontinuation ($n = 4$). In the continuation group, the remaining 4 patients chose to continue their medication because of fear of relapse, which is a sign of good insight. In contrast, in the discontinuation group, 4 patients decided to stop their antipsychotic treatment despite risk of relapse. Because insight is a predictor of good outcome,⁵⁵ the continuation group might have consisted of patients with a better outcome than the discontinuation group. However, all patients were clinically stable enough to allow for discontinuation at inclusion in the study.

In this study, the patients used olanzapine, risperidone, or quetiapine, which are grouped among the atypical antipsychotics²⁸ and have less binding potential for the D₂ receptor than typical antipsychotics.⁵⁶ However, risperidone is known to have a more firm grip on the D₂ receptor than the other second-generation antipsychotics.⁵⁷⁻⁵⁹ This differential effect of binding potential for the 3 antipsychotics used in this study might have diluted the volume changes in the discontinuation group in the basal ganglia structures.

The exclusion of more severe patients (at risk or with history of suicide, and abandonment of previous treatment) and the inclusion of patients with a priori better prognosis than schizophrenia such as schizoaffective disorder and schizophreniform disorder, made this sample one with a better prognosis than the general population of first psychotic episodes, as indicated by the values of the PANSS, the Global Assessment of Functioning, and the Clinical Global Impression at baseline. This is a

consequence of the design of the study, as guidelines offer the psychiatrist the possibility to discontinue antipsychotic medication only in remitted and stable patients with first-episode schizophrenia.²⁸

CONCLUSIONS

We confirmed earlier findings of GM volume decrements in patients with schizophrenia in comparison to healthy controls. Our main conclusion is that the excessive cerebral GM volume decrease found in patients with schizophrenia is unlikely to be explained by atypical antipsychotic treatment. However, the increase in putamen volume at baseline seems to be (at least partly) a medication effect as putamen (and also nucleus accumbens) volume decreased in patients after discontinuation with atypical antipsychotics.

AUTHOR DISCLOSURE INFORMATION

The authors declare no relevant conflicts of interest.

REFERENCES

- Wright IC, Rabe-Hesketh S, Woodruff PW, et al. Meta-analysis of regional brain volumes in schizophrenia. *Am J Psychiatry*. 2000;157(1):16–25.
- Cahn W, Hulshoff Pol HE, Lems EB, et al. Brain volume changes in first-episode schizophrenia: a 1-year follow-up study. *Arch Gen Psychiatry*. 2002;59(11):1002–1010.
- DeLisi LE, Sakuma M, Tew W, et al. Schizophrenia as a chronic active brain process: a study of progressive brain structural change subsequent to the onset of schizophrenia. *Psychiatry Res*. 1997;74(3):129–140.
- Gur RE, Cowell P, Turetsky BI, et al. A follow-up magnetic resonance imaging study of schizophrenia. Relationship of neuroanatomical changes to clinical and neurobehavioral measures. *Arch Gen Psychiatry*. 1998;55(2):145–152.
- Hulshoff Pol HE, Kahn RS. What happens after the first episode? A review of progressive brain changes in chronically ill patients with schizophrenia. *Schizophr Bull*. 2008;34(2):354–366.
- Pantelis C, Yucel M, Wood SJ, et al. Structural brain imaging evidence for multiple pathological processes at different stages of brain development in schizophrenia. *Schizophr Bull*. 2005;31(3):672–696.
- Job DE, Whalley HC, Johnstone EC, et al. Grey matter changes over time in high risk subjects developing schizophrenia. *Neuroimage*. 2005;25(4):1023–1030.
- Cahn W, van Haren NE, Hulshoff Pol HE, et al. Brain volume changes in the first year of illness and 5-year outcome of schizophrenia. *Br J Psychiatry*. 2006;189:381–382.
- Lieberman J, Chakos M, Wu H, et al. Longitudinal study of brain morphology in first episode schizophrenia. *Biol Psychiatry*. 2001;49(6):487–499.
- Buchsbaum MS, Shihabuddin L, Brickman AM, et al. Caudate and putamen volumes in good and poor outcome patients with schizophrenia. *Schizophr Res*. 2003;64(1):53–62.
- van Haren NE, Hulshoff Pol HE, Schnack HG, et al. Progressive brain volume loss in schizophrenia over the course of the illness: evidence of maturational abnormalities in early adulthood. *Biol Psychiatry*. 2008;63(1):106–113.
- Dorph-Petersen KA, Pierri JN, Perel JM, et al. The influence of chronic exposure to antipsychotic medications on brain size before and after tissue fixation: a comparison of haloperidol and olanzapine in macaque monkeys. *Neuropsychopharmacology*. 2005;30(9):1649–1661.
- Haren vNE, Hulshoff Pol HE, Schnack HG, et al. Focal gray matter changes in schizophrenia across the course of the illness: a 5-year follow-up study. *Neuropsychopharmacology*. 2007;2057–2066.
- Molina V, Reig S, Sanz J, et al. Increase in gray matter and decrease in white matter volumes in the cortex during treatment with atypical neuroleptics in schizophrenia. *Schizophr Res*. 2005;80(1):61–71.
- Lieberman JA, Tollefson GD, Charles C, et al. Antipsychotic drug effects on brain morphology in first-episode psychosis. *Arch Gen Psychiatry*. 2005;62(4):361–370.
- Keshavan MS, Rosenberg D, Sweeney JA, et al. Decreased caudate volume in neuroleptic-naive psychotic patients. *Am J Psychiatry*. 1998;155(6):774–778.
- Keshavan MS, Bagwell WW, Haas GL, et al. Changes in caudate volume with neuroleptic treatment. *Lancet*. 1994;344(8934):1434.
- Scheepers FE, de Wied CC, Hulshoff Pol HE, et al. The effect of clozapine on caudate nucleus volume in schizophrenic patients previously treated with typical antipsychotics. *Neuropsychopharmacology*. 2001;24(1):47–54.
- Lang DJ, Kopala LC, Vidorpe RA, et al. Reduced basal ganglia volumes after switching to olanzapine in chronically treated patients with schizophrenia. *Am J Psychiatry*. 2004;161(10):1829–1836.
- Corson PW, Nopoulos P, Miller DD, et al. Change in basal ganglia volume over 2 years in patients with schizophrenia: typical versus atypical neuroleptics. *Am J Psychiatry*. 1999;156(8):1200–1204.
- Heitmiller DR, Nopoulos PC, Andreasen NC. Changes in caudate volume after exposure to atypical neuroleptics in patients with schizophrenia may be sex-dependent. *Schizophr Res*. 2004;66(27–3):137–142.
- Glenthøj A, Glenthøj BY, Mackeprang T, et al. Basal ganglia volumes in drug-naive first-episode schizophrenia patients before and after short-term treatment with either a typical or an atypical antipsychotic drug. *Psychiatry Res*. 2007;154(3):199–208.
- Tauscher-Wisniewski S, Tauscher J, Christensen BK, et al. Volumetric MRI measurement of caudate nuclei in antipsychotic-naive patients suffering from a first episode of psychosis. *J Psychiatr Res*. 2005;39(4):365–370.
- Massana G, Salgado-Pineda P, Junque C, et al. Volume changes in gray matter in first-episode neuroleptic-naive schizophrenic patients treated with risperidone. *J Clin Psychopharmacol*. 2005;25(2):111–117.
- Chakos MH, Lieberman JA, Alvir J, et al. Caudate nuclei volumes in schizophrenic patients treated with typical antipsychotics or clozapine. *Lancet*. 1995;345(8947):456–457.
- Crespo-Facorro B, Roiz-Santianez R, Perez-Iglesias R, et al. Effect of antipsychotic drugs on brain morphometry. A randomized controlled one-year follow-up study of haloperidol, risperidone and olanzapine. *Prog Neuropsychopharmacol Biol Psychiatry*. 2008;32(8):1936–1943.
- Frazier JA, Giedd JN, Kaysen D, et al. Childhood-onset schizophrenia: brain MRI rescan after 2 years of clozapine maintenance treatment. *Am J Psychiatry*. 1996;153(4):564–566.
- Lehman AF, Lieberman JA, Dixon LB, et al. Practice guideline for the treatment of patients with schizophrenia, second edition. *Am J Psychiatry*. 2004;161(suppl 2):23.
- Kuipers E, Kendall T, Antoniou J, et al. *Schizophrenia (update)*. National Clinical Practice Guideline Number 82. London, UK: National Collaborating Centre for Mental Health. National Clinical Practice Guideline; 2009.
- Kay SR, Fiszbein A, Opler LA. The positive and negative syndrome scale (PANSS) for schizophrenia. *Schizophr Bull*. 1987;13(2):261–276.
- Kane JM, Leucht S, Carpenter D, et al. The Expert Consensus Guideline series. Optimizing pharmacologic treatment of psychotic disorders. Introduction: methods, commentary, and summary. *J Clin Psychiatry*. 2003;64(suppl 12):5–19.

32. Talairach J, Tournoux P. *Co-Planar Stereotaxic Atlas of the Human Brain. 3-Dimensional Propositional System: An Approach to Cerebral Imaging*. Stuttgart, Germany: Thieme; 1988.
33. Sled JG, Zijdenbos AP, Evans AC. A nonparametric method for automatic correction of intensity nonuniformity in MRI data. *IEEE Trans Med Imaging*. 1998;17(1):87–97.
34. Schnack HG, Hulshoff HE, Baare WF, et al. Automatic segmentation of the ventricular system from MR images of the human brain. *Neuroimage*. 2001;14(1 Pt 1):95–104.
35. Schnack HG, Hulshoff Pol HE, Baare WF, et al. Automated separation of gray and white matter from MR images of the human brain. *Neuroimage*. 2001;13(1):230–237.
36. Staal WG, Hulshoff Pol HE, Schnack HG, et al. Structural brain abnormalities in patients with schizophrenia and their healthy siblings. *Am J Psychiatry*. 2000;157(3):416–421.
37. Chua SE, Deng Y, Chen EY, et al. Early striatal hypertrophy in first-episode psychosis within 3 weeks of initiating antipsychotic drug treatment. *Psychol Med*. 2009;39(5):793–800.
38. Degreef G, Ashtari M, Wu HW, et al. Follow-up MRI study in first episode schizophrenia. *Schizophr Res*. 1991;5(3):204–206.
39. Deng MY, McAlonan GM, Cheung C, et al. A naturalistic study of grey matter volume increase after early treatment in anti-psychotic naive, newly diagnosed schizophrenia. *Psychopharmacology (Berl)*. 2009;206(3):437–446.
40. Garver DL, Holcomb JA, Christensen JD. Cerebral cortical gray expansion associated with two second-generation antipsychotics. *Biol Psychiatry*. 2005;58(1):62–66.
41. Ho BC, Andreasen NC, Nopoulos P, et al. Progressive structural brain abnormalities and their relationship to clinical outcome: a longitudinal magnetic resonance imaging study early in schizophrenia. *Arch Gen Psychiatry*. 2003;60(6):585–594.
42. McClure RK, Carew K, Greeter S, et al. Absence of regional brain volume change in schizophrenia associated with short-term atypical antipsychotic treatment. *Schizophr Res*. 2008;98(1–3):29–39.
43. Milev P, Ho BC, Arndt S, et al. Initial magnetic resonance imaging volumetric brain measurements and outcome in schizophrenia: a prospective longitudinal study with 5-year follow-up. *Biol Psychiatry*. 2003;54(6):608–615.
44. Tauscher-Wisniewski S, Tauscher J, Logan J, et al. Caudate volume changes in first episode psychosis parallel the effects of normal aging: a 5-year follow-up study. *Schizophr Res*. 2002;58(2–3):185–188.
45. Chua SE, Cheung C, Cheung V, et al. Cerebral grey, white matter and CSF in never-medicated, first-episode schizophrenia. *Schizophr Res*. 2007;89(1–3):12–21.
46. Jayakumar PN, Venkatasubramanian G, Gangadhar BN, et al. Optimized voxel-based morphometry of gray matter volume in first-episode, antipsychotic-naive schizophrenia. *Prog Neuropsychopharmacol Biol Psychiatry*. 2005;29(4):587–591.
47. Ohrmann P, Siegmund A, Suslow T, et al. Cognitive impairment and in vivo metabolites in first-episode neuroleptic-naive and chronic medicated schizophrenic patients: a proton magnetic resonance spectroscopy study. *J Psychiatr Res*. 2007;41(8):625–634.
48. Venkatasubramanian G, Jayakumar PN, Gangadhar BN, et al. Neuroanatomical correlates of neurological soft signs in antipsychotic-naive schizophrenia. *Psychiatry Res*. 2008;164(3):215–222.
49. Cahn W, Hulshoff Pol HE, Bongers M, et al. Brain morphology in antipsychotic-naive schizophrenia: a study of multiple brain structures. *Br J Psychiatry Suppl*. 2002;43:s66–s72.
50. Gur RE, Maany V, Mozley PD, et al. Subcortical MRI volumes in neuroleptic-naive and treated patients with schizophrenia. *Am J Psychiatry*. 1998;155(12):1711–1717.
51. John JP, Burgess PW, Yashavantha BS, et al. Differential relationship of frontal pole and whole brain volumetric measures with age in neuroleptic-naive schizophrenia and healthy subjects. *Schizophr Res*. 2009;109(1–3):148–158.
52. Salgado-Pineda P, Baeza I, Perez-Gomez M, et al. Sustained attention impairment correlates to gray matter decreases in first episode neuroleptic-naive schizophrenic patients. *Neuroimage*. 2003;19(2 Pt 1):365–375.
53. Navari S, Dazzan P. Do antipsychotic drugs affect brain structure? A systematic and critical review of MRI findings. *Psychol Med*. 2009;39(11):1763–1777.
54. Christensen J, Holcomb J, Garver DL. State-related changes in cerebral white matter may underlie psychosis exacerbation. *Psychiatry Res*. 2004;130(1):71–78.
55. Drake RJ. Insight into illness: impact on diagnosis and outcome of nonaffective psychosis. *Curr Psychiatry Rep*. 2008;10(3):210–216.
56. Zipursky RB, Meyer JH, Verhoeff NP. PET and SPECT imaging in psychiatric disorders. *Can J Psychiatry*. 2007;52(3):146–157.
57. Catafau AM, Penengo MM, Nucci G, et al. Pharmacokinetics and time-course of D(2) receptor occupancy induced by atypical antipsychotics in stabilized schizophrenic patients. *J Psychopharmacol*. 2008;22(8):882–894.
58. Richelson E. Preclinical pharmacology of neuroleptics: focus on new generation compounds. *J Clin Psychiatry*. 1996;57(suppl 11):4–11.
59. Tauscher J, Kufferle B, Asenbaum S, et al. Striatal dopamine-2 receptor occupancy as measured with [¹²³I]iodobenzamide and SPECT predicted the occurrence of EPS in patients treated with atypical antipsychotics and haloperidol. *Psychopharmacology (Berl)*. 2002;162(1):42–49.