

University of Groningen

## Dental implant treatment for two adjacent missing teeth in the maxillary aesthetic zone

Tymstra, Nynke; Raghoobar, Gerry; Vissink, Arjan; Meijer, Hendrikus

*Published in:*  
CLINICAL ORAL IMPLANTS RESEARCH

*DOI:*  
[10.1111/j.1600-0501.2010.02017.x](https://doi.org/10.1111/j.1600-0501.2010.02017.x)

**IMPORTANT NOTE: You are advised to consult the publisher's version (publisher's PDF) if you wish to cite from it. Please check the document version below.**

*Document Version*  
Publisher's PDF, also known as Version of record

*Publication date:*  
2011

[Link to publication in University of Groningen/UMCG research database](#)

*Citation for published version (APA):*

Tymstra, N., Raghoobar, G. M., Vissink, A., & Meijer, H. J. A. (2011). Dental implant treatment for two adjacent missing teeth in the maxillary aesthetic zone: a comparative pilot study and test of principle. *CLINICAL ORAL IMPLANTS RESEARCH*, 22(2), 207-213. DOI: 10.1111/j.1600-0501.2010.02017.x

**Copyright**

Other than for strictly personal use, it is not permitted to download or to forward/distribute the text or part of it without the consent of the author(s) and/or copyright holder(s), unless the work is under an open content license (like Creative Commons).

**Take-down policy**

If you believe that this document breaches copyright please contact us providing details, and we will remove access to the work immediately and investigate your claim.

*Downloaded from the University of Groningen/UMCG research database (Pure): <http://www.rug.nl/research/portal>. For technical reasons the number of authors shown on this cover page is limited to 10 maximum.*

Nynke Tymstra  
 Gerry M. Raghoobar  
 Arjan Vissink  
 Henny J. A. Meijer

# Dental implant treatment for two adjacent missing teeth in the maxillary aesthetic zone: a comparative pilot study and test of principle

## Authors' affiliations:

Nynke Tymstra, Gerry M. Raghoobar, Arjan Vissink, Henny J. A. Meijer, Department of Oral and Maxillofacial Surgery, University Medical Center Groningen and University of Groningen, Groningen, The Netherlands and Department of Prosthetic Dentistry, Dental School, University Medical Center Groningen and University of Groningen, Groningen, The Netherlands

## Corresponding author:

Henny J. A. Meijer  
 Department of Oral and Maxillofacial Surgery  
 University Medical Center Groningen  
 PO Box 30.001, NL-9700 RB Groningen  
 The Netherlands  
 Tel.: +31 50 3612567  
 Fax: +31 50 3611136  
 e-mail: h.j.a.meijer@kchir.umcg.nl

**Key words:** adjacent implants, aesthetics, dental implants

## Abstract

**Aim:** The aim of this prospective comparative pilot study was to evaluate hard and soft peri-implant tissues in patients with a missing adjacent central and lateral upper incisor treated with either one implant and an implant crown with a cantilever or two implants with solitary implant crowns up to 1 year after functional loading.

**Material and methods:** In the "Implant-cantilever group", five patients were treated with one dental implant in the region of the central incisor (NobelReplace Groovy Regular Platform). In the "Implant-implant group", five patients were treated with two adjacent dental implants: at the position of the central incisor (NobelReplace Groovy Regular Platform) and at the position of the lateral incisor (NobelReplace Groovy Narrow Platform). Implant survival, pocket probing depth, papilla index, marginal bone level and patient satisfaction were assessed during a 1-year follow-up period.

**Results:** No implants were lost during the 1-year follow-up. Mean pocket probing values of the implants were comparable between the two groups. Papilla index scores in both groups were relatively low, pointing towards a compromised papilla. Marginal bone loss was minimal and comparable between the groups. Patient satisfaction was very high in both groups.

**Conclusion:** In this 1-year prospective comparative study, no large differences in hard- and soft-tissue levels could be shown between patients with a missing central and lateral upper incisor treated with either one implant and an implant crown with a cantilever or two implants with solitary implant crowns.

Dental implants are increasingly being applied in the aesthetic zone; therefore, it is essential to be able to establish a predictable aesthetic result. According to the professionals' opinion, dental implant crowns in the aesthetic zone are successful if a harmonious anatomical outcome has been established with the right dimensions of white and pink structures (Belser et al. 2004; Meijndert et al. 2007). On the other hand, regeneration of a soft-tissue contour with intact inter-proximal papillae and a gingival outline that is harmonious with the gingival silhouette of the adjacent teeth appears to be one of the major challenges (Den Hartog et al. 2008). In case of a single-tooth replacement, the presence of inter-proximal papillae is determined predominantly by the attachment level of the neighbouring teeth (Kan et al. 2003; Grunder et al. 2005; Kourkouta et al. 2009), which favours the aesthetic outcome of single-tooth replacements in case of periodontally unaffected neighbouring teeth. However, the advantage of having neighbouring teeth on both sides of a single-tooth replacement is not present if two adjacent teeth are missing. As a result, the

presence of a papilla between two implant crowns is predominantly dictated by the highest bone level between the implants (Kourkouta et al. 2009). Inter-implant distance appears to be another important factor in the preservation of bone height between two adjacent implants and should be at least 3 mm. In case of an inter-implant distance of < 3 mm, a loss of crestal bone height can be expected. This is caused by the lateral component of the peri-implant bone loss around implants. Overlap of both resorption areas between the adjacent implants will eventually result in vertical reduction of the inter-implant bone crest level (Tamow et al. 2000; Castaldo et al. 2004; Kourkouta et al. 2009). The reduced papilla height between two adjacent implants in comparison with single-tooth replacement complicates the aesthetic outcome. Only a maximum of 3 mm of inter-implant soft-tissue height should be expected instead of 3–5 mm of soft-tissue height between an implant and a natural tooth (Castaldo et al. 2004). To avoid black triangles and ensure that the distance between the contact point and the inter-implant bone

## Date:

Accepted 13 June 2010

## To cite this article:

Tymstra N, Raghoobar GM, Vissink A, Meijer HJA. Dental implant treatment for two adjacent missing teeth in the maxillary aesthetic zone: a comparative pilot study and test of principle. *Clin. Oral Impl. Res.* 22, 2011; 207–213.  
 doi: 10.1111/j.1600-0501.2010.02017.x

crest is fully filled with soft tissue, the contact point of the two adjacent implant crowns should be positioned more apically to obtain a longer contact area. This technique is often used in case of compromised papilla presence, but impedes the manufacture of harmonious anatomically shaped crowns.

Therefore, the purpose of rehabilitation in the aesthetic zone should be to maintain bone around implants at an ideal level. Vertical and lateral bone loss around most implant systems at the interface of implant and abutment is up to 1.5 mm and is due to chronic irritation from bacteria products out of this interface (Hermann et al. 1997; Tarnow et al. 2000; Cardaropoli et al. 2006). This means that bone around implants must be at least 1.5 mm wide at the approximal sides to ensure that the level of bone crest and thus the level of soft tissue remain stable. Sometimes, when the two missing adjacent teeth are an upper central incisor and a lateral incisor, there is lack of space to create enough distance between the implants and between the implants and their neighbouring teeth. Also, utilization of a smaller diameter implant in the region of the lateral incisor does not solve this problem. It is suggested that platform-switched implants, with less widespread lateral resorption, could have an effect (Rodríguez-Ciurana et al. 2009). Another option could be to place only one implant in the region of the central incisor and a prosthetic restoration consisting of an implant crown on this implant connected with a cantilever at the position of the lateral incisor. In this option, bone crest height is not affected by the lateral resorption of the adjacent implant. This option has not been evaluated so far in the literature. Therefore, the purpose of this prospective comparative pilot study was to evaluate hard and soft peri-implant tissue levels of patients with a missing central and lateral upper incisor treated with either one implant and a prosthetic restoration with a cantilever or two implants with solitary restorations up to 1 year after functional loading.

## Methods

### Patient selection

The patients selected for this study were referred to the Department of Oral and Maxillofacial Surgery (University Medical Center Groningen, University of Groningen, Groningen, the Netherlands) for implant therapy. To be included in this study, patients had to present with two missing adjacent teeth, a central and a lateral maxillary incisor. All patients had to be 18 years or older and were included in the study only after

providing informed consent. The study was approved by the hospital medical ethical committee and written informed consent was obtained from all patients. Patients were selected on the basis of the following inclusion criteria:

- sufficient mesio-distal, bucco-lingual and interocclusal space available for the placement of two implant-retained restorations with the right anatomical design;
- sufficient bone available for the placement of two dental implants with a minimum inter-implant distance of at least 3 mm and a minimum tooth-implant distance of 1.5 mm (if required, a bone augmentation procedure was performed at least 4 months before implant placement) and
- implant site free from infection.

Exclusion criteria for this study were as follows:

- presence of medical and general contraindications for the surgical procedures;
- presence of active and uncontrolled periodontal disease;
- bruxism;
- smoking;
- history of previous dental implant therapy in the same region and
- history of local radiotherapy to the head and neck region.

The study population was divided into two groups:

- (1) "Implant-cantilever group": Five patients to treat with one dental implant in the region of the central incisor (NobelReplace Groovy Regular Platform; Nobel Biocare AB, Göteborg, Sweden); prosthetic restoration will consist of an implant crown connected with a cantilever at the position of the lateral incisor
- (2) "Implant-implant group": Five patients to treat with two adjacent dental implants (NobelReplace Groovy Regular Platform at the position of the central incisor and NobelReplace Groovy Narrow Platform at the position of the lateral incisor); prosthetic restoration will consist of two single-tooth implant crowns.

Treatment allocation was performed using a balancing procedure to provide for an equal distribution of patients over the treatment groups with regard to whether a preoperative augmentation was performed.

### Surgical and prosthetic procedures

All patients were treated at the same department (Oral and Maxillofacial Surgery, University Med-

ical Center Groningen, University of Groningen, Groningen, the Netherlands) by one experienced oral-maxillofacial surgeon and two experienced prosthodontists. Preoperatively, diagnostic casts were made with a diagnostic arrangement representing the future restoration in the ideal prosthetic position. Next, this ideal prosthetic position was transformed into a surgical guide from transparent acrylic resin (Vertex Castapress; Vertex-Dental BV, Zeist, the Netherlands). If it was clear that not enough bone was present to insert an implant with primary stability, a bone augmentation procedure was carried out with bone harvested from the retromolar region in a separate session. One day before implant placement, patients began using a 0.2% chlorhexidine mouthwash (Corsodyl; GlaxoSmithKline, Utrecht, the Netherlands). One hour before implant surgery, patients started taking antibiotics (amoxicillin 500 mg, three times daily for 7 days). Under local anaesthesia (Ultracaine D-S Forte; Aventis Pharma Deutschland GmbH, Frankfurt am Main, Germany), the implants were placed, according to the procedure prescribed by the manufacturer, guided by the surgical guide. The implants used in this study were tapered and roughened to the top of the implants with a titaniumoxide surface (TiUnite, Nobel Biocare AB, Göteborg, Sweden). A mucoperiosteal full-thickness flap was raised to provide a clear view of the surgery area. The shoulder of the implants was placed at a depth of 2–3 mm apical to the buccal and cervical aspects of the future clinical crown to allow soft tissue to develop an adequate emergence profile. The implants were placed with an insertion torque of at least 45 N cm. If necessary, the osseous crest was recontoured or slightly overcontoured to acquire a bone wall of at least 2 mm on the facial aspect of the implant. Furthermore, if part of the implant surface remained uncovered or if only a thin layer of labial bone was present, a local bone augmentation procedure was performed. For the simultaneous augmentation procedures, an autogenous bone graft, collected during drilling or harvested intra-orally, was combined with Bio-Oss® (Bio-Oss®, spongiosa granules (0.25–1 mm), Geistlich, Wolhusen, Switzerland) and overlaid with a Bio-Gide® GB membrane (Bio-Gide®, Geistlich). The wound was closed primarily with sutures (Ethilon 5-0, Johnson & Johnson Health Care, Piscataway, NJ, USA). For pain control, 600 mg ibuprofen (Brufen Bruis 600; Abott BV, Hoofddorp, the Netherlands) was prescribed, to be taken three times daily if needed. Following surgery, a temporary removable partial denture was adjusted to not exert pressure on the wound. Two weeks after implant surgery, the sutures were removed. Three months after implant

placement, the implants were uncovered and a healing abutment (NobelRepace healing abutment, Nobel Biocare AB) was placed.

One week after abutment connection, an open tray impression was made at the implant level using an impression post (Impression Coping Implant Level Open Tray for NobelRepace, Nobel Biocare AB), a custom acrylic resin impression tray (Lightplast base plates; Dreve Dentamid GmbH, Unna, Germany) and a polyether impression material (Impregum Penta; 3M ESPE, St Paul, MN, USA). In the dental laboratory, a screw-retained provisional restoration was fabricated, consisting of a temporary abutment (NobelRepace temporary abutment Engaging; Nobel Biocare AB) against which a veneering composite (Solidex; Shofu, Inc., Kyoto, Japan) was modelled. In the implant–cantilever group, the lateral incisor was modelled as a cantilever. A metal reinforcement was placed at the palatal side at the connection between the two composite crowns. The plaster cast was prepared in such a way that the lateral incisor could be overcontoured in the region of contact with the mucosa. In this way, the illusion was created that the cantilever crown emerged out of the mucosa. In the implant–implant group, two solitary screw-retained provisional restorations were fabricated. The provisional crowns were contoured so that the peri-implant soft tissue was optimally supported. Extra care was given to the inter-proximal areas: the inter-proximal papillae were provided enough space to regenerate. The cantilever crown was cleared from heavy contacts; only light contact was allowed. With excursion, all contact was avoided. One week after the impression was made, healing abutments were removed and the provisional implant crowns were placed and torqued to 32 N cm. For 3 months, the patients visited the prosthodontist once a month for examination. Three months later (6 months following implant placement), another implant-level impression was made for the fabrication of a definitive restoration. In the dental laboratory, a soft-tissue cast was prepared. First, a waxing of the definitive restoration was made on a temporary abutment (NobelRepace Temporary Abutment Engaging; Nobel Biocare AB). After that, the waxing was cut back to the desired form and scanned for fabrication of custom-made zirconia abutments (Procera, Nobel Biocare AB). If the screw access hole was located at the mid-palatal side, the porcelain was added directly to the abutment to create a screw-retained crown. If the access hole was not located at the mid-palatal side, a custom-made zirconia abutment was fabricated together with a full ceramic cement-retained restoration. Again, in the implant–cantilever group, the lateral incisor was modelled as a

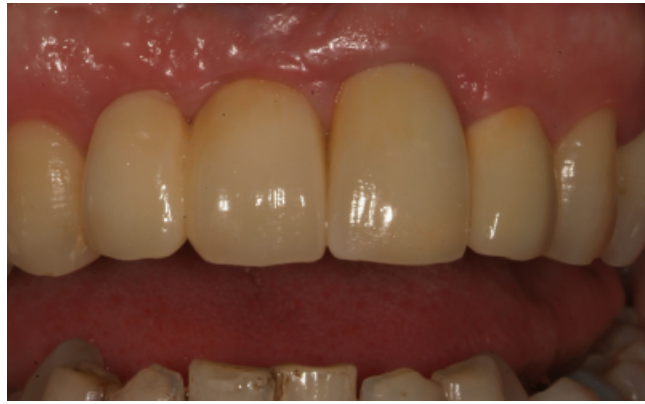

Fig. 1. Implant crown with a cantilever as a lateral incisor, dental implant located at the central incisor.

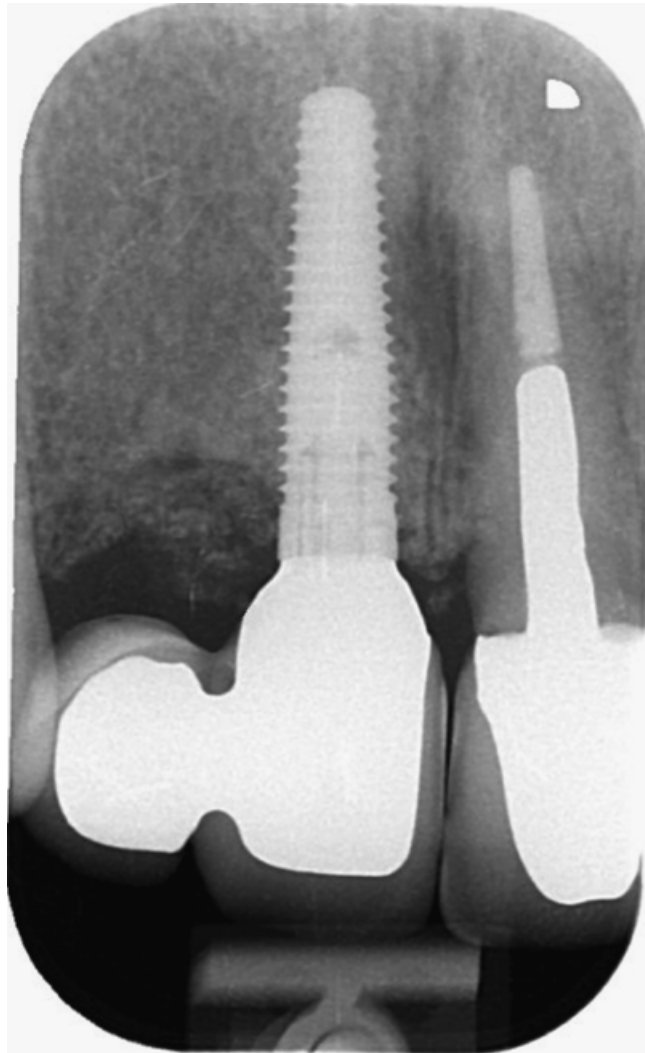


Fig. 2. Intraoral radiograph of dental implant and neighbouring teeth from the implant–cantilever group.

cantilever with a zirconia base connected to the centrally located restoration. The cantilever crown was cleared from heavy contacts; only light contact was allowed. With excursion, all contact was avoided. In the implant–implant group, two solitary restorations were fabricated.

Screw-retained restorations and zirconia abutments were torqued to 32 N cm. Screw holes of screw-retained restorations were filled with a cotton pellet composite resin (Clearfil AP-x; Kuraray Medical Inc., Okayama, Japan). Screw holes of abutments were filled with a cotton

pellet alone. Cement-retained restorations were fastened with Fuji Plus cement (GC, Alsip, IL, USA) (Fig. 1).

#### Data collection

Data were collected starting pre-operatively (Tpre), directly after implant surgery (Tpost), directly (within a month) after placement of the definitive implant crown (T0) and 1 year after placement of the definitive restoration (T1).

The following parameters were assessed:

- implant loss during the entire evaluation period;
- pocket probing depth at Tpre (only neighbouring teeth), T0 and T1: the depth was measured to the nearest millimetre at three locations around the implants and the neighbouring teeth (mid-buccally and at both approximal sides);
- papilla index according to Jemt (1997) at T1;
- marginal bone level and bone crest level: 2 weeks after implant placement and 1 year after placement of the definitive restoration, intraoral radiographs were taken using a standardized paralleling technique (Meijndert et al. 2008) (Fig. 2). A computer-assisted calibration was carried out in the horizontal plane and, if necessary, in the vertical plane for each radiograph. In the horizontal plane, the known dimension of the diameter of the implant was used to calibrate the radiograph.

If the implant was slightly angulated, the radiograph was also calibrated in the vertical plane using the known distance of several threads as calibration. This calibration ensured a correct measurement (Sewerin 1990). The radiographs were analysed using computer software to perform linear measurements on the digital radiographs. The measurements were performed by two observers to assess inter-observer differences. The mean of these two measurements was used for analysis of the data. In the vertical plane, the following linear measurements were assessed to the nearest 0.1 mm: (1) the interface of the implant and the abutment was used as a reference line (line *a*) from which all distances were measured, (2) the first bone to implant level: the vertical distance between line *a* and the first bone to implant level, measured at the implant side facing the adjacent implant and at the implant side facing the neighbouring tooth, (3) the bone level of the neighbouring tooth: the vertical distance between line *a* and the first bone to tooth level, (4) the bone crest level: the vertical distance between line *a* and the most coronal bone peak of the inter-implant bone crest and the most coronal bone peak of the bone crest between the implants and their neighbouring teeth and

- a subjective appreciation of the final result of the treatment was assessed using a patient

questionnaire modified from the one used by Meijndert et al. (2007). The questionnaire comprised an overall satisfaction score (range 0–10), two questions concerning the implant-supported restoration and two questions concerning the peri-implant mucosa (possible score 0–4)

#### Statistical analysis

Because of the setting being a pilot study, statistical analysis has been restricted to means, median and standard deviation.

#### Results

Mean age in the implant–cantilever group was 33 years (range 20–43) and two males and three females were present in this group. The mean age in the implant–implant group was 28 years (range 18–49), and four males and one female were present in this group. The reason for tooth loss was trauma for all patients in both groups. All 10 patients could be evaluated during the 1-year evaluation period. No implants failed in any group during the 1-year follow-up. Mean and median pocket probing depths are listed in Table 1. These pocket probing values of the implants are in line with each other in the two groups. Pocket probing depths are larger around the implants than around the natural neighbouring teeth. Papilla indices are listed in Table 2. Scores are relatively low, pointing towards a

**Table 1.** Mean, SD and median of pocket probing depth (mm) measured around implants and neighbouring teeth at the proximal sides facing the adjacent implant, midbuccally and the proximal sides facing the adjacent tooth

Location		Implant–cantilever						Implant–implant					
		Tpre		T0		T1		Tpre		T0		T1	
		Mean (SD)	Median	Mean (SD)	Median	Mean (SD)	Median	Mean (SD)	Median	Mean (SD)	Median	Mean (SD)	Median
Central incisor	Proximal side facing adjacent tooth	2 (0.71)	2	2 (0.71)	2	2.2 (0.84)	2	2.2 (0.45)	2	1.8 (0.45)	2	2.4 (0.55)	2
	Midbuccally	1.4 (0.55)	1	1.8 (0.45)	2	1.6 (0.55)	2	1.6 (0.55)	2	1.4 (0.55)	1	1.4 (0.55)	1
	Proximal side facing adjacent implant	3 (0.71)	3	2 (0.71)	2	2.2 (1.10)	2	2 (0.71)	2	1.8 (0.45)	2	2.2 (0.84)	2
Central implant	Proximal side facing adjacent tooth	NA	NA	3.4 (0.89)	4	3.4 (1.52)	3	NA	NA	2.2 (0.84)	2	2.2 (0.84)	2
	Midbuccally	NA	NA	3 (0.71)	3	3.2 (1.1)	3	NA	NA	2.2 (0.84)	2	2.8 (0.45)	3
	Proximal side facing no implant/adjacent lateral implant	NA	NA	4.4 (0.89)	5	3.8 (1.10)	4	NA	NA	2.4 (0.55)	2	4 (1)	4
No implant/lateral implant	Proximal side facing adjacent implant	NA	NA	NA	NA	NA	NA	NA	NA	3.2 (1.64)	2	3.6 (0.89)	3
	Midbuccally	NA	NA	NA	NA	NA	NA	NA	NA	3 (1)	3	3.6 (0.89)	3
	Proximal side facing adjacent tooth	NA	NA	NA	NA	NA	NA	NA	NA	2.8 (0.45)	3	3.8 (1.3)	3
Cuspid	Proximal side facing no implant/adjacent lateral implant	2.8 (1.3)	3	2 (0)	2	2.4 (0.55)	2	2.2 (0.45)	2	2 (0)	2	2.6 (0.55)	3
	Midbuccally	1 (0)	1	1 (0)	1	1 (0)	1	1.2 (0.45)	1	1 (0)	1	1.6 (0.55)	2
	Proximal side facing adjacent tooth	2.6 (0.55)	3	2.4 (0.55)	2	2 (0.71)	2	2.4 (0.55)	2	2.2 (0.45)	2	2.4 (0.55)	2

NA, not applicable; Tpre, evaluation visit before implant surgery; T0, evaluation visit directly after placement of definitive restoration; T1, evaluation visit 1 year after placement of definitive restoration.

compromised papilla presence. The frequency distributions of the scores of both groups are more or less the same. The mean marginal bone level, the bone crest level and changes during the evaluation period are listed in Table 3. Marginal bone loss occurs, yielding similar results for both groups. Patients' opinion is listed in Table 4. Patient satisfaction is more or less the same in both groups and is very high, with a mean overall satisfaction score of 8.8 for

the implant–cantilever group and 9.2 for the implant–implant group.

### Discussion

Reporting no implant failures of a study group with solitary implant crowns in the aesthetic region, conventional healing and a follow-up period of at least 1 year is not uncommon.

Palmer et al. (1997), Jemt & Lekholm (2003), Cardaropoli et al. (2006) and Zarone et al. (2006) all reported a 100% survival rate. In general, survival rates of implants are very high in this region (Den Hartog et al. 2008). However, survival rates of implants supporting a crown with a cantilever has not been reported so far. It must be noted that the cantilever crown was cleared from heavy contacts; only light contact was allowed. However, higher forces may have an impact on the cantilever during biting, thus exerting moment forces on the implant.

Mean pocket probing values around the implants of both groups were comparable; the presence of a cantilever and possible moment forces on the implant apparently has no or negligible negative effect on the pocket probing depth. Mean pocket probing depths were larger around the implants than around the natural neighbouring teeth. The observed values and difference between implants and natural teeth is in agreement with other studies (Bragger et al. 1997; Hultin et al. 2000; Meijndert et al. 2008). This is due to the biological width being different around natural teeth compared with implants

**Table 2.** Frequency distribution of scores of papilla index 1 year after placement of the definitive crown

Score	T1					
	Implant–cantilever			Implant–implant		
	Central–implant	Implant–cantilever	Cantilever–cuspid	Central–implant	Implant–implant	Implant–cuspid
0	0	1	0	1	1	0
1	0	3	1	0	3	1
2	3	1	1	4	1	2
3	2	0	3	0	0	2
4	0	0	0	0	0	0

Score 0, no papilla formation; score 1, less than half of the papilla; score 2, at least half of the papilla is present; score 3, papilla fills whole approximate space; score 4, abundance of papilla.

**Table 3.** Mean, SD and Median of marginal bone level, bone crest level and changes during the evaluation period in mm

Location	Implant–cantilever						Implant–implant						
	Tpost		T1		Tpost–T1		Tpost		T1		Tpost–T1		
	Mean (SD)	Median	Mean (SD)	Median	Mean (SD)	Median	Mean (SD)	Median	Mean (SD)	Median	Mean (SD)	Median	
Central incisor	Marginal bone level facing the adjacent central implant	–1.63 (0.84)	–1.3	–2.14 (0.72)	–2.0	+0.51 (0.33)	–0.5	–1.83 (1.48)	–1.4	–2 (1.58)	–1.4	+0.17 (1.42)	0.3
Bone crest	Bone crest level between central incisor and central implant	–2.2 (0.56)	–2.1	–2.41 (0.64)	–2.2	+0.21 (0.69)	–0.1	–1.89 (1.5)	–1.8	–1.92 (1.6)	–1.2	–0.03 (1.61)	0.6
Central implant	Marginal bone level facing the adjacent central incisor	–0.02 (0.04)	0	0.88 (0.72)	0.6	–0.9 (0.74)	0.6	0.03 (0.08)	0.1	0.95 (0.23)	1.	–0.92 (0.27)	1
	Marginal bone level facing no implant/lateral implant	0.06 (0.14)	0	1.92 (1.23)	2.5	–1.85 (1.16)	2.5	0.37 (0.64)	0.1	1.34 (0.32)	1.2	–0.97 (0.5)	1.1
Bone crest	Bone crest level between central implant and no implant/lateral implant	–1.19 (0.9)	–1.7	–0.06 (1.92)	–1	–1.13 (1.05)	0.8	–0.38 (0.6)	–0.4	0.96 (0.54)	0.8	–1.34 (0.7)	1.6
No implant/lateral implant	Marginal bone level facing the adjacent central implant							0.34 (0.46)	0.3	1.37 (0.84)	1	–1.03 (1.16)	0.7
	Marginal bone level facing the adjacent cuspid							0.43 (0.48)	0.4	1.33 (0.26)	1.4	–0.9 (0.35)	1
Bone crest	Bone crest level between no implant/lateral implant and cuspid	–1.32 (1.67)	–0.5	–1.05 (1.78)	–0.8	–0.27 (0.43)	0.2	–1.65 (0.97)	–1.8	–1.44 (0.86)	–1.8	–0.21 (1.32)	0.2
Cuspid	Marginal bone level facing the adjacent no implant/lateral implant	–1.29 (1.76)	–0.3	–1.01 (1.8)	–0.7	–0.28 (0.47)	0.3	–1.38 (0.93)	–1.5	–1.15 (0.68)	–1.0	–0.23 (0.95)	0.6

Positive numbers in the column Tpost and T1 mean a bone level apically of the reference line (= microgap).  
 Negative numbers in the column Tpost–T1 mean bone loss during the evaluation period.  
 Tpost, evaluation visit directly after implant surgery; T1, evaluation visit 1 year after placement of definitive restoration.

**Table 4.** Frequency scores of the satisfaction questionnaire about the appearance of the implant crown, the appearance of the mucosa and the mean and SD of the overall appearance of the implant crowns

Score	Implant–cantilever group (n = 5)					Implant–implant group (n = 5)				
	0	1	2	3	4	0	1	2	3	4
Shape of the crown	0	0	0	1	4	0	1	0	0	4
Colour of the crown	0	0	0	0	5	0	0	0	1	4
Shape of the mucosa	0	0	3	0	2	0	1	0	1	3
Colour of the mucosa	0	1	0	1	3	0	0	0	2	3
	Mean (SD)					Mean (SD)				
Overall score (range 0–10)	8.8 (0.8)					9.2 (0.8)				

Implant crown and mucosa score: scale 0, completely dissatisfied; 1, dissatisfied; 2, neutral; 3, satisfied; 4, completely satisfied.  
Overall score: scale 0, completely dissatisfied to score 10, completely satisfied.

(Cochran et al. 1997), which might result in a stronger resistance to probing in a gingival sulcus around natural teeth when compared with a mucosal seal around implants (Ericsson & Lindhe 1993). Another factor that may influence the probing depth is the difference between the marginal bone height of the implants and the neighbouring teeth. The more coronally positioned marginal bone level of the teeth predominantly determines the inter-proximal soft-tissue level, resulting in deeper pockets on the proximal side of the implants with a more apical positioning of the marginal bone level.

Papilla indices are listed in Table 2. Scores were relatively low, pointing towards a compromised papilla presence. There were no significant differences in the frequency distribution of the scores between the groups. Scores were the same for the presence of the papilla between the implant crown and the cantilever and the papilla between the two implant-neighbouring implant crowns. In both groups, the inter-implant papillae scored worse compared with papillae between an implant and a natural tooth. In case of two missing adjacent teeth, the bone condition in most cases is compromised. Because of resorption, the characteristic inter-dental bone peak is missing, which causes an underdevelopment of the papilla in that region (Tamow et al. 1992).

The mean marginal bone level, the bone crest level and changes during the evaluation period are listed in Table 3. There were no significant differences between the groups. A marginal bone loss of 0.9–1.8 mm mesially and distally

of the implants occurred in the period from the placement of the implants to 1 year after placement of the definitive crowns. Marginal bone level was, at placement of the implants, more or less at the level of the top of the implant. This phenomenon of resorption of bone in the vicinity of the microgap has been described as a result of a chronic irritant, such as bacteria, coming from the implant–abutment interface. A resorption of 1.5–2 mm has been reported (Hermann et al. 1997; Tamow et al. 2000). On the other hand, the mean marginal bone loss at the side of the implants facing the cantilever tended to be slightly larger in comparison with the other approximal implant sides of the implant–cantilever group and the implant–implant group. Mean bone crest resorption distally of the central implant in the implant–cantilever group was comparable with the mean inter-implant bone crest resorption between the central implant and the lateral implant in the implant–implant group. Mean bone crest resorption distally of the central implant in the implant–cantilever group is 1.1 mm. Mean bone crest resorption between the central implant and the lateral implant in the implant–implant group is 1.4 mm. Although the inter-implant distance is more than 3 mm, there could still be an effect of a lateral resorption area. Considerably large standard deviations were observed for mean changes in the marginal bone level and the crestal bone level. Similar observations were reported in other studies (Palmer et al. 2000; Small & Tamow 2000; Steveling et al. 2001; Karoussis et al. 2003; Tawil & Younan

2003; Meijndert et al. 2008). The large standard deviations suggest a considerable variability in changes in the marginal bone level between individual patients, making a reliable prediction of the expected changes in hard and soft peri-implant tissues for an individual patient rather difficult. Variations in the distance from the contact point to the approximal crestal bone and variations in the level of the marginal approximal bone of the adjacent might be the basis of the variation in individual changes of the approximal peri-implant tissues (Tamow et al. 1992; Kan et al. 2003; Grunder et al. 2005).

Patients' opinion is listed in Table 4. Patient satisfaction was very high, without differences between the groups. It appears from the papilla index scores that the presence of papillae, especially between the implant crown and cantilever and the adjacent implant crowns, is compromised. This disagreement has been described before by Meijndert et al. (2007). Also, in this study, patients were less critical than one might expect.

As no significant differences can be found between the two treatment options, it is beneficial and cost-effective to choose the prosthodontic solution of one implant restored with an implant crown and cantilever. More patients in the study groups are required based on a power analysis to confirm the findings of this pilot study with a thorough statistical analysis.

## Conclusions

In this 1-year prospective comparative study, no significant differences in hard- and soft-tissue levels were observed between patients with a missing central and lateral upper incisor treated with either one implant and an implant crown with a cantilever or two implants with solitary implant crowns. Thus, a prosthodontic solution wherein patients with a missing central and lateral upper incisor are treated with only one implant restored with an implant crown and cantilever could serve as an alternative for treatment with two implants restored with solitary implant crowns.

## References

- Belser, U.C., Schmid, B., Higginbottom, F. & Buser, D. (2004) Outcome analysis of implant restorations located in the anterior maxilla: a review of the recent literature. *The International Journal of Oral & Maxillofacial Implants* **19** (Suppl.): 30–42.
- Bragger, U., Burgin, W.B., Hämmerle, C.H. & Lang, N.P. (1997) Associations between clinical parameters assessed around implants and teeth. *Clinical Oral Implants Research* **8**: 412–421.
- Castaldo, J.F., Cury, P.R. & Sendyk, W.R. (2004) Effect of the vertical and horizontal distances between adjacent implants and between a tooth and an implant on the incidence of interproximal papilla. *Journal of Periodontology* **75**: 1242–1246.
- Cardaropoli, G., Lekholm, U. & Wennström, J.L. (2006) Tissue alterations at implant-supported single-tooth replacements: a 1-year prospective clinical study. *Clinical Oral Implants Research* **17**: 165–171.
- Cochran, D.L., Hermann, J.S., Schenk, R.K., Higginbottom, F.L. & Buser, D. (1997) Biologic width around titanium implants. A histometric analysis of

- the implanto-gingival junction around unloaded and loaded nonsubmerged implants in the canine mandible. *Journal of Periodontology* **68**: 186–198.
- Den Hartog, L., Slater, J.J., Vissink, A., Meijer, H.J. & Raghoebar, G.M. (2008) Treatment outcome of immediate, early and conventional single tooth implants in the aesthetic zone: a systematic review to survival, bone level, soft-tissue, aesthetics and patient satisfaction. *Journal of Clinical Periodontology* **35**: 1073–1086.
- Ericsson, I. & Lindhe, J. (1993) Probing depth at implants and teeth. An experimental study in the dog. *Journal of Clinical Periodontology* **20**: 623–627.
- Grunder, U., Gracis, S. & Capelli, M. (2005) Influence of the 3-D bone-to-implant relationship on esthetics. *International Journal of Periodontics and Restorative Dentistry* **25**: 1113–1119.
- Hermann, J.S., Cochran, D.L., Nummikoski, P.V. & Buser, D. (1997) Crestal bone changes around titanium implants. A radiographic evaluation of unloaded non-submerged and submerged implants in the canine mandible. *Journal of Periodontology* **68**: 1117–1130.
- Hultin, M., Gustafsson, A. & Klinge, B. (2000) Long-term evaluation of osseointegrated dental implants in the treatment of partly edentulous patients. *Journal of Clinical Periodontology* **27**: 128–133.
- Jemt, T. (1997) Regeneration of gingival papillae after single-implant treatment. *International Journal of Periodontics and Restorative Dentistry* **17**: 326–333.
- Jemt, T. & Lekholm, U. (2003) Measurements of buccal tissue volumes at single-implant restorations after local bone grafting in maxillas: a 3-year clinical prospective study case series. *Clinical Implant Dentistry & Related Research* **5**: 63–70.
- Kan, J.Y., Rungcharassaeng, K., Umezumi, K. & Kois, J.C. (2003) Dimensions of peri-implant mucosa: an evaluation of maxillary anterior single implants in humans. *Journal of Periodontology* **74**: 557–562.
- Karoussis, I.K., Salvi, G.E., Heitz-Mayfield, L.J., Bragger, U., Hämmerle, C.H. & Lang, N.P. (2003) Long-term implant prognosis in patients with and without a history of chronic periodontitis: a 10-year prospective cohort study of the ITI dental implant system. *Clinical Oral Implants Research* **14**: 329–339.
- Kourkouta, S., Dedi, K.D., Paquette, D.W. & Mol, A. (2009) Interproximal tissue dimensions in relation to adjacent implants in the anterior maxilla: clinical observations and patient aesthetic evaluation. *Clinical Oral Implants Research* **20**: 1375–1385.
- Meijndert, L., Meijer, H.J.A., Stellingsma, K., Stegenga, B. & Raghoebar, G.M. (2007) Evaluation of aesthetics of implant-supported single-tooth replacements using different bone augmentation procedures: a prospective randomized clinical study. *Clinical Oral Implants Research* **18**: 715–719.
- Meijndert, L., Raghoebar, G.M., Meijer, H.J. & Vissink, A. (2008) Clinical and radiographic characteristics of single-tooth replacements preceded by local ridge augmentation: a prospective randomized clinical trial. *Clinical Oral Implants Research* **19**: 1295–1303.
- Palmer, R.M., Palmer, P.J. & Smith, B.J. (2000) A 5-year prospective study of astra single tooth implants. *Clinical Oral Implants Research* **11**: 179–182.
- Palmer, R.M., Smith, B.J., Palmer, P.J. & Floyd, P.D. (1997) A prospective study of Astra single tooth implants. *Clinical Oral Implants Research* **8**: 173–179.
- Rodriguez-Ciurana, X., Vela-Nebot, X., Segalà-Torres, M., Calvo-Guirado, J.L., Cambra, J., Méndez-Blanco, V. & Tamow, D.P. (2009) The effect of interimplant distance on the height of the interimplant bone crest when using platform-switched implants. *International Journal of Periodontics and Restorative Dentistry* **29**: 141–151.
- Sewerin, I.P. (1990) Errors in radiographic assessment of marginal bone height around osseointegrated implants. *Scandinavian Journal of Dental Research* **98**: 428–433.
- Small, P.N. & Tamow, D.P. (2000) Gingival recession around implants: a 1-year longitudinal prospective study. *The International Journal of Oral & Maxillofacial Implants* **15**: 527–532.
- Stevelling, H., Roos, J. & Rasmusson, L. (2001) Maxillary implants loaded at 3 months after insertion: results with astra tech implants after up to 5 years. *Clinical Implant Dentistry & Related Research* **3**: 120–124.
- Tamow, D.P., Cho, S.C. & Wallace, S.S. (2000) The effect of inter-implant distance on the height of inter-implant bone crest. *Journal of Periodontology* **71**: 546–549.
- Tamow, D.P., Magner, A.W. & Fletcher P. (1992) The effect of the distance from the contact point to the crest of bone on the presence or absence of the interproximal dental papilla. *Journal of Periodontology* **63**: 995–996.
- Tawil, G. & Younan, R. (2003) Clinical evaluation of short, machined-surface implants followed for 12 to 92 months. *The International Journal of Oral & Maxillofacial Implants* **18**: 894–901.
- Zarone, F., Sorrentino, R., Vaccaro, F. & Russo, S. (2006) Prosthetic treatment of maxillary lateral incisor agenesis with osseointegrated implants: a 21–39 month prospective clinical study. *Clinical Oral Implants Research* **17**: 94–101.