

University of Groningen

Fatal N-butyl-2-cyanoacrylate pulmonary embolism after sclerotherapy for variceal bleeding
van Beek, A.P.; van Erpecum, KJ

Published in:
Endoscopy

DOI:
[10.1055/s-2005-861427](https://doi.org/10.1055/s-2005-861427)

IMPORTANT NOTE: You are advised to consult the publisher's version (publisher's PDF) if you wish to cite from it. Please check the document version below.

Document Version
Publisher's PDF, also known as Version of record

Publication date:
2005

[Link to publication in University of Groningen/UMCG research database](#)

Citation for published version (APA):

van Beek, A. P., & van Erpecum, K. J. (2005). Fatal N-butyl-2-cyanoacrylate pulmonary embolism after sclerotherapy for variceal bleeding. *Endoscopy*, 37(7), 687. DOI: 10.1055/s-2005-861427

Copyright

Other than for strictly personal use, it is not permitted to download or to forward/distribute the text or part of it without the consent of the author(s) and/or copyright holder(s), unless the work is under an open content license (like Creative Commons).

Take-down policy

If you believe that this document breaches copyright please contact us providing details, and we will remove access to the work immediately and investigate your claim.

Downloaded from the University of Groningen/UMCG research database (Pure): <http://www.rug.nl/research/portal>. For technical reasons the number of authors shown on this cover page is limited to 10 maximum.

A 30-year-old man presented with hematemesis. Five years earlier, he had been diagnosed with *Escherichia coli* liver abscesses, without a clear underlying cause being identified. Although he recovered with antibiotic treatment, extensive thrombosis of the portal, splenic, and superior mesenteric veins remained. The patient received prophylactic propranolol for a large fundic varix, and oral anticoagulants during the first year as well. Endoscopic evaluation during the current admission revealed bleeding from the fundic varix, and an injection of 1 ml *N*-butyl-2-cyanoacrylate (enbucrilate, Histoacryl), 0.5/0.8 (v/v) diluted with Lipiodol, was administered. Although the hemorrhage was temporarily stopped, repeated cyanoacrylate injections (two injections of 1 ml) and subsequent placement of a Sengstaken-Blakemore tube had to be carried out due to recurrent severe bleeding.

The same day, a partial gastrectomy, splenectomy, and esophageal transection were performed. Postoperative chest radiography (Figure 1, left) and computed tomography (Figure 1, top right) revealed multiple cyanoacrylate pulmonary emboli. Mechanical ventilation had to be started. Abdominal sepsis from a subphrenic abscess, with multiple organ failure, subsequently occurred. Intravenous heparin therapy was started due to deep vein thrombosis in both legs. The patient showed further pulmonary deterioration (Figure 1, bottom right). Thirty-seven days after the initial sclerotherapy, he died of abdominal sepsis and deteriorating pulmonary function. No recurrent bleeding had occurred since the surgical procedure.

Although cyanoacrylate is generally regarded as the first-line treatment for bleeding gastric varices [1], complications may occur, such as the needle adhering to the varix, pyrexia, deep ulceration due to accidental paravariceal injection, and in particular pulmonary embolism [2,3]. Risk factors for pulmonary embolism are: more than 1 ml cyanoacrylate-Lipiodol per injection, excess Lipiodol (cyanoacry-

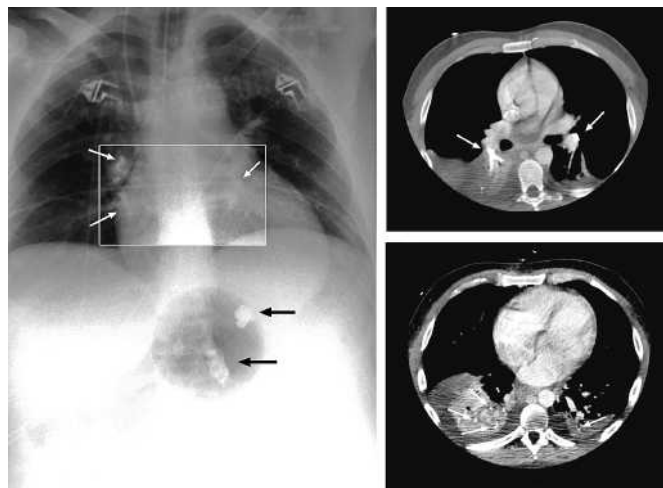


Figure 1 **Left:** A chest radiograph showing multiple pulmonary emboli (white arrows) and two large fragments of Cyanoacrylate in the upper abdomen (black arrows). **Top right:** Postoperative computed tomogram, showing multiple cyanoacrylate pulmonary emboli on both sides (arrows), with an increased signal intensity in the segmental and subsegmental pulmonary arteries. **Bottom right:** Computed tomograph approximately 2 weeks after the onset of the pulmonary emboli, showing pulmonary infarction, formation of bullae, extensive consolidation, pleural effusions, and residual enbucrilate (arrows).

late/lipiodol ratio below 5:8 v/v), injection of excess distilled water with the needle still located in the varix [4], and slow injection, especially in case of varices with a high flow rate and a large diameter [5]. Surgery is still a valuable treatment alternative, especially in cases of left-sided portal hypertension.

A. P. van Beek¹, K. J. van Erpecum²

¹ Dept. of Internal Medicine, University Medical Center, Utrecht, The Netherlands

² Dept. of Gastroenterology, University Medical Center, Utrecht, The Netherlands.

References

- Lo GH, Lai KH, Cheng JSet al. A prospective, randomized trial of butyl cyanoacrylate injection versus band ligation in the management of bleeding gastric varices. *Hepatolgy* 2001; 33: 1060–1064
- Tsokos M, Bartel A, Schoel Ret al. [Fatal pulmonary embolism after endoscopic embolization of downhill esophageal varix; in German]. *Dtsch Med Wochenschr* 1998; 123: 691–695

³ Naga M, Foda A. An unusual complication of Histoacryl injection. *Endoscopy* 1997; 29: 140

⁴ Seewald S, Sriram PV, Naga Met al. Cyanoacrylate glue in gastric variceal bleeding. *Endoscopy* 2002; 34: 926–932

⁵ Suga T, Akamatsu T, Kawamura Yet al. Actual behavior of *N*-butyl-2-cyanoacrylate (Histoacryl) in a blood vessel: a model of the varix. *Endoscopy* 2002; 34: 73–77

Corresponding Author

A. P. van Beek, M.D., Ph.D.

Dept. of Internal Medicine,
Dept. of Endocrinology, De Beng 4^{ob},
Groningen University Medical Center
P.O. Box 30001
9700 RB Groningen
The Netherlands
Fax: +31-50-3619308
E-mail: a.p.van.beek@int.azg.nl