

University of Groningen

Early loading of endosseous implants in the augmented maxilla

Raghoobar, Gerry; Schoen, Pieter; Meijer, Hendrikus; Stellingsma, Cornelius; Vissink, Arjan

Published in:
CLINICAL ORAL IMPLANTS RESEARCH

DOI:
[10.1046/j.0905-7161.2003.00953.x](https://doi.org/10.1046/j.0905-7161.2003.00953.x)

IMPORTANT NOTE: You are advised to consult the publisher's version (publisher's PDF) if you wish to cite from it. Please check the document version below.

Document Version
Publisher's PDF, also known as Version of record

Publication date:
2003

[Link to publication in University of Groningen/UMCG research database](#)

Citation for published version (APA):

Raghoobar, G. M., Schoen, P., Meijer, H. J. A., Stellingsma, K., & Vissink, A. (2003). Early loading of endosseous implants in the augmented maxilla: A 1-year prospective study. *CLINICAL ORAL IMPLANTS RESEARCH*, 14(6), 697-702. DOI: 10.1046/j.0905-7161.2003.00953.x

Copyright

Other than for strictly personal use, it is not permitted to download or to forward/distribute the text or part of it without the consent of the author(s) and/or copyright holder(s), unless the work is under an open content license (like Creative Commons).

Take-down policy

If you believe that this document breaches copyright please contact us providing details, and we will remove access to the work immediately and investigate your claim.

Downloaded from the University of Groningen/UMCG research database (Pure): <http://www.rug.nl/research/portal>. For technical reasons the number of authors shown on this cover page is limited to 10 maximum.

Gerry M. Raghoebar
Pieter Schoen
Henny J. A. Meijer
Kees Stellingsma
Arjan Vissink

Early loading of endosseous implants in the augmented maxilla: a 1-year prospective study

Authors' affiliations:

Gerry M. Raghoebar Pieter Schoen Henny J. A. Meijer Kees Stellingsma Arjan Vissink, Department of Oral and Maxillofacial Surgery and Maxillofacial Prosthetics, University Hospital Groningen, the Netherlands
Henny J. A. Meijer, Dental School, Faculty of Medical Sciences, University of Groningen, the Netherlands

Correspondence to:

Dr G. M. Raghoebar
Department of Oral and Maxillofacial Surgery and Maxillofacial Prosthetics
University Hospital Groningen,
PO Box 30.001
9700 RB Groningen
The Netherlands
Tel: +31 50 3613840
Fax: +31 50 3696724
e-mail: g.m.raghoebar@kchir.azg.nl

Key words: dental implants, early loading, autogenous bone graft, maxilla, rehabilitation

Abstract: In 10 patients, 68 endosseous implants were inserted in the augmented edentulous maxilla using a one-stage implant placement technique. Three months before implant insertion, the width and height of the alveolar crest were augmented with autologous bone grafts from the iliac crest. In all cases, the resulting bone volume was sufficient for implant insertion. According to an early loading protocol, the implant-supported overdenture was fabricated 2 months after insertion of the implants. Evaluation was performed according to a standardised protocol immediately and 1 year after fabrication of the prosthetic construction. The protocol included assessment of both clinical (bleeding score, pocket depth, implant mobility) and radiographic (marginal bone level on standardised radiographs) parameters. Three implants in two patients in the upper jaw were lost (survival rate: 95.6%). The peri-implant tissues had a healthy appearance and bone loss was minimal. Overall, the patients were very satisfied with the prosthetic construction. From this preliminary study, it is concluded that in selected cases, early loading of implants may develop into a predictable treatment modality after augmentation of the maxilla.

Implant-supported fixed and removable prostheses provide a proper treatment modality with reliable success, especially for the rehabilitation of an edentulous mandible (Adell et al. 1981; Engquist et al. 1988; Jemt et al. 1996; Batenburg et al. 1998). Prosthetic rehabilitation of the edentulous maxilla using endosseous implants is often limited by insufficient quality and quantity of bone. Several grafting procedures have been described to create sufficient volume of bone for the placement of implants in atrophic maxillae, including total or segmental bone onlays, Le Fort I osteotomy with interpositional bone grafts, and grafting of the maxillary sinus with autogenous bone or bone substitutes. In particular, bone grafting of the floor of the maxillary sinus with autogenous bone for the insertion of implants has been shown to be a

reliable treatment modality with good long-term results (Raghoebar et al. 2001).

The multistep process of endosseous implant therapy is time-consuming and may limit patient acceptance. In the past, one-stage surgery has already solved part of this problem and has developed to a proven alternative (Batenburg et al. 1998). The next steps in increasing patient acceptance are thought to be early loading (maxillary prosthetic construction provided within 8 weeks after implant placement) and immediate loading (prosthetic construction provided on the day of implant placement). Whether immediate or early loading is possible depends, among others, on bone and soft tissue quality. Several immediate and early loading studies have been performed over the last decades. These studies indicate that immediate (Ledermann 1979,

Date:

Accepted 10 October 2002

To cite this article:

Raghoebar GM, Schoen P, Meijer HJA, Stellingsma K, Vissink A. Early loading of endosseous implants in the augmented maxilla: a 1-year prospective study. *Clin. Oral Impl. Res.* 14, 2003; 697–702

1984; Schnitman et al. 1990, 1997; Henry & Rosenberg 1994; Salama et al. 1995; Spiekerman et al. 1995; Balshi & Wolfinger 1997; Chiapasco et al. 1997; Tamow et al. 1997; Horiuchi et al. 2000; Andersen et al. 2002) and early (Lazzara et al. 1998; Randow et al. 1999; Ericsson et al. 2000; Rocuzzo et al. 2001; Røynesdal et al. 2001; Cochran et al. 2002; Testori et al. 2002) loading can be applied with good success. Immediate loading means functional loading within 72 h after insertion of the implants, while early loading refers to functional loading within half of the conventional healing time. Additional research is still needed before these techniques can be applied in daily practice.

The long-term success rates achieved in the dental implantology suggest that flexibility might well exist within the system to a degree that an altered protocol can be considered under controlled conditions if carefully carried out by experienced clinicians. The use of reduced healing time of implants in an augmented maxilla has never been investigated yet. It has even been posed in the literature to avoid immediate loading of implants in such cases (Horiuchi et al. 2000). When considering the rather long treatment time in this group of patients when applying a conventional protocol, particularly in these patients reduction of treatment time is a goal to achieve. Therefore, the aim of this study was to evaluate the clinical and radiographic outcomes as well as patient satisfaction after early loading of dental implants inserted in the maxilla after augmentation of the maxillary sinus floor with autogenous bone grafts.

Patients and methods

Patients

From the patients referred to the Department of Oral and Maxillofacial Surgery and Maxillofacial Prosthetics of the University Hospital Groningen in 2000, 10 consecutive patients were selected on the basis of the following inclusion criteria: severely resorbed maxilla (class V–VI, Cawood & Howell 1988) with reduced stability and retention of the upper denture, an edentulous period of at least 1 year, no history of radiotherapy in the head and neck region, and no history of reconstructive, pre-pro-

Table 1. Sex, age, mandibular dentition, number of implants placed and loss of implants in the 10 patients involved in this study

Patient	Sex	Age (years)	Mandibular dentition	Number of implants	Loss of implants
1	M	56	CD	6	
2	M	67	RPD	6	1
3	F	56	CD	6	
4	M	51	ISO	8	
5	F	56	RPD	6	
6	F	61	CD	6	
7	F	58	ISO	6	
8	F	49	RPD	8	2
9	M	52	ISO	8	
10	M	49	RPD	8	

ISO = implant-supported overdenture; CD = complete denture; RPD = removable partial denture.

thetic surgery or previous oral implantology. Eligible patients were informed about the early loading protocol and written informed consent was obtained from all participants. Surgery and prosthodontics were performed within the same clinic. All patients (five women, five men; mean age 55.5 years, range 49–67 years at the time of surgery) agreed to participate in the study (Table 1). The patients had been edentulous in the maxilla for 1–16 years. In the mandible the edentulous patients wore implant-supported overdentures ($n = 3$) or conventional dentures ($n = 3$). Four patients were partially dentulous in the mandible.

Planning of treatment

Orthopantomograms, lateral cephalograms, and postero-anterior oblique radiographs were made to assess the height of the maxillary alveolar bone, the dimensions of the maxillary sinus, and the antero-posterior relationship of the maxilla to the mandible. The radiographs were also screened for sinus pathology. For every sinus to be included in this study, the alveolar height was measured on the orthopantomogram. The mean vertical height of the alveolar bone between the most caudal part of the maxillary sinus and the oral cavity was 3 ± 1 mm, range 1–4 mm.

In all cases, a diagnostic setup of the planned overdenture was made to get more insight in the position and number of desired implants and converted to a surgical template. Factors considered in the diagnostic setup included aesthetics (support for lips and cheeks), position of the posterior teeth, intermaxillary relationship, para-

functions (for example, bruxism) and the space available for the superstructure. A minimum of six implants with a length of at least 10 mm was aimed for. The implants were preferably equally distributed across both sides of the maxilla and connected with a superstructure. Prosthodontic considerations for the additional insertion of implants in the anterior region included the need to position the implants as near as possible to the planned maxillary dental arch, sufficient intermaxillary space for the mesostructure and the overstructure, especially considering the distance to the occlusal plane, and the width of the prosthesis in the anterior region. In case the interarch distance was insufficient for prosthetic construction with an optimal aesthetic and phonetic result, two superstructures were planned supported by three implants, inserted in the region between the canine and first molar ($n = 6$) (Fig. 1).

Surgery

In all cases, the maxilla of the patients was reconstructed with superior anterior medial iliac crest bone grafts under general anaesthesia. In all cases, a two-stage procedure (first stage, bone grafting; second stage, placement of implants) had to be performed because the height of the maxillary bone and/or the width of the alveolar crest were less than 5 mm. After augmentation of the maxillary sinus floor, the height of the maxillary bone was at least 13 mm. Subsequently, the width was increased by placing monocortico-cancellous bone blocks buccally of the cortex of the alveolar defect, with the cancellous side of the bone graft in contact with the jawbone. The graft was fixed with titanium screws (Martin

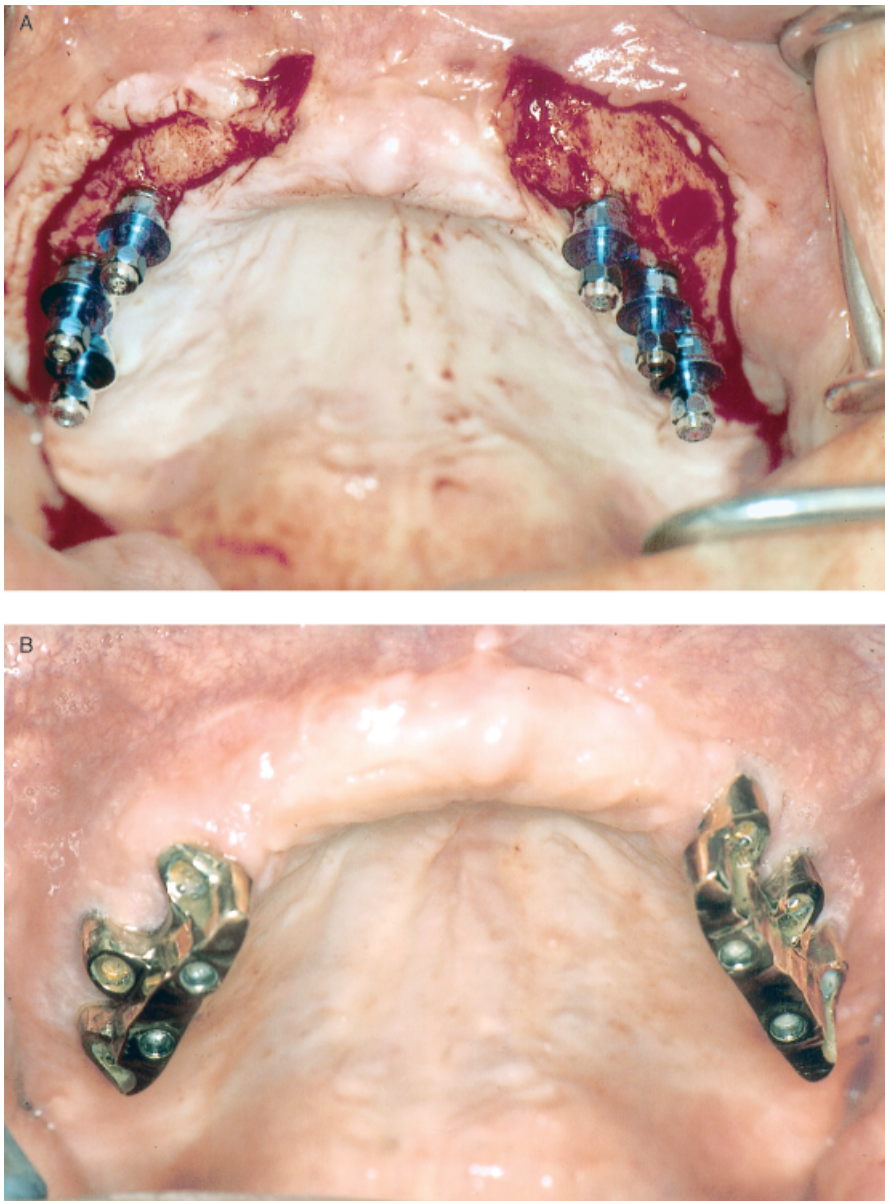


Fig. 1. (A) Clinical view of the augmented maxilla after insertion of six implants. (B) Clinical appearance of the bilateral prosthetic bars on the implants for overdenture support.

Medizin Technik, Tuttlingen, Germany) to the alveolar bone. Condensed cancellous bone particles were used to fill the small gaps between the bone graft and the alveolar crest. In all cases the width of the maxillary bone was at least 7 mm. After a healing period of 3 months, Osseotite® implants (3i Implant Innovations Inc., Palm Beach Gardens, FL, USA) were inserted using a surgical template for the position and direction of the implants (Fig. 1A). In all cases the bone volume was sufficient at the time of implantation, except in one patient (one implant) where the bone width was not enough. In the latter case, the implant could be inserted with sufficient primary

stability, but some threads of the implant were exposed. These threads were covered with bone and a Bio-Gide® membrane (Geistlich Pharma AG, Wolhusen, Switzerland). The oral mucosa was thinned where applicable and the healing abutments placed.

Prostodontics

Two months after insertion of the implants, the prosthetic construction was fabricated. This phase begins with abutment connection with a torque to 32 N cm. The patients were rehabilitated with a milled bar superstructure and an overdenture with a Ceka

revax precision attachment system (Ceka, Antwerp, Belgium).

Data collection

All patients and prosthetic constructions were evaluated according to a standardised protocol immediately and 1 year after fabrication of the overdenture. The protocol included assessment of both clinical (bleeding score, pocket depth, implant mobility) and radiographic (panoramic and standardised long cone radiographs) (Fig. 2) parameters. Complications during surgery and postoperative healing (inflammation, wound dehiscence, sequestration and loss of bone particles) and loss of implants were obtained from the patients' records. During the 1-year visit, the bars were removed and all implants were individually checked if they were mobile. The clinical examination included assessment of peri-implant soft tissue, bleeding index (Mombelli et al. 1987), gingival index (Löe & Silness 1963) and the probing depth (Merritt-B, Hu-Friedy, Chicago, IL, USA). Also plaque index (Mombelli et al. 1987) and presence of calculus were registered.

Possible marginal peri-implant bone loss was recorded by taking long-cone intraoral radiographs immediately after placement of the overdenture and at the 1-year follow-up visit. The distance from the implant/connector interface to the first bone-to-implant contact was measured with a digital calliper. The measurements were made at the two approximal implant sites. The site showing the most bone loss was used for data analysis. Analysis of the radiographs was performed by two observers.

Implant failure was defined according to the following criteria: implant mobility; persistent pain, infection, presence of peri-implant radiolucency; significant, ongoing cervical or apical implant-related bone loss; or the implant could not be used for prosthetic rehabilitation. Patient satisfaction was assessed by using a validated questionnaire (Vervoorn et al. 1988). The questionnaire focused on satisfaction with function of the prosthetic construction and with aesthetics. Eight items were presented with a five-point rating scale on which the patient indicated to what extent he or she was (dis)satisfied (1 = very satisfied, 2 = satisfied, 3 = neither satisfied nor dissatisfied, 4 = dissatisfied, 5 = very dissatisfied).

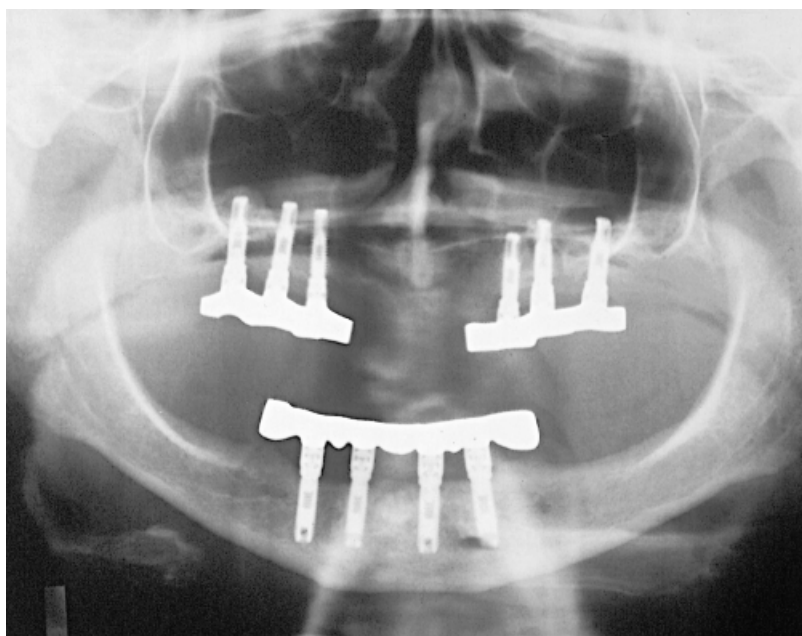


Fig. 2. Panoramic radiograph 1 year after placement of prosthesis.

The patient's overall treatment satisfaction was expressed on a 10-point rating scale (1 = very bad to 10 = excellent).

Results

Surgical complications

Although the sinus membrane was perforated during surgery in two cases (10%), healing was uneventful and loss of bone particles through the nose was not observed. Symptoms of transient sinusitis were observed in one patient, which resolved with decongestants and antibiotics used for a period of 2 weeks. The wound healing was uneventful. No major complications were observed at the donor sites.

Implants

A total of 68 Osseotite[®] implants were placed in the augmented maxillae (Table 1). The lengths of the implants were: 11.5 mm, $n = 3$; 13 mm, $n = 31$; 15 mm, $n = 34$. Thus, at least two-thirds of each implant was surrounded by grafted bone. After 2 months, two implants were mobile and had to be removed. One of these two implants was the implant covered with a membrane. One implant could be rotated after 2 months on abutment tightening. The patient did not experience any discomfort or pain. As the implant did not show lateral mobility, the implant was

Table 2. Mean values and standard deviations (SD) of plaque index, gingival index, bleeding index, calculus index and probing depth

Plaque index (score 0–3)	0.6±0.8
Gingival index (score 0–3)	0.5±0.7
Bleeding index (score 0–3)	0.7±0.9
Calculus index (score 0–1)	0.2±0.3
Probing depth (mm)	3.4±1.3
Marginal bone loss (mm)	0.3±0.7

included in the prosthetic construction. At the 1-year follow-up, the implant was mobile and had to be removed. There was no need to replace the lost implants as proper prosthodontic rehabilitation could be undertaken without replacement.

The parameters for evaluating peri-implant tissue health showed favourable results (Table 2). Radiological evaluation after 1 year indicated a mean marginal bone loss around 65 implants of 0.3±0.7 mm. The mobile implant showed peri-implant radiolucency. No other implant-related adverse events were reported.

The mean score on the questionnaire concerning denture satisfaction was 1.85±0.9. The mean satisfaction score with regard to the total treatment was 7.9±0.9.

Discussion

The aim of this study was to evaluate the placement and restoration of endosseous

implants that were inserted in an augmented maxilla and loaded after 2 months of healing. The short-term results demonstrate a success rate of 95.6% during the first year of loading. This is comparable to the success rates reported when applying a conventional protocol (Esposito et al. 1998a; Raghoobar et al. 2001). The conventional protocol data can be considered to be a historical control.

Lazarra et al. (1998), Cochran et al. (2002) and Testori et al. (2002) reported a 98–100% short-term success rate for implants in the maxilla with the early loading protocol. However, the patients were partially dentulous and no augmentation techniques were necessary. Although the results of implant survival rates between the partial dentulous and edentulous maxilla have not been analysed separately, there are some indications from the literature that the survival rate is higher in the case of partially dentulous patients (Mazor et al. 1999). Retrospectively, we observed long-term implant survival rates between 90.8% for the edentulous and 97.0% for the partially dentulous maxilla (Raghoobar et al. 2001). A possible explanation is that partially edentulous patients have less resorbed jaws (speaking in favour of sufficient bone volume and bone quality). In addition, in contrast to partially dentulous patients, edentulous patients were allowed to wear their upper dentures (relieved in the operated areas) during the healing phase. Moreover, in partially dentulous patients, occlusal forces on the prosthetic construction are merely transferred to the natural dentition. Since the overload is directly proportional to the bone–implant contact, early loss of the implants can occur when wearing prostheses during the healing phase. In the edentulous patients, there is thus an increased risk of implant failure due to biomechanical imbalance and poor bone quality. Most likely, late failures have a multifactorial background, such as overload and bacterial infection (Esposito et al. 1998b).

Overall, the patients were satisfied with their prosthetic construction. The patient's satisfaction in this study was comparable to that after a conventional treatment protocol for the augmented maxilla (Raghoobar et al. 2001).

It is difficult to determine the time at which an implant has sufficient stability in

bone to start with loading of the implants. Primary implant stability is a function of local bone quality and quantity, implant design, and the surgical technique used. Secondary implant stability is also determined by the bone tissue response to surgical trauma and the implant surface. It is highly desirable to have a quantitative method for establishing the primary stability of an implant at the time of implant placement especially if early or immediate loading of the implants is performed, even if it is still unknown what the minimal stability of an implant has to be before loading. Such information may be used to predict the optimum healing period and point at when an implant may be suitable for loading. During implant placement, primary stability is often defined by the surgeon as the lack of clinically detectable motion when using two opposing instruments in a lateral direction. In more recent studies this method has increasingly been replaced by instruments such as the Perioste[®] (Siemens, Bensheim, Germany) and resonance frequency analysis (Osstell[™], Integration Diagnostics Ltd, Sweden) to quantify the lateral movements of the implant under controlled force (Meredith 1998). After the healing period, however, these instruments do not evaluate resistance to rotation of the implant, which is an indication of the strength of the implant-to-bone contact. Cochran et al. (2002) used a controlled rotational force of 35 Ncm and two subjective evaluation criteria, which were clinically detectable rotation of the implant and patient discomfort. Their data suggest that either implant rotation or patient discomfort on rotation may be an indication of premature osseous integration of the implant, rather than an indicator of implant failure as in the case of lateral mobility of an implant. Their method, however, cannot be used immediately after insertion of the implant.

From this study it is concluded that early loading of endosseous implants inserted in an augmented maxilla is possible. It has been shown to result in a reduced overall treatment time, a high 1-year implant survival rate and good overall denture satisfaction of patients. These data are comparable to those obtained by conven-

tional protocols. Further investigation and long-term evaluation are certainly needed to confirm the encouraging results of this clinical study and to fully evaluate the clinical impact of early implant loading as predictable osseointegration is the goal to achieve in dental implantology. Before early or immediate loading protocols can be performed in daily practice, controlled clinical studies that validate performance over a 5-year period in different bone quality and restorative situations have to be performed. Evidence-based treatment demands scientific documentation before utilisation.

Résumé

Chez dix patients, 68 implants ont été insérés dans des maxillaires édentés et épaissis en utilisant la technique du placement implantaire en une étape. Trois mois avant l'insertion implantaire la largeur et la hauteur du bord alvéolaire ont été épaissies par des greffes osseuses autogènes provenant de la crête iliaque. Dans tous les cas, le volume osseux résultant de cette chirurgie était suffisant pour le placement des implants. Suivant un protocole de mise en charge précoce, la prothèse ancrée sur les implants a été fabriquée deux mois après l'insertion de ces derniers. L'évaluation a été effectuée suivant un protocole standardisé immédiatement et une année après la construction des prothèses. Cette évaluation incluait des critères cliniques (indice de saignement, profondeur des poches, mobilité implantaire) et radiographiques (niveau osseux marginal sur radiographies standardisées). Trois implants maxillaires chez deux patients ont été perdus (taux de survie : 95,6%). Les tissus paroiimplantaires avaient une apparence saine et la perte osseuse était minime. Les patients étaient satisfaits de la construction prothétique. De cette étude préliminaire, il ressort que dans des cas sélectionnés le placement précoce d'implants peut être un traitement prévisible après l'épaississement du maxillaire.

Zusammenfassung

Bei 10 Patienten wurden 68 enossale Implantate in die augmentierte Maxilla transmukosal eingesetzt. Drei Monate vor der Implantatplatzierung wurde die Breite und die Höhe des Alveolarkammes mit autologen Knochentransplantaten vom Beckenkamm augmentiert. Das resultierende Knochenvolumen war in allen Fällen ausreichend für die Eingliederung von Implantaten. Gemäss eines Protokolls zur Frühbelastung wurden die implantatgetragenen Hybridprothesen zwei Monate nach der Implantatplatzierung angefertigt. Die Evaluation wurde gemäss Standardprotokoll sofort und ein Jahr nach der Anfertigung der prothetischen Rekonstruk-

tion durchgeführt. Das Protokoll beinhaltete sowohl klinische (Blutungs Index, Taschentiefe, Implantatmobilität) als auch radiologische (marginale Knocheniveau auf standardisierten Röntgenbildern) Parameter. Drei Implantate im Oberkiefer von 2 Patienten gingen verloren (Ueberlebensrate: 95,6%). Die peri-implantären Gewebe sahen gesund aus und der Knochenverlust war minimal. Die Patienten waren generell sehr zufrieden mit der prothetischen Rekonstruktion. Aus dieser ersten Studie wird die Schlussfolgerung gezogen, dass in ausgewählten Fällen die frühe Belastung von Implantaten nach Augmentation der Maxilla zu einer voraussagbaren Behandlungsmodalität entwickelt werden kann.

Resumen

Se insertaron 68 implantes endoóseos en 10 pacientes en el maxilar edéntulo aumentado usando una técnica de implante de una sola fase. 3 meses antes de la inserción de los implantes se aumentaron la anchura y la altura de la cresta alveolar con injertos de hueso autólogo de la cresta ilíaca. En todos los casos el volumen de hueso resultante fue suficiente para la inserción de los implantes. De acuerdo con el protocolo de carga temprana, se fabricó la sobredentadura implantosoportada 2 meses tras la inserción de los implantes. Se llevó a cabo una evaluación de acuerdo con un protocolo estándar inmediatamente y tras 1 año tras la fabricación de la reconstrucción protésica. El protocolo incluyó valoración de tanto parámetros clínicos (valores de sangrado, profundidad de bolsas, movilidad de implantes) como radiográficos (nivel de hueso marginal en radiografías estándar). Se perdieron 3 implantes en 2 pacientes en el maxilar superior (índice de supervivencia: 95,6%) Los tejidos periimplantarios tuvieron una apariencia sana y la pérdida ósea fue mínima. En conjunto, los pacientes estuvieron muy satisfechos con la reconstrucción protésica. Se concluye de este estudio preliminar que en casos seleccionados, la carga temprana de los implantes puede desembocar en una modalidad predecible de tratamiento tras el aumento del maxilar.

要旨

患者 10 名の骨増生した無菌顎上顎に、1 回法のテクニックを用いて、6 8 本の骨内インプラントを埋入した。インプラント埋入 3 ヶ月前に歯槽頂の幅径と高径を、腸骨稜から採取した自家骨移植によって増生した。全ての症例においてインプラントの埋入に十分な骨量が得られた。早期荷重プロトコールに沿って、インプラント支持によるオーバーデンチャーを、インプラント埋入後 2 ヶ月後に製作した。標準プロトコールに則って、補綴物製作の直後と 1 年後に評価を行った。同プロトコールには、臨床的パラメータ (出血スコア、ポケット深さ、インプラント動揺性) と放射線像上のパラメータ (標準放射線像上の辺縁骨レベル) が含まれていた。患者 2 名において、上顎のインプラント 3 本が失われた (生存率 : 95.6%)。インプラント周囲の組織は健全で、骨喪失は最低限であった。全体として患者は補綴物に大変満足していた。この予備的研究から、選択した症例においてインプラントの早期荷重は、上顎骨増生後の予知性が高い治療様式となりうるかと結論される。

References

- Adell, R., Lekholm, U., Rockler, B. & Brånemark, P.I. (1981) A 15-year study of osseointegrated implants in the treatment of edentulous jaw. *International Journal of Oral Surgery* **10**: 387–416.
- Andersen, E., Haanaes, H.R. & Knutsen, B.M. (2002) Immediate loading of single-tooth ITI implants in the anterior maxilla: a prospective 5-year pilot study. *Clinical Oral Implants Research* **13**: 281–287.
- Balshi, T.J. & Wolfinger, G.J. (1997) Immediate loading of Brånemark implants in edentulous mandibles: a preliminary report. *Implant Dentistry* **6**: 83–88.
- Batenburg, R.H.K., Meijer, H.J.A., Raghoobar, G.M., Van Oort, R.P. & Boering, G. (1998) Mandibular overdenture supported by two Brånemark, IMZ or ITI implants. A prospective comparative study: one-year results. *Clinical Oral Implants Research* **9**: 374–383.
- Cawood, J.I. & Howell, R.A. (1988) A classification of the edentulous jaws. *International Journal of Oral and Maxillofacial Surgery* **17**: 232–236.
- Chiapasco, M., Gatti, C., Rossi, E., Haefliger, W. & Markwalder, T.H. (1997) Implant-retained mandibular overdentures with immediate loading. A retrospective multicenter study on 226 consecutive cases. *Clinical Oral Implants Research* **8**: 48–57.
- Cochran, D.L., Buser, D., ten Bruggenkate, C.M., Weingart, D., Taylor, T.M., Bernard, J.P., Peters, F. & Simpson, J.P. (2002) The use of reduced healing times on ITI[®] implants with a sandblasted and acid-etched (SLA) surface: early results from clinical trials on ITI[®] SLA implants. *Clinical Oral Implants Research* **13**: 144–153.
- Engquist, B., Bergendal, T., Kallus, T. & Linden, U. (1988) A retrospective multicenter evaluation of osseointegrated implants supporting overdentures. *International Journal of Oral Maxillofacial Implants* **3**: 129–134.
- Ericsson, I., Nilson, H., Lindh, T., Nilner, K. & Randow, K. (2000) Immediate functional loading of Brånemark single tooth implants. An 18 months' clinical pilot study. *Clinical Oral Implants Research* **11**: 26–33.
- Esposito, M., Hirsch, J.M., Lekholm, U. & Thomsen, P. (1998a) Biological factors contributing to failures of osseointegrated oral implants. (I) Success criteria and epidemiology. *European Journal of Oral Sciences* **106**: 527–551.
- Esposito, M., Hirsch, J.M., Lekholm, U. & Thomsen, P. (1998b) Biological factors contributing to failures of osseointegrated oral implants. (II) Etiopathogenesis. *European Journal of Oral Sciences* **106**: 721–764.
- Henry, P.J. & Rosenberg, I. (1994) Single-stage surgery for rehabilitation of the edentulous mandible: preliminary results. *Practical and Periodontics Aesthetic Dentistry* **6**: 15–22.
- Horiuchi, K., Uchida, H., Yamamoto, K. & Sugimura, M. (2000) Immediate loading of Brånemark system implants following placement in edentulous patients: a clinical report. *International Journal of Oral and Maxillofacial Implants* **15**: 824–830.
- Jemt, T., Harnett, J., Heath, M.R., Hutton, J.E., Johns, R.B., McKenna, S., McNamara, D.C., Van Steenberghe, D., Taylor, R., Watson, R.M. & Herrmann, I. (1996) A 5-year prospective multicenter follow-up report on overdentures supported by oral implants. *International Journal of Oral and Maxillofacial Implants* **11**: 291–298.
- Lazzara, R.J., Porter, S.S., Testori, T., Galante, J. & Zetterqvist, L. (1998) A prospective multicenter study evaluating loading of osseointegrated implants two months after placement: one-year results. *Journal of Esthetic Dentistry* **10**: 280–289.
- Ledermann, P.D. (1979) Stegprothetische Versorgung des zahnlosen Unterkiefers mit Hilfe plasmabeschichteten Titananschraubimplantaten. *Deutsche Zahnärztliche Zeitung* **34**: 907–911.
- Ledermann, P.D. (1984) Das TPS-Schraubimplantat nach siebenjähriger Anwendung. *Quintessenz* **30**: 1–11.
- Löe, H. & Silness, J. (1963) Periodontal disease in pregnancy. I. Prevalence and severity. *Acta Odontologica Scandinavica* **21**: 533–551.
- Mazor, Z., Peleg, M. & Gross, M. (1999) Sinus augmentation for single-tooth replacement in the posterior maxilla: a 3-year follow-up clinical report. *International Journal of Oral and Maxillofacial Implants* **14**: 55–60.
- Meredith, N. (1998) Assessment of implant stability as a prognostic determinant. *International Journal of Prosthodontics* **11**: 491–501.
- Mombelli, A., van Oosten, M.A.C., Schürch, E. & Lang, N.P. (1987) The microbiota associated with successful or failing osseointegrated titanium implants. *Oral Microbiology and Immunology* **2**: 145–151.
- Raghoobar, G.M., Timmenga, N.M., Reintsema, H., Stegenga, B. & Vissink, A. (2001) Maxillary bone grafting for the insertion of endosseous implants: results after 12–124 months. *Clinical Oral Implants Research* **12**: 279–286.
- Randow, K., Ericsson, I., Nilner, K., Petersson, A. & Glantz, P.O. (1999) Immediate functional loading of Brånemark dental implants. An 18-month clinical follow-up study. *Clinical Oral Implants Research* **10**: 8–15.
- Roccuzzo, M., Bunino, M., Prioglio, F. & Bianchi, S.D. (2001) Early loading of sandblasted and acid-etched (SLA) implants: a prospective split-mouth comparative study. One-year results. *Clinical Oral Implants Research* **12**: 572–578.
- Røynesdal, A., Amundrud, B. & Hannaes, H.R. (2001) A comparative clinical investigation of 2 early loaded ITI dental implants supporting an overdenture in the mandible. *International Journal of Maxillofacial Implants* **2001**: 246–251.
- Salama, H., Rose, L.F., Salama, M. & Betts, N.J. (1995) Immediate loading of bilaterally splinted titanium root form implants in fixed prosthodontics: a technique re-examined. Two case reports. *International Journal of Periodontology and Restorative Dentistry* **15**: 345–361.
- Schnitman, P.A., Wöhrle, P.S. & Rubenstein, J.E. (1990) Immediate fixed interim prostheses supported by two-stage threaded implants: methodology and results. *Journal of Oral Implantology* **2**: 96–105.
- Schnitman, P.A., Wöhrle, P.S., Rubenstein, J.E., DaSilva, J.D. & Wang, N.-H. (1997) Ten years results for Brånemark implants immediately loaded with fixed prostheses at implant placement. *International Journal of Maxillofacial Implants* **12**: 495–503.
- Spiekerman, H., Jansen, V.K. & Richter, E.-J. (1995) A 10-year follow-up study of IMZ and TPS implants in the edentulous mandible using bar-retained overdentures. *International Journal of Oral and Maxillofacial Implants* **10**: 231–243.
- Tarnow, D.P., Emtiaz, S. & Classi, A. (1997) Immediate loading of threaded implants at stage 1 surgery in edentulous arches: ten consecutive case reports with 1- to 5-year data. *International Journal of Oral and Maxillofacial Implants* **12**: 319–324.
- Testori, T., Del Fabro, M., Feldman, S., Vincenzi, G., Sullivan, D., Rossi, R., Anitua, E., Bianchi, F., Francetti, L. & Weinstein, R.L. (2002) A multicenter prospective evaluation of 2-months loaded Osseotite[®] implants placed in the posterior jaws: 3-year follow-up results. *Clinical Oral Implants Research* **13**: 154–161.
- Vervoom, J.M., Duinkerke, A.S.H., Luteijn, F. & van de Poel, A.C.M. (1988) Assessment of denture satisfaction. *Community Dentistry and Oral Epidemiology* **16**: 364–367.