

University of Groningen

A Technique for Standardized Evaluation of Soft and Hard Peri-Implant Tissues in Partially Edentulous Patients

Meijndert, Leo; Meijer, Hendrikus; Raghoobar, Gerry; Vissink, Arjan

Published in:
 JOURNAL OF PERIODONTOLOGY

IMPORTANT NOTE: You are advised to consult the publisher's version (publisher's PDF) if you wish to cite from it. Please check the document version below.

Document Version
 Publisher's PDF, also known as Version of record

Publication date:
 2004

[Link to publication in University of Groningen/UMCG research database](#)

Citation for published version (APA):

Meijndert, L., Meijer, H. J. A., Raghoobar, G. M., & Vissink, A. (2004). A Technique for Standardized Evaluation of Soft and Hard Peri-Implant Tissues in Partially Edentulous Patients. *JOURNAL OF PERIODONTOLOGY*, 75(5), 646-651.

Copyright

Other than for strictly personal use, it is not permitted to download or to forward/distribute the text or part of it without the consent of the author(s) and/or copyright holder(s), unless the work is under an open content license (like Creative Commons).

Take-down policy

If you believe that this document breaches copyright please contact us providing details, and we will remove access to the work immediately and investigate your claim.

Downloaded from the University of Groningen/UMCG research database (Pure): <http://www.rug.nl/research/portal>. For technical reasons the number of authors shown on this cover page is limited to 10 maximum.

A Technique for Standardized Evaluation of Soft and Hard Peri-Implant Tissues in Partially Edentulous Patients

Leo Meijndert,*† Henny J.A. Meijer,*‡ Gerry M. Raghoobar,* and Arjan Vissink*

Background: There is a growing need to evaluate the esthetics of implant-supported crowns and bridges. An important tool for such an evaluation is standardized assessment of the soft and hard peri-implant tissue levels.

Methods: A simple acrylic device has been developed for reliable and reproducible assessment of soft and hard peri-implant tissues using standardized color slides and standardized dental x-rays. With this device, changes in both the soft and hard tissues around implant-supported crowns can be evaluated as a function of time. The reproducibility of the technique was tested on color slides as well as on dental x-rays in a series of implant-supported crowns and their neighboring teeth.

Results: The reproducibility of this technique was excellent. The measuring errors for repeated measurements of the soft and hard tissues were 0.14 ± 0.02 mm and 0.13 ± 0.01 mm, respectively.

Conclusions: The device is a reliable tool to assess changes in both soft and hard tissues around crowns and implants over time. Likewise, it is suggested that this technique also can be used to objectively assess soft and hard tissue changes around natural teeth with or without prosthetic restorations. *J Periodontol* 2004;75:646-651.

KEY WORDS

Alveolar bone loss; dental esthetics; dental implants; diagnostic equipment; diagnostic imaging; gingival recession/diagnosis; radiography, dental.

* Department of Oral and Maxillofacial Surgery and Maxillofacial Prosthodontics, Groningen University Hospital, Groningen, The Netherlands.

† Department of Oral and Maxillofacial Surgery, Nij Smellinghe Christian Hospital, Drachten, The Netherlands.

‡ Department of Oral Function and Prosthetic Dentistry, Faculty of Medical Sciences, University of Groningen, Groningen, The Netherlands.

Since it is possible to insert dental implants with high levels of survival, the focus of attention is moving towards esthetic results. The condition of the soft and hard tissues around dental implants plays a major role in assessing esthetics. To objectively evaluate changes in soft and hard tissue conditions, the marginal gingiva level (MGL) and the marginal bone level (MBL) might play an important role. Comparison of these parameters within a study or between various studies gains reliability when standardized methods of measurement are used. Unfortunately, no reliable tool to assess the soft tissue parameters is available; neither is a tool for objective comparison of changes in the hard and soft tissue parameters that might occur over time. Among other problems to be solved is that of minimizing the distortion and the magnification factor between images, as this makes comparison between two or more images of the surrounding tissues of the same implant less reliable. These latter conditions have a significant impact on the MGL and MBL results for the marginal bone height around dental implants.¹

MGL is usually assessed by clinical measurements of the actual site,² but also could be assessed by taking a photograph (color slide) on which similar and additional measurements can be performed. When using photography for the purpose of assessing time-related changes in MGL, it is important to take the color slides in a standardized way. The angulation of the film to the object might vary between the various moments of taking

a photograph, as might the magnification due to a change in film-object distance. Intraoral dental radiographs are usually taken to assess MBL around dental implants. This has been proven to be a reliable assessment when the radiographs are taken in a standardized way. However, there is no technique available allowing for objective comparison of MGL and MBL as a function of time. Therefore, the aim of this study was to develop a simple and effective method for the reproducible assessment of both the MGL and MBL as a function of time as well as to assess its reproducibility. The basis of the developed method is a custom made acrylic "imaging guide," which minimizes variation in angulation of object to film in color slide photography and dental radiography and which eliminates variations in object to film distance.

MATERIALS AND METHODS

Construction of the Imaging Guide

A cast model of the dentition is used to construct a custom made acrylic splint to the occlusal surface. At the site where the implant is to be located a small gap is left in the splint. For greater stability, the device is extended from the occlusal surface to just over the buccal cusps (2 mm) and to the palatal side of the teeth (5 mm). The incisal edges of the implant-supported crown and its neighboring teeth are not enclosed so as to provide a stable reference point for the assessment of the MGL on the color slides. With one or two interdental retaining eyelets on each side, the acrylic plate is secured to the dentition (Fig. 1). To the left or right side of the implant a short metal bar (± 2 cm) is fixed to the acrylic splint, perpendicular to the long axis of the implant and pointing to the labial side. This bar

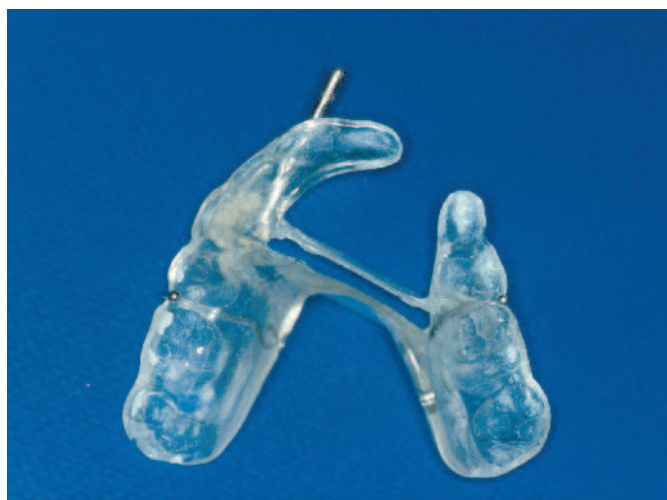

Figure 1.

Bottom-up view of the imaging guide for the upper jaw (future implant-supported crown on tooth #22).

acts as a direction indicator for the long axis of the camera lens and as a direction indicator for the x-ray beam.

A prefabricated, acrylic small film holder (to fit film size 1) is connected on the palatal side to the splint (Fig. 2). In order to use the long-cone parallel imaging technique, the film holder is positioned to the acrylic splint in such a way that the x-ray film is as parallel to the implant location as possible (Fig. 2).

Imaging Technique

After positioning the acrylic imaging guide in the mouth, a removable extension bar is attached to the metal bar (direction indicator) in the acrylic plate to facilitate paralleling the long axis of the camera lens and the x-ray tube to this direction indicator. To position the implant-supported crown with its surrounding

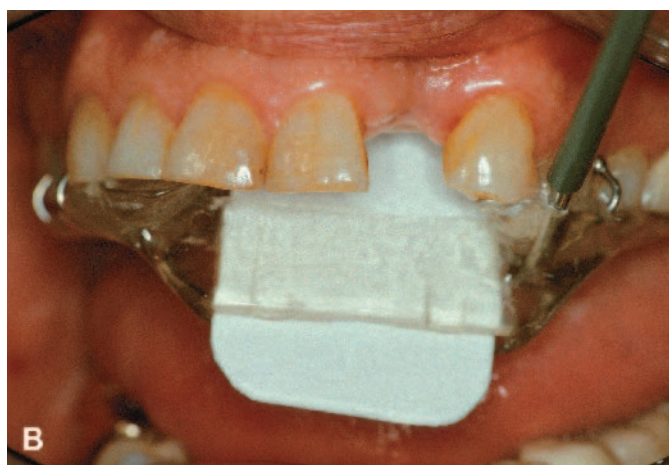
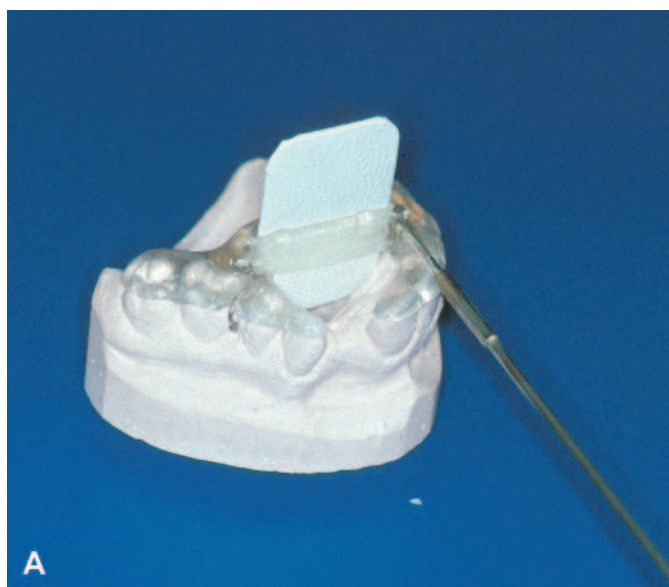
Figure 2.

Intraoral dental x-ray film parallel to the long-axis of the scheduled implant position and of the surrounding teeth in the laboratory (A) and in a clinical situation (B).

tissues in the center of the image, it might be necessary to bend the removable extension bar to provide enough space for the camera lens or x-ray tube (Fig. 3).

To facilitate pointing the long axis of the camera lens parallel to the extension bar on the acrylic imaging guide in the patient's mouth, another straight bar is fixed to the camera itself, parallel to the long axis of the lens (Fig. 3). A custom made snap-on ring for the camera lens provides an anchor for the camera's extension bar (Fig. 4). A standard magnification is used (1:1), making sure that all the relevant hard and soft tissues are captured in the photographic image (Fig. 5).

Using the long cone on the x-ray machine, the cone is paralleled to a straight extension bar while the tip

of the cone is moved forward until it almost touches the patient (Fig. 6). The marginal peri-implant bone level is in the center of the x-ray beam. The dental radiograph is then taken with a standard kV/mA and exposure time (Fig. 7).

Assessment of the Method's Reliability

The reproducibility of the technique and the imaging device was tested for measurements on the color slides in a group of five patients. A series of five color slide pictures of a portion of each patient's dentition was taken at various times, using a camera with a ring flash. The imaging device is removed and replaced between the shots.

The reproducibility of intraoral radiographs was




Figure 3.
The extension bar on the acrylic plate is clearly seen, as is the bar on the camera lens.



Figure 4.
The custom made snap-on ring for the extension bar on the camera lens. The ring is placed over the lens.

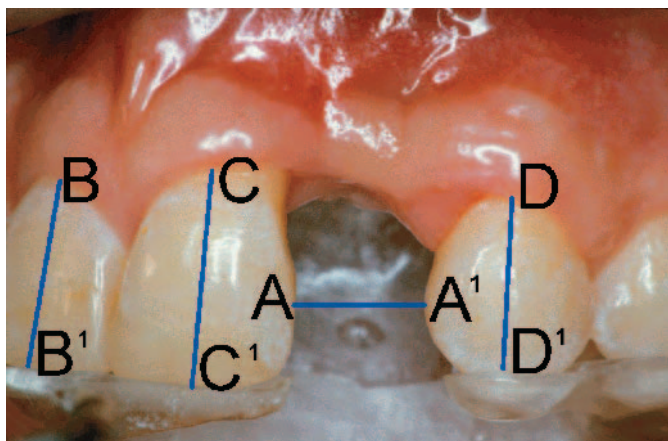


Figure 5.
All relevant hard and soft tissues are captured in the photographic image. The horizontal measuring point (A-A') and the three vertical measuring points (B-B', C-C', D-D') are shown.

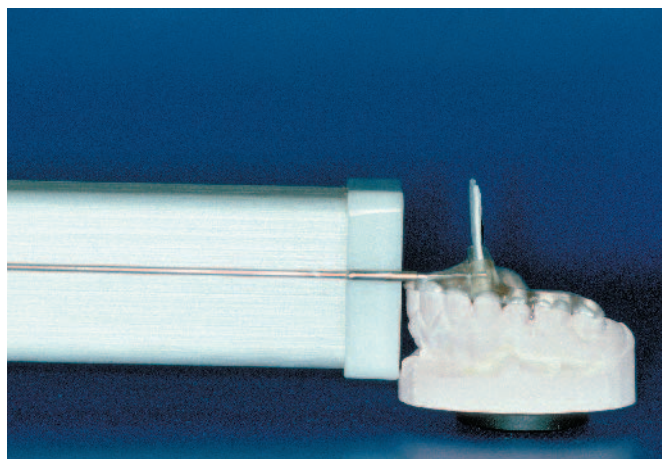


Figure 6.
The x-ray tube perpendicular to the intraoral dental film and parallel to the extension bar of the imaging guide.

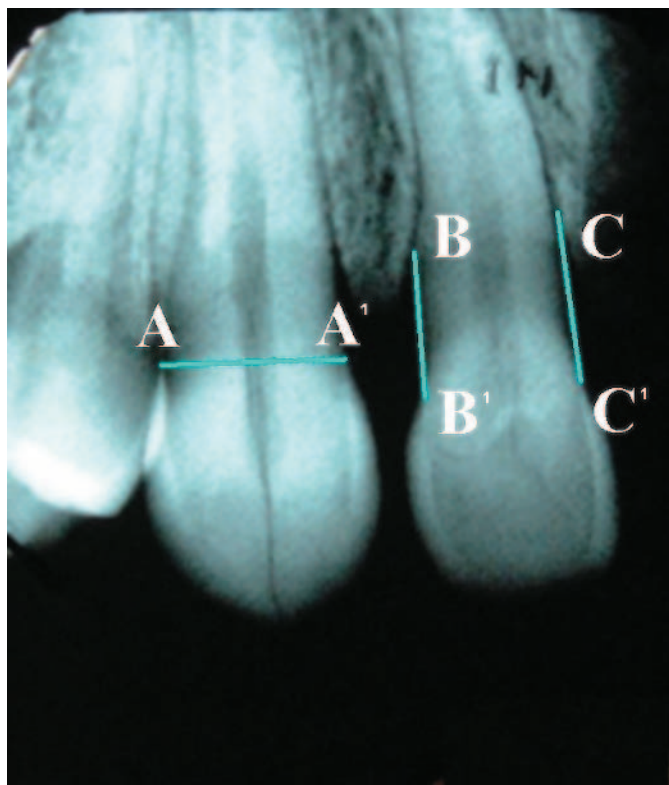


Figure 7. Intraoral x-ray taken with the imaging device. The horizontal (A-A') and both vertical measuring points (B-B', C-C') are shown.

of the slide). One measuring point was used to assess the horizontal reproducibility (width of the crown of the incisor in the center or the width of the diastema in the center of the image). In the dental radiographs two measuring points were used to assess the vertical reproducibility (mesial and distal MBL of the incisor in the center of the dental radiograph; MBL was measured from the proximal cemento-enamel junction to the bone). One measuring point was used to assess the horizontal reproducibility (width of the incisor/cuspid in the center of the radiograph at the level of the cemento-enamel junction).

RESULTS

The measuring error of each series of five measurements is shown in Table 1. The measuring error for repeated measurements on color slides was 0.14 ± 0.02 mm. This was mainly caused by the intra-examiner inconsistency, which amounted to 0.11. Consequently, the measuring error is largely due to the intraexaminer inconsistency, making the repositioning error to an insignificant contributing error. The measuring error for repeated measurements on the dental intraoral x-rays was 0.13 ± 0.01 mm. Again, the intra-examiner inconsistency (0.10) is primarily responsible and the contribution of the repositioning error is negligible. It is noted that the measuring error for the color slides (0.14 ± 0.02 mm) is comparable to that for the intraoral dental x-rays (0.13 ± 0.01 mm).

Table 1. Measuring Errors (mm, mean \pm SD) as Calculated for Each Series of Slides and Dental Radiographs

	Patient					Overall
	1	2	3	4	5	
Color slides	0.14 ± 0.05	0.20 ± 0.10	0.14 ± 0.06	0.08 ± 0.05	0.12 ± 0.04	0.14 ± 0.02
Dental radiographs	0.13 ± 0.05	0.12 ± 0.04	0.14 ± 0.06	–	–	0.13 ± 0.01

assessed on three series of five dental radiographs on a portion of the dentition of a dried human skull. The imaging device was removed and replaced between radiographs. The trial for assessing the reproducibility of the dental radiographs was not performed in vivo because of medical ethical reasons. Using a digital measuring-gauge[§] (measurement uncertainty $U_{95} = 20 \mu\text{m}$), MGL and MBL were measured directly on the color slides and dental radiographs (Figs. 5 and 7). On each color slide three vertical measuring points were used to assess the vertical reproducibility (incisogingival distance on an incisor on the left side, an incisor in the center, and an incisor on the right side

DISCUSSION

Assessment of the marginal soft and hard tissue levels around dental implants and their prosthetic restorations is necessary to evaluate short- and long-term esthetic success of dental implants. Standardized color slide photography and dental radiography are good clinical tools for this purpose. The measurements within one patient were very consistent with a measuring error

of 0.14 ± 0.02 mm and 0.13 ± 0.01 mm, respectively.

If one focuses on the accuracy in repositioning of the imaging device, it is clear that the intraexaminer inconsistency largely contributes to the overall measuring error. This makes the intraexaminer inconsistency the determining factor for reliability of repeated measurements. The results of our study are in accordance with the results of the experimental study of Hermann et al.³ comparing linear radiographic with histometric measurements. They concluded that with standardized periapical radiography crestal bone levels around implants

[§] Cal IP65, Type 00530200, Tesa, Renens, Switzerland.

can be measured accurately (within 0.2 mm) in a high percentage (89%) of cases. Similarly, changes in MGL can be measured as accurately with the method proposed in this study.

The relatively large contribution of the intraexaminer inconsistency to the total measuring error could be related to the measuring method. However, Meijer et al.,⁴ in their study focusing on the best method to assess the MBL around endosseous implants, reported an intra-examiner inconsistency as high as 0.39 mm when using a digital measuring gauge. Regardless of this high inconsistency, the authors⁴ concluded that the use of a digital measuring gauge was the instrument of choice to assess the MBL, as it proved superior to a magnifying glass with measuring scale attached to the lens and no less accurate than a computerized image analysis system.^{4||} The digital measuring gauge has been used in many studies,⁵⁻⁷ so the even lower measuring error of the technique proposed is well within acceptable limits.

It has been reported that the mean annual bone loss around dental implants is 0.6 mm in the first year after insertion and about 0.1 mm/year thereafter.^{5,8-11} The measuring error of 0.13 ± 0.01 mm on repeatedly taken dental radiographs has to make one cautious in drawing definitive conclusions based on radiograph measurements with a short follow-up. However, changes in MBL less than 0.20 mm are not considered clinically relevant. The same is also true for MGL, although currently no data are available on the annual change of this parameter around dental implant restorations. Again, we consider changes in the MGL less than 0.22 mm not clinically relevant. The mean measuring error of the device used in this study is comparable for color slides and dental radiographs. Thus, a major advantage is that with the same device changes both in MGL and in MBL can be studied.

Previous reports mentioned the use of an imaging device to take reproducible dental radiographs.¹²⁻¹⁷ The various reports all can be applied to study radiographic changes at the implantation site as a function of time post-treatment, but do not allow for comparison of radiographic and clinical data as no application is available for such comparative studies. The main improvement of the method introduced in this study is that it makes such comparative studies possible. Furthermore, Meijer et al.¹⁵ regarded a repositioning error with a standard deviation of 0.02 mm due to the radiographic technique acceptable to judge the marginal bone loss as a function of time. The very small repositioning error of the method discussed in the current study is in accordance with this statement.

The fact that, by using this device, both the color slides and the dental radiographs are taken from the same horizontal and vertical angulation towards the

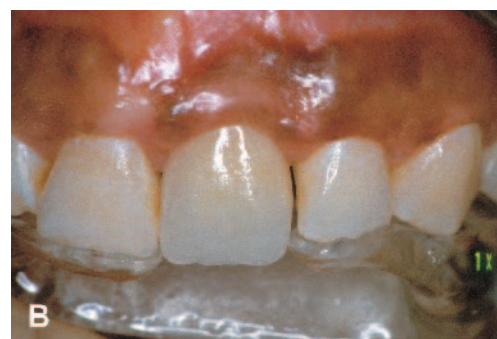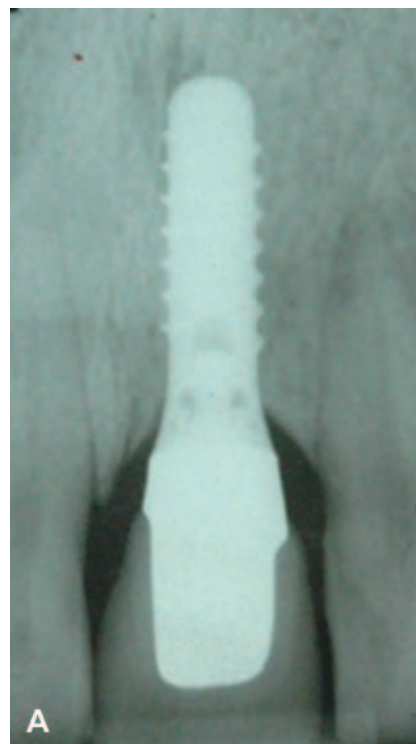


Figure 8. An intraoral dental radiograph (A) and a color slide (B) of the same area.

implant/tooth and surrounding hard and soft tissues will probably enable researchers to relate changes in MGL to changes in MBL (Fig. 8). Hypothetically, this is an important achievement in the understanding of changes in the soft tissue levels around dental implant restorations as well as around natural teeth. Extensive studies are needed to determine whether there is a relationship between changes in MGL and changes in MBL. Besides its use in oral implant studies, the imaging device can probably play a role in assessing the long-term effects of periodontal and prosthodontic treatment on soft and hard tissues around natural teeth as well. This might lead to the development of a generally applicable “esthetic index” for the hard and soft oral structures in the esthetic zone.

|| IBAS, Zeiss/Kontron, Eching, Germany.

ACKNOWLEDGMENT

The authors thank Mr. A. Wietsma, dental technician in the Department of Oral and Maxillofacial Surgery and Maxillofacial Prosthodontics, Groningen University Hospital, Groningen, The Netherlands, for his helpful ideas and cooperation in the development of the imaging device.

REFERENCES

1. Sewerin IP. Errors in radiographic assessment of marginal bone height around osseointegrated implants. *Scand J Dent Res* 1990;98:428-433.
2. Bengazi F, Wennström JL, Lekholm U. Recession of soft tissue margin at oral implants. A 2-year longitudinal prospective study. *Clin Oral Implants Res* 1996;7:303-310.
3. Hermann JS, Schoolfield JD, Nummikoski PV, Buser D, Schenk RK, Cochran DL. Crestal bone changes around titanium implants: A methodologic study comparing linear radiographic with histometric measurements. *Int J Oral Maxillofac Implants* 2001;16:475-485.
4. Meijer HJA, Steen WHA, Bosman F. A comparison of methods to assess marginal bone height around endosseous implants. *J Clin Periodontol* 1993;20:250-253.
5. Heydenrijk K, Raghoobar GM, Meijer HJ, Van Der Reijden WA, van Winkelhoff AJ, Stegenga B. Two-part implants inserted in a one-stage or a two-stage procedure. A prospective comparative study. *J Clin Periodontol* 2002;29:901-909.
6. Raghoobar GM, Schoen P, Meijer HJ, Stellingsma K, Vissink A. Early loading of endosseous implants in the augmented maxilla: A 1-year prospective study. *Clin Oral Implants Res* 2003;14:697-702.
7. Meijer HJ, Heijdenrijk K, Raghoobar GM. Mucosal and radiographic aspects during the healing period of implants placed in a one-stage procedure. *Int J Prosthodont* 2003;16:397-402.
8. Oates TW, West J, Jones J, Kaiser D, Cochran DL. Long-term changes in soft tissue height on the facial surface of dental implants. *Implant Dent* 2002;11:272-279.
9. Grunder U. Stability of the mucosal topography around single-tooth implants and adjacent teeth: 1-year results. *Int J Periodontics Restorative Dent* 2000;20:11-17.
10. Adell R, Lekholm B, Rockler B, Brånemark PI. A 15-year study of osseointegrated implants in the treatment of the edentulous jaw. *Int J Oral Surg* 1981;10:387-416.
11. Adell R, Lekholm B, Rockler B, et al. Marginal tissue reactions at osseointegrated titanium fixtures (I). A three year longitudinal prospective study. *Int J Oral Maxillofac Surg* 1986;15:39-52.
12. Jeffcoat MK, Reddy MS, Webber RL, Williams RC, Ruttimann UE. Extraoral control of geometry for digital subtraction radiography. *J Periodontal Res* 1987;22:396-402.
13. McHenry K, Hausmann E, Wikesjö U, Dunford R, Lyon-Bottenfield E, Christersson L. Methodological aspects and quantitative adjuncts to computerized subtraction radiography. *J Periodontal Res* 1987;22:125-132.
14. Hausmann E. A contemporary perspective on techniques for the clinical assessment of alveolar bone. *J Periodontol* 1990;61:149-156.
15. Meijer HJA, Steen WHA, Bosman F. Standardized radiographs of the alveolar crest around implants in the mandible. *J Prosthet Dent* 1992;68:318-321.
16. Hausmann E, Allen K, Loza J, Buchanan W, Cavanaugh PF. Validation of quantitative digital subtraction radiography using the electronically guided alignment device/impression technique. *J Periodontol* 1996;67:895-899.
17. Jeffcoat MK, Reddy MS, Magnusson I, et al. Efficacy of quantitative digital subtraction radiography using radiographs exposed in a multicenter trial. *J Periodontal Res* 1996;31:157-160.

Correspondence: Dr. L. Meijndert, Department of Oral and Maxillofacial Surgery and Maxillofacial Prosthodontics, University Hospital Groningen, P.O. Box 30.001, NL-9700 RB Groningen, The Netherlands. Fax: 31-50-3611136; e-mail: l.meijndert@kchir.azg.nl.

Accepted for publication September 12, 2003.