

Case report

Late spontaneous resolution of a double anterior chamber post deep anterior lamellar keratoplasty



Andrea Passani; Angela Tindara Sframeli; Pasquale Loiudice*; Marco Nardi

Abstract

A 31-year-old healthy male underwent deep anterior lamellar keratoplasty with big-bubble technique for treatment of keratoconus in his right eye. One week after surgery, he presented with detachment of the endothelium-Descemet complex with formation of a double anterior chamber, despite the apparent absence of an intraoperative Descemet membrane rupture. A subsequent intervention with the intent to relocate the corneal graft button was not effective, because the detachment appeared again one day later. The authors hypothesized that, at the time of the stromal dissection with big bubble technique, a small amount of air penetrated into the anterior chamber, creating a false pathway through the trabecular meshwork. The aqueous humor then penetrated the graft flowing through the false pathway, causing the endothelium-Descemet detachment. The persistence of that pathway, even after the intervention of graft repositioning, caused the failure of the latter procedure and persistence of the double chamber. We decided to wait and observe. The double anterior chamber spontaneously resolved in approximately three months.

Keywords: Big-bubble technique, Deep anterior lamellar keratoplasty, Double anterior chamber, Keratoconus

© 2017 The Authors. Production and hosting by Elsevier B.V. on behalf of Saudi Ophthalmological Society, King Saud University. This is an open access article under the CC BY-NC-ND license (<http://creativecommons.org/licenses/by-nc-nd/4.0/>).
<http://dx.doi.org/10.1016/j.sjopt.2017.01.003>

Introduction

The term Deep Anterior Lamellar Keratoplasty (DALK) indicates a corneal surgical transplantation technique in which the donor's corneal button, deprived of the endothelium and the Descemet membrane (DM), is fixed above the host's endothelium-Descemet complex. Anwar and Teichman described a technique in which, after partial thickness trephination, air was injected through a 30-gauge needle into the stroma to form a large bubble between the DM and the deep stromal layers.¹ Currently, the DALK with big bubble dissection is considered a reliable and safe surgical technique and

represents the technique of choice in keratoconus patients since, when compared with penetrating keratoplasty, this procedure demonstrated several advantages including lower risk of rejection and higher endothelial survival.² A possible complication associated with the DALK procedure is the rupture of the endothelium-Descemet complex, which occurs in 4.4–36% of interventions depending on the technique used although a lower perforation rate was reported after big bubble technique.^{1,3,4} DM rupture facilitates the formation of a double anterior chamber because it enables the aqueous humor to penetrate into the virtual space between the graft's stroma and the host's Descemet membrane.

Received 12 February 2016; received in revised form 13 January 2017; accepted 16 January 2017; available online 16 February 2017.

Abbreviations: C₃F₈, perfluoropropane, SF₆, sulfur hexafluoride

Ophthalmology Unit, Department of Surgical, Medical, Molecular and Critical Area Pathology, University of Pisa, Via Paradisa 2, 56124 Pisa, Italy

* Corresponding author at: Dipartimento di Patologia Chirurgica, Medica, Molecolare e dell'Area Critica; Unità Operativa Oculistica Universitaria, Via Paradisa 2, 56124 Pisa, Italy.

e-mail address: ldcpasquale@gmail.com (P. Loiudice).



Peer review under responsibility of Saudi Ophthalmological Society, King Saud University



Production and hosting by Elsevier

Access this article online:
www.saudiophthaljournal.com
www.sciencedirect.com

We report a case that demonstrated a late but spontaneous resolution of DM detachment post deep anterior lamellar keratoplasty.

Case presentation

A 31-year-old healthy male referred to our ophthalmic department with a previous diagnosis of bilateral keratoconus. At presentation a complete ocular examination was performed, demonstrating a best-corrected visual acuity of 20/200 in his right eye (RE) and 20/32 in his left eye (LE), an intraocular pressure (IOP) of 10 mmHg (RE) and 12 mmHg (LE) (Goldmann Applanation Tonometer), and no alterations at fundus oculi examination. The corneal topography (Sirius system, CSO, Firenze, Italy) showed keratometric readings of K1 = 53.51D, K2 = 65.27D, AK = 72.25D in RE and K1 = 45.73D, K2 = 53.40D, AK = 54.31D in LE. Pachymetry could not be performed in RE using a non-contact specular microscope (Tomey EM-3000, Topcon, Japan). In LE pachymetry was 508 microns. Clinical and instrumental findings supported the indication for a surgical approach in RE. We chose a big-bubble technique DALK. The entire surgical procedure was uneventful, except for the development of a small, peripherally-arranged air bubble in the anterior chamber, coincidental with the development of the intrastromal bubble. No Descemet membrane micro-rupture or any other complication occurred (also confirmed by the subsequent revision of the intervention tape). One day after surgery, the corneal button appeared adherent and transparent, with some slight folds of the DM. The anterior chamber was regularly deep and the IOP was 13 mmHg. One week after surgery, we observed in RE that the DM was centrally detached from the corneal stroma, with the consequent formation of a double anterior chamber. Corneal edema reduced visual acuity to light perception. IOP was 13 mmHg. An anterior segment examination using a Scheimpflug camera (Sirius system, CSO, Firenze, Italy) confirmed the diagnosis of an endothelium-Descemet detachment (Fig. 1). After obtaining a new informed consent, sterile air was introduced into the anterior chamber and the liquid at the interface level was drained. This procedure, however, did not resolve the endothelium-Descemet detachment. Therefore, in agreement with the patient, during the same surgical session, the corneal graft was repositioned. After removing the original sutures, the graft was lifted; the endothelium-Descemet complex was exposed and appeared intact and free from any Descemet membrane microruptures. The transplanted flap was then sutured again and a small amount of sterile air was injected into the anterior chamber.

At the conclusion of the surgery, neither the Descemet membrane detachment nor any other complication was observed. Unfortunately, one day after replacing the corneal graft button, the patient's endothelium-Descemet complex appeared detached for a second time with the formation, once again, of an anterior double chamber. At the next follow-up visit, 7 days later, the transplanted flap appeared transparent but the anterior double chamber persisted. We decided to wait and observe. About three months after DALK, we observed that the graft button was now adhered and transparent. A degree of lens opacity was due, in our opinion, to the sterile air injection in the anterior chamber. Visual acuity was 20/50, IOP was 14 mmHg and fundus oculi appeared normal. Scheimpflug camera acquisitions demonstrated the complete resolution of the detachment (Fig. 2) Pachymetry was 582 μm , in line with the standard level after DALK, like the corneal astigmatism (3 diopters) and the specular microscopy endothelial cell count (2481/mm²).⁵

Discussion

The detachment of the endothelium-Descemet complex, with the formation of an anterior double chamber, is one of the rare complications of the DALK procedure and is usually due to the presence of Descemet membrane macro or micro tears. These tears may occur during air injection or as a result of accidental insertion of instruments, saline solution, or the ophthalmic viscosurgical device between stroma and DM. Predisposing factors include shallow AC, blunt keratomes or weak adhesions between stroma and DM.⁶ This complication is usually treated by sterile air or gas (SF₆/C₃F₈) injection into the anterior chamber in order to increase the pressure on the endothelium-Descemet complex. This enables the resolution of the aqueous humor which has been accumulated at the interface level, favoring the adhesion of the transplanted graft. This is usually sufficient to resolve the detachment and the procedure can be repeated several times in the post-operative phase. In some cases, despite repeated injection of the tamponade, the clinical picture does not improve.⁶ In similar conditions, some surgeons opt for a re-intervention with penetrating technique. However, the criteria for optimal management, including proper timing and type of treatment, have not been defined.⁶ On the other hand, others prefer to wait for spontaneous resolution of the endothelium-Descemet complex, as has been shown to occur in some cases.⁷ The injection of gas, especially if repeated, has however shown a non-negligible toxicity to the endothelium with an increased risk of corneal decomposition.⁸ It has been associated with a transient increased IOP with a subsequent increased risk of angle closure, pupillary block and Urrets

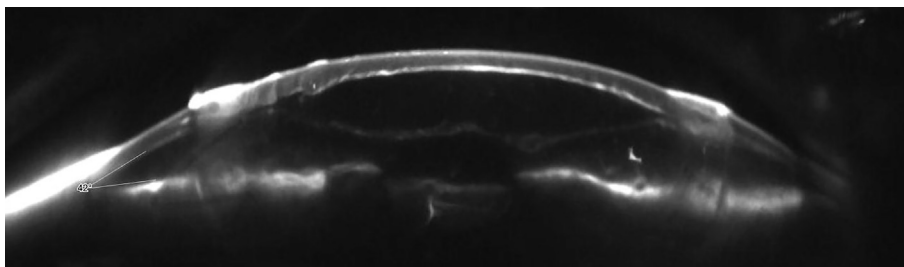


Figure 1. Right eye: anterior segment photograph with Scheimpflug camera showing a double anterior chamber.

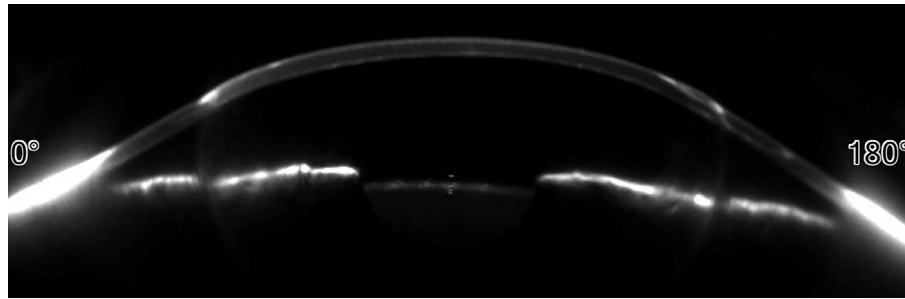


Figure 2. Right eye: anterior segment photograph with Scheimpflug camera showing spontaneous resolution of the double anterior chamber.

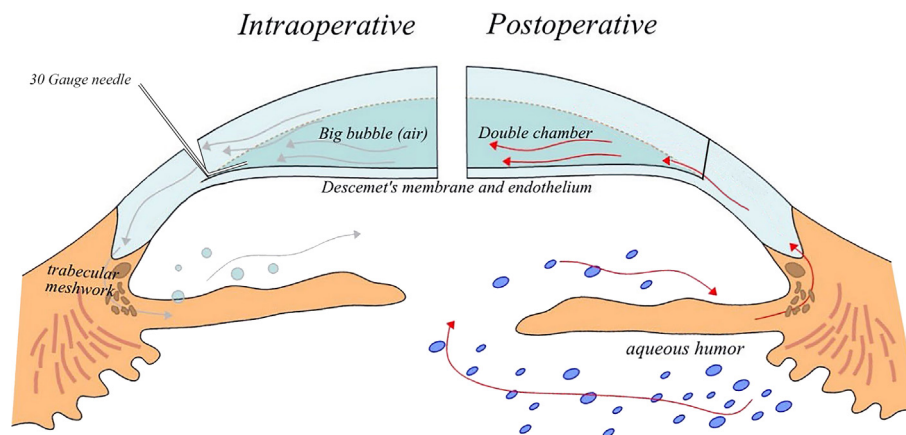


Figure 3. Supposed mechanism of double chamber formation. On the left: false trabecular pathway formation during big bubble dissection. On the right: aqueous humor flows through the trabecular pathway formed during the big bubble dissection.

Zavalía syndrome.⁹ These findings suggest that repeated injections of gas tamponade should be avoided. The pathogenesis of non-resolving DM detachment has been associated with several potential causes. One of them is a perforation of the DM as a consequence of the surgical procedures that may result in a non-self-sealing tear. Postoperative hypotony and shallow anterior chamber may also cause insufficient buffering on the endothelium-Descemet complex. Sharifipour reported an escape of the tamponading agent through the fistula in a case of DM detachment following trabeculectomy.¹⁰ A familiar and anatomical predisposition may explain a certain number of unusual and delayed presentations.¹¹ In our case, we hypothesized that during stromal dissection with the big bubble technique, a small amount of air penetrated into the anterior chamber creating a false pathway through the trabecular meshwork (Fig. 3). The aqueous humor then penetrated the graft flowing through the false pathway causing the endothelium-Descemet detachment. The persistence of that pathway, even after the secondary intervention to reposition the graft, caused the failure of the previous procedures and the persistence of the double chamber. Only after the spontaneous closure of the false pathway, the endothelium-Descemet detachment resolved.

Conflict of interest

The authors declared that there is no conflict of interest.

References

1. Anwar M, Teichmann KD. Big-bubble technique to bare Descemet's membrane in anterior lamellar keratoplasty. *J Cataract Refractive Surg* 2002;**28**(3):398–403.
2. Han DC, Mehta JS, Por YM, Htoon HM, Tan DT. Comparison of outcomes of lamellar keratoplasty and penetrating keratoplasty in keratoconus. *Am J Ophthalmology* 2009;**148**(5):744–51, 744–51.e1.
3. Leccisotti A. Descemet's membrane perforation during deep anterior lamellar keratoplasty: prognosis. *J Cataract Refractive Surg* 2007;**33**(5):825–9.
4. Jhanji V, Sharma N, Vajpayee RB. Intraoperative perforation of Descemet's membrane during "big bubble" deep anterior lamellar keratoplasty. *Int Ophthalmology* 2010;**30**(3):291–5.
5. Kubaloglu A, Koytak A, Sari ES, Akyol S, Kurnaz E, Ozerturk Y. Corneal endothelium after deep anterior lamellar keratoplasty and penetrating keratoplasty for keratoconus: a four-year comparative study. *Indian J Ophthalmology* 2012;**60**(1):35–40.
6. Chow VW, Agarwal T, Vajpayee RB, Jhanji V. Update on diagnosis and management of Descemet's membrane detachment. *Curr Opin Ophthalmology* 2013;**24**(4):356–61.
7. Venkatraman A. Spontaneous resolution of double anterior chamber with perforation of Descemet's membrane in deep anterior lamellar keratoplasty. *Oman J Ophthalmology* 2012;**5**(2):112–4.
8. Landry H, Aminian A, Hoffart L, et al. Corneal endothelial toxicity of air and SF6. *Invest Ophthalmology Visual Sci* 2011;**52**(5):2279–86.
9. Maurino V, Allan BD, Stevens JD, Tuft SJ. Fixed dilated pupil (Urrets-Zavalía syndrome) after air/gas injection after deep lamellar keratoplasty for keratoconus. *Am J Ophthalmology* 2002;**133**(2):266–8.
10. Sharifipour F, Nassiri S, Idan A. Descemet's membrane detachment management following trabeculectomy. *J Ophthalmic Vision Res* 2016;**11**(3):323–5.
11. Hirano K, Kojima T, Nakamura M, Hotta Y. Triple anterior chamber after full-thickness lamellar keratoplasty for lattice corneal dystrophy. *Cornea* 2001;**20**(5):530–3.