

Submitted:  
03.01.2017  
Accepted:  
12.02.2017  
Published:  
30.06.2017

## Repeatability and reproducibility of measurements of the suburethral tape location obtained in pelvic floor ultrasound performed with a transvaginal probe

Maria Magdalena Dresler<sup>1</sup>, Jacek Kociszewski<sup>2</sup>, Edyta Właźlak<sup>1</sup>,  
Piotr Pędraszewski<sup>3</sup>, Agnieszka Trzeciak<sup>4</sup>, Grzegorz Surkont<sup>1</sup>

<sup>1</sup> *Ultrasound Diagnostics Laboratory, Division of Operative Gynecology and Gynecologic Oncology, Gynecology and Obstetrics Department, Medical University of Łódź, Poland*

<sup>2</sup> *Frauenklinik, Evangelisches Krankenhaus Hagen-Haspe GmbH, Hagen, Germany*

<sup>3</sup> *Gynecology and Obstetrics Unit, Voivodeship Hospital Complex, Płock, Poland*

<sup>4</sup> *Medical Center, Remedium Municipal Outpatient Center, Głowno, Poland*

*Correspondence: Dr n. med. Edyta Właźlak, Klinika Ginekologii Operacyjnej i Onkologicznej, I Katedra Ginekologii i Położnictwa, Uniwersytet Medyczny w Łodzi, ul. Wileńska 37, 94-029 Łódź, Polska, tel.: +48 42 686 04 71, e-mail: edytawlazlak@gmail.com*

DOI: 10.15557/JoU.2017.0014

### Keywords

pelvic ultrasound,  
urogynecology,  
suburethral tape,  
repeatability,  
transvaginal probe

### Abstract

**Introduction:** Implants used to treat patients with urogynecological conditions are well visible in US examination. The position of the suburethral tape (sling) is determined in relation to the urethra or the pubic symphysis. **Aim of the study:** The study was aimed at assessing the accuracy of measurements determining suburethral tape location obtained in pelvic US examination performed with a transvaginal probe. **Material and methods:** The analysis covered the results of sonographic measurements obtained according to a standardized technique in women referred for urogynecological diagnostics. Data from a total of 68 patients were used to analyse the repeatability and reproducibility of results obtained on the same day. **Results:** The intraclass correlation coefficient for the repeatability and reproducibility of the sonographic measurements of suburethral tape location obtained with a transvaginal probe ranged from 0.6665 to 0.9911. The analysis of the measurements confirmed their consistency to be excellent or good. **Conclusions:** Excellent and good repeatability and reproducibility of the measurements of the suburethral tape location obtained in a pelvic ultrasound performed with a transvaginal probe confirm the test's validity and usefulness for clinical and academic purposes.

## Introduction

Stress urinary incontinence (SUI) is the most common type of urinary incontinence (UI) in women. A conservative or a surgical approach to treatment are possible. The mainstay of the currently employed surgical treatment are the Burch procedure also known as colposuspension, and the sling procedure utilizing a synthetic suburethral tape<sup>(1–3)</sup>.

Imaging tests play a crucial role in the diagnostics of urogynecological disorders, yielding essential information on the structure, anatomical relationships, and

mobility of the structures of the lesser pelvis<sup>(4)</sup>. Ultrasound examination (US) has been employed in urogynecology for over 20 years now. Since polypropylene suburethral tapes for the surgical management of SUI were introduced, sonographic imaging has become more commonly used. The present-day slings are made of polypropylene mesh that is strongly echogenic and thus well visible in an US scan. It is, however, not visible in a conventional radiograph, CT or MRI scan<sup>(5,6)</sup>. Various US modalities are used in contemporary urogynecology, including 2D, 3D, and 4D US, obtained with a transabdominal, transvaginal or transrectal probe<sup>(5–8)</sup>. Commonly, the effect of suburethral tape placement is

assessed in pelvic floor sonography with a transvaginal probe (PFS-TV)<sup>(5)</sup>. It is a low-cost, non-invasive test allowing real-time visualization of the pelvic structures, enabling numerous repetitions, and characterized by high frequency. The repeatability and reproducibility of the measurements determining the position of the suburethral tape on PFS-TV have not, however, been evaluated so far. Repeatability is the degree to which measurements of the same anatomical distance are consistent when measured using the same device, the same measuring protocol, and by the same specialist. Reproducibility, in turn, is understood as the degree to which measurement results for the same anatomical distance are consistent when taken under changed measuring circumstances, e.g. when measured by different specialists<sup>(9,10)</sup>.

The purpose of the study was to evaluate the accuracy of PFS-TV measurements of suburethral tape position in relation to the bladder and the urethra.

## Material and methods

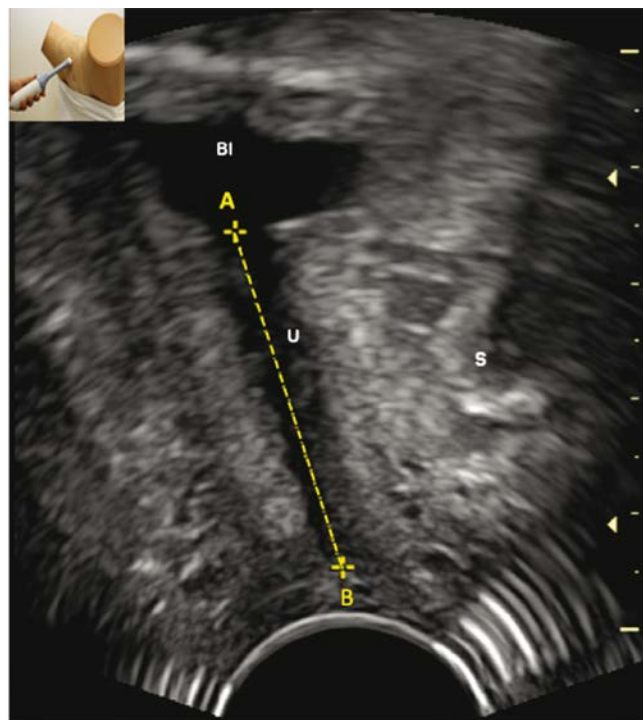
The analysis covered sonographic measurements performed in 68 female patients referred to the Division of Operative Gynecology and Gynecologic Oncology in Łódź for urogynecological diagnostics. All patients included in the study provided their informed consent, and the study was approved by a bioethics committee (Ref. No. RNN/125/2001/KE).

The patients were examined with B-K Medical Pro Focus UltraView device, using 8848, 2D transvaginal probe of 6.5 MHz frequency, by specialists with highly experienced in gynecological and urogynecological US imaging. The accuracy of the measurements was up to 0.1 mm.

For the purpose of analysing the repeatability and reproducibility, measurements taken by two different operators were used, obtained in the following setups:

- each specialist individually – measurements on one and two different ultrasound images;
- comparison of findings by two different specialists – measurements on the same ultrasound image.

PFS-TV followed a standardized technique developed by Kociszewski<sup>(5)</sup>, and was performed in patients with the bladder filled with 200–300 ml of liquid. The amount of the collected urine was computed by the US device, based on three bladder dimensions: right-left, anterior-posterior and superior-inferior. Introital ultrasound was performed with a 2D, high frequency (6.5 MHz, emission angle of 160°) transvaginal probe in a patient sitting in a half-reclined position in a gynecology chair. The transducer was placed over the external orifice of the urethra, its axis aligned with the body's axis, with minimal pressure exerted on the examined area. The pubic symphysis (which was the sole fixed orientation point), the urethra, and the neck of the bladder were



**Fig. 1.** Method of measuring the sonographic urethral length in PFS-TV, sagittal axis<sup>(11)</sup>. AB – sonographically measured urethral length, A – mid-point of the internal urethral orifice, B – mid-point of the most peripherally located portion of the hypoechoic urethral region, U – urethra, Bl – bladder, S – symphysis

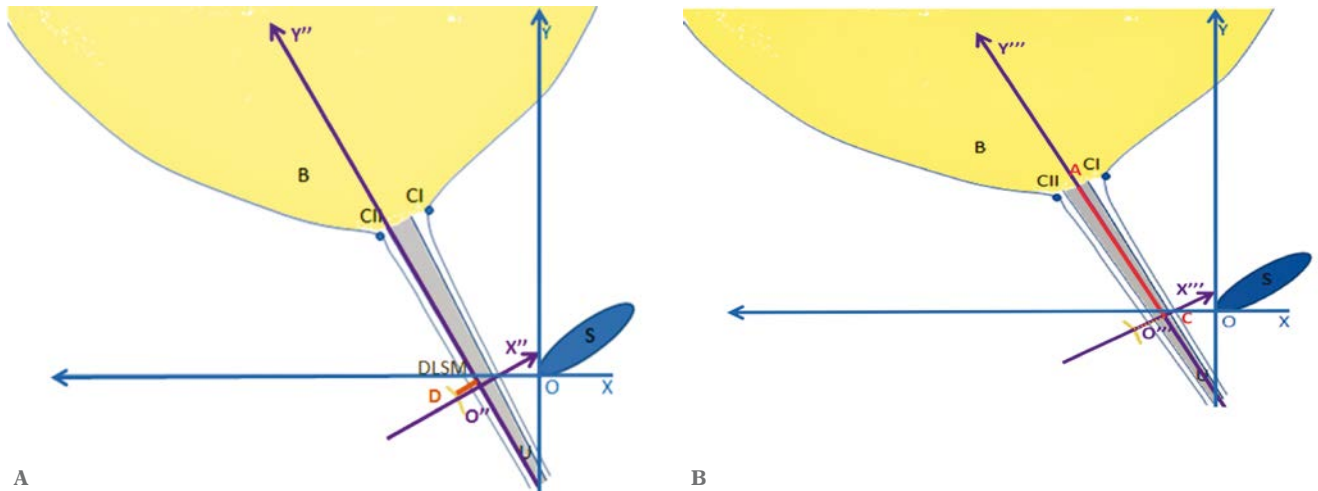
all depicted in one image, and the sonographic urethral length was measured in the sagittal axis (Fig. 1).

Following Kociszewski's recommendations<sup>(5,11–14)</sup>, suburethral tape location was identified along the transverse and the longitudinal urethral axis (Fig. 2, 3).

introital ultrasound of the urethra conducted in alignment with the urethral axis, two urethral layers are visualized, hyperechoic and hypoechoic. Kociszewski determined the hypoechoic portion of the urethra to consist of the mucosa, submucosa, and a layer of smooth muscles, terming it the longitudinal smooth muscle complex (LSM). The tape position along the transverse urethral axis is identified by Kociszewski as the distance between the LSM complex and the point of the tape that is the most proximal to the outermost layer of the complex, and is thereby referred to as the tape-urethra distance (TUD).

The methodology of tape positioning according to Kociszewski assumes X''O''Y'' and X'''O'''Y''' coordinate sets.

To measure the tape location along the transverse urethral axis (TUD), the O''Y''-axis is placed along the edge of the hypoechoic urethral region that is in closer proximity to the tape. The O''X''-axis is then run through the point of the tape that is the most proximal to the hy-



**Fig. 2.** *S*Methods of determining tape location – schematic representation: *A.* tape location along the transverse urethral axis: TUD parameter –  $DO''$  distance; *B.* tape location along the longitudinal urethral axis: TP parameter –  $AC$  distance. *S* – symphysis; *B* – bladder; *U* – urethra; distance  $DO''$  – TUD parameter; *D* – point of the tape most proximal to the LSM complex;  $O''$  – projection of *D* point on the  $O''Y''$ -axis;  $AC$  distance – TP parameter; *A* – mid-point of the internal urethral orifice; *D* – mid-tape; *C* – projection of the mid-tape (*D* point) on the  $O''Y''$  –  $O''$ -axis; *CI* and *CII* – points locating the urethral orifice at rest

poechoic urethral region. TUD is the distance between the point of the tape that is the most proximal to the LSM complex (situated on the  $O''X''$ -axis) and its projection on the  $O''Y''$ -axis ( $DO''$  distance in Fig. 2 A).

RTP (relative tape position) is used in this study to refer to the tape location along the longitudinal urethral axis.

To measure the location of the tape along the longitudinal urethral axis (RTP parameter), the  $O'''Y'''$ -axis is placed along the midurethra. The  $O'''X'''$ -axis is then run through the mid-tape (point *D*). The TP parameter is the distance between the point *A*, identified when measur-

ing the urethral length (Fig. 1), and the mid-tape's projection on the  $O'''Y'''$ - axis (Fig. 2 A).

The RTP parameter, computed with Formula 1, is the relationship of the two distances, the TP parameter ( $AC$ ) and the sonographically measured urethral length ( $AB$ ), expressed as a percentage.

**Formula 1**

$$RTP (\%) = \frac{AC}{AB} \times 100\%$$

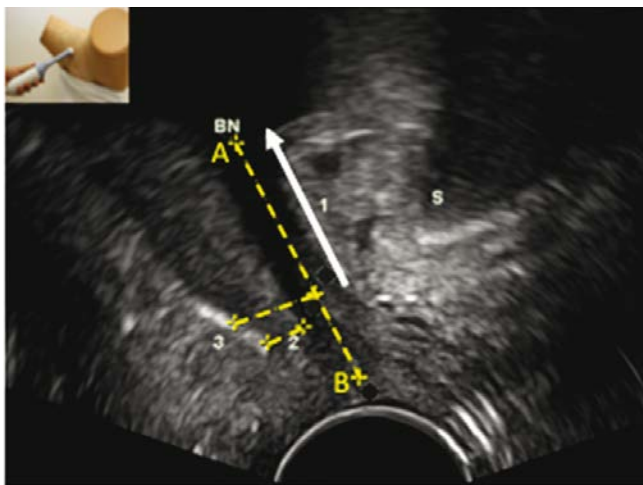
RTP was calculated in two steps. In the first step, the sonographic urethral length ( $AB$  distance in Fig. 1), and the distance between the mid-tape and the internal urethral orifice ( $AC$  distance in Fig. 2B) were measured. In the second, the measurements were transferred to a computer database. RTP along the longitudinal urethral axis was then computed using Formula 1.

To evaluate the limits of agreement, Bland-Altman agreement scale was applied. ICC values  $< 0.20$  were considered as poor, those in the range of 0.21–0.41 as fair, 0.41–0.60 as moderate, 0.61–0.80 as good, and 0.81–1.00 as excellent<sup>(9,10)</sup>.

**Results**

The analysis of the repeatability and reproducibility of the parameters of the tape location covered both the sonographic measurements as such (i.e. TUD and TP) and the RTP parameter computed with Formula 1.

For measurements taken by the same specialist on the same US image, the repeatability of TUD values ranged



**Fig. 3.** *S*Methods of determining tape location in PFS-TV, sagittal axis. *AB* – sonographically measured urethral length; *1* (arrow) – the distance of the tape from the internal urethral orifice (TP distance); *2* – the shortest tape – urethra distance (TUD distance); *3* – mid-tape; *BN* – bladder neck; *S* – symphysis

from 0.9820–0.9826, TP – 0.9846–0.9911, and RTP – 0.9879–0.9891. The reproducibility of measurements obtained by two different specialists on the same US image was for TUD – 0.9671, for TP – 0.9507, and for RTP – 0.9575. For measurements taken by the same specialist on two different US images, the repeatability of TUD values was in the range of 0.6665–0.9151, TP – 0.8691–0.9519, and RTP – 0.9122–0.9585

## Discussion

Tension-free vaginal tape (TVT) has for many years been the mainstay of surgical management of SUI<sup>(2,15)</sup>. Tape procedures are characterized by high efficiency and a low complication rate<sup>(2,13,15–17)</sup>, yet the exact mechanism of its action and the causes of treatment failure have not been clarified so far.

The effect that TVT positioning has on effective treatment of SUI raises controversies<sup>(7,13,17)</sup>. Some authors believe that the tape location in the midurethral area according to Ulmsten's recommendations is critical for the successful surgical outcome<sup>(13,14,18)</sup>. Others claim that the tape location along the longitudinal axis of the urethra is of little importance<sup>(7,17)</sup>. The tension of the tape, however, constitutes a commonly-acknowledged determinant of the TVT procedure's success<sup>(19,20)</sup>. Kociszewski et al. believe that, aside from the importance of the tape positioning along the longitudinal urethral axis, also its alignment with the transverse urethral axis, as well as the urethra's mobility may affect the outcome<sup>(13,14,18)</sup>. In their opinion, individual planning of tape position for each patient improves the final outcome<sup>(13,14,18)</sup>. Dietz

et al. in their analyses did not manage to confirm the effect of the tape location along the longitudinal and transverse axis of the urethra on the successful management of SUI. In their opinion, the tape's mobility within the suprapubic arch results with a reduced distance between the tape and the symphysis. In Dietz's studies, introital 4D US performed with a transabdominal probe in patients with an empty bladder demonstrated the tape's distance from the symphysis to influence successful management of SUI<sup>(7,17,21)</sup>. However, so far no studies comparing the two US techniques have been undertaken.

Our findings confirm good and excellent repeatability of sonographic measurements of TVT location performed by the same or two different specialists, proving the usefulness of PFS-TV for the assessment of the suburethral tape location.

## Conclusions

The excellent and good repeatability and reproducibility of PFS-TV measurements of the suburethral tape confirm the test's usefulness for clinical practice and academic research.

## Conflict of interest

*The authors do not claim any financial or personal links to persons or organizations that might adversely affect the content of this publication or claim rights thereto.*

## References

1. Surkont G, Właźlak E, Kowalski A, Zdziennicki A, Suzin J: Ocena skuteczności kolposuspensji sposobem Burcha w zakresie leczenia wysiłkowego nietrzymania moczu (WNM) za pomocą diagramu CONSORT. *Ginekol Pol* 2006; 77: 463–467.
2. Surkont G, Właźlak E, Kazimierak W, Dunicz-Sokołowska A, Suzin J: Efekty leczenia operacyjnego wysiłkowego nietrzymania moczu (WNM) za pomocą kolposuspensji sposobem Burcha oraz taśmy IVS oceniane przy użyciu różnych badań uroginekologicznych. *Ginekol Pol* 2007; 6: 460–463.
3. Surkont G, Właźlak E, Stetkiewicz T, Sobczuk A, Krajewski P, Suzin J: Kolposuspensja zmodyfikowanym sposobem Burcha – kompleksowa ocena średnioterminowych wyników leczenia wysiłkowego nietrzymania moczu (WNM) u kobiet z zastosowaniem subiektywnych i obiektywnych metod diagnostycznych. *Przegląd Menopauzalny* 2005; 19: 29–35.
4. Wieczorek A, Stankiewicz A, Santoro GA, Woźniak M, Bogusiewicz M, Rechberger T: Nowoczesne techniki ultrasonograficzne w diagnostyce dysfunkcji narządów miednicy mniejszej u kobiet. *Ultrasonografia* 2011; 45: 9–19.
5. Kociszewski J, Rautenberg O, Kolben S, Eberhard J, Hilgers R, Viereck V: Tape functionality: position, change in shape, and outcome after TVT procedure – mid-term results. *Int Urogynecol J* 2010; 21: 795–800.
6. Dietz HP: Pelvic floor ultrasound in incontinence: what's in it for the surgeon? *Int Urogynecol J* 2011; 22: 1085–1097.
7. Chantarasorn V, Shek K, Dietz HP: Sonographic appearance of transobturator slings: implications for function and dysfunction. *Int Urogynecol J* 2011; 22: 493–498.
8. Santoro GA, Wieczorek AP, Dietz HP, Mellgren A, Sultan AH, Shobeiri SA et al.: State of the art: an integrated approach to pelvic floor ultrasonography. *Ultrasound Obstet Gynecol* 2011; 37: 381–396.
9. Digesu GA, Calandrini N, Derpapas A, Gallo P, Ahmed S, Khullar V: Intraobserver and interobserver reliability of the three-dimensional ultrasound imaging of female urethral sphincter using a translabial technique. *Int Urogynecol J* 2012; 23: 1063–1068.
10. Bland JM, Altman DG: Statistical methods for assessing agreement between two methods of clinical measurement. *Lancet* 1986; 1: 307–310.
11. Właźlak E, Kociszewski J, Suzin J, Dresler M, Surkont G: Urethral length measurement in women during sonographic urethrocytography – an analysis of repeatability and reproducibility. *J Ultrason* 2016; 16: 25–31.
12. Kociszewski J, Rautenberg O, Perucchini D, Eberhard J, Geissbühler V, Hilgers R et al.: Tape functionality: sonographic tape characteristics and outcome after TVT incontinence surgery. *Neurourol Urodyn* 2008; 27: 485–490.
13. Kociszewski J, Rautenberg O, Kuszka A, Eberhard J, Hilgers R, Viereck V: Can we place tension-free vaginal tape where it should be? The one-third rule. *Ultrasound Obstet Gynecol* 2012; 39: 210–214.
14. Viereck V, Kuszka A, Rautenberg O, Właźlak E, Surkont G, Hilgers R et al.: Do different vaginal tapes need different suburethral incisions? The one-half rule. *Neurourol Urodyn* 2015; 34: 741–746.
15. Ward KL, Hilton P; UK and Ireland TVT Trial Group: A prospective multicenter randomized trial of tension-free vaginal tape and colposuspension for primary urodynamic stress incontinence: two-year follow-up. *Am J Obstet Gynecol* 2004; 190: 324–331.

16. Cetinel B, Demirkesen O, Onal B, Akkus E, Alan C, Can G: Are there any factors predicting the cure and complication rates of tension-free vaginal tape? *Int Urogynecol J Pelvic Floor Dysfunct* 2004; 15: 188–193.
17. Dietz H, Mouritsen L, Ellis G, Wilson PD: How important is TVT location? *Acta Obstet Gynecol Scand* 2004; 83: 904–908.
18. Właźlak E, Viereck V, Kociszewski J, Kuszka A, Rautenberg O, Walser C *et al.*: Role of intrinsic sphincter deficiency with and without urethral hypomobility on the outcome of tape insertion. *Neurourol Urodyn* 2017. DOI: 10.1002/nau.23211 [Epub ahead of print].
19. Chene G, Cotte B, Tardieu AS, Savary D, Mansoor A: Clinical and ultrasonographic correlations following three surgical anti-incontinence procedures (TOT, TVT and TVT-O). *Int Urogynecol J Pelvic Floor Dysfunct* 2008; 19: 1125–1131.
20. Yang JM, Yang SH, Huang WC, Tzeng CR: Correlation of tape location and tension with surgical outcome after transobturator suburethral tape procedures. *Ultrasound Obstet Gynecol* 2012; 39: 458–465.
21. Dietz HP, Wilson PD: The ‘iris effect’: how two-dimensional and three-dimensional ultrasound can help us understand anti-incontinence procedures. *Ultrasound Obstet Gynecol* 2004; 23: 267–271.