



British Journal of Medicine & Medical Research

21(10): 1-5, 2017; Article no.BJMMR.33309
ISSN: 2231-0614, NLM ID: 101570965

Generalized Gingival Pyogenic Granuloma in a 11 Years Old Female – A Diagnostic Challenge

J. Leelavathy¹, Shilpa K. Ramesh^{2*} and A. Winnifred Christy¹

¹Department of Oral Medicine and Maxillofacial Radiology, CSI College of Dental Sciences and Research, Madurai, Tamil Nadu, India.

²CSI College of Dental Sciences and Research, Madurai, Tamil Nadu, India.

Authors' contributions

This work was carried out in collaboration between all authors. Author JL diagnosed the case, designed the manuscript. Author SKR prepared the manuscript and managed the literature searches, Author WC helped in reviewing and editing the manuscript. All authors read and approved the final manuscript.

Article Information

DOI: 10.9734/BJMMR/2017/33309

Editor(s):

(1) Rodrigo Crespo Mosca, Department of Biotechnology, Institute of Energetic and Nuclear Research (IPEN-CNEN), University of Sao Paulo (USP), Brazil.

Reviewers:

(1) José López López, University of Barcelona, Spain.

(2) Parag M. Khatri, Sri Aurobindo College of Dentistry, India.

(3) Gowri Pendyala, Rural Dental College, Pravara Institute of Medical, India.

Complete Peer review History: <http://www.sciencedomain.org/review-history/19285>

Case Study

Received 9th April 2017
Accepted 18th May 2017
Published 1st June 2017

ABSTRACT

Aims: To include pyogenic granuloma as one of the differential diagnosis of generalized gingival enlargements.

Presentation of Case: In this article, we report a 11 years old female patient with generalized gingival enlargement, which on thorough clinical, histopathological and radiological examination concluded as a generalized gingival pyogenic granuloma.

Discussion: Pyogenic granuloma (PG), a non specific conditioned gingival enlargement is a common localized exaggerated reactive hyperplasia of connective tissue of the oral cavity or skin in response to local factors and chronic irritation. But PG presenting as a generalized gingival enlargement is very rare and uncommon. Only one case was reported on "Generalized gingival pyogenic granuloma" in 2011, showing its rarity. But in our case, in addition to generalized presentation of pyogenic granuloma, it was also associated with extensive alveolar bone loss, tooth mobility and root resorption.

Conclusion: Hence, although it is uncommon, pyogenic granuloma can also occur as a generalized gingival enlargement.

*Corresponding author: E-mail: krshilpashree@gmail.com;

Keywords: Generalized gingival enlargement; Pyogenic Granuloma (PG); generalised pyogenic granuloma.

1. INTRODUCTION

Gingival enlargement is defined as an increase in size of the gingiva. It can be classified as inflammatory, drug induced, enlargements associated with systemic diseases and conditions (hormonal, nutritional, allergic), neoplastic and false enlargements. Non-specific conditioned enlargement such as pyogenic granuloma is a tumor like growth, in which systemic conditioning factor has not been identified [1] and considered as an exaggerated conditioned response to minor trauma. Here, we report a case with an unique generalized presentation of gingival pyogenic granuloma. To the best of our knowledge and literature review, it is the second case reported in the literature after 2011 showing its rarity.

2. PRESENTATION OF CASE

A 11 years old female patient reported to our department of oral medicine and radiology, as referred by a general surgeon, with the chief complaint of painless, slowly growing growth in the gums since 2 months. History of growth in the gums which was initially smaller in size and progressed to that present size which was impeding during mastication and tooth brushing. No history of bleeding and other associated symptoms. No loss of weight and appetite. Family and systemic history were non-contributory. Review of systems were normal.

On extra-oral examination, a firm, non- fluctuant bilateral facial enlargement was evident. No abnormalities were detected in salivary glands and lymph nodes (Fig. 1).

Intraorally, a generalized diffuse gingival enlargement was evident in both maxilla and mandible (Fig. 2a,b).

Gingival enlargement covered almost entire crowns of the maxillary posterior teeth and three quarter the crown of the remaining teeth. The enlargement was pale pink in colour, firm and resilient in consistency, smooth and no bleeding on probing was elicited. Maxillary 1st molars showed grade – III mobility and all other teeth showed grade – I mobility. Local factors like plaque and calculus were evident due to inefficient oral hygiene practice because of the gingival enlargement. Considering all these, a

provisional diagnosis of fibrous dysplasia was given. Differential diagnosis of generalized gingival enlargement were given as in Table 1.

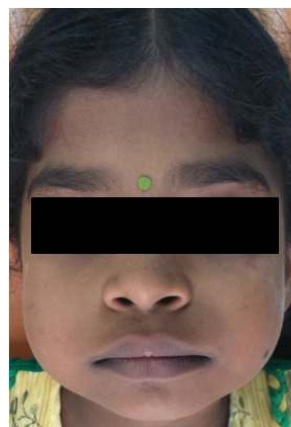

Fig. 1. Extraoral view showing bilateral facial enlargement

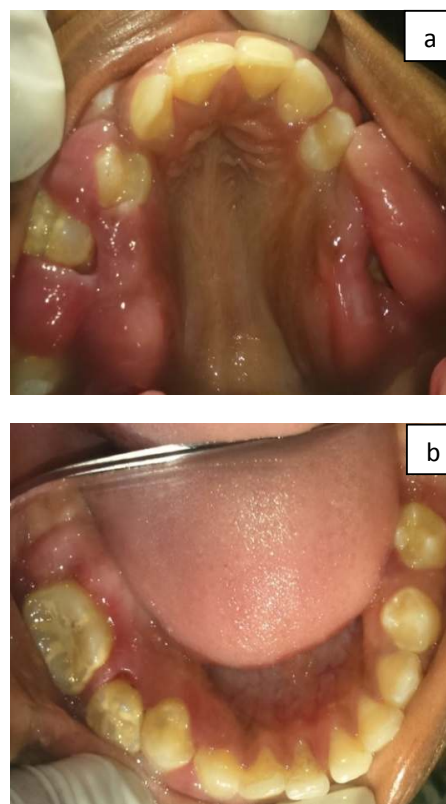


Fig. 2. Generalised gross gingival enlargement in both maxilla (a) and mandible (b)

Table 1. Differential diagnosis of generalised gingival enlargement

Common generalised gingival enlargements	Unusual generalised gingival enlargements reported in the literatures
<ul style="list-style-type: none"> • Chronic inflammatory gingival enlargement • Drug induced gingival enlargement • Hormonal gingival enlargement • Nutritional gingival enlargement • Allergic gingival enlargement • Plasma cell gingivitis • Leukemic enlargement • Sarcoidosis • Wegner’s granulomatosis • Crohn’s disease (regional enteritis) • Hereditary / idiopathic gingival fibromatosis • Acanthosis nigricans • Hashimoto’s thyroiditis • I cell disease / mucopolidosis II • Langerhans cell histiocytosis 	<ul style="list-style-type: none"> • Gingival fibromatosis with chronic periodontitis • Gingival fibromatosis with aggressive periodontitis • Primary orofacial granulomatosis • Non-specific inflammatory enlargement • Primary tuberculosis • Ligneous periodontitis / plasminogen deficiency • Multiple myeloma • Diffuse / multifocal peripheral odontogenic fibroma • Diffuse peripheral giant cell fibroma • Kaposi’s sarcoma • Diffuse periosteal fibroma, peripheral ossifying fibroma • Metastatic tumors

Routine blood investigations were found to be normal. Computed tomography scan (CT scan) which was prescribed by a general surgeon whom they consulted earlier, showed an ill-defined osteolytic lesions in the alveolar process of posterior aspect of maxilla and mandible with thinning of the bony floor of the maxillary antrum on both sides in coronal section (Fig. 3a) and gingival hypertrophy was noted on both sides in axial section (Fig. 3b).

Incisional biopsy was made under local anaesthesia and subjected to histopathological examination in which, hematoxylin and eosin stained section (10x) (Fig. 4) showed a hyperplastic epithelium and fibrous connective tissue with numerous tiny blood vessels, neutrophils, plasma cells and some fibrocytes suggestive of involutionary phase of pyogenic granuloma. Hence, a final diagnosis of generalized pyogenic granuloma was given.

3. DISCUSSION

The term “Pyogenic granuloma” (granuloma pyogenicum, hemangiomatous granuloma, granuloma telangiectaticum) introduced by Hartzell in 1904, is a misnomer as there is neither pus nor granuloma formation. It is a hyperactive benign inflammatory lesion commonly seen in the oral cavity. According to Kerr et al, in a study of 289 cases, reported that pyogenic granuloma has no apparent

predilection of any one age group [2]. The case reported here is 11 years old female patient and the incidence of pyogenic granuloma in 11-12 years old female patients is 11.16% only [3]. Gingiva, i.e. interdental papilla is the most common affected site (75%) followed by extragingival sites such as buccal mucosa (3.22%), tongue, lips (9.67%), palate and edentulous ridge [4]. It grows slowly sometimes rapidly, rarely exceeding 2-2.5 cm within weeks [5]. Classically pyogenic granuloma arises in response to various stimuli such as low-grade local irritation, [6,7] traumatic injury, hormonal factors, or certain kinds of drugs. The case reported here didn’t have such etiology and was unknown. And also pyogenic granuloma is commonly presented in the literature as localized, elevated, sessile or pedunculated vascular mass with smooth, lobulated or even warty surface which is commonly ulcerated and shows a tendency for hemorrhage either spontaneously or upon slight trauma [8] and long standing nature of the lesion can lead to fibrous maturation. [4] Rarely pyogenic granuloma can cause significant bone loss [9]. But in our case it was pink, smooth, firm, fibrous and resilient with no ulcerations or bleeding and uniquely presented as generalized gingival enlargement as well as fibrous maturation within a very short duration of 2 months and there was extensive alveolar bone loss with thinning of the floor of maxillary sinus on both sides and also resorption of the roots with tooth mobility. The

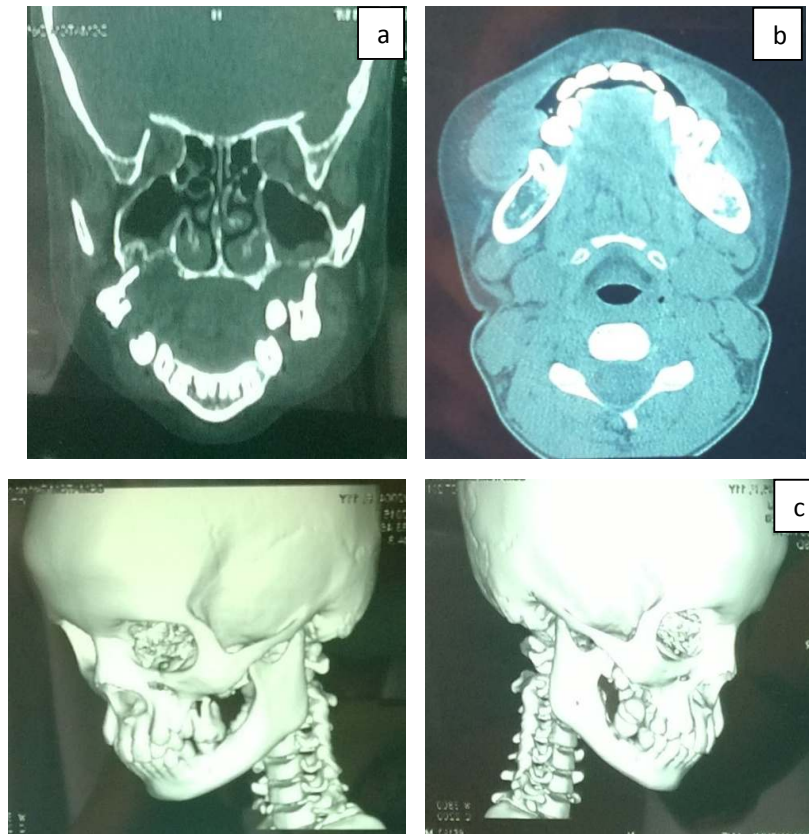


Fig. 3. CT scan showing (a) coronal section (b) axial section (c) 3D reconstructed

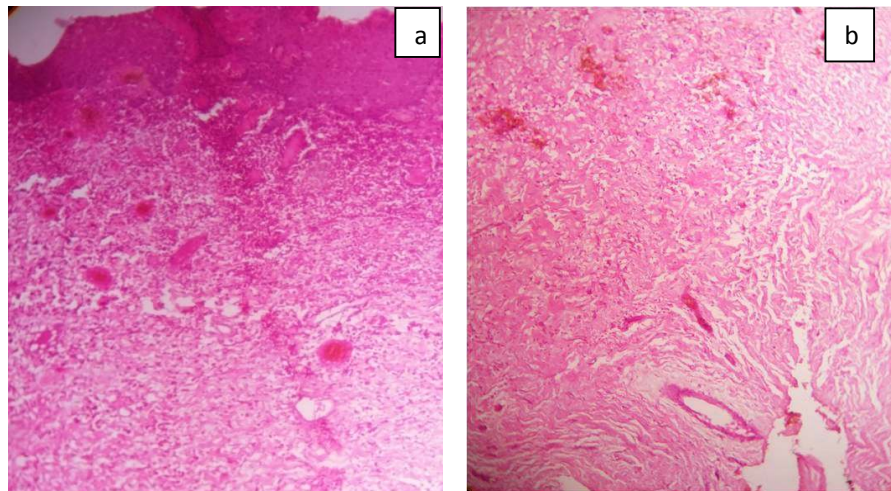


Fig. 4. Photomicrograph of hematoxylin and eosin stained section showing (a) hyperplastic epithelium and numerous capillaries (magnification: 10x) (b) fibrous connective tissue suggestive of involutory phase of pyogenic granuloma (magnification: 100x)

cause for the root resorption is unknown. The histopathological examination ruled out every possible differential diagnosis of generalized gingival enlargement (Table 1) [8] and arrived at a diagnosis of pyogenic granuloma, which is very

rare to be in the list of generalized gingival enlargement.

Hence this case report shows that the pyogenic granuloma can /can be

- A generalised gingival enlargement
- Get fibrous maturation within a short duration
- Associated with extensive alveolar bone loss,
- Cause tooth mobility and resorption of the roots
- Manifest as an extraoral facial enlargement

By combining generalised gingival enlargement and pyogenic granuloma, "Generalised gingival pyogenic granuloma" as a definitive diagnosis was given. In the PubMed search, only one case was reported on "generalised pyogenic granuloma" by Shivaswamy et al. in 2011 [10] and no other case of this kind was reported before 2011, showing its rarity. Treatment plan was surgical excision of the lesion using Nd: YAG laser by two appointments in a week interval, first in the right side and then in left side of the maxilla. Then gingivectomy and gingivoplasty in other regions. Grade – III mobile teeth were advised for extraction and review after 3 months. Unfortunately we missed the follow up of the case because the patient and her parents were not willing for the above advised treatment plan due to their low socioeconomic status.

4. CONCLUSION

The unique generalised enlargement in gingiva made the clinical diagnosis of pyogenic granuloma, as a challenging and perplexing one. But the histopathological description was similar to the classical one. Hence by considering only the clinical presentations, one may end up with erroneous diagnosis of any serious lesions. To avoid this, the histopathological and radiological examination should be used as an adjunctive aid to land up with the final diagnosis of any lesion or condition.

CONSENT

All authors declare that 'written informed consent was obtained from the patient (or other approved parties) for publication of this paper and accompanying images.

ETHICAL APPROVAL

It is not applicable.

COMPETING INTERESTS

Authors have declared that no competing interests exist.

REFERENCES

1. Bhaskar SN, Jacoway JR. Pyogenic granuloma: Clinical features, incidence, histology and result of treatment. J Oral Surg. 1950;8:165.
2. Kerr DA. Granuloma pyogenicum. Oral Surg Oral Med Oral Pathol;1951
3. 3.Rekha Krishnapillai, Kurian Punnose, Punnya V. Angadi, Anila Koneru. Oral Pyogenic granuloma – a review of 215 cases in a south Indian teaching hospital, Karnataka, over a period of 20 years. Oral Maxillofac Surg. 2012;16:305-309.
4. Shafer, Hine and Levy. A textbook of oral pathology. Fourth edition, Pennsylvania, Elsevier; 2003.
5. Greenberg MS, Glick M. Burket's oral medicine: Diagnosis and treatment. 10th ed. BC Decker, Hamilton, 141-142.
6. Neville BW, Damm DD, Allen CM, Bouquot JE. Oral and maxillofacial pathology, 2nd ed. WB Saunders. Philadelphia, 437-495.
7. Regezi JA, Sciubba JJ, Jordan RCK. Oral pathology: Clinical pathologic considerations. 4th ed, WB Saunders, Philadelphia. 2003;115-116.
8. Amit Arvind Agrawal. Gingival enlargements: Differential diagnosis and review of literature. World J Clin Cases. 2015;3(9):779-788.
9. Goodman-Topper ED, Bimstein E. Pyogenic granuloma as a cause of bone loss in a twelve year old child: Report of case. ASDJ J Dent Child. 1994;61:55-67.
10. Shivaswamy S, Siddiqui N, Jain SA, Koshy A, Tambwekar S, Shankar A. A rare case of generalised pyogenic granuloma: A case report. Quintessence Int. 2011;42(6): 493-9.