

[Mamatha et. al., Vol.5 (Iss.4: RACSIT), April, 2017]

ICV (Index Copernicus Value) 2015: 71.21

Recent Advances in Computer Science and Information Technology

ISSN- 2350-0530(O), ISSN- 2394-3629(P)

IF: 4.321 (CosmosImpactFactor), 2.532 (I2OR)

InfoBase Index IBI Factor 3.86



**INTERNATIONAL JOURNAL OF RESEARCH –
GRANTHAALAYAH**
A knowledge Repository



RACSIT - 17

DIAGNOSIS AND CLASSIFICATION OF DEMENTIA USING MRI IMAGES

Mamatha K ^{*1}, Dr.H.N.Suma ²

^{*1,2} Department of Medical Electronics, B.M.S college of Engineering, India

DOI: <https://doi.org/10.5281/zenodo.572291>

Abstract

The proposed work is to present an effective approach to diagnose of dementia using MRI images and classify into different stages. There are many manual segmentation algorithms on detection and classification or very simple and specific segmentation algorithms to segment each region of interest exclusively. Thus, the proposed system shall use one of the most effective automatic segmentation techniques on MRI images at once. The regions of interest to segment are CSF (Cerebralspinal fluid), gray matter, and white matter and ventricles using the effective segmentation method called level set segmentation. The features are extracted from these four regions of interest and classification of the dementia is performed using K-nearest neighbor.

Keywords: MRI Images; Dementia; Level Set Segmentation; Region of Interest; K-Nearest Neighbor.

Cite This Article: Mamatha K, and Dr.H.N.Suma. (2017). “DIAGNOSIS AND CLASSIFICATION OF DEMENTIA USING MRI IMAGES.” *International Journal of Research - Granthaalayah*, 5(4) RACSIT, 30-37. <https://doi.org/10.5281/zenodo.572291>.

1. Introduction

Dementia are currently afflicting more than millions to millions people around the global say it's about 36 million [1] and this millions to millions number which are infinitely countable can be increased to grow up to 100 million where it can predicted to extend up to 2050. The dementia are occurred with the age above 65 years, but dementia could be occurred to youngsters also, normally the dementia occurs more in female than male and more over dementia is a disorder not a disease.

The diagnoses of the dementia are typically done through the examination known as the clinical examination [1] of the patient's mental state, which is nothing but the subjective measures of individual health.

The human brain is the main part of the human body and the frontal most part of the central nervous system, where this CNS is formed along with the spinal cord [2] where the cranium, which is a bony box in the skull, will guards it. Since the brain is the main part of the human body it helps to do lots of work like thinking, acting, reasoning, walking, talking etc.

There are different types of technique to study about the brain of healthy and diseased such as CT scan, MRI scan, PET scan, SPECT scan. But Magnetic resonance imaging (MRI) [3] is the fast technique to choice for the study between the healthy and the diseased brain because MR imaging has a unique advantage over the other modalities, where it can provide the multispectral images of tissues based on the important parameters such as proton density, T1 and T2 weighted where the variety of the contrast is available only through MRI.

There are different types of dementia are Alzheimer’s dementia, vascular dementia, mixed dementia, dementia with Lewy’s body, Frontotemporal dementia and others. The below figure shows the pyramid structure of the percentage of the different types of the dementia.

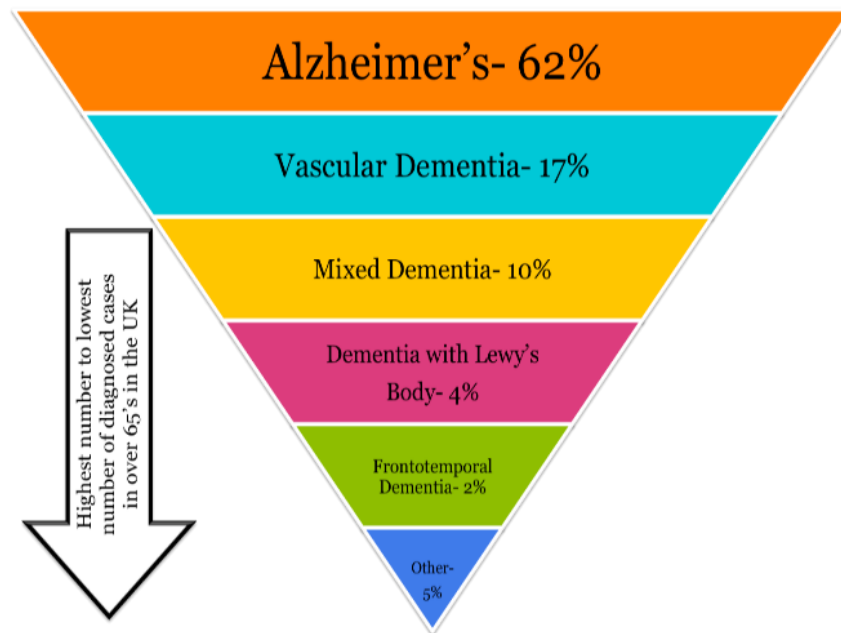


Figure 1: Illustrating the different types of dementia with their percentages

The above i.e. Fig.1 is illustrating the different types of dementia with respect to their decreasing in the percentages thus the structure is called as the inverted pyramid structure where from this pyramid we can tell that Alzheimer’s type of dementia is most dangerous type of dementia and the Frontotemporal dementia is the least type of dementia.

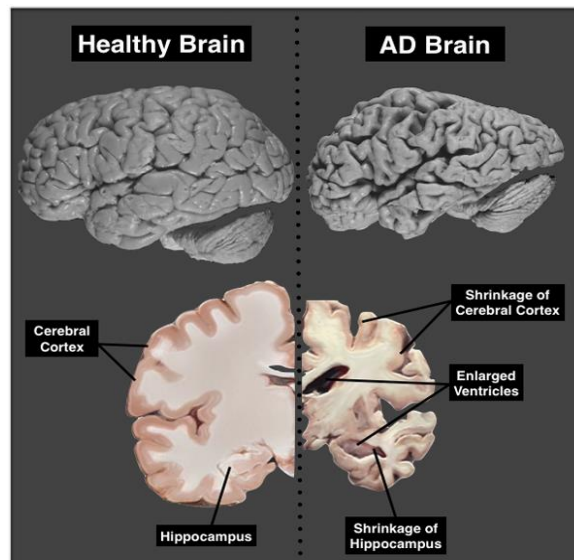


Figure 2: Illustration of the healthy brain and the AD brain

The above figure i.e., Fig.2 illustrating the healthy brain versus the Alzheimer brain, where dementia could be occurred due to the shrinkage of the cerebral cortex, hippocampus and the enlargement of the ventricles.

Thus, there are several proposed methods where the segmentation of cerebral cortex, gray matter, white matter and ventricles was performed.

The automatic segmentation requires less time when compared to the manual segmentation not only that it also provides less variable results from human experts.

Since there are several, manual segmentation algorithms on detecting and classifying by segmenting each region of interest. The automatic segmentation of normal tissues are done [2][3] where it segments the white matter, gray matter and CSF where the whole volume of the brain changes and thus it is segmented with the help of SOFM artificial neural network[3].

Thus, in this proposed system shall use one of the most effective automatic segmentation techniques on MRI images at once. Thus, finally CSF, white matter, gray matter and ventricles are the four region of interest, which are automatically segmented.

In this paper, traces of dementia is done using automatic segmentation algorithm with a KNN classifier. Section II introduces the data collection, Section III introduces the methodology, Section IV introduces the results and Section V introduces the conclusion and future work.

2. Data Collection

The MRI images are collected from the open source, OASIS(open series of imaging studies) where this open source [1] are the project aimed at providing and making MRI data sets of the

brain for free. Thus, there are two MRI data's are available from an open source it is detailed as follows:

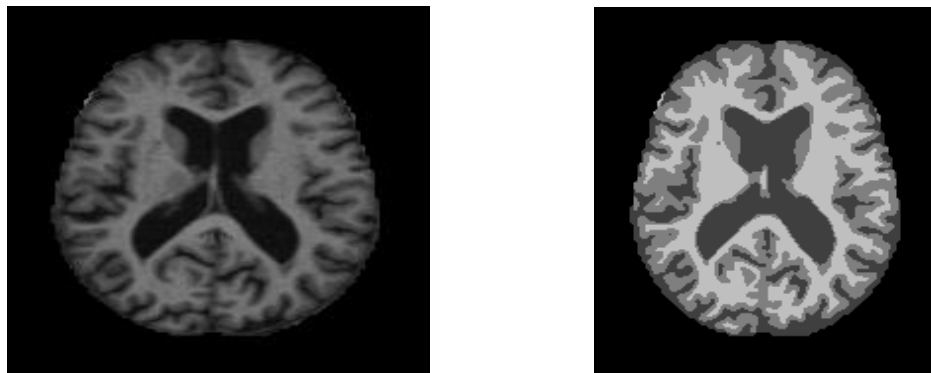
2.1.Cross-Sectional MRI Datasets

This sets consists of a datasets of collection of about 416 subjects aged from 18-96 years, so in this each subjects we can find the 3 or 4 individual T1 weighted MRI scans and all right-handed, and the datasets includes young, middle aged and older adults.

2.2.Longitudinal MRI Datasets

This set's consists of about 150 subjects aged 60 – 96 years, so the datasets are all right-handed and includes only demented and non-demented older adults only.

For our project study, we have considered the cross-sectional MRI datasets.



(a)

(b)

Figure 3: Illustrating the datasets of the cross-sectional MRI datasets (a) T1-weighted image (b) T1-weighted image with segmented colors.

3. Methodology

There are several algorithms are applied for automatic segmentation of CSF, white matter, gray matter and ventricles. Segmentation of gray and white matter spinal cord are fully automated [4] where it involves the steps such as localization using OPAL algorithm and using STEPS algorithm are used[4]. The ventricle boundaries are also done automated segmentation [5] of a normal brain images and where the segmented boundary of the ventricles, navies [5] classifier are applied for classification purposes. As we know that dementia are mostly to occur after the age of 60 years, the gray and white matter are also considered with respect to the age [6] , where volume of CSF , white and gray matter are segmented with respect to the T1-weighted image and their mean and standard deviation that is statistical analysis are done. The segmentation process are carried out for segmenting the brain tissues for the Alzheimer's dementia [7], where they had used the T2- weighted images MR images where they are used the unsupervised neural networks for segmenting the ROI. As, Frontal temporal is also one type of dementia where different techniques are used for segmentation [8] here fuzzy c means algorithm (FCM) are used which is

an unsupervised a type of algorithm which has been widely used for the automatic segmentation process for segmenting ROI.

Thus, methodology followed for this paper is as follows:

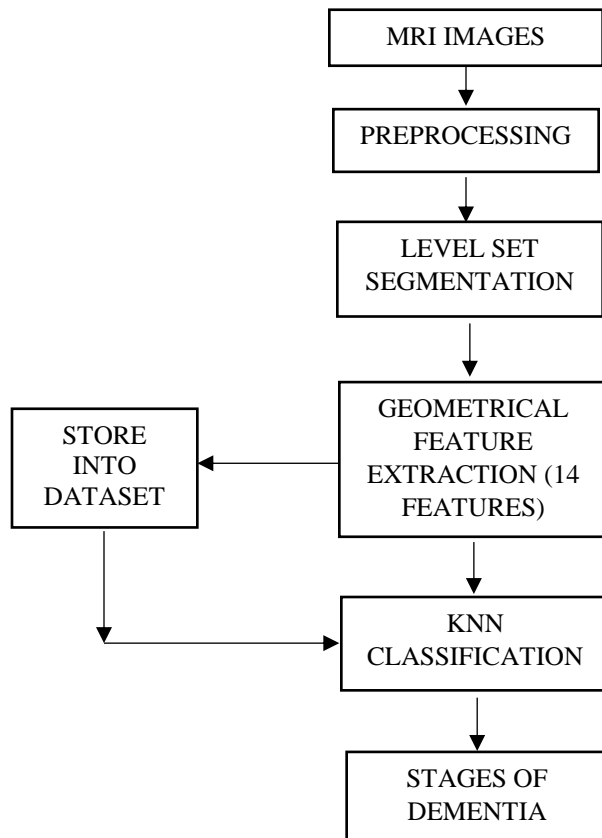


Figure 4: Block diagram of the proposed system

The segmented or T1-weighted MRI images are taken as an input. Thus, the segmentation and feature extraction is performed to classify the stages of dementia.

Pre-processing

Pre-processing is one of the major step or a phase that need to be considered in the medical image application [8], where in the medical image like MRI images of brain may consists of the skull, the outer layer of the image, which is not necessary for the further steps to handle in the medical applications so this pre-processing step in medical image is also called as skull stripping.

Level set segmentation

Segmentation is nothing but the portioning [9] of an image. Thus, the segmentation are done for the region of interest. There are so many segmentation methods but level set segmentation reduces the problem for finding the curve that encloses the regions of interest.

The computations of level set segmentation are as follows:

Usual choice for ψ : signed distance to the front $\gamma(0)$

- $d(x,y,\gamma)$ if (x,y) inside the front

$$\psi(x, y, 0) = \begin{cases} 0 & \text{if } (x, y) \text{ on the front} \\ d(x,y,\gamma) & \text{if } (x, y) \text{ outside the front} \end{cases}$$

Thus, the above equation shows the computational equation, based on the pixel distance with respect to the initial time 0.

Feature extraction

After segmentation process is done for the ROI, next we need extract the features of the ROI and this feature extracted are used for classification.

According to the literature, surveys there are many technique for feature selection process such as PCA and LDA [10] feature selection based on the SVN weight vector. Feature selection-using t-statistics, feature selection using prior knowledge [11].

In this, paper the ROI features are extracted automatically. When the automatic segmentation of the train and test images are segmenting, the geometrical features are automatically stored in the Excel sheet, where based on the features extracted the classification are done.

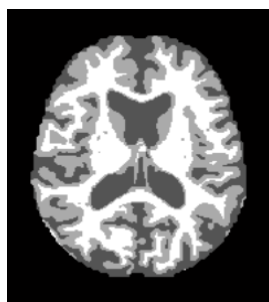
K – nearest neighbor

K nearest neighbor algorithm is a non- parametric method, which is used for both classification and regression. Thus, it is a type of instance-based learning.

Here, we are using KNN algorithm for classification thus the output is a class membership, and K is always be positive integer and typically, it will be small. Thus if $K=1$, then the object is simply assigned to the class of that single nearest neighbor.

In KNN, a commonly used distance metric for the continuous variable is Euclidean distance, thus in this paper the KNN, Euclidean distance will be selected where it is having the minimum distance.

4. Results



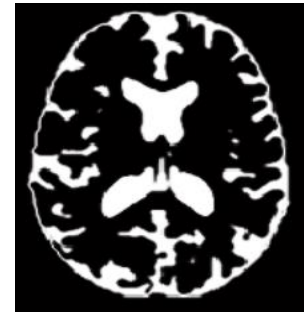(a)



(b)



(c)



(d)

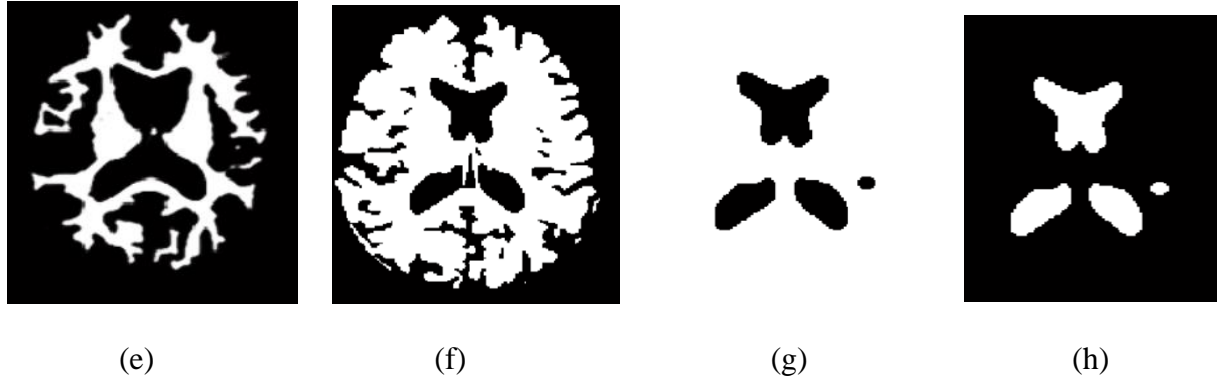


Figure 5: results of the level set segmentation. (a) Input image (b) masked image (c) gray matter segmentation (d) CSF segmentation (e) white matter segmentation (f) segmentation mask (g) ventricles mask (h) ventricles segmentation

Thus, the geometrical features are extracted with respect to the all four ROI and classifiers are used for tracing the different stages of dementia.

5. Conclusion and Future Work

Here 299 images are considered for the training and 110 are considered for the testing. Thus after feature extraction, applying KNN algorithm the overall accuracy was found around 70%, by considering only geometrical features about 14 features.

Thus the future work involves considering textures feature also into consideration along with the geometrical feature and to improve the accuracy and finally the features that are extracted are should be selected properly to increase the accuracy.

Acknowledgement

I would like to thank my guide professor Dr.H.N.Suma, Department of Medical Electronics, B.M.S college of Engineering, Bangalore.

References

- [1] V. Miller, S. Erlien, and J. Piersol, "Identifying dementia in MRI scans using machine learning," pp. 18–22.
- [2] M. Y. Bhanumurthy and K. Anne, "An Automate Segmentation of Brain MRI for detection of Normal Tissues using Improved Machine Learning Approach," pp. 3–8, 2015.
- [3] J. Alirezaie, M. E. Jernigan, and C. Nahmias, "Automatic Segmentation of Cerebral MR Images using Artificial Neural Networks," vol. 45, no. 4, pp. 2174–2182, 1998.
- [4] F. Prados, M. J. Cardoso, M. C. Yiannakas, L. R. Hoy, E. Tebaldi, H. Kearney, M. D. Liechti, D. H. Miller, O. Ciccarelli, C. A. M. G. Wheeler-kingshott, and S. Ourselin, "Fully automated grey and white matter spinal cord segmentation," Nat. Publ. Gr., no. October, pp. 1–10, 2016.
- [5] B. Clangphukhieo, "Automated Segmentation of a Ventricle Boundary from CT Brain Image Based on Naïve Bayes Classifier," pp. 1168–1173.

- [6] Y. Ge, R. I. Grossman, J. S. Babb, M. L. Rabin, L. J. Mannon, and D. L. Kolson, "Age-Related Total Gray Matter and White Matter Changes in Normal Adult Brain . Part I: Volumetric MR Imaging Analysis," no. September, pp. 1327–1333, 2002.
- [7] M. Ito, K. Sato, M. Fukumi, and I. Namura, "Brain Tissues Segmentation for Diagnosis of Alzheimer-Type Dementia," pp. 3847–3849, 2011.
- [8] R. S. Kumari, T. Varghese, P. S. Mathuranath, and C. Kesavdas, "Segmentation of MR Brain Images Using FCM Technique in Frontotemporal Dementia," pp. 27–30, 2012.
- [9] T. F. Chen, "Medical Image Segmentation using Level Sets," pp. 1–8, 2008.
- [10] M. M. Dessouky and T. E. Taha, "Selecting and Extracting Effective Features for Automated Diagnosis of Alzheimer ' s Disease," vol. 81, no. 4, pp. 17–28, 2013.
- [11] E. E. Bron, M. Smits, W. J. Niessen, S. Klein, and D. Neuroimaging, "Feature Selection Based on the SVM Weight Vector for Classification of Dementia," vol. 19, no. 5, pp. 1617–1626, 2015.

*Corresponding author.

E-mail address: k1993mamatha@gmail.com