

## CAROTID INTIMA-MEDIA THICKNESS (IMT): A SURROGATE MARKER OF ATHEROSCLEROSIS

Tanja Rundek<sup>1</sup> and Vida Demarin<sup>2</sup>

<sup>1</sup>Department of Neurology, Division of Stroke and Critical Care, Columbia University in the City of New York, NY, USA

<sup>2</sup>University Department of Neurology, Sestre milosrdnice University Hospital;

**SUMMARY** – Atherosclerosis is chronic, progressive disease of the arterial wall with onset decades prior to its clinical manifestations. Carotid intima-media thickness (IMT) measurement by ultrasound is an important tool for evaluation of early stages of atherosclerosis. Also, carotid intima-media thickness can be used for assessment of therapeutic effect of various regimens. Carotid IMT is sensitive marker of atherosclerosis. The causal relationship between carotid IMT and the clinical endpoint has been established on the basis of epidemiological studies and clinical trials. The strength of carotid IMT as a marker of atherosclerosis is enhanced by the fact that it may yield pathophysiological information at an early stage of atherogenic process.

**Key words:** *Carotid arteries – pathology; Cerebrovascular disorders – pathology; Cerebrovascular disorders – etiology; Arteriosclerosis – diagnosis*

### Introduction

Carotid intima-media thickness (IMT) assessed by B-mode ultrasound is a validated surrogate marker for atherosclerosis that can efficiently identify and describe populations at cardiovascular risk and investigate therapeutic effect of various regimens. Carotid IMT is also a substitute for clinical endpoints, and therefore an important surrogate endpoint. Carotid IMT is sensitive and more readily available than the clinical endpoint, easy to evaluate, and the causal relationship between carotid IMT and the clinical endpoint has been established on the basis of epidemiological studies and clinical trials. In intervention studies, the anticipated clinical benefits were deducible from the observed changes in carotid IMT. Moreover, the strength of carotid IMT as a surrogate marker is enhanced by the fact that it may yield pathophysiological information at an early stage of the disease process.

### Atherosclerosis and Carotid IMT as a Surrogate Endpoint

Atherosclerosis progression with clinical endpoints requires prospective epidemiological studies or intervention clinical trials with long follow up time and participation of large populations. These requirements have to be met in order to provide data from which valid conclusions about determinants of the disease or efficacy of a therapeutic intervention can be drawn. As a consequence, such studies consume precious time and financial resources. To overcome these challenges surrogate markers are currently the focus of intense attention. Such markers might be used to investigate determinants of atherosclerosis at an early stage of the process and can, subsequently, assess disease modifiers of atherosclerosis progression such as lifestyle and pharmacological interventions. Criteria for the validity of such markers as a substitute for clinical endpoints have been proposed<sup>1</sup>. Three conditions for the validity ascertainment are stipulated. First, a surrogate marker should be more sensitive and more readily available (sensitivity and availability) than the clinical endpoint. Also, the surrogate marker should be easy to evaluate (convenient),

Correspondence to: *Tanja Rundek* Department of Neurology, Division of Stroke and Critical Care, Columbia University in the City of New York, NY, USA

Received July 12, 2005, accepted January 3, 2006

preferably by noninvasive means. Second, the causal relationship between the surrogate marker and the clinical endpoint (proximity) should be established on the basis of epidemiological, pathophysiological and clinical studies. This entails a prerequisite that patients with and without vascular disease exhibit differences in surrogate marker measurements (specificity). Third and last, in intervention studies, the anticipated clinical benefits (assessment of benefit) should be deducible from the observed changes in the surrogate marker. The latter argument implies that it is not just cost and time that favors the development of surrogate markers. Validated surrogate markers enable assessment of promising new drugs in a relatively short period of time at a relatively low cost compared to clinical outcome measures, thus obviating the need to await the outcome of trials driven by clinical events<sup>2</sup>. Moreover, the strength of a surrogate marker is enhanced by the fact that it may yield pathophysiological information at an early stage of the disease process. Surrogate markers, therefore, have an inherent value of their own.

Early surrogate markers have originated from techniques available for the clinical assessment of patients with vascular disease, such as angiography and Doppler ultrasound. These techniques have significant clinical relevance but they do not provide useful information on the early stages of arterial wall thickening prior to lesion formation. Doppler ultrasound and angiography can only visualize luminal changes in the very late stages of the disease process. Furthermore, both techniques are inadequate in light of the Glagov effect of initial arterial wall remodeling in the course of atherosclerosis progression<sup>3,4</sup>. In contrast, B-mode ultrasound imaging technology has evolved to such an extent that the walls of superficial arteries can be imaged noninvasively, in real time and at high resolution. Unlike angiography or 'luminology', ultrasound imaging can visualize the arterial wall itself in every stage of atherosclerosis, from 'normal' to complete arterial occlusion. Arterial wall thickness can therefore be measured as a continuous variable from childhood into old age, in patients as well as in healthy controls<sup>5</sup>.

Studies that evaluated the origin of the lumen-intima and media-adventitia ultrasound interfaces in relation to carotid and femoral far wall arterial histology have demonstrated that the distance between these interfaces reflects the intima-media complex. Consequently, this distance is referred to as the intima-media thickness, abbreviated IMT<sup>6,7</sup>. Carotid IMT provides useful

information on the early stages of arterial wall thickening prior to lesion formation and is useful in assessing initial arterial wall remodeling in the course of atherosclerosis. Since B-mode ultrasound is noninvasive, these IMT measurements can be used in observational studies in healthy populations as well as in atherosclerosis regression trials, to assess medication efficacy. A group of international experts have recently started a communication in order to achieve consensus regarding the carotid IMT assessment and its use in cerebrovascular disease (CVD) risk stratification, as an outcome measure in observational studies and clinical trials, and its potential use in clinical practice<sup>8</sup>.

### Carotid IMT and Observational Studies

Carotid IMT measured by B-mode ultrasound was investigated as a determinant of atherosclerotic disease in the general population. Examples of such large follow up studies are the Cardiovascular Health Study (CHS), the Rotterdam Study and the Atherosclerosis Risk in Communities Study (ARIC)<sup>9-12</sup>.

In CHS, among 4476 participants over 65 years of age without clinical cardiovascular disease, carotid IMT was shown to be associated with incident cardiovascular events over a median follow up time of 6 years<sup>9</sup>. The age/sex-adjusted relative risk of myocardial infarction or stroke for the highest quintile of carotid artery IMT was 3.87 compared with the lowest quintile<sup>13</sup>. In the Rotterdam Study, a single-center prospective follow up study in 8000 individuals aged over 55, associations between carotid IMT and stroke, angina pectoris, myocardial infarction, intermittent claudication and essential hypertension were found during a mean follow up of 2.7 years<sup>11</sup>. In ARIC, a study of 15,800 participants, high resolution B-mode ultrasound was shown to be able to assess all stages of atherosclerosis. A seemingly small increase of 0.20 mm in the mean carotid IMT was shown to significantly increase the relative risk of myocardial infarction (33%) and stroke (28%)<sup>12</sup>.

### Carotid IMT and Interventional Studies

B-mode ultrasound measurements of carotid IMT have been used extensively to demonstrate the efficacy of "anti-atherosclerotic effect" of various regimens, predominantly lipid and blood pressure lowering therapies. The 4-year Cholesterol Lowering Atherosclerosis Study (CLAS) assessed the effects of colestipol-niacin thera-

py in men with previous coronary by-pass surgery and showed statistically significant treatment effects after 2 and 4 years of therapy<sup>13</sup>. In the Asymptomatic Carotid Artery Progression Study (ACAPS), a 3-year clinical trial of lovastatin in asymptomatic individuals between 40 and 79 years of age with early carotid atherosclerosis, lovastatin compared to placebo modified the combined IMT of 12 carotid artery wall segments<sup>14</sup>. The Kuopio Atherosclerosis Prevention Study (KAPS) investigated the 3-year efficacy of pravastatin in hypercholesterolemic men between 44 and 65 years of age. In this trial, the primary outcome measure (combined IMT of 4 carotid arterial wall segments) showed near significance and a highly significant effect on common carotid IMT<sup>15</sup>. In the Regression Growth Evaluation Statin Study (REGRESS), a 2-year atherosclerosis regression trial, the efficacy of 40 mg pravastatin was demonstrated by B-mode ultrasound of peripheral arteries, which was not obtained in any of the coronary angiographic parameters of the REGRESS cohort<sup>16</sup>.

The SECURE trial (Study to Evaluate Carotid Ultrasound changes in patients treated with Ramipril and vitamin E), a substudy of the HOPE (Heart Outcomes Prevention Evaluation) trial, evaluated the effects of long-term treatment (4.5 years) with the angiotensin-converting enzyme (ACE) inhibitor ramipril and vitamin E on atherosclerosis progression among 732 high-risk patients over age 55<sup>17</sup>. The SECURE study demonstrated a significant reduction in IMT progression with ramipril (36%), which could not be explained by the effect of the blood pressure lowering alone. The progression slope of the mean maximum carotid IMT was 0.0217 mm/year in the placebo group, and 0.0137 mm/year in the ramipril 10 mg/d group ( $p=0.033$ ). Vitamin E (400 IU/day) had a neutral effect on carotid IMT.

In a 2-year study of aggressive *versus* conventional lipid lowering on atherosclerosis progression (ASAP), the effects of 80 mg atorvastatin and 40 mg simvastatin were investigated in 325 patients with familial hypercholesterolemia (FH)<sup>18</sup>. In this trial, aggressive cholesterol lowering with statins was more effective than conventional statin treatment. Specifically, the study showed an actual decrease in carotid IMT in the most aggressively treated group ( $\pm 51\%$  LDL-cholesterol lowering), whereas the less aggressive treatment ( $\pm 41\%$  LDL-C lowering) only showed inhibition of atherosclerosis progression. The outcome of the 1-year ARBITER, a secondary prevention study in 161 patients with cardiovascular disease and LDL-C of 100 mg/dL, was in line with

the ASAP findings<sup>19</sup>. In the pravastatin group IMT stabilized while in the atorvastatin group the IMT decreased and showed atherosclerosis regression. Further LDL-C lowering, even beyond the present guidelines, may possibly have a favorable effect on arterial walls and consequently on the occurrence of future cardiovascular disease.

The recently completed  $\beta$ -Blocker Cholesterol-Lowering Asymptomatic Study (BCAPS) showed a significant reduction in progression of IMT in the carotid bulb for those on the  $\beta$ -blocker metoprolol *versus* those on placebo, which was apparent after 1 year and sustained at 3 years<sup>20</sup>.

The European Lacidipine Study on Atherosclerosis (ELSA), a randomized, double-blind trial in 2334 patients with hypertension, compared the effects of 4-year treatment based on either lacidipine (a calcium antagonist) or atenolol (a  $\beta$ -blocker) on carotid IMT<sup>21</sup>. Lacidipine had a greater efficacy on carotid IMT progression and number of plaques *per* patient despite a smaller ambulatory blood pressure reduction, indicating an anti-atherosclerotic action of lacidipine independent of its antihypertensive action.

In the Prospective Randomized Evaluation of the Vascular Effects of Norvasc Trial (PREVENT), a randomized placebo-controlled clinical trial, amlodipine (a calcium channel blocker) had a significant effect in slowing the 36-month progression of carotid IMT, whereas it had no demonstrable effect on angiographic progression of coronary atherosclerosis<sup>22</sup>.

### Standardized B-mode Ultrasound Imaging Scanning and Reading Protocol

The assessment of carotid IMT consists of the standardized scanning (image acquisition) and reading protocol (off-line analyses). Standardization of image acquisition and reading protocols is essential in accurate carotid IMT measurements. We present the high-resolution B-mode carotid ultrasound scanning and reading protocols used in the main large epidemiology studies and clinical trials<sup>9,10,12,14-18,23-25</sup>.

#### Carotid IMT scanning protocol

##### *Image acquisition*

Subjects are placed in supine position with the head rotated by 45° to the left using a 45° head pillow. The jugular vein and carotid artery are located in the trans-

verse view with the jugular vein visualized above the carotid artery. The transducer is then rotated by 90° around the central line of the transverse image of the jugular vein-carotid artery to obtain a longitudinal image while maintaining the vessels in the mound position. In addition to the jugular vein above the carotid artery, all images contain anatomical landmarks for reproducing probe angulations, including visualization of the carotid bulb. For each individual, the depth of the field, gain, monitor intensity setting, and all other initial instrumentation settings used at baseline examination are maintained for all follow up examinations. A hardcopy of each individual's baseline image is used as a guide to match the repeat image to the baseline image. This is a direct visual aid method for reproducing probe angulations that has resulted in significant reductions in measurement variability between scans<sup>9,10,23-25</sup>.

All examinations are recorded on the high-speed hard drive in real-time from a single image frame pass. Ultrasound scans are recorded in digital format, compressed and saved as JPEG files. Image acquisition and image scans are digitized according to DICOM standards, which allow for high quality ultrasound image capture, the ability to control measurements from image acquisition to regulatory guidelines for drug trials using image based measurements as endpoints.

### Carotid IMT scanning protocol

The carotid IMT protocol consists of scanning the carotid arteries longitudinally in three segments, using the lateral extent of each carotid segment as defined relative to the tip of the flow divider, which is normally the most clearly defined anatomical reference in the proximity of the carotid bifurcation. The carotid segments are defined as: 1) near wall and far wall of the segment extending from 10 to 20 mm proximal to the

tip of the flow divider into the common carotid artery (CCA); 2) near wall and far wall of the carotid bifurcation beginning at the tip of the flow divider and extending 10 mm proximal to the flow divider tip; and 3) near wall and far wall of the proximal 10 mm of the internal carotid artery (ICA). Using fine transducer angulations to clearly display both the blood-intima and media-adventitia boundaries on both the near and far walls of the artery, the transducer is moved towards the mandible until the lumen area increases with the appearance of the carotid bifurcation, and finally the internal carotid artery is visualized. The focus is positioned at the 40-mm depth of the near or the far wall depending on the optimized image during the scanning.

### Carotid IMT reading protocol

Measurements of carotid IMT are performed off-line using semi-automated or automated edge detection image analysis software. Recorded image sequences are reviewed frame-by-frame to select the best quality images for measurement. On each frame, the visualized blood-intima and media-adventitia boundaries are marked with a mouse-controlled caliper within the defined segment. Leading edges are traced with the calipers for measuring the far walls, and trailing edges are traced for measuring the near walls (Figure 1.).

Total carotid IMT is calculated as a composite measure (mean of the 12 sites) that combines the near and the far wall of the maximal CCA IMT, the maximal bifurcation IMT, and the maximal ICA IMT of both sides of the neck.

Carotid IMT is measured in all carotid segments out of the proportion of plaques. If plaques are present in any of the pre-specified carotid IMT segments, the maximal carotid plaque thickness (MCPT) is measured<sup>23-25</sup>. Atherosclerotic plaques are defined as an area

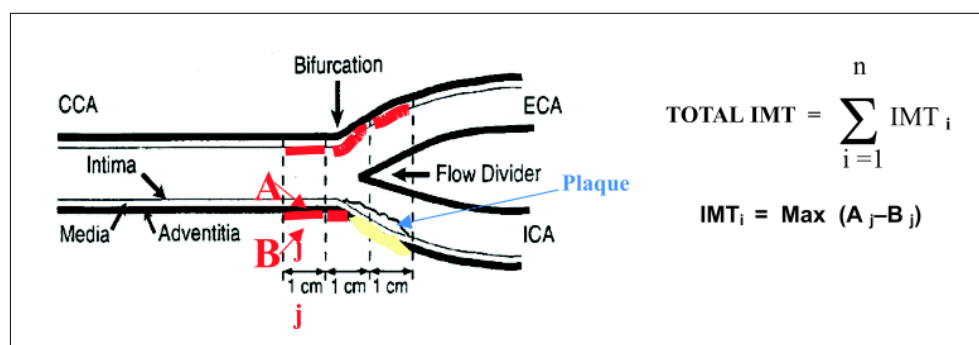


Fig. 1. Carotid intima media thickness measurement

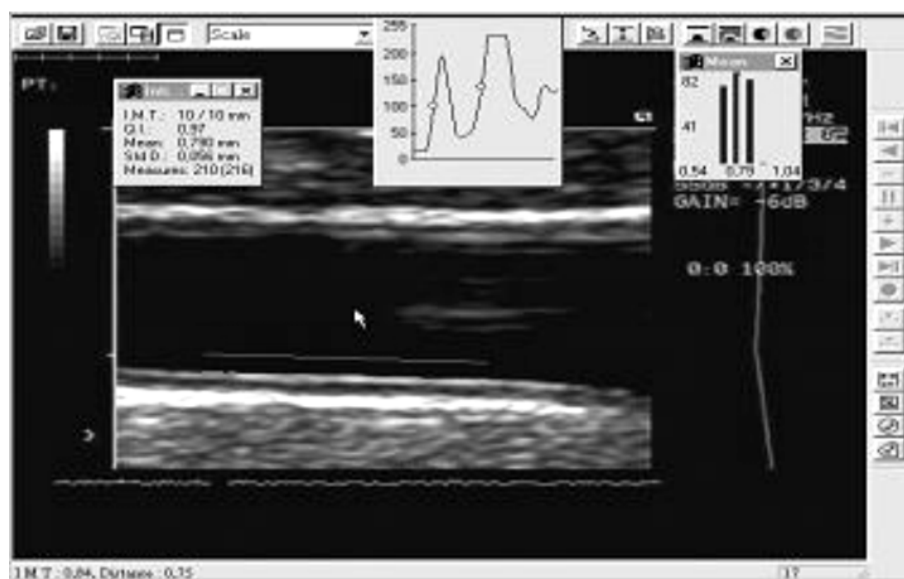


Fig. 2. Multiframe image processing ACET method of carotid IMT

of focal wall protrusion or focal thickening by more than 50% greater than the surrounding wall thickness. Measurements of MCPT in mm are performed at the highest plaque prominence in any of the three carotid artery segments assessed from the multi-angled images.

### Carotid IMT and automatic computerized edge tracking (ACET)

The method of computerized edge tracking-multiframe processing of B-mode ultrasound images represents a technological advance for determining arterial lumen and wall dimensions with direct applicability to noninvasive imaging of atherosclerosis<sup>26-28</sup> (Figure 2.).

The application of the computerized multiframe image processing ACET method to all of the processable frames generates a sequence of carotid IMT. Therefore, ACET processing of B-mode ultrasound images is a highly reproducible, readily available improved method for evaluating IMT, plaque and arterial diameter<sup>29,30</sup>.

### Carotid IMT measurement issues

The intra-observer and inter-observer variability of the carotid IMT measurements is of particular importance. Our reliability studies of carotid IMT using the semi-automated IMT measurement technique as well as the automatic edge detection system were satisfactory. In a sample of 88 stroke-free community subjects from the Northern Manhattan Study (NOMAS), the

mean absolute difference in carotid IMT between two sonographers was  $0.19 \pm 0.36$  mm, variation coefficient 7.5%, correlation coefficient 0.87, and percent error 8.6%. The intra-sonographer mean absolute IMT difference was  $0.07 \pm 0.04$  mm, variation coefficient 5.4%, correlation coefficient 0.94, and percent error 5.6%<sup>25</sup>. These results were similar to those published in other studies<sup>29,30</sup>. Reproducibility of IMT measurements was, however, worse in studies which included measurements of the ICA and bulb as opposed to studies limited only to the CCA<sup>9,10,12,14-18,29-31</sup>. The use of the computerized edge detection and multiframe image processing method improved the reproducibility of these measurements. In a sample from NOMAS, the mean absolute difference in carotid IMT between two readers was  $0.09 \pm 0.04$  mm and variation coefficient 1.5%.

### Conclusion

Atherosclerosis is a protracted disease process of the arterial wall with onset decades prior to its clinical manifestations. To understand the determinants of the process and to develop therapeutic approaches requires life-long follow up if clinical endpoint data are used. This approach needs extensive time and resources. Therefore validated surrogate markers for atherosclerosis that can efficiently identify and describe populations at cardiovascular risk and investigate therapeutic regimens have drawn increasing attention. B-mode ultrasound intima-media thickness measurement is an important

tool for evaluation of arterial wall remodeling and may be used as a valid surrogate marker of atherosclerosis in CVD risk prediction and surrogate endpoint in interventional clinical trials.

## References

- BOISSEL J-P, COLLET J-P, MOLEUR P, HAUGH M. Surrogate endpoints: a basis for a rational approach. *Eur J Clin Pharmacol* 1992;43:235-44.
- DEMOL P, WEIHRAUCH TR. Surrogate endpoints: their utility for evaluating therapeutic efficacy in clinical trials. *Appl Clin Trials* 1998;7:45-56.
- GLAGOV S, WEISENBERG E, ZARINS CK, STANKUNAVICIUS R, KOLETTIS GJ. Compensatory enlargement of human atherosclerotic coronary arteries. *N Engl J Med* 1987; 316:1371-5.
- PROBSTFIELD JL, BYINGTON RP, EGAN DA, ESPELAND MA, MARGITIC SE, RILEY WA Jr, FURBERG CD. Methodological issues facing studies of atherosclerotic change. *Circulation* 1993;87:II74-II81.
- BLANKENHORN DH, HODIS HN. Arterial imaging and atherosclerosis reversal. *Arterioscler Thromb* 1994;14:177-92.
- PIGNOLI P, TREMOLI E, POLI A, ORESTE P, PAOLETTI R. Intimal plus medial thickness of the arterial wall: a direct measurement with ultrasound imaging. *Circulation* 1986; 74:1399-406.
- POLIA, TREMOLI E, COLOMBO A, SIRTORI M, PIGNOLI P, PAOLETTI R. Ultrasonographic measurement of the common carotid artery wall thickness in hypercholesterolemic patients. A new model for the quantitation and follow-up of preclinical atherosclerosis in living human subjects. *Atherosclerosis* 1988;70:253-61.
- TOUBOUL PJ, HENNERICI MG, MEAIRS S, ADAMS H, AMARENCO P, DESVARIEUX M, EBRAHIM S, FATAR M, HERNANDEZ HERNANDEZ R, KOWNATOR S, PRATI P, RUNDEK T, TAYLOR A, BORNSTEIN N, CSIBA L, VICAUT E, WOO KS, ZANNAD F. Mannheim intima-media thickness consensus. On behalf of the Advisory Board of the 3<sup>rd</sup> Watching the Risk Symposium 2004, 13<sup>th</sup> European Stroke Conference, Mannheim, Germany, May 14, 2004. *Cerebrovasc Dis* 2004;18:346-934.
- O'LEARY DH, POLAK JF, KRONMAL RA, MANIOLO TA, BURKE GL, WOLFSON SK *et al.* Carotid-artery intima and media thickness as a risk factor for myocardial infarction and stroke in older adults. *N Engl J Med* 1999;340:14-22.
- KULLER L, BORHANI N, FURBERG C, GARDIN J, MANOLIO T, O'LEARY D *et al.* Prevalence of subclinical atherosclerosis and cardiovascular disease and association with risk factors in the Cardiovascular Health Study. *Am J Epidemiol* 1994;139:1164-79.
- BOTS ML, HOES AW, KOUDESTAAL PJ, HOFMAN A, GROBBEE DE. Common carotid intima-media thickness and risk of stroke and myocardial infarction: the Rotterdam Study. *Circulation* 1997;96:1432-7.
- CHAMBLESS LE, HEISS G, FOLSOM AR, ROSAMOND W, SZKLO M, SHARRETT AR *et al.* Association of coronary heart disease incidence with carotid arterial wall thickness and major risk factors: the Atherosclerosis Risk in Communities (ARIC) Study, 1987-1993. *Am J Epidemiol* 1997;146:483-94.
- BLANKENHORN DH, SELZER RH, CRAWFORD DW, BARTH JD, LIU CR, LIU CH *et al.* Beneficial effects of colestipol-niacin therapy on the common carotid artery. Two- and four-year reduction of intima-media thickness measured by ultrasound. *Circulation* 1993;88:20-8.
- FURBERG CD, ADAMS HP Jr, APPELEGATE WB, BYINGTON RP, ESPELAND MA, HARTWELL T *et al.* Effect of lovastatin on early carotid atherosclerosis and cardiovascular events. Asymptomatic Carotid Artery Progression Study (ACAPS) Research Group. *Circulation* 1994;90:1679-87.
- SALONEN R, NYSSONEN K, PORKKALA E, RUMMUKAINEN J, BELDER R, PARK JS *et al.* Kuopio Atherosclerosis Prevention Study (KAPS). A population-based primary preventive trial of the effect of LDL lowering on atherosclerotic progression in carotid and femoral arteries. *Circulation* 1995; 92:1758-64.
- JUKEMA JW, BRUSCHKE AV, van BOVEN AJ, REIBER JH, BAL ET, ZWINDERMAN AH *et al.* Effects of lipid lowering by pravastatin on progression and regression of coronary artery disease in symptomatic men with normal to moderately elevated serum cholesterol levels. The Regression Growth Evaluation Statin Study (REGRESS). *Circulation* 1995;91:2528-40.
- LONN E, YUSUF S, DZAVIK V, DORIS C, YI Q, SMITH S *et al.* Effects of ramipril and vitamin E on atherosclerosis: the study to evaluate carotid ultrasound changes in patients treated with ramipril and vitamin E (SECURE). *Circulation* 2001;103:919-25.
- SMILDE TJ, van WISSEN S, WOLLERSHEIM H, TRIP MD, KASTELEIN JJ, STALENHOF AE Effect of aggressive *versus* conventional lipid lowering on atherosclerosis progression in familial hypercholesterolaemia (ASAP): a prospective, randomised, double-blind trial. *Lancet* 2001;357(9256):577-81.
- TAYLOR AJ, KENT SM, FLAHERTY PJ, COYLE LC, MARKWOOD TT, VERNALIS MN. ARBITER: Arterial Biology for the Investigation of the Treatment Effects of Reducing Cholesterol: a randomized trial comparing the effects of atorvastatin and pravastatin on carotid intima medial thickness. *Circulation* 2002;106:2055-60.
- WIKLUND O, HULTHE J, WIKSTRAND J, SCHMIDT C, OLOFSSON SO, BONDJERS G. Effect of controlled release/extended release metoprolol on carotid intima-media thickness in patients with hypercholesterolemia: a 3-year randomized study. *Stroke* 2002;33:572-7.
- ZANCHETTI A, BOND MG, HENNIG M, NEISS A, MANCIA G, DAL PALU C *et al.* Calcium antagonist lacidipine slows down progression of asymptomatic carotid atherosclerosis: principal results of the European Lacidipine Study on Atherosclerosis (ELSA), a randomized, double-blind, long-term trial. *Circulation* 2002;106:2422-7.

22. PITT B, BYINGTON RP, FURBERG CD, HUNNINGHAKE DB, MANCINI GB, MILLER ME *et al.* Effect of amlodipine on the progression of atherosclerosis and the occurrence of clinical events. PREVENT Investigators. *Circulation* 2000;102:1503-10.
23. DESVARIEUX M, DEMMER RT, RUNDEK T, BODEN-ALBALA B, JACOBS Jr DR, SACCO RL, PAPAPANOU PN. Periodontal microbiota and carotid intima-media thickness: the Oral Infections and Vascular Disease Epidemiology Study (INVEST). *Circulation* 2005;111:576-82.
24. ELKIND MS, RUNDEK T, SCIACCA RR, RAMAS R, CHEN HJ, BODEN-ALBALA B, RABBANI L, SACCO RL. Interleukin-2 levels are associated with carotid artery intima-media thickness. *Atherosclerosis* 2005;180:181-7.
25. RUNDEK T, ELKIND MS, PITTMAN J, BODEN-ALBALA B, MARTIN S, HUMPHRIES SE *et al.* Carotid intima-media thickness is associated with allelic variants of stromelysin-1, interleukin-6, and hepatic lipase genes: the Northern Manhattan Prospective Cohort Study. *Stroke* 2002;33:1420-3.
26. SELZER RH, HODIS HN, KWONG-FU H, MACK WJ, LEE PL, LIU CR *et al.* Evaluation of computerized edge tracking for quantifying intima-media thickness of the common carotid artery from B-mode ultrasound images. *Atherosclerosis* 1994; 111:1-11.
27. TOUBOUL PJ, PRATI P, SCARABIN PY, ADRAI V, THIBOUT E, DUCIMETIERE P. Use of monitoring software to improve the measurement of carotid wall thickness by B-mode imaging. *J Hypertens Suppl* 1992;10:S37-S41.
28. ZUREIK M, TOUBOUL PJ, BONITHON-KOPP C, COURBON D, BERR C, LEROUX C *et al.* Cross-sectional and 4-year longitudinal associations between brachial pulse pressure and common carotid intima-media thickness in a general population. The EVA study. *Stroke* 1999;30:550-5.
29. BALDASSARRE D, WERBA JP, TREMOLI E, POLI A, PAZZUCCONI F, SIRTORI CR. Common carotid intima-media thickness measurement. A method to improve accuracy and precision. *Stroke* 1994;25:1588-92.
30. RILEY WA, BARNES RW, APPLGATE WB, DEMPSEY R, HARTWELL T, DAVIS VG *et al.* Reproducibility of noninvasive ultrasonic measurement of carotid atherosclerosis. The Asymptomatic Carotid Artery Plaque Study. *Stroke* 1992;23: 1062-8.
31. BOTS ML, EVANS GW, RILEY WA, GROBEE DE. Carotid intima-media thickness measurements in intervention studies. Design options, progression rates and sample size considerations: a point of view. *Stroke* 2003;34:2985-94.

### Sažetak

#### DEBLJINA INTIME MEDIJE KAROTIDNIH ARTERIJA: ZAMJENSKI BILJEG ATEROSKLEROZE

*T. Rundek i V. Demarin*

Ateroskleroza je kronična progresivna bolest stijenke arterija koja počinje desetljećima prije kliničkih manifestacija. Mjerenje zadebljanja intime i medije karotidnih arterija ultrazvukom je značajna metoda za procjenu ranijih stadija ateroskleroze. Osim toga, mjerenje zadebljanja intime i medije karotidnih arterija može poslužiti za procjenu učinka različitih terapijskih postupaka. Zadebljanje intime i medije karotidnih arterija je osjetljiv pokazatelj ateroskleroze. Utvrđena je uzročna povezanost zadebljanja intime i medije karotidnih arterija i kliničkog ishoda temeljem epidemioloških studija i kliničkih pokusa. Značaj zadebljanja intime i medije karotidnih arterija kao pokazatelja ateroskleroze je povećan činjenicom da može pružiti patofiziološke podatke o ranim stadijima ateroskleroze procesa.

*Ključne riječi: Karotidne arterije – patologija; Cerebrovaskularne bolesti – patologija; Cerebrovaskularne bolesti – etiologija; Ateroskleroza – dijagnostika*